

## EXPERIMENTAL IgA NEPHROPATHY INDUCED BY ORAL IMMUNIZATION\*

BY STEVEN N. EMANCIPATOR,<sup>‡</sup> GLORIA R. GALLO, AND MICHAEL E. LAMM

*From the Department of Pathology, New York University Medical Center, New York 10016; and the  
Institute of Pathology, Case Western Reserve University, Cleveland, Ohio 44106*

Clinical and histopathological observations suggest that the mucosal immune system plays a role in the pathogenesis of some forms of human immune complex glomerulonephritis (1, 2). For example, many studies of idiopathic recurrent hematuria (Berger's nephropathy) and glomerulonephritis associated with anaphylactoid purpura (Henoch-Schönlein syndrome), in which immunoglobulin A (IgA) is the predominant or sole Ig deposited in glomeruli, report the clinical association of viral-like respiratory and gastrointestinal syndromes (2-13). Also, much of the body's IgA is derived from gut and respiratory-associated lymphoid tissue (14-16), and an expansion of specific IgA synthesizing cells in mesenteric lymph nodes, spleen, and secretory mucosae and a significant elevation of IgA antibody in serum and exocrine fluids can occur in response to oral immunization (14-21). These considerations prompted the hypothesis that IgA nephropathy can follow a mucosal immune response, such as might result from an infection. To test this hypothesis experimentally, protein antigens were presented to mice in their drinking water for 14 wk. Kidneys from immunized and nonimmunized mice were then examined for evidence of immune deposits.

### Materials and Methods

*Animals.* Female BALB/cAnNCrIBR mice, 6-8 wk old, were obtained from the Charles River Breeding Laboratories, Inc., Wilmington, MA.

*Immunization.* Ovalbumin (OVA),<sup>1</sup> bovine gamma globulin (BGG) (Sigma Chemical Co., St. Louis, MO), and horse spleen ferritin (FER) (Calbiochem-Behring Corp., American Hoechst Corp., San Diego, CA) were used as antigens. Mice (four to six per group) received 100 mg/dl OVA (one group), FER (one group), or BGG (two groups), or water alone (control; three groups) prepared fresh in acidified water (6 mM HCl) on alternate days for 14 wk.

*Sacrifice and Tissue Processing.* After completion of oral immunization, all mice were maintained for an additional 2 d with free access to food and plain acidified water. Under ether anesthesia, mice were bled by transection of the right axillary artery. Sera were frozen at -70°C until assayed (described below). Portions of renal cortex were processed for light and electron microscopy as previously described (22). Slices of the remainder of the kidneys and segments of small intestine, liver, spleen, lung/bronchus, and skin were snap frozen and stored at -70°C. Cryostat sections 4-6  $\mu$ m thick on glass slides were air-dried for 5 min and stored at -70°C for immunofluorescence.

\* Supported in part by grants AI 19073 and CA 32582 from the National Institutes of Health.

<sup>‡</sup> Research Fellow, Kidney Disease Institute, New York State Department of Health.

<sup>1</sup> *Abbreviations used in this paper:* BGG, bovine gamma globulin; BSA, bovine serum albumin; C, complement; ELISA, enzyme linked immunosorbent assay; FER, horse spleen ferritin; PBS, phosphate-buffered saline; OVA, ovalbumin.

*Antisera.* Fluoresceinated goat antisera to mouse IgA, IgM and C3 were obtained from N.L. Cappel Laboratories Inc., Cochranville, PA. Fluoresceinated goat antiserum to mouse IgG was obtained from Calbiochem-Behring Corp. Preparation of rabbit antisera specific for mouse IgA and IgG has been described (23). Rabbit anti-mouse IgM was obtained from N.L. Cappel Laboratories Inc.

Rabbit anti-FER, anti-OVA, and anti-BGG were prepared by immunization with antigen in complete Freund's adjuvant (19, 22). The anti-BGG was absorbed with Sepharose 4B-conjugated normal BALB/c serum to eliminate cross-reactivity with mouse IgG. Each final antibody preparation reacted only with its respective immunogen and not with the other antigens, mouse serum proteins, or MOPC-315 ascites fluid, when tested by double immunodiffusion. Rabbit anti-rat secretory component and rabbit anti-mouse J chain were kindly provided by Dr. Brian Underdown and Dr. Reuben Baumal, respectively. Rhodaminated goat anti-rabbit IgG and peroxidase-conjugated goat anti-rabbit IgG were obtained from Miles Laboratories Inc., Research Products Div., Elkhart, IN. Both goat antisera reacted with all of the rabbit sera, but not with mouse serum, when tested by double immunodiffusion. Indirect immunofluorescence staining of normal BALB/c kidney with each of the rabbit antisera described above, followed by rhodaminated goat anti-rabbit IgG, was negative. Indirect immunofluorescence on sections of mouse intestine with rabbit anti-rat secretory component and rhodaminated goat anti-rabbit IgG revealed bright staining of the apical margins of the lining epithelial cells. Similar sections incubated with rabbit anti-mouse J chain followed by rhodaminated goat anti-rabbit IgG revealed staining of plasma cells in the lamina propria and lining epithelial cells.

*Immunofluorescence.* All immunofluorescence was performed as described previously (19, 22). Incubations with antisera were for 30 min each except as noted. Sections of lung, liver, small intestine, and spleen were examined by a double label sandwich technique to assess antibody to FER, OVA, or BGG in plasma cells which were making IgA, IgG, or IgM by the binding of antigen as previously described (19), using 100  $\mu\text{g}/\text{ml}$  of antigen and appropriate antisera diluted 1:10. In the intestine and bronchus, IgA-producing cells (green fluorescence only), specific IgA-producing cells (both green and red fluorescence), and non-IgA antigen-binding cells (red fluorescence only) were counted in each of three different 400  $\times$  fields from each of three different mice immunized with each of the three antigens (27 fields in all). The arithmetic means of the 9 fields examined for antigen binding for each of the three antigens, and the arithmetic mean of the 27 fields examined for IgA-producing cells were calculated. Sections of skin were stained for IgA with fluoresceinated goat anti-mouse IgA.

Sections of kidney were stained by the direct method for mouse IgA, IgG, IgM, and complement (C3) using fluorescein-conjugated antisera diluted 1:10. In addition, sections of kidney were stained for the presence of antigen with rabbit anti-OVA, rabbit anti-FER, or rabbit anti-BGG (each diluted 1:10) followed by rhodaminated goat anti-rabbit IgG (diluted 1:80). Because of the weak staining for antigen by indirect immunofluorescence with a standard 30 min incubation with the primary (rabbit anti-antigen) antiserum, indirect stains of kidney sections to detect antigen were done with a 120-min incubation of the primary antiserum. The weak staining for antigen with a 30-min incubation of primary antiserum afforded a means to assess the presence of specific antibody (by antigen binding) in the kidney sections by a sandwich technique. This consisted of incubating sections with 100  $\mu\text{g}/\text{ml}$  of antigen, followed by rabbit anti-antigen (for 30 min), and finally rhodaminated goat anti-rabbit IgG.

Kidney sections from six BGG immunized mice and six nonimmunized control mice were each stained for J chain with rabbit anti-mouse J chain (diluted 1:10) followed by rhodaminated goat anti-rabbit IgG (1:80), and for the secretory component with rabbit anti-rat secretory component (diluted 1:15) followed by rhodaminated goat anti-rabbit IgG (1:80).

Coded sections were examined independently by two observers and the intensity of staining was scored as 0-3+. In the occasional instances when the scores from the two observers differed, the section was reexamined (prior to decoding) by both observers and a score was agreed upon. Mice were classified as negative if the score was 0 or trace, and positive if 1+ or greater.

*Light Microscopy.* Coded sections of paraffin-embedded, formalin-fixed kidney from 13 immunized and 12 nonimmunized mice were examined independently by two observers.

*Electron Microscopy.* Coded grids from 15 immunized and 14 nonimmunized mice were

examined and photographed in a Zeiss EM 10 microscope (Carl Zeiss, Inc., NY) and scored as positive (definite electron-dense deposits present) or negative (no electron-dense deposits observed).

*Serum Antibody Levels.* Assays of the specific antibody of each major isotype and of the total Ig of each isotype in immunized and nonimmunized mice were performed by adaptations of the enzyme-linked immunosorbent assay (ELISA) (24, 25). Polyvinylchloride microtiter dishes (Dynatech Laboratories, Inc., Dynatech Corp., Alexandria, VA) were coated with a 1  $\mu\text{g}/\text{ml}$  solution of one of the three protein antigens (to assay for antibody) or with goat anti-mouse IgA, IgG, or IgM (to assay for total Ig of a particular isotype). After three washes, sera diluted in 1% bovine serum albumin (BSA)-0.05% Tween 20-phosphate-buffered saline (PBS) were incubated at ambient temperature for 2 h, with three washes between incubations, in the following sequence: sample (diluted 1:100) or standard mouse serum, isotype-specific rabbit anti-mouse serum (diluted 1:500), and peroxidase-conjugated goat anti-rabbit IgG (diluted 1:1,000). Enzyme activity was detected in the wells by the addition to each well of 150  $\mu\text{l}$  substrate solution (prepared by dissolving 10 mg of *o*-phenylenediamine [Sigma Chemical Co.] in 100 ml distilled water and adding 10  $\mu\text{l}$  30%  $\text{H}_2\text{O}_2$  [Fisher Scientific Co., Pittsburgh, PA] just before use). An Artek model 210 v-beam reader coupled to an Apple II microcomputer (Artek Systems Corp., Farmingdale, NY), kindly made available by Dr. Zoltan Ovary (New York University Medical Center, New York), was used to read the plates. The arithmetic mean of the difference in optical densities at 45 and 0 min in the duplicate wells was taken as the concentration of antibody in arbitrary units. Standard curves were constructed with the values from serially diluted arbitrary standard sera (rabbit anti-OVA, rabbit anti-BGG, rabbit anti-FER) and purified MOPC-315 IgA, a purified monoclonal mouse IgG (44D) (26), and a purified monoclonal mouse IgM (DLK 23603), the last two kindly provided by Dr. Victor Nussenzweig (New York University Medical Center). All the data points fell within the linear portions of the standard curves.

*Hematuria and Proteinuria.* At the time of killing, urine was collected from each mouse by applying pressure to the suprapubic triangle. Drops of urine were placed upon Bili-Labstix (Miles Laboratories, Ames Division, Elkhart, IN) and semiquantitated for protein and blood. BGG immunized mice and nonimmunized control mice (6 per group) were placed in metabolic cages overnight at weekly intervals starting 4 wk before killing. Urine collected under mineral oil was tested for protein and blood with Bili-Labstix.

## Results

*Immunofluorescence in Nonrenal Tissues.* In both intestines and bronchi the number of specific IgA-producing cells in immunized mice was significantly greater than in nonimmunized mice, whereas the total number of IgA-producing cells and the number of specific cells not producing IgA were not significantly different in the immunized and nonimmunized groups (Table I). The binding of antigens other than the immunogen, e.g., OVA or FER binding in BGG-immunized mice, was not different in immunized vs. nonimmunized groups (three to four cells per ten 400  $\times$  fields). These findings indicate that a specific IgA immune response occurred in orally immunized mice.

Sections of liver showed weak fluorescence for IgA around liver cell membranes in both immunized and nonimmunized mice. In sections of spleen there were numerous IgA-positive cells, about equal in number in immunized and nonimmunized mice. Rare antigen binding was demonstrable in plasma cells in the spleen in immunized but not in nonimmunized mice. IgA was always associated with cells in the liver, spleen and gut; there were no extracellular deposits. Sections of skin did not exhibit any staining for IgA.

*Serum Antibody Levels.* The mean serum IgA antibody levels against the three antigens are summarized in Table II. In all cases the mean IgA antibody level against

TABLE I  
Quantification of Plasma Cells in Intestinal and Bronchial Lamina Propria in Immunized and Nonimmunized Mice\*

	Total IgA	Specific IgA	Specific non-IgA
Immunized mice			
Intestine	148 ± 6.0	28 ± 2.7‡	10 ± 1.0
Bronchus	56 ± 2.2	6.2 ± 1.3§	ND¶
Nonimmunized mice			
Intestine	162 ± 6.7	3.2 ± 0.63	12 ± 1.4
Bronchus	52 ± 1.9	2.5 ± 0.70	ND¶

\* Expressed as 10 times the mean number per 400 × field ± 1 SE.

‡ Different from nonimmunized mice ( $P < 0.01$ ).

§ Different from nonimmunized mice ( $P < 0.05$ ).

¶ Not done.

TABLE II  
Mean Serum IgA Antibody Levels\*

Immunogen	Anti-OVA	Anti-FER	Anti-BGG
OVA	87.1 ± 8.45‡	20.3 ± 6.86	49.5 ± 8.24
FER	47.1 ± 12.8	34.1 ± 4.63†	42.0 ± 6.75
BGG	22.0 ± 1.90	18.0 ± 2.96	126.6 ± 10.3†
CON	25.8 ± 5.40	21.0 ± 4.57	44.7 ± 3.02

\* Means of all sera in duplicate ± 1 SE (arbitrary units).

† Different from the anti-antigen level in all other groups in the same column ( $P < 0.001$ ).

the particular immunogen in immunized mice was significantly different from the mean antibody level against the immunogen in nonimmunized mice or in mice immunized with the other antigens ( $P < 0.001$ ). These values, when interpolated into each particular standard curve, indicate 16–32-fold, 16-fold, and 8–16-fold increases in specific IgA antibody in mice orally immunized with BGG, OVA, or FER when compared with nonimmunized controls. There was no difference in levels of IgA antibody to antigens other than the particular immunogen in immunized vs. nonimmunized mice, and there was no significant difference in specific IgG or IgM antibody, or total IgA, IgG, or IgM between immunized and nonimmunized groups. These data, indicating a rise in specific IgA antibody in serum, correlate with the expansion of specific IgA-producing plasma cells observed in mucosae.

*Renal Immunofluorescence and Electron Microscopy.* Table III summarizes the immunofluorescence for IgA and the ultrastructural findings in glomeruli. There was mesangial accumulation of IgA in 14 of 19 immunized mice, but in only 2 of 15 nonimmunized control mice ( $\chi^2 = 9.95$ ;  $0.001 < P < 0.01$ ). In positive mice the staining among glomeruli was uniform throughout the cortex and deposits were restricted to mesangial areas (Fig. 1A). In contrast, there was no difference in the weak staining observed for IgG or IgM between immunized and nonimmunized groups. Deposits of C3 could not be demonstrated in any animal.

Whereas sections of kidney showed only weak fluorescence staining for antigen when incubated with the primary antiserum for 30 min, sections incubated with primary antiserum for 120 min demonstrated uniform diffuse mesangial fluorescence

TABLE III  
Correlation of Immunofluorescence for IgA and Electron-dense Deposits in Glomeruli

Immunogen	Increased serum IgA antibody*	Total number of mice	Positive IgA immunofluorescence‡			Negative IgA immunofluorescence		
			EM positive	EM negative	No EM	EM positive	EM negative	No EM
BGG	+	8	6	1	0	0	1	0
	-	3	1	2	0	0	0	0
OVA	+	3	1	0	1	0	0	1
	-	1	0	0	0	0	0	1
FER	+	0	0	0	0	0	0	0
	-	4	1	1	0	0	0	2
CON	+	0	0	0	0	0	0	0
	-	15	1	1	0	0	12	1

\* + indicates a mean serum antibody level that is  $\geq 2$  SD greater than in nonimmunized mice.

‡ Positive immunofluorescence for IgA is  $\geq 1+$  score by both observers.

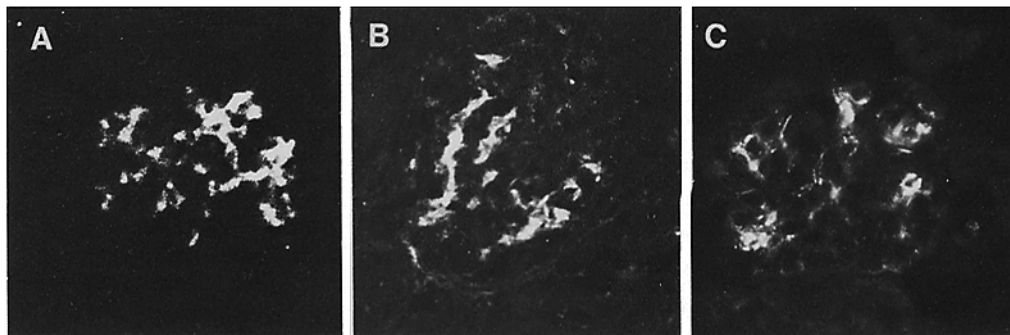


FIG. 1. Glomeruli from mice orally immunized with BGG show mesangial immunofluorescence staining for mouse IgA (A), BGG (B), and mouse J chain (C).  $\times 400$ .

for antigen in 14 of 16 immunized but only 5 of 14 nonimmunized mice examined ( $\chi^2 = 6.54$ ;  $0.01 < P < 0.02$ ) (Fig. 1 B). There was a tendency towards an inverse correlation between the intensity of staining for IgA and that for antigen, although this did not attain significance when tested by the rank-correlation method of Kendall. The presence of BGG in OVA- and FER-immunized mice (1 of 8) was not significantly different from that seen in nonimmunized control mice (3 of 15). Because of positive staining for BGG in occasional mice not immunized with BGG, the rabbit anti-BGG antiserum was absorbed with Sepharose-conjugated BGG. This absorption eliminated staining in all BGG-positive mice, including those not actively immunized with BGG.

The sandwich technique used to investigate the antigen-binding specificity of the deposited mesangial IgA (see Methods and Materials) revealed consistently brighter intensity in 12 of the 15 immunized mice examined but in only 4 of 15 nonimmunized mice when compared with parallel sections preincubated with saline and subsequently stained for antigen with 30 min incubation of primary antiserum ( $\chi^2 = 6.56$ ;  $0.01 < P < 0.02$ ). Binding by the sandwich technique was not seen for protein antigens other than the respective immunogen, except in the case of one OVA-immunized mouse positive for BGG.

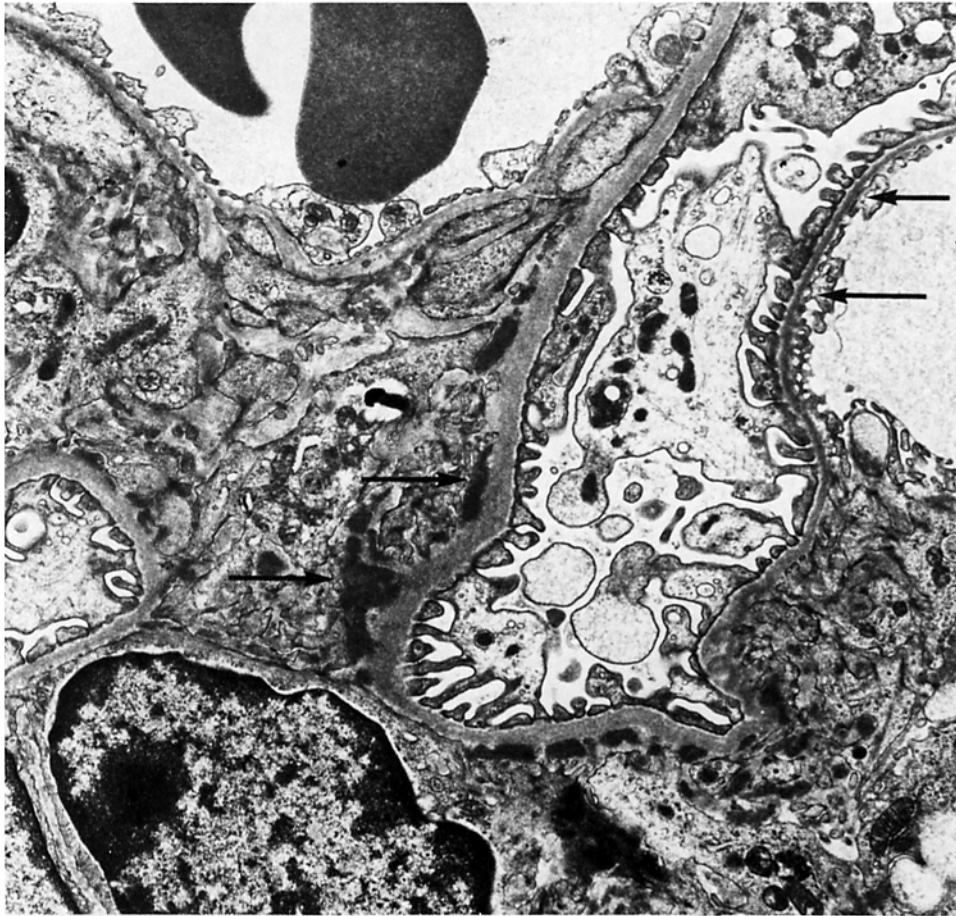

FIG. 2. Electron micrograph of a portion of a glomerulus from a mouse that had been orally immunized with OVA. Electron-dense deposits (left-hand pair of arrows) are present in the mesangium but not in peripheral capillary wall (right-hand pair of arrows).  $\times 8,800$ .

Of six BGG-immunized mice, five revealed mesangial deposition of J chain in a pattern similar to that seen for IgA and antigen (Fig. 1C) whereas none of the six nonimmunized mice showed staining for J chain ( $\chi^2 = 5.49$ ;  $0.01 < P < 0.02$ ). All the mice had trace mesangial staining for IgM, but staining for J chain was only observed in sections which revealed IgA. No secretory component was demonstrable in the six BGG immunized mice or five nonimmunized controls examined.

Electron-dense deposits were observed within mesangial and paramesangial sites (Fig. 2) but not in peripheral capillary walls in 9 of 14 immunized mice examined by electron microscopy (Table III). Of the 14 nonimmunized control mice examined ultrastructurally, only one had electron-dense deposits ( $\chi^2 = 7.6$ ;  $0.01 < P < 0.02$ ). There was a close correlation between mesangial deposition of IgA as assessed by immunofluorescence and electron microscopic deposits: 10 of 15 mice examined by electron microscope in which deposits of IgA were found had electron-dense deposits, whereas none of the 13 mice that were negative for IgA had deposits demonstrable ultrastructurally ( $\chi^2 = 10.7$ ;  $P < 0.001$ ).

*Light Microscopy.* No changes were observed by light microscopy in any animal.

*Hematuria and Proteinuria.* Urine from mice studied periodically by placement in metabolic cages revealed sporadic proteinuria but no hematuria in both immunized and control groups, nor could hematuria or proteinuria be consistently demonstrated in any group at the time of killing.

### Discussion

The major finding that emerged from these studies is that orally administered antigen can induce a specific IgA mucosal immune response that results in glomerular mesangial deposits of specific IgA antibody and antigen, which is indicative of immune complexes. Several observations support this conclusion. First, there was codeposition of specific IgA antibody and immunogen in the same distribution by immunofluorescence, plus mesangial electron-dense deposits in the glomeruli of immunized mice. These findings were significantly different from those in nonimmunized mice. Second, the specific immunogen, but neither of the other two antigens used, was demonstrated in the glomeruli of each immunized group. Third, incubation of tissue sections with each of the three different antigens indicated that the immunogen for each group was the only one which bound to glomeruli containing IgA antibody. Thus, not only was the deposition of IgA statistically more frequent in immunized than in nonimmunized mice, but antigen deposition and antibody specificity were dependent upon the particular immunogen used. If the demonstration of antigen by immunofluorescence had been due to other factors, such as nonspecific binding of the protein antigens to deposited immunoglobulin or altered renal tissue, this specificity for the particular immunogen would be difficult to explain. We speculate that the correlation of active mucosal immunity with IgA glomerulopathy in this model has relevance to human IgA nephropathies, especially those associated with viral syndromes.

The association of glomerular immune complexes with specific IgA antibody in serum and the expansion of specific IgA producing plasma cells in the mucosae of immunized but not nonimmunized mice clearly supports a role for the secretory immune system in the pathogenesis of this model. The immune response was restricted in terms of immunoglobulin isotype, in that the expansion of specific plasma cells, elevated serum antibody levels, and renal deposits were all observed in association with only one Ig class, namely IgA.

The fact that in the kidneys of immunized animals it was easier to demonstrate binding of exogenous antigen to sections than to demonstrate antigen already present suggests that the deposits were in antibody excess. However, initial deposition of serum immune complexes in glomeruli is in general favored by antigen excess (27), so that it is a good possibility that the antigen demonstrated was largely originally deposited relatively early during the immune response when circulating complexes would be expected to be in antigen excess. As the secretory immune response then gained momentum, absorption of additional antigen from the lumen of the intestine would diminish. During the course of the continuing mucosal immune response some of the newly synthesized IgA that directly entered the circulation could combine with complexes already in the glomeruli, and convert them to antibody excess. In a sense, if this concept is correct, IgA nephropathy would be a subversion of the natural barrier function of IgA as it normally operates in mucosal secretions. The IgA

antibody is encountering antigen inside the body (in the case of an intramucosal infection, for example) instead of intralumenally outside the body proper, and thus the resulting immune complexes become noxious rather than being simply excreted without ever gaining access to the interior of the body.

The site of the initial formation of immune complexes in the model is not absolutely certain. Complexes could form in the lumen of the gut, in some compartment of the extracellular fluid, or possibly in situ within the mesangial matrix itself. It is likely, however, that the complexes form in the extracellular fluid. The predominant antibody in complexes formed within the intestinal lumen would be secretory IgA, with a molecular weight of 400,000 and four combining sites for antigen in each molecule. Complexes formed with secretory IgA would therefore be large. Although absorption of immune complexes formed at extreme antigen excess has been described with IgG immune complexes (28), in an orally primed host, the absorption of antigen, free or bound in immune complexes, was significantly reduced. In addition, the lack of secretory component in mice with IgA glomerular deposits is evidence against the absorption of secretory IgA immune complexes from the gut lumen. Most likely, in the model some antigen is initially absorbed and then combines with IgA antibody within the extracellular fluid. The IgA in this case would lack secretory component, which is consistent with our observations and with the rarity of secretory component in human idiopathic IgA nephropathy (1, 2, 4).

The lack of C3 deposition in glomeruli, histologic changes such as mesangial proliferation or increased matrix, and hematuria/proteinuria are the major differences between this murine model and the human disease. Biopsies in humans are necessarily limited to instances in which clinical manifestations are apparent but such manifestations are quite variable. Moreover, light microscopic changes are absent in up to 20% of the cases of the human disease, and complement is not always demonstrable (1). Interestingly, in clinical studies that assess the role of liver disease in the pathogenesis of IgA nephropathy, an asymptomatic subpopulation has been identified (8-11, 29). If one accepts the immunopathological findings in such patients as within the spectrum of the disease, then the model described in this work corresponds to the more mild human cases.

Differences in the chronicity of immune stimulation and the intensity and character of the immune response, or a species difference in activation of complement with its phlogogenic sequelae, might account for some of the differences noted between the model and the typical human disease. In the model there may be a prolonged low dose of exogenous antigenic stimulation as opposed to the intense acute exposure to antigen that could occur with intramucosal infection. Moreover, during infection a replicating agent could elicit a more pronounced antibody response, and because of the invasive properties of infectious agents, they or their shed antigens could penetrate the mucosal surface, enter the interior of the body, and elicit an IgG and/or IgM component to the response.

The biologic mechanisms underlying proteinuria, hematuria, and the proliferation of glomerular cells and matrix are currently unclear. Generally the factors which modulate immunologic injury are labile. If this holds true for immunologically mediated renal injury, whether consequent to immune complex deposition, complement deposition, or some combination, then the rate as well as the amount of deposition of immune reactants would be significant. The contrast between a presum-



ably rapid, intense aggregation and deposition of immune complexes during the course of an intramucosal infection vs. the gradual protracted immune complex deposition in the model could then be expressed as the distinction between the injury usually seen in human IgA nephropathy and the seemingly more mild changes in the model.

Complement deposition may or may not fully account for the histologic changes and/or hematuria and proteinuria in the human disease. The lack of complement deposition in the glomeruli of immunized mice in these studies, whether accounting for the lack of other findings or not, is the major immunopathologic difference between the model and human IgA nephropathy. Several factors may explain this difference. Slow deposition of antibody in a chronic time course might limit the positive feedback component of the alternative pathway C3 convertase, thereby limiting complement deposition. In two previous studies of experimental murine IgA nephropathy, Rifai et al. (27) injected large (milligram range) doses of antigen and specific antibody, and Isaacs et al. (30) injected doses of antigen (milligram range) in an active model. Both studies reported C3 deposition in the glomeruli in a distribution similar to that of IgA. Parenteral administration of comparatively large doses of immune reactants in these studies distinguishes them from our work. Although we have shown that enteric administration of antigen can lead to immune complex deposition in the kidney, the rate of deposition would be expected to be less under the conditions of our model.

Second, there is evidence that immune complexes containing only IgA antibody fix complement by the alternative pathway but that this complement fixation (in the mouse) is limited to the fluid phase (31), whereas complexes with some IgG or IgM can result in the full activation of the membrane attack complex. The apparently pure IgA immune response observed in our model of IgA nephropathy, compared with the usual admixture of IgG and/or IgM in the human disease, might account for the differences in C3 deposition. More fulminant mucosal antigenic exposure with penetration of antigen into the extracellular fluid could lead to an associated IgG or IgM antibody response, which would favor C3 deposition. This idea is further supported by the observations of some authors that codeposition of IgG and/or IgM in humans correlates with a more severe disease (4-7, 12). Finally, species differences in the capacity of pure IgA immune complexes to promote full complement fixation may exist between mice and men.

An additional difference in the immunopathological findings in this study vs. the human disease relates to the polymerization of the IgA. Although all the IgA deposits in our experiments contained J chain, which indicates that at least some of the IgA was dimeric or oligomeric, J chain has not been described in the human disease (1). The higher percentage of IgA dimers and oligomers in normal mouse serum compared with human serum (32) could account for this.

The model used here affords a basis for further study of the mechanisms and determinants of glomerular immune deposits in IgA nephropathy. By altering the rate, dose, and nature of the antigenic stimulation and the method of immunization, by effecting changes in the natural tissue handling of IgA and IgA immune complexes, and by more precisely quantifying immune reactants localized to glomeruli, it should be possible to identify the most significant factors which promote or retard IgA immune deposits and to elucidate the mechanisms by which these deposits form.

### Summary

To test the hypothesis that IgA nephropathy can result from a mucosal immune response, mice were orally immunized with one of three protein antigens for 14 wk. Such mice exhibited an essentially pure mucosal antibody response characterized by specific IgA-producing plasma cells in exocrine sites and specific IgA antibodies in serum. Furthermore, 73% of immunized mice had IgA and 88% had immunogen deposited in the glomerular mesangium, and 64% of immunized mice examined ultrastructurally had electron-dense mesangial deposits. All three were present concurrently in 57% of the immunized mice. No differences in regard to IgG or IgM were observed between immunized and control mice for any of these parameters. Mucosal immunization therefore can result in a specific immune response that leads to mesangial deposition of immune complexes containing IgA antibody. In its fundamental features the experimental renal lesion resembles that seen in the human disease IgA nephropathy.

The authors wish to express their gratitude for the excellent technical assistance of Ms. Susan Schechter-Buda, Ms. Beatrice Delgado, and Ms. Virginia Myer, and to thank Ms. Bonnie Berry for preparation of the manuscript.

*Received for publication 13 September 1982 and in revised form 28 October 1982.*

### References

1. Emancipator, S. N., G. R. Gallo, and M. E. Lamm. 1981. IgA nephropathy: clinical, morphologic and immunologic features. *Surg. Pathol. Q. Index.* 3:179.
2. Dobrin, R. S., F. E. Knudson, and A. F. Michael. 1975. The secretory immune system and renal disease. *Clin. Exp. Immunol.* 21:318.
3. Berger, J. 1969. IgA glomerular deposits in renal disease. *Transplant. Proc.* 1:939.
4. McCoy, R. C., C. R. Abramowsky, and C. C. Tisher. 1974. IgA nephropathy. *Am. J. Pathol.* 76:126.
5. Baart de la Faille-Kuyper, E. H., L. Kater, R. H. Kuijten, C. J. Kooiker, S. S. Wagenaar, P. van der Zouwen, and E. J. D. Mees. 1976. Occurrence of vascular IgA deposits in clinically normal skin of patients with renal disease. *Kidney Int.* 9:424.
6. Woodroffe, A. J., N. M. Thomson, R. Meadows, and J. R. Lawrence. 1975. IgA-associated glomerulonephritis. *Aust. N. Z. J. Med.* 5:97.
7. Clarkson, A. R., A. E. Seymour, A. J. Thompson, W. D. G. Haynes, Y.-L. Chan, and B. Jackson. 1977. IgA nephropathy: a syndrome of uniform morphology, diverse clinical features, and uncertain prognosis. *Clin. Nephrol.* 8:459.
8. Nochy, D., P. Callard, B. Bellon, J. Bariety, and P. Druet. 1976. Association of overt glomerulonephritis and liver disease: a study of 34 patients. *Clin. Nephrol.* 6:422.
9. Berger, J., H. Yaneva, and B. Nabarra. 1978. Glomerular changes in patients with cirrhosis of the liver. *Adv. Nephrol.* 7:3.
10. Woodroffe, A. J., A. A. Gromly, P. E. McKenzie, A. M. Wootton, A. J. Thompson, A. E. Seymour, and A. R. Clarkson. 1980. Immunologic studies in IgA nephropathy. *Kidney Int.* 18:366.
11. Whitworth, J. A., S. Leibowitz, M. C. Kennedy, J. S. Cameron, and C. Chantler. 1976. IgA and glomerular disease. *Clin. Nephrol.* 5:33.
12. Morel-Maroger, L., A. Leatham, and G. Richet. 1972. Glomerular abnormalities in nonsystemic diseases. Relationship between findings by light microscopy and immunofluorescence in 433 renal biopsy specimens. *Am. J. Med.* 53:170.

13. Kauffmann, R. H., W. A. Herrmann, C. J. L. M. Meyer, M. R. Daha, and L. A. van Es. 1980. Circulating IgA immune complexes in Henoch-Schoenlein purpura. *Am. J. Med.* **69**:859.
14. Craig, S. W., and J. J. Cebra. 1975. Rabbit Peyer's patches, appendix and popliteal lymph node B-lymphocytes: a comprehensive analysis of their membrane immunoglobulin components and plasma cell precursor potential. *J. Immunol.* **114**:1599.
15. Rothberg, R. M., C. H. L. Rieger, S. C. Kraft, and J. V. Lustig. 1978. Development of humoral antibody following the ingestion of soluble protein antigen by passively immunized animals. In *Secretory Immunity and Infection*. J. R. McGhee, J. Mestecky, and J. L. Babb, editors. Plenum Publishing Corp., New York. 123-142.
16. Vaerman, J.-P., and J. F. Heremans. 1970. Origin and molecular size of IgA in the mesenteric lymph of the dog. *Immunology.* **18**:27.
17. Crabbé, P. A., D. R. Nash, H. Bazin, H. Eyssen, and J. F. Heremans. 1979. Antibodies of the IgA type in intestinal plasma cells of germfree mice after oral or parenteral immunization with ferritin. *J. Exp. Med.* **130**:723.
18. Lamm, M. E. 1976. Cellular aspects of immunoglobulin A. *Adv. Immunol.* **22**:223.
19. Weisz-Carrington, P., M. E. Roux, M. McWilliams, J. M. Phillips-Quagliata, and M. E. Lamm. 1979. Organ and isotype distribution of plasma cells producing specific antibody after oral immunization: evidence for a generalized secretory immune system. *J. Immunol.* **123**:1705.
20. Mestecky, J., J. R. McGhee, R. R. Arnold, S. M. Michalek, S. J. Prince, and J. L. Babb. 1978. Selective induction of an immune response in human external secretions by ingestion of bacterial antigen. *J. Clin. Invest.* **61**:731.
21. Montgomery, P. C., I. M. Lemaitre-Coelho, and J.-P. Vaerman. 1980. Molecular diversity of secretory IgA anti-DNP antibodies elicited in rat bile. *J. Immunol.* **125**:518.
22. Gallo, G. R., T. Caulin-Glaser, and M. E. Lamm. 1981. Charge of circulating immune complexes as a factor in glomerular basement membrane localization in mice. *J. Clin. Invest.* **67**:1305.
23. McWilliams, M., M. E. Lamm, and J. M. Phillips-Quagliata. 1975. Surface and intracellular markers of mouse mesenteric and peripheral lymph node and Peyer's patch cells. *J. Immunol.* **113**:1326.
24. Cantarero, L. A., J. E. Butler, and J. W. Osborne. 1980. The adsorptive characteristics of proteins for polystyrene and their significance in solid-phase immunoassays. *Anal. Biochem.* **105**:375.
25. Engvall, E. 1980. Enzyme immunoassay: ELISA and EMIT. *Methods Enzymol.* **70**:419.
26. Iida, K., R. Mornaghi, and V. Nussenzweig. 1981. Complement receptor deficiency in erythrocytes from patients with systemic lupus erythematosus. *J. Exp. Med.* **155**:1427.
27. Rifai, A., P. A. Small, P. O. Teague, and E. M. Ayoub. 1979. Experimental IgA nephropathy. *J. Exp. Med.* **150**:1161.
28. Walker, W. A., S. N. Abel, M. Wu, and K. J. Bloch. 1976. Intestinal uptake of macromolecules. V. Comparison of the in vitro uptake by rat small intestine of antigen-antibody complexes prepared in antibody or antigen excess. *J. Immunol.* **117**:1028.
29. Callard, P., G. Feldmann, D. Prandi, M. F. Belair, C. Mandet, Y. Weiss, P. Druet, J. P. Benhamou, and J. Bariety. 1975. Immune complex type glomerulonephritis in cirrhosis of the liver. *Am. J. Pathol.* **80**:329.
30. Isaacs, K., F. Miller, and B. Lane. 1981. Experimental model for IgA nephropathy. *Clin. Immunol. Immunopath.* **20**:419.
31. Pfaffenbach, G., M. E. Lamm, and I. Gigli. 1982. Activation of the guinea pig alternative complement pathway by mouse IgA immune complexes. *J. Exp. Med.* **155**:231.
32. Vaerman, J.-P. 1973. Comparative immunochemistry of IgA. In *Research in Immunochemistry and Immunobiology*. J. B. G. Kwapinski, editor. University Park Press, Baltimore. **3**:91-183.