

REACTIVE LYMPHOCYTES IN LACRIMAL GLAND AND  
VASCULITIC RENAL LESIONS OF AUTOIMMUNE MRL/*lpr*  
MICE EXPRESS L3T4

BY DOUGLAS A. JABS AND ROBERT A. PRENDERGAST

*From The Wilmer Ophthalmological Institute, The Johns Hopkins University School of  
Medicine, Baltimore, Maryland 21205*

MRL/Mp-*lpr/lpr* (MRL/*lpr*) mice spontaneously develop an autoimmune disorder characterized by glomerulonephritis, vasculitis, autoantibodies to nucleic acids, and massive lymphadenopathy (reviewed in reference 1). Previous analyses of the enlarged lymph nodes have demonstrated that the proliferating cells are T cells, expressing both Thy-1 and Lyt-1 (1-4), and are thought to be Th cells because they lack Lyt-2 (3, 4), a cell surface marker found on suppressor/cytotoxic T cells (Ts), and because they support Ig production by B cells in culture (5). Although these cells are considered to be Th cells, they do not express L3T4 (4), a more recently defined cell surface antigen that is analogous to the human marker Leu-3/T4 (6). L3T4 appears to participate in the T cell response to class II major histocompatibility antigens on APCs (7), and is recognized by the mAb GK 1.5 (6).

Among the many autoimmune lesions of MRL/*lpr* mice is lacrimal gland inflammation consisting of multiple foci of mononuclear inflammatory cells (8, 9). These lesions are not seen in the lacrimal glands of control strains such as BALB/c or C3H/HeJ. ~75% of MRL/*lpr* mice develop vasculitis, commonly present in the kidney and other viscera (1, 10, 11). In this communication, we report the results of immunohistologic analysis of the lacrimal gland inflammatory and renal vasculitic lesions in MRL/*lpr* mice and demonstrate that the majority of the mononuclear inflammatory cells present are T cells that express L3T4, a finding strikingly dissimilar to the lymphocyte population in the enlarged nodes.

**Materials and Methods**

*Mice.* 4-wk-old MRL/*lpr* mice were obtained from The Jackson Laboratory (Bar Harbor, ME) and kept under standard conditions in the animal facilities of the Woods Research Building of the Johns Hopkins Hospital. 20-26-wk-old animals were killed by exsanguination, and exorbital lacrimal glands, cervical lymph nodes, and kidneys were removed. One of the lacrimal gland specimens and one-half of each kidney were fixed in 4% buffered formaldehyde, embedded in paraffin, sectioned at 5  $\mu$ m, and stained with hematoxylin and eosin. The other lacrimal gland, half of the kidney, and lymph node were embedded in OCT, frozen in liquid nitrogen, sectioned at 6  $\mu$ m on a cryostat, and stained as outlined below.

*Immunohistologic Analysis.* Frozen sections of lacrimal gland and kidney were stained

This work was supported in part by U. S. Public Health Service grants EY-05912 and EY-01765.

TABLE I  
Immunohistologic Staining of MRL/lpr Lesions

Tissue	Mean percent ( $\pm$ SD) of mononuclear cells recognized by mAb against:				
	Thy-1.2	L3T4	Lyt-2	sIg	Mac-3
Lacrimal gland	85 $\pm$ 5 (75-92)*	64 $\pm$ 9 (51-83)	14 $\pm$ 4 (5-19)	10 $\pm$ 2 (7-14)	3 $\pm$ 2 (1-6)
Renal vasculitis	85 $\pm$ 4 (77-89)	58 $\pm$ 8 (49-70)	12 $\pm$ 3 (8-16)	5 $\pm$ 1 (5-7)	3 $\pm$ 1 (1-4)

\* Range.

with the panel of mAbs to cell surface markers using the avidin-biotin-peroxidase complex (ABC) technique (12). The mAbs used for purposes of identification were the following: rat anti-Thy-1.2 (Becton Dickinson, Mountain View, CA) for T cells (13); rat anti-L3T4 (GK 1.5, ATCC, Rockville, MD or Becton Dickinson & Co., Mountain View, CA) for Th cells (6, 7); rat anti-Lyt-2 (Becton Dickinson & Co.) for Ts cells (13); rat anti-Mac-3 (M3/84.6.34; American Type Culture Collection, Rockville, MD) for macrophages (14); and goat F(ab')<sub>2</sub> anti-mouse IgG + IgM (Tago Inc., Burlingame, CA) for surface Ig on B cells (sIg). Briefly, frozen sections were fixed in chilled (4°C) acetone, air dried, rehydrated in PBS, and incubated with the appropriate blocking agent (Vector Laboratories, Inc., Burlingame, CA) for 20 min. The primary mAb was applied, and the slides were incubated for 60 min. For rat anti-mouse monoclonals, adjacent sections on a separate slide were incubated with normal rat IgG as a negative control. Slides were washed in PBS and then incubated with the biotinylated secondary antibody for 30 min. The secondary antibody used for rat anti-mouse monoclonals was a rabbit anti-rat IgG, adsorbed for mouse activity (Vector Laboratories, Inc.), and for goat anti-mouse primary antibodies, a rabbit anti-goat. Slides were rinsed in PBS, incubated with the ABC reagent for 45 min, washed again in PBS, developed with a hydrogen peroxide (0.01%) and 3-amino-9-ethyl-carbazole-containing acetate buffer, and counterstained with Harris' hematoxylin. Lymph node sections from each animal were simultaneously stained to compare with the lacrimal gland, kidney, and previously published results for MRL/lpr lymph nodes (2-4). The percentage of mononuclear inflammatory cells staining positively with a given mAb was enumerated using a 10  $\times$  20 grid net micrometer disc, covering an area of 0.16 mm<sup>2</sup> with a 25 $\times$  objective; the average number of cells counted for each determination was 1,300.

## Results

All animals used for immunohistologic staining of the lacrimal gland had advanced lacrimal gland disease, with multiple foci of mononuclear inflammatory cells present in the gland (9). Lacrimal glands of 13 MRL/lpr mice, 8 male and 5 female, 20-26 wk old (mean, 22 wk), were analyzed, and the results are summarized in Table I. No differences in the lacrimal gland lesions were detected between male and female mice. The vast majority of cells in the lacrimal gland lesions stained for Thy-1.2 (75-92%, mean 85%) and were thus identified as T cells (Fig. 1). Furthermore, 51-83% (mean, 64%) of the mononuclear inflammatory cells in the lacrimal gland lesions stained with antibody to L3T4 (Fig. 2). A small but clearly stained minority of cells stained for Lyt-2 (5-19%; mean, 14%). Macrophages and B cells were less common in the inflammatory foci (Table I).

The kidneys used for immunohistologic staining were selected for the presence

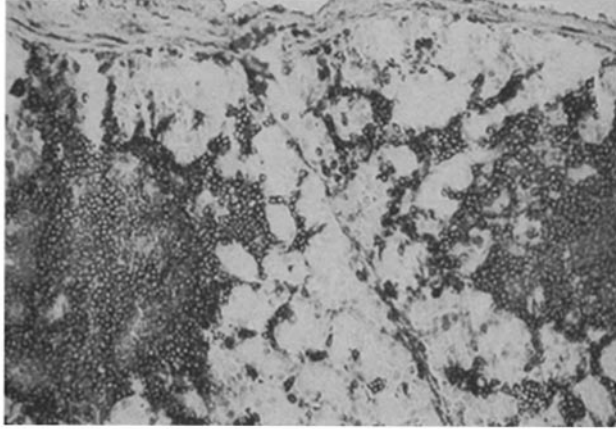


FIGURE 1. Lacrimal gland of a 20-wk-old female MRL/*lpr* mouse stained for Thy-1.2, showing two inflammatory foci in two adjacent lobules. Original magnification,  $\times 40$ .

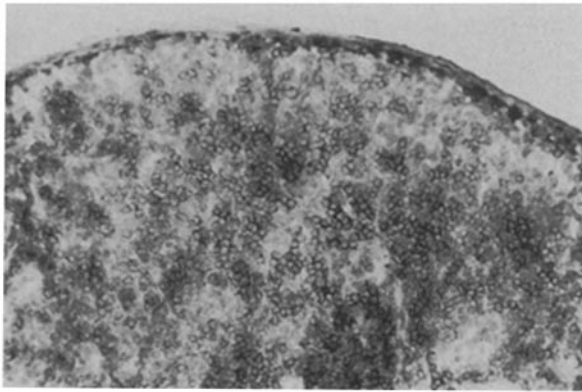


FIGURE 2. Lacrimal gland of a 21-wk-old female MRL/*lpr* mouse stained for L3T4. Original magnification,  $\times 40$ .

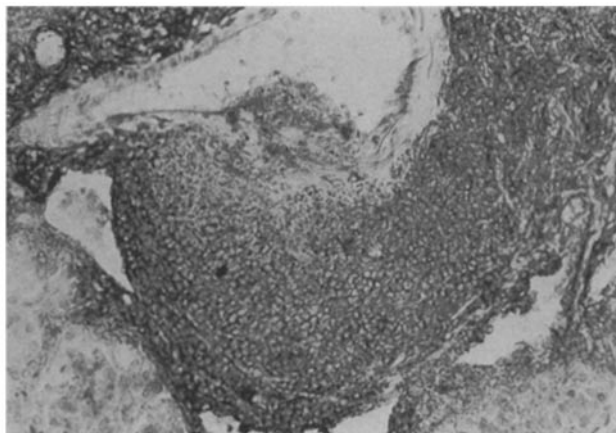


FIGURE 3. Renal vasculitic lesion of a 26-wk-old male MRL/*lpr* mouse stained for Thy-1.2. Original magnification,  $\times 64$ .

of necrotizing vasculitis. Kidneys from 7 MRL/*lpr* mice, 5 male and 2 female, 22–26 wk old (mean, 24 wk), were analyzed, and the results are summarized in Table I. Most of the cells in the vasculitic renal lesions stained for Thy-1.2 (77–89%; mean, 85%) and were identified as T cells (Fig. 3). As in the lacrimal gland lesion, the majority of the inflammatory mononuclear cells in the vasculitic

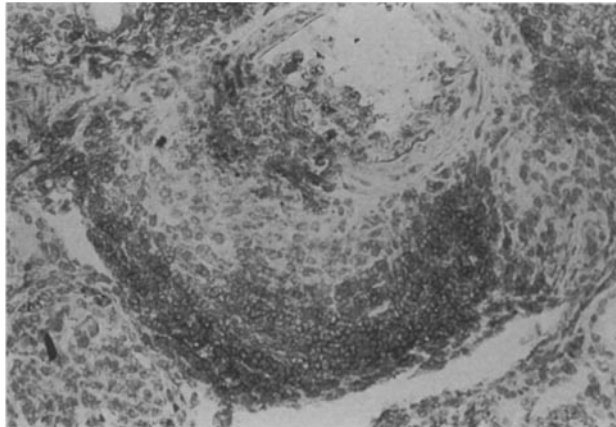


FIGURE 4. Renal vasculitic lesion of a 26-wk-old male MRL/*lpr* mouse stained for L3T4. Original magnification,  $\times 64$ .

lesions in the kidney stained for L3T4 (49–70%; mean, 58%) (Fig. 4), and lesser numbers of cells stained for Lyt-2, Mac-3, and sIg.

In the lymph nodes, >90% of the mononuclear cells stained positively for Thy-1.2, with only occasional cells staining for sIg or Mac-3. Furthermore, while definite staining of occasional lymph node lymphocytes with either L3T4 (10–15%) or Lyt-2 (<10%) could be seen, a large majority of lymphocytes in the lymph nodes were negative for both of these markers (data not shown).

### Discussion

In addition to accelerating the autoimmune disease present in MRL/Mp mice, the *lpr* gene induces massive lymphoproliferation. Previously, others demonstrated (1–5) that the lymphocytes present in these lymph nodes are primarily T cells. However, these cells are only weakly positive for Lyt-1, suggesting a low density of this surface marker (3), and the lack of both L3T4 and Lyt-2 (4) makes them an unusual double-negative T cell. Wofsy et al. (4) have found that this double-negative T cell is also the predominant lymphocyte phenotype in the peripheral blood of adult MRL/*lpr* mice. Immunohistologic analysis of the lacrimal gland lesions was performed to determine the phenotype of the mononuclear cells present. The great majority of mononuclear inflammatory cells present were positive for Thy-1.2 and therefore considered T cells. The numbers of B cells and macrophages were small. While only a small number of cells expressed Lyt-2, the surprising finding was that the majority of lymphocytes in the lacrimal gland lesions expressed L3T4.

As a control on our technique, we simultaneously stained sections of MRL/*lpr* lymph nodes, and our results paralleled those of Wofsy et al. (4): while >90% of lymph node lymphocytes stained positively for Thy-1.2, only a small minority stained for either L3T4 or Lyt-2. Because of the difference between the lacrimal gland inflammatory cell population and the lymph node, we analyzed the vasculitic renal lesions to determine if this difference was characteristic of the lacrimal gland or of the autoimmune target organs in general. Our results in the kidneys are similar to those in the lacrimal gland. Thus, the lymphocyte phenotypes in the lacrimal gland lesions and renal vasculitic lesions are clearly dissimilar from

those in the lymph node. Since L3T4 is thought to participate in the T cell response to class II antigen on APCs (6, 7), these results suggest that the immunopathologic events in target organ lesions (lacrimal gland and renal vasculature) are different from those in the lymph nodes.

The presence of mononuclear cell inflammatory lesions in the lacrimal glands of MRL/*lpr* mice has suggested that the MRL/*lpr* mouse may be a model for the human disorder Sjögren's syndrome (8, 9). This syndrome is characterized by dry eyes and xerostomia caused by a lymphocytic infiltrate into the lacrimal and salivary glands. While biopsy tissue of human lacrimal glands is generally not available for analysis, immunohistologic analysis of minor salivary gland biopsies from patients with Sjögren's syndrome has demonstrated that the majority of cells involved are T cells of the Th phenotype, with 50–75% of the lymphocytes in minor salivary gland lesions staining for Leu-3a and <25% of lymphocytes staining for Leu-2a (15). The similarity of these results in humans to our findings in MRL/*lpr* mice suggests that the MRL/*lpr* mouse may be an appropriate animal model for Sjögren's syndrome.

### Summary

The lacrimal gland inflammatory lesions and renal vasculitic lesions of autoimmune MRL/*lpr* mice were analyzed for the lymphocyte subsets present. The majority of cells were Thy-1.2<sup>+</sup> T cells (mean, 85%) of the L3T4<sup>+</sup> helper T phenotype (mean, 64 and 58%, respectively). Lesser numbers of Lyt-2<sup>+</sup> suppressor/cytotoxic T cells, B cells, and macrophages were present. The finding that the majority of lymphocytes in both the lacrimal gland inflammatory lesions and renal vasculitis of MRL/*lpr* mice expressed L3T4 suggests that these cells may be capable of responding to antigen presentation and that an active immunologic response occurs at these sites.

The authors wish to thank Bella Lee for technical assistance and Deni Starr for preparation of the manuscript.

*Received for publication 3 March 1987 and in revised form 10 July 1987.*

### References

1. Theofilopoulos, A. N., and F. J. Dixon. 1985. Murine models of systemic lupus erythematosus. *Adv. Immunol.* 37:269.
2. Theofilopoulos, A. N., R. A. Eisenberg, M. Bourdon, J. S. Crowel, Jr., and F. J. Dixon. 1979. Distribution of lymphocytes identified by surface markers in murine strains with systemic lupus erythematosus-like syndromes. *J. Exp. Med.* 149:516.
3. Lewis, D. E., J. V. Giorgi, and N. L. Warner. 1981. Flow cytometry analysis of T cells and continuous T-cell lines from autoimmune MRL/1 mice. *Nature (Lond.)* 289:298.
4. Wofsy, D., R. R. Hardy, and W. E. Seaman. 1984. The proliferating cells in autoimmune MRL/*lpr* mice lack L3T4, an antigen on "helper" T cells that is involved in the response to class II major histocompatibility antigens. *J. Immunol.* 132:2686.
5. Prud'homme, G. J., C. L. Park, T. M. Feiser, R. Kofler, F. J. Dixon, and A. N. Theofilopoulos. 1983. Identification of a B cell differentiation factor(s) spontaneously

- produced by proliferating T cells in murine lupus of the *lpr/lpr* genotype. *J. Exp. Med.* 157:730.
6. Dialynas, D. P., Z. S. Quan, K. A. Wall, J. Quintans, M. R. Loken, M. Pierres, and F. W. Fitch. 1983. Characterization of murine T cell surface molecule, designated L3T4, identified by monoclonal antibody GK-1.5: similarity of L3T4 to the human Leu-3/T4 molecule. *J. Immunol.* 131:2445.
  7. Dialynas, D. P., D. B. Wilde, P. Marrack, A. Pierres, K. A. Wall, W. Havran, G. O. Hen, M. R. Loken, M. Pierres, J. Kappler, and F. W. Fitch. 1983. Characterization of the murine antigenic determinant, designated L3T4 A, recognized by monoclonal antibody GK-1.5: expression of L3T4 A by functional T cell clones appears to correlate primarily with class II MHC antigen reactivity. *Immunol. Rev.* 74:29.
  8. Hoffman, R. W., M. A. Alspaugh, K. S. Waggie, J. B. Durham, and S. E. Walker. 1984. Sjögren's syndrome in MRL/1 and MRL/n mice. *Arthritis Rheum.* 27:157.
  9. Jabs, D. A., E. L. Alexander, and W. R. Green. 1985. Ocular inflammation in autoimmune MRL/Mp mice. *Invest. Ophthalmol. & Visual Sci.* 26:1223.
  10. Berden, J. H. M., L. Hang, P. J. McConahey, and F. J. Dixon. 1983. Analysis of vascular lesions in murine SLE. I. Association with serologic abnormalities. *J. Immunol.* 130:1699.
  11. Alexander, E. L., C. Moyer, G. S. Travlos, J. B. Roths, and E. D. Murphy. 1985. Two histopathologic types of inflammatory vascular disease in MRL/Mp autoimmune mice. Model for human vasculitis in connective tissue disease. *Arthritis Rheum.* 28:1146.
  12. Hsu, S., L. Raine, and H. Fanger. 1981. Use of avidin-biotin-peroxidase complex (ABC) techniques: a comparison between ABC and unlabeled antibody (PAP) procedures. *J. Histochem. Cytochem.* 29:577.
  13. Ledbetter, J. A., R. V. Rouse, H. S. Micklem, and L. A. Herzenberg. 1980. T cell subsets defined by expression of Lyt-1,2,3 and Thy-1 antigens. *J. Exp. Med.* 152:280.
  14. Springer, T. A. 1981. Monoclonal antibody analysis of complex biological systems. *J. Biol. Chem.* 256:3833.
  15. Adamson, T. C., III, R. I. Fox, D. M. Frisman, and F. V. Howell. 1983. Immunohistologic analysis of lymphoid infiltrates in primary Sjögren's syndrome using monoclonal antibodies. *J. Immunol.* 130:203.