

THE SUSCEPTIBILITY OF THE GOLDEN HAMSTER
(*CRICETUS AURATUS*) TO BOVINE, HUMAN AND
AVIAN TUBERCLE BACILLI AND TO THE VOLE
STRAIN OF ACID-FAST BACILLUS (WELLS)

BY A. STANLEY GRIFFITH, C.B.E., M.D., PH.D.
Member of the Scientific Staff, Medical Research Council

From the Field Laboratories, University of Cambridge

HISTOLOGICAL OBSERVATIONS BY W. PAGEL, M.D.

*From the Sims Woodhead Memorial Laboratory, Papworth
Village Settlement, Cambridge*

(With Plate I, containing Figs. 1-9)

IN his paper on the experimental transmission of rat leprosy to the golden hamster Balfour-Jones (1937) stated that he had confirmed the findings of the late Capt. S. R. Douglas (1935, personal communication) that this hamster is susceptible to infection with both human and bovine types of tubercle bacilli. "A dose of 5 mg. of an active culture of either type, injected by the intraperitoneal route, killed two out of three hamsters in 5 weeks in each of two groups, the organism being recovered from the liver and spleen in each case. The third hamster in each group showed marked evidence of infection when killed 8 weeks after inoculation." Balfour-Jones (1937) also tested the susceptibility of the hamster to a strain of the avian tubercle bacillus. Four hamsters were inoculated (method not stated) each with 50 mg. and killed at intervals ranging from 2 to 6 months after inoculation; they showed no signs of infection either macroscopically or microscopically and all cultures proved sterile.

The experiments on the golden hamster were made (by A. S. G.) for the purpose of comparing the effects produced in this species by each of the three types of tubercle bacilli with those of the vole strain of acid-fast bacilli. Six hamsters from the stock bred at the Farm Laboratories of the National Institute for Medical Research were used in the experiments and were injected subcutaneously in the abdominal wall with cultures of the different organisms.

The details and the results of the experiments are summarized in the following table:

No. of hamster	Strain of bacilli	Dose of culture mg.	Duration of life days	Results
3)	Bovine 34	1.0	D. 78	General tuberculosis. Caseation of some lesions. Tubercle bacilli extremely abundant
4)		1.0	D. 99	
5		1-2	D. 101	
	Human C.S. 404 (sputum)			
6	Avian	5.0*	D. 145	No macroscopic tuberculous lesions. Tubercle bacilli abundant in liver, spleen and marrow
1)	L.V. 286† (Vole)	1.0	K. 152	Generalized lesions in which bacilli extremely abundant. No caseation
2)		1.0	D. 188	

* The dose of avian bacilli was larger than those of the other types because the results of Balfour-Jones suggested that this type was not pathogenic for the hamster.

† This strain was obtained from a dorsal subcutaneous lesion in a naturally infected vole received from Dr A. Q. Wells.

DISTRIBUTION AND CHARACTERS OF THE LESIONS

Hamster 3, inoculated with bovine bacilli, died 78 days.

Autopsy. Skin of abdomen showed a tuberculous ulcer, 2 × 1.5 cm. Inguinal gland on each side enlarged, 12 × 8 mm., left completely, right about three-quarters caseous, just beginning to soften. Both axillary glands enlarged, same size as inguinals but only diffusely caseated. Both iliac glands enlarged—one 10 × 5 mm., the other smaller—showed diffuse caseation. Within pelvis, and practically filling it, there was a large gland which showed an irregular yellow caseous patch and more recent caseation elsewhere. A renal, left lumbar, a colic and the mesenteric glands were enlarged and showed early caseous foci. Right lumbar, left ventral mediastinal, a prescapular and the submaxillary glands were slightly enlarged and not caseous. The tissue of the glands, where not caseous, was very soft and appeared to have little supporting structure. Spleen, 3.5 cm. in length, contained numerous grey translucent millet-seed-sized bodies which crushed like glandular tissue; there was one caseous tubercle projecting from the hilum. Liver, lobules pale, showed not numerous, rather irregularly distributed, translucent grey tubercles. Kidneys normal. The mucous membrane of the colon showed a fine grey mottling. Lungs, pink and crepitant, showed distributed throughout a moderate number of tubercles, ranging from a mere point up to a millet seed, all grey and translucent, except one which was opaque; there was also a disk-shaped congested caseous nodule, 4 mm. in diameter, which projected from the ventral surface of a lobe.

Smear preparations of lymphatic glands (inguinal, iliac, colic and submaxillary), spleen and lungs showed tubercle bacilli in great abundance; they were moderately numerous in the marrow and in the faeces of the small and large intestines.

Histological. Liver contains, in the periphery of the liver lobules, epithelioid cell nodules, with abundant intracellular acid-fast rods. The nodules have developed in the sheath of the portal veins and are often intravascular; there is no caseation or necrosis. Spleen shows a diffuse proliferation of reticulum cells and sinus endothelia so that the original structure of the organ is abolished. Although the cells contain many acid-fast rods, there is no necrosis or caseation. In a lymphatic gland numerous epithelioid cell nodules with enormous numbers of intracellular acid-fast rods are seen. There are also small necrotic areas containing numerous bacilli. In the lungs subpleural foci are seen consisting of alveoli filled with large foamy cells with many intracellular tubercle bacilli. No caseation or necrosis was observed here. No lesions were observed in the kidney.

Hamster 4, inoculated with bovine bacilli, died 99 days.

Autopsy. Local tumour in subcutaneous tissues, 1.5 cm. in diameter, caseous centrally and translucent-fibroid peripherally. Both inguinal, axillary, iliac and ileo-sacral, lumbar (chain of four), portal, renal and left ventral mediastinal glands all much enlarged and caseous throughout; the pelvis was nearly filled with the enlarged iliac and ileo-sacral glands. One submaxillary gland on right side contained a pin-head caseous tubercle; the mesenteric glands contained a few caseous tubercles. Spleen pale, 4 cm. in length, filled with caseous tubercles up to 2.5 mm. Liver, lobules pale and interlobular tissue congested, closely beset with greyish-yellow tubercles, not very uniformly distributed and ranging from a mere point up to about 2 mm. in diameter. Kidneys, no lesions seen. Lungs: left anterior lobe a mass of caseating substance; in right caudal lobe a mass 1 cm. in diameter and somewhat flattened; elsewhere smaller caseating nodules and numerous miliary and submiliary translucent tubercles.

Smear preparations of liver and lung showed extremely numerous tubercle bacilli, lung lesion being mainly composed of bacilli. The faeces showed numerous bacilli and a few were seen in the blood.

Histological. In the liver small and large necrotic nodules are found chiefly in the periphery of the liver lobules. The nodules are filled with innumerable acid-fast rods; in some of them large mononuclear cells engorged with acid-fast rods are visible in the periphery. The spleen contains large necrotic foci of the same type as those seen in the liver. The structure of the organ is abolished, the remaining walls of the pulp sinuses showing hyaline thickening. In the lungs large necrotic foci, containing nuclear debris; enormous numbers of tubercle bacilli and remnants of large mononuclear cells are visible. In the kidneys hyaline (amyloid) degeneration of glomeruli and occasionally a bacillary embolus are observed. The tubules show hyaline casts. Lymph gland: diffuse necrosis with liquefaction and partial calcification. Innumerable acid-fast rods.

The chief histological feature of the bovine infection is the massive necrosis and the large size of the foci. *Hamster 3* offers apparently the changes at an early stage with commencing necrosis in the lymphatic gland. This allows a reconstruction of the necrotic lesions observed in *hamster 4*. The infection was apparently very virulent.

Hamster 5, inoculated with human bacilli, died 101 days.

Autopsy. Tuberculous ulcer in centre of abdomen, 2.5 cm. in diameter. Inguinal, axillary, iliac, ventral mediastinal and portal glands were enlarged (up to 1 cm. in diameter) and caseous throughout. Several other lymphatic glands were enlarged and diffusely caseated. Spleen, 3 cm. in length, filled with grey translucent tubercles up to 2 mm. Liver enlarged and pale, showed moderate number grey miliary tubercles, some with opaque centre. Kidneys, no macroscopic tubercles. Lungs enlarged, congested, parenchyma extensively replaced by tuberculous foci which varied much in size; majority were about 1 mm. and were translucent; others were larger, up to 4 mm., of irregular outline, and contained caseous foci irregularly distributed; in addition there were many minute translucent foci visible only with a lens. The bronchial glands were slightly enlarged and not caseous. Microscopically tubercle bacilli were extremely numerous in pus from local ulcer, axillary gland, lung, spleen and liver and were found in moderate numbers in the faeces. Cultures were made but became contaminated. A guinea-pig injected with a tenth of the dose given to *hamster 5* was killed, on account of paralysis, 112 days after inoculation. The autopsy showed general tuberculosis of human type (hyperplasia of glands; lesions in organs grey and free from caseation).

Histological. The liver contains large epithelioid cell nodules with large number of intracellular acid-fast rods, and small areas of necrosis and caseation. A similar picture is seen in the spleen, the number of bacilli exceeding that observed in the liver. In the lung intra-alveolar nodules consisting of large mononuclear cells with enormous numbers of bacilli are found; there are small, but definite areas of necrosis and caseation. The kidneys show

amyloidosis chiefly of the glomeruli. The submaxillary gland shows some large epithelioid cell nodules full of bacilli.

There is in the nodules definite necrosis and caseation although smaller in extent than in hamster 4.

Hamster 6, inoculated with avian bacilli, died 145 days.

Autopsy. No sign of local lesion but skin of abdomen readily parted when stretched along a line which may have been site of healed ulcer. Inguinal glands, ? a little enlarged, blackish in colour, substance diffuent. All other glands were coal-black and little if at all enlarged. Lungs congested and oedematous. Spleen enlarged and black, the pulp was blackish, rather granular, friable and bloodless, only slightly blood-stained fluid exuding on pressure. Liver slaty black; black points seen in substance with aid of lens. Kidneys; minute yellow points in cortices suggesting deposited salts. No tuberculous lesions were seen anywhere. The body showed no adipose tissue and was very anaemic.

Smear preparations of left inguinal gland and spleen resembled a pure culture, almost no blue-stained tissue elements being seen. Bacilli were very numerous also in liver and marrow and relatively scanty in lung, cervical glands, blood and faeces. Avian bacilli were recovered in culture from the spleen and liver.

Histological. The liver contains (a) small nodules in the peripheral parts of the liver lobules, and (b) small islets of proliferating Kupffer cells in the intermediate part of the liver lobules. The nodules (a) consist of large mononuclear and giant cells filled with acid-fast rods. Many of the giant cells contain crystals consisting of concentric rings of a substance which gives a positive iron reaction. The proliferating Kupffer cells (b) are engorged with acid-fast rods. In the spleen no organ structure is visible, the outlines of the elements of the red pulp showing as faint shadows without any nuclear staining (amyloid reaction: weakly positive). Agglomerations of mononuclear cells engorged with acid-fast rods seem to have taken the place of the follicles. The lungs show scanty acid-fast rods in alveolar cells, but no nodules. Kidneys: amyloid degeneration of glomeruli and the wall of some tubules. Some of the glomerular capillaries contain bacillary emboli. Inguinal lymph gland is a necrotic mass with an enormous number of acid-fast rods.

The avian infection shows histological characters slightly different from the other groups. In addition to the nodules there is also diffuse proliferation of endothelial cells, e.g. in the liver. Giant cells are very conspicuous in the liver nodules. They contain spheroid crystals which are a common finding in giant cells in human tubercles. There is no caseation or necrosis (apart from the inguinal gland). The whole picture corresponds to what is generally seen in avian tuberculosis in other animals.

Hamster 1, inoculated with the vole strain, killed 152 days.

Autopsy. In right groin oval ulcer, 2×1.5 cm. with everted edges, floor formed by abdominal muscles which showed purulent foci, yellow necrotic substance under margins of skin, most abundant near inguinal gland which was on point of being involved in ulcer. Right inguinal gland, 6 or 7 mm. in diameter; substance soft and mushy but not purulent. Left inguinal, smaller than right, showed a slightly opaque cortical area; its substance was soft and almost diffuent. Other lymphatic glands showed some degree of enlargement, in no instance very pronounced; on section they were soft, hyperplastic, without necrosis or caseation. Lungs pink and crepitant, showed on dorsal surface one subpleural grey translucent tubercle, 1.5 mm. in diameter, and sparsely scattered glassy tubercles barely visible to the naked eye. Spleen enlarged, 4 cm. in length, nodular in outline, pulp almost completely replaced by reddish grey nodules ranging from 2 or 3 up to 5 mm. in diameter, one blackish suggesting old haemorrhage. Liver enlarged, speckled with grey foci, not regularly distributed and in places forming a coarse network; some of the foci were about 1 mm. across but majority were microscopic or only just visible to naked eye. Kidneys, no macroscopic lesions. Marrow and brain normal.

Smear preparations showed extraordinarily numerous typical vole bacilli in the local pus, inguinal, axillary and bronchial glands, spleen and liver, occurring chiefly in irregular masses and balls. Acid-fast bacilli were only moderately numerous in the mesenteric glands and not numerous in the marrow; they were fairly numerous in the faeces of the large intestine, occurring chiefly in large clumps.

Histological. Liver contains nodules consisting of epithelioid cells filled with acid-fast rods. Most nodules are in the periphery of the liver lobules and attached to the small branches of the portal vein. Some of them are situated in the vascular wall including the intima. The nodules are devoid of necrosis and caseation. Spleen shows large nodules built up by large reticulum (epithelioid) cells filled with the typical acid-fast rods. There is neither necrosis nor caseation, but extensive amyloid degeneration of the red pulp (sinus walls). Extensive amyloidosis is also found in the kidneys (glomeruli) which do not, however, contain any nodules. An inguinal lymph gland shows nodules of the same type as those found in the spleen. In the lungs small and large foci are met with, consisting of large foamy mononuclear cells, full of acid-fast rods. No caseation, no necrosis.

Hamster 2, inoculated with the vole strain, died 188 days.

Autopsy. Skin of abdomen on right side showed irregular ulcer, 1.4 × 0.5 cm., with everted edges and dry reddish floor; under the edges of the skin there was scanty translucent substance resembling granulation tissue; some purulent substance could be scraped from it. Right inguinal gland much enlarged, 1.2 cm. in diameter, composed of thick purulent substance with a wall of soft gland-like tissue. Right axillary gland as large as right inguinal, composed of soft diffuent glandular tissue diffusely infiltrated with yellow purulent areas. The left inguinal gland was enlarged and composed of soft hyperplastic glandular tissue. Most other lymphatic glands were a little enlarged and hyperplastic only. Lungs crepitant, showed one translucent grey tubercle, 2 mm. in diameter, and half a dozen minute pellucid tubercles. Spleen enlarged, nodular in outline, filled with reddish grey nodules up to 5 mm. in diameter. Liver speckled with pale grey translucent foci from 0.5 mm. to microscopic. Kidneys, no definite foci. The body was fat.

Smear preparations of local pus, a lumbar gland, lung and spleen showed extremely abundant acid-fast bacilli; a bronchial, the inguinal and a cervical gland showed very numerous bacilli, though not so numerous as in lumbar gland; acid-fast bacilli were sparse in faeces and marrow. The vole organism was recovered in culture from the livers of hamsters 1 and 2.

Histological. In all organs (spleen, liver, lymphatic gland and lungs) epithelioid cell nodules without necrosis or caseation are found. The nodules have the same structure in all organs examined. The epithelioid cells are full of the typical acid-fast rods. No nodules were found in the kidneys.

In the organs of both hamsters infected with vole bacilli numerous epithelioid cell nodules are found. Abundance of the typical acid-fast rods in the cells of the nodules and absence of caseation and giant cells are the most marked histological features of the infection. The picture is that of a "large cell hyperplasia" which is not uncommon in human tuberculosis of the lymphatic glands, although in the latter tubercle bacilli are not, or only rarely, found in the cells.

HISTOLOGICAL SUMMARY

A comparison of the histological pictures suggests definite differences in virulence of the different types of bacilli used: the mildest infection was caused by the vole type of bacilli, the strongest by the bovine. In the former, no caseation or necrosis was produced at all, whereas such changes were

extensive in bovine infection. The human bacillus proved to be less virulent than the bovine, as judged by the amount of necrosis and caseation. The avian bacillus caused a picture comparable with avian tuberculosis in other animals. There was no caseation, and necrosis was confined to the lymph gland. Secondary degenerations of the organs, however, such as amyloid changes were very conspicuous.

In spite of the differences in virulence (as shown by the extent of caseation and necrosis) the fundamental histological changes following the invasion of the tissues of the hamster by tubercle bacilli of different types are identical. The first reaction consists of a proliferation of mononuclear (epithelioid) cells which form a nodule. This may or may not undergo caseation or necrosis. In all pictures the enormous number of acid-fast rods is impressive—a picture familiar in tuberculosis of rodents. Obviously the number of bacilli is not decisive for the development of caseation, since the number of rods seen in lesions—with no caseation—produced by the vole strain is as large as in infections with other types. It is noteworthy that the vole bacillus produces epithelioid cell tubercles indistinguishable from genuine tuberculous changes, e.g. in man (“large cell hyperplasia”). On the other hand, the absence of caseation is a feature differentiating infection by the vole strain from those by human and bovine bacilli. Giant cells were produced in the hamster only by the avian bacillus.

SUMMARY

All the four types of acid-fast bacilli used in this investigation have proved virulent for the golden hamster. Of the four types the bovine is the most virulent for the species and, after subcutaneous inoculation, gives rise to severe generalized progressive tuberculosis, the lesions containing enormous numbers of tubercle bacilli. The human type is also highly virulent for the hamster and produces general progressive tuberculosis closely resembling that set up by bovine bacilli. Caseation of the lesions in the organs was, however, less extensive in the human than in the bovine infections but there was little difference in this respect between the glandular lesions of the two infections, and multiplication of bacilli was as profuse in one as in the other. Avian bacilli can readily multiply in the tissues of the hamster and cause death, but appear unable to give rise to macroscopic tuberculous lesions. Only one hamster was injected with avian bacilli and the result of this experiment is not in accord with those of Balfour-Jones already quoted. The vole bacillus is less virulent for the hamster than either the bovine or the human type of bacillus. Of the two hamsters injected with this type of bacillus one was killed 152 days later, its general condition then being good and its body showing plenty of subcutaneous fat. Nevertheless the organs were found to contain tuberculosis-like lesions, numerous in the spleen and liver, and the lymphatic glands generally were enlarged. The remaining hamster died 188 days after inoculation and showed generalized disease very similar to that in the last hamster. The glandular and visceral lesions of both hamsters

contained very numerous acid-fast bacilli but, in striking contrast to those produced by bovine and human bacilli, showed no evidence of caseation.

Acid-fast bacilli were present in the faeces of all the hamsters; they were numerous in those of hamsters 3, 4, 5 and 2 and relatively sparse in those of hamsters 1 and 6.

CONCLUSIONS

The golden hamster is highly susceptible to infection with both bovine and human types of tubercle bacilli, rather less so to the latter than to the former.

The hamster is susceptible also to infection with avian bacilli but—like all mammals—reacts to this type in a manner different from its reactions to bovine and human bacilli. The avian bacilli readily multiply in the tissues but do not give rise to macroscopic tuberculous lesions.

The hamster is susceptible to the vole strain of acid-fast bacillus but much less so than to bovine or to human tubercle bacilli. Though anatomically resembling tuberculosis, the disease produced by the vole organism differs from that set up by mammalian tubercle bacilli in not proceeding to caseation.

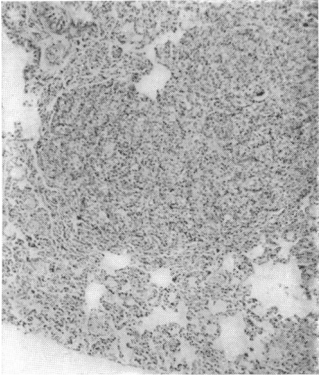
REFERENCE

BALFOUR-JONES, S. E. B. (1937). *J. Pathol. and Bacteriol.* **45**, 739.

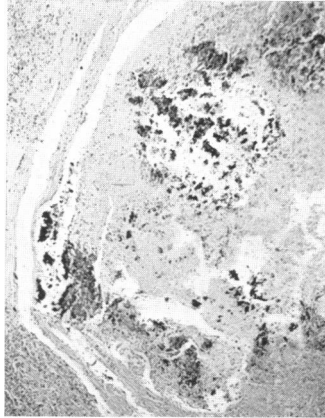
EXPLANATION OF PLATE I

- Fig. 1. Hamster 2. Infected with the vole strain. Liver (low power). Group of epithelioid cell nodules. No caseation.
- Fig. 2. Hamster 2. Infected with the vole strain. Spleen. Epithelioid cell nodules. Numerous acid-fast bacilli intracellular.
- Fig. 3. Hamster 3. Bovine infection. Epithelioid cell nodules in the lung (low power).
- Fig. 4. Hamster 3. Bovine infection. Lung. Foam cells in the alveoli.
- Fig. 5. Hamster 4. Bovine infection. Liver. Focus with massive caseation.
- Fig. 6. Hamster 4. Bovine infection. Lymphatic gland. Extensive caseation and deposition of lime salts.
- Fig. 7. Hamster 5. Human infection. Liver. Small "tubercle", consisting of proliferating Kupffer cells and hyalin degenerating liver tissue.
- Fig. 8. Hamster 5. Human infection. Lung. Alveolitis with numerous intracellular acid-fast rods.
- Fig. 9. Hamster 6. Avian infection. Liver. Tubercle in the sheath of a portal vein. Epithelioid and giant cells engorged with acid-fast rods. In some of the giant cells crystals with concentric rings.

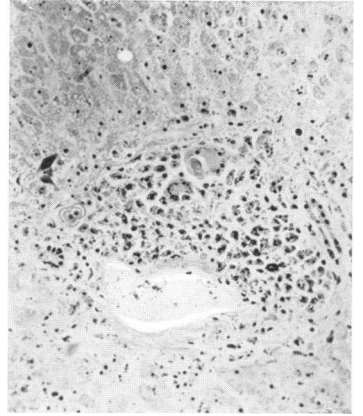
(*MS. received for publication 7. XII. 38.—Ed.*)



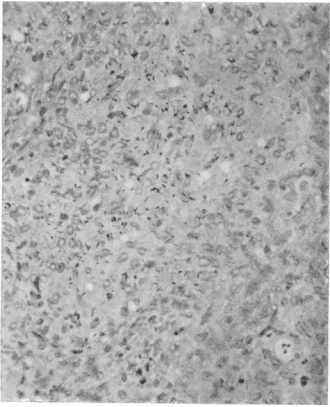
3



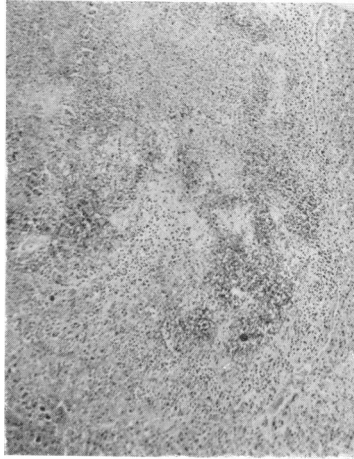6



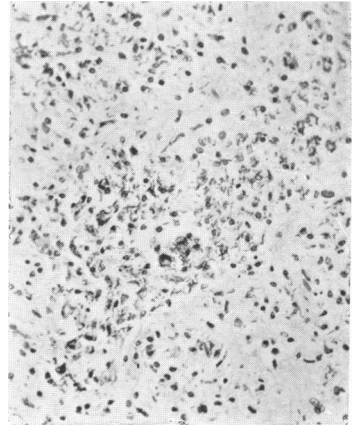
9



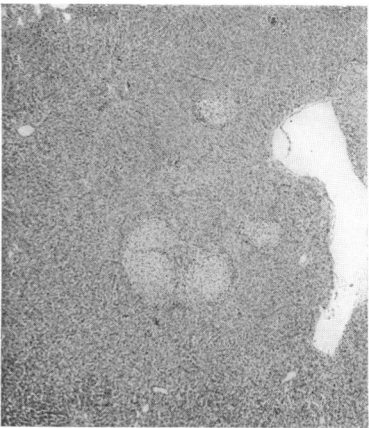
2



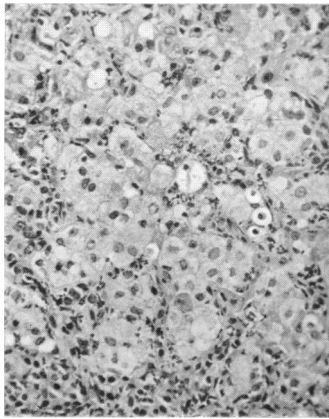
5



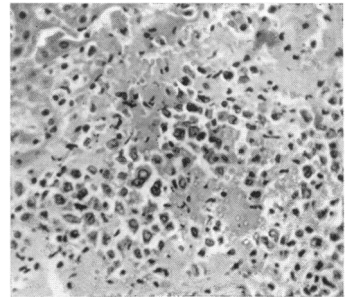
8



1



4



7