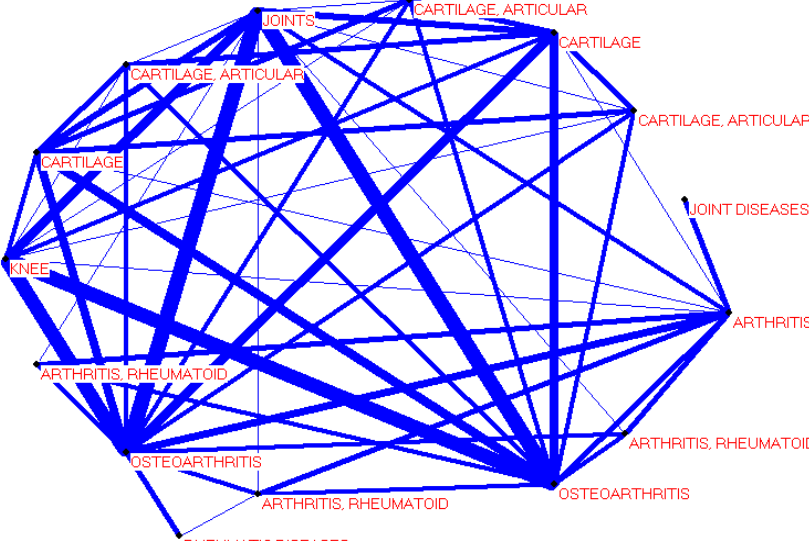


Document Clustering Performance Decrease as Summary Compression Ratio Increase for Each Summarization Method

<p><i>Alzheimer Disease</i></p>	<p>Document Cluster Model</p>	
	<p>Top 7 Sentences as Summary</p>	<ul style="list-style-type: none"> • Tau protein extracted from filaments of familial multiple system tauopathy with presenile dementia shows a minor 72-kDa band and two major bands of 64 and 68 kDa that contain mainly hyperphosphorylated four-repeat tau isoforms of 383 and 412 amino acids. • The central pathological cause of Alzheimer disease (AD) is hypothesized to be an excess of beta-amyloid (Abeta) which accumulates into toxic fibrillar deposits within extracellular areas of the brain. These deposits disrupt neural and synaptic function and ultimately lead to neuronal degeneration and dementia • In dementia of Alzheimer type (DAT), cerebral glucose metabolism is reduced in vivo, and enzymes involved in glucose breakdown are impaired in post-mortem brain tissue • Alzheimer's disease (AD), a progressive, degenerative disorder of the brain, is believed to be the most common cause of dementia amongst the elderly • The fundamental cause of Alzheimer dementia is proposed to be Alzheimer disease, i.e. the neurobiological abnormalities in Alzheimer brain • Alzheimer's disease (AD) is a degenerative disease of the brain, and the most common form of dementia • Regional quantitative analysis of NFT in brains of non-demented elderly persons: comparisons with findings in brains of late-onset Alzheimer's disease and limbic NFT dementia.

	<p>Document Cluster Model</p>	
<p><i>Osteoarthritis</i></p>	<p>Top 7 Sentences as Summary</p>	<ul style="list-style-type: none"> • Pathological joint events in both inflammatory arthritis and degenerative arthritis are perpetuated by complex cytokine interactions • In 8, who had severe osteoarthritis, a bicompartamental ICLH (Imperial College-London Hospital) prosthesis was used; in 12, with moderate arthritis, the medial side of the joint was replaced by a unicompartmental Brigham prosthesis • In old scaphoid fractures, the degenerative arthritis begins with an impingement between radial styloid process and proximal pole of the scaphoid, and then reaches the lunocapitate joint. A dorsi flexion by instability is then constant • These patients suffered from painful posttraumatic degenerative arthritis after tarsometatarsal joint fracture-dislocation • More than 85% of all adult cadavers demonstrate degenerative arthritis of the radial subsesamoid joint • OBJECTIVE: Osteoarthritis (OA) is the most common type of arthritis; involvement of joints in the hand is highly prevalent, especially in the elderly • Dysfunction of the pisotriquetral joint: degenerative arthritis treated by excision of the pisiform