

THE LOCALIZATION OF ENZYME ACTIVITIES IN THE RAT BRAIN

NORWIN H. BECKER, M.D., SIDNEY GOLDFISCHER,
WOO-YUNG SHIN, and ALEX B. NOVIKOFF, Ph.D.

From the Department of Pathology, Albert Einstein College of Medicine, Yeshiva University, New York. Dr. Becker's present address is Laboratory Division, Montefiore Hospital, New York. Mr. Goldfischer's present address is New York University College of Medicine, New York

ABSTRACT

Studies with rat brain illustrate the usefulness of formol-calcium-fixed tissue for studying both enzymatic "chemoarchitectonics" and intracellular organelles. Unembedded frozen sections and polyvinyl alcohol-embedded sections may be used to demonstrate the activities of DPNH-tetrazolium reductase localized in mitochondria and ergastoplasm, TPNH-tetrazolium reductase localized in mitochondria, ATPase (and/or apyrase or ADPase) in cell membranes, and acid phosphatase in lysosomes.¹ Among the observations recorded are: (1) the presence of lysosomes in all cells of the brain; (2) the presence of numerous large lysosomes near the nuclei of capillary endothelial cells; (3) a polarized arrangement of large lysosomes in epithelial cells of the ependyma and choroid plexus; (4) the presence of ATPase activity in the cell membranes of some neurons; (5) the presence of either an apyrase or combination of ATPase and ADPase in the cell membranes of neuroglia and capillaries; (6) the presence of both DPNH- and TPNH-tetrazolium reductase activities in neuroglia; (7) the presence of DPNH- and TPNH-tetrazolium reductase activities in mitochondria and of DPNH-tetrazolium reductase activity in Nissl substance. The possible functional significance of these localizations is briefly discussed, as is their relation to "quantitative histochemistry" data available in the literature.

INTRODUCTION

Reports in the literature deal with localization of enzymatic activities in the brain on a histological level but relatively few describe intracellular localizations. Initially limited to the study of phos-

¹ *Abbreviations:* ADP, adenosinediphosphate; ADPase, adenosine diphosphatase; ATP, adenosine-triphosphate; ATPase, adenosine triphosphatase; A5'P, 5'-adenylic acid or adenosine-5'-monophosphate; DPNH, reduced diphosphopyridine nucleotide; TPNH, reduced triphosphopyridine nucleotide.

phatases and other esterases, the studies have recently been extended to oxidative enzymes. In most instances morphological preservation has been inadequate and the results obtained by staining reactions have been difficult to translate into enzyme localizations due to the prevalence of adsorption artifacts (*cf.* 12).

The distribution of *acid phosphatase* in the central nervous system of the rat was studied by Wolf *et al.* (33) using the Gomori method on *acetone-fixed*,

This work was supported by research grants from the National Science Foundation (G-2310) United States Public Health Service (C-3153), and American Cancer Society, Inc. (E-60).

Received for publication, April 14, 1960.

paraffin-embedded tissue. Neural tissue was moderately and diffusely stained. The neurons of the midbrain, pons, and medulla stained more frequently than in other parts of the central nervous system, with the larger neurons staining more frequently and more intensely. The most prominently stained neurons were those of the pyramidal layer of the cerebral cortex, the corpus striatum, the Purkinje layer, and the cerebellar and cranial nerve nuclei. Within the neurons, both the nuclei and cytoplasm stained, including dendrites and axons. Staining of the neuroglia was limited to the cell nuclei. Both the cytoplasm and nuclei of the choroidal epithelium cells stained. In the ependymal epithelium cells, as in the blood vessels, only the nuclei stained.

Naidoo and Pratt (11) applied the Gomori method for acid phosphatase on *freeze-dried, paraffin-embedded tissue*. The cytoarchitecture of the cerebral cortex was well displayed as a consequence of neuronal staining. The pyriform lobe, thalamus, hypothalamus, the Purkinje and basket cells of the cerebellum, and the cranial nerve nuclei stained relatively deeply; the glial cells stained moderately. With long incubation times, blood vessels and nerve fibers stained. In the cerebral cortical neurons the nuclei were unstained except for the nucleoli. The cytoplasm, including that of the dendritic processes, stained

darkly. In the Purkinje cells, the nucleoli stained most deeply, followed in intensity by the nuclei and cytoplasm. Both vasculature and epithelium of the choroid plexus stained deeply. Nuclear staining of the ependymal cells was more prominent than that of the cytoplasm. In the blood vessels staining was limited to the nuclei.

The distribution of *alkaline phosphatase* in mouse, cat, chicken, and human brain was studied by Landow *et al.* (9) using *ethanol-fixed, paraffin-embedded tissue* and the Gomori procedure. The endothelial cells of the cerebral blood vessels displayed marked staining. In the chicken brain both focal and diffuse staining was noted in the parenchyma but the neurons were inactive.

Bourne (2) performed similar studies on *acetone-fixed paraffin-embedded rat brain*. The blood vessels were first to react. With longer incubation times selective portions of the stroma, as well as neuronal and glial nuclei and nucleoli, gave positive reactions.

Naidoo and Pratt (11) studied the localization of *adenosinetriphosphatase* activity in the rat brain with *freeze-dried paraffin-embedded tissue*. Cytoarchitectonic staining was not impressive, except for the molecular layer of the cerebellum which showed intense staining of the glial elements. Staining of cranial nerve neurons was more prominent than in neurons of cortex and di-

FIGURE 1

Cerebral cortex: acid phosphatase activity; incubation time: 35 minutes. $\times 110$.

The most deeply stained neurons are the large pyramidal cells of the ganglionic layer (5). Capillaries are indicated at *v*.

FIGURE 2

Cerebrum: ATPase activity; incubation time: 20 minutes. $\times 30$.

Capillaries (*v*) are intensely stained, as is the neuropil of the cortex (*C*), hippocampus (*H*), pyramidal band of hippocampus (*P*), and fascia dentata (*F*).

FIGURE 3

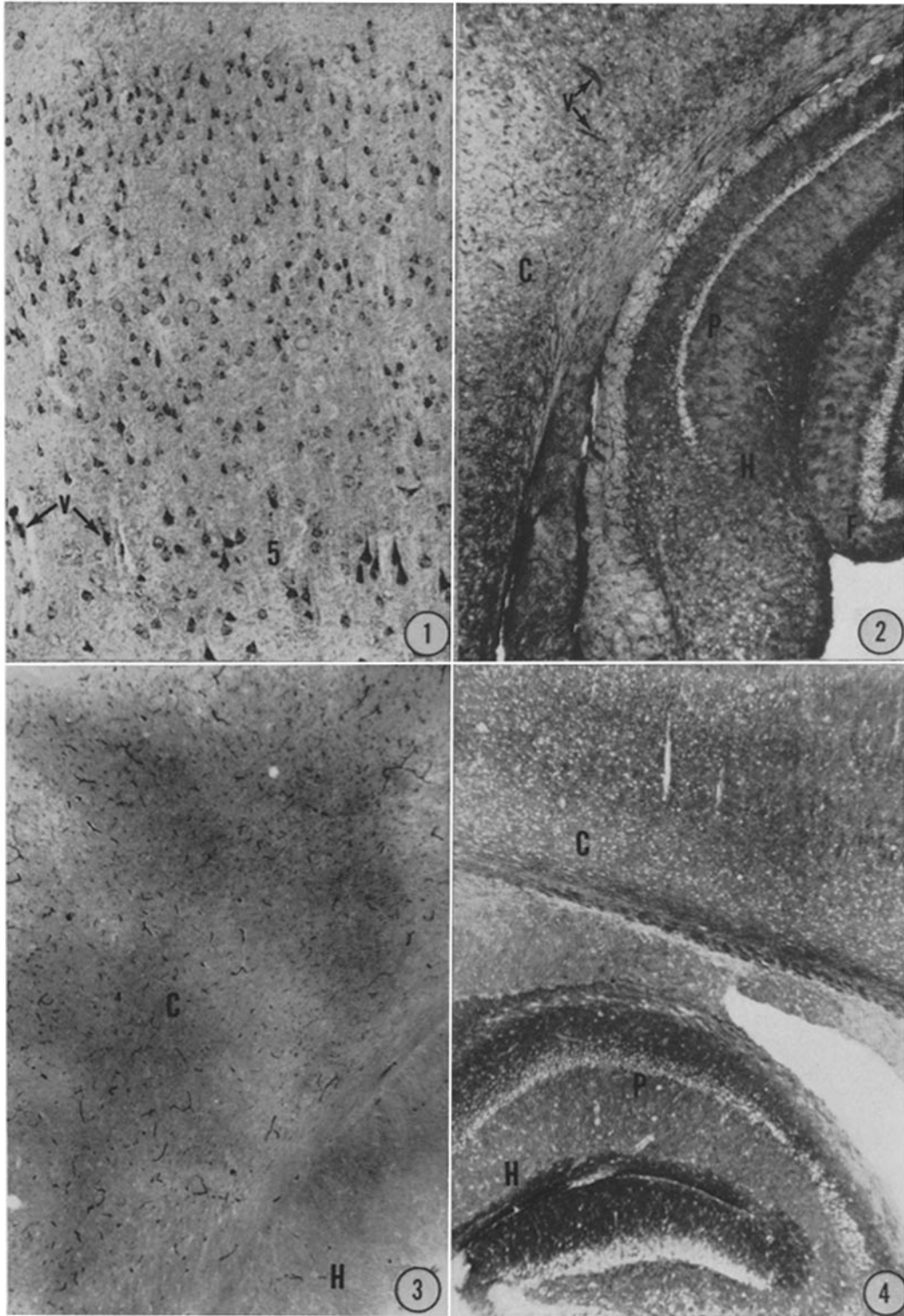
Cerebrum: alkaline phosphatase activity; incubation time: 45 minutes. $\times 35$.

Staining is limited to the capillaries in both cortex (*C*) and hippocampus (*H*). Compare with Fig. 2 in which the neuropil and capillaries are both deeply stained.

FIGURE 4

Cerebrum: DPNH-tetrazolium reductase activity; incubation time: 45 minutes. $\times 30$.

Note that in all areas the nuclei are unstained while the cytoplasm is stained. The labeled regions are cerebral cortex (*C*), hippocampus (*H*), and pyramidal band of hippocampus (*P*).



encephalon. In the choroid plexus both blood vessels and epithelium stained. Cytologically, nuclei of all elements stained to some degree. Neuronal cytoplasm gave a light diffuse staining with occasional deeply staining particles. The ependymal cells and the blood vessels showed only nuclear staining.

The localization of *succinic dehydrogenase activity* has been studied with *unfixed frozen sections*, as in the studies of Shimizu and Morikawa (30) and Friede (7). Different architectonic zones and nuclei showed variations in activity. Observations on a cytological level were not possible because of the thickness of the frozen sections.

Wolfgram and Rose (34) studied *several dehydrogenases* using *unfixed frozen sections* of rat and cat brain *dried in vacuo* at room temperature. Their attention was focused on the neuroglia, where staining was demonstrated in the perinuclear cytoplasm at sites considered to be mitochondria.

Potanos *et al.* (27) studied succinic dehydrogenase in human neural biopsies by incubating *fresh blocks of tissue* and following this by paraffin embedding and sectioning. Cytoplasmic staining was seen in neurons (including dendritic processes), astrocytes, oligodendroglia, and to some extent in the endothelial cells of blood vessels.

The present study describes the localization,

both cytological and histological, of several enzyme activities that survive cold formol-calcium fixation. The advantage of this fixative is that it preserves morphological detail while permitting visualization of a variety of enzyme activities in mitochondria and basophilic substance, lysosomes, and plasma membranes (13-23). DPNH- and TPNH-tetrazolium reductase activities are localized in mitochondria and basophilic substance, acid phosphatase activity in lysosomes, and adenosinetriphosphatase or related enzymes in some plasma membranes.

MATERIALS AND METHODS

Twenty-four male or female Sprague-Dawley rats, weighing 250 to 350 grams, were killed by decapitation, the cranial vaults were reflected and the brains removed. The brains were cut into coronal or transverse blocks 3 to 4 mm. in thickness and fixed in cold formol-calcium (1). After fixation at 2-4°C. for 18 to 24 hours, frozen sections (10 to 20 μ) were cut on a Bausch and Lomb freezing microtome or the tissue was rinsed in water and embedded in the water-soluble plastic, polyvinyl alcohol, according to Feder (6). After some 10 days or more in a desiccator at 2-4°C., the plastic hardened sufficiently for sectioning. Sections, 5 to 10 μ in thickness, were cut with a Spencer rotary microtome at room temperature.

FIGURE 5

Cerebellum: acid phosphatase activity; incubation time: 30 minutes. $\times 35$.

Highest staining is present in the Purkinje cells (*P*). The fiber tracts (*F*) stain a light brown in contrast to the black color in the neuron cell bodies. At this low magnification the molecular layer (*M*) and granular layer (*G*) appear unstained.

FIGURE 6

Cerebellum: activity with ATP as substrate; incubation time: 20 minutes. $\times 35$.

Staining is most prominent in the molecular layer (*M*). Capillaries (*v*) and fiber tracts (*F*) are stained. At this magnification, the Purkinje cells (*P*) are barely visible.

FIGURE 7

Cerebellum: activity with ADP as substrate; incubation time: 30 minutes. $\times 115$.

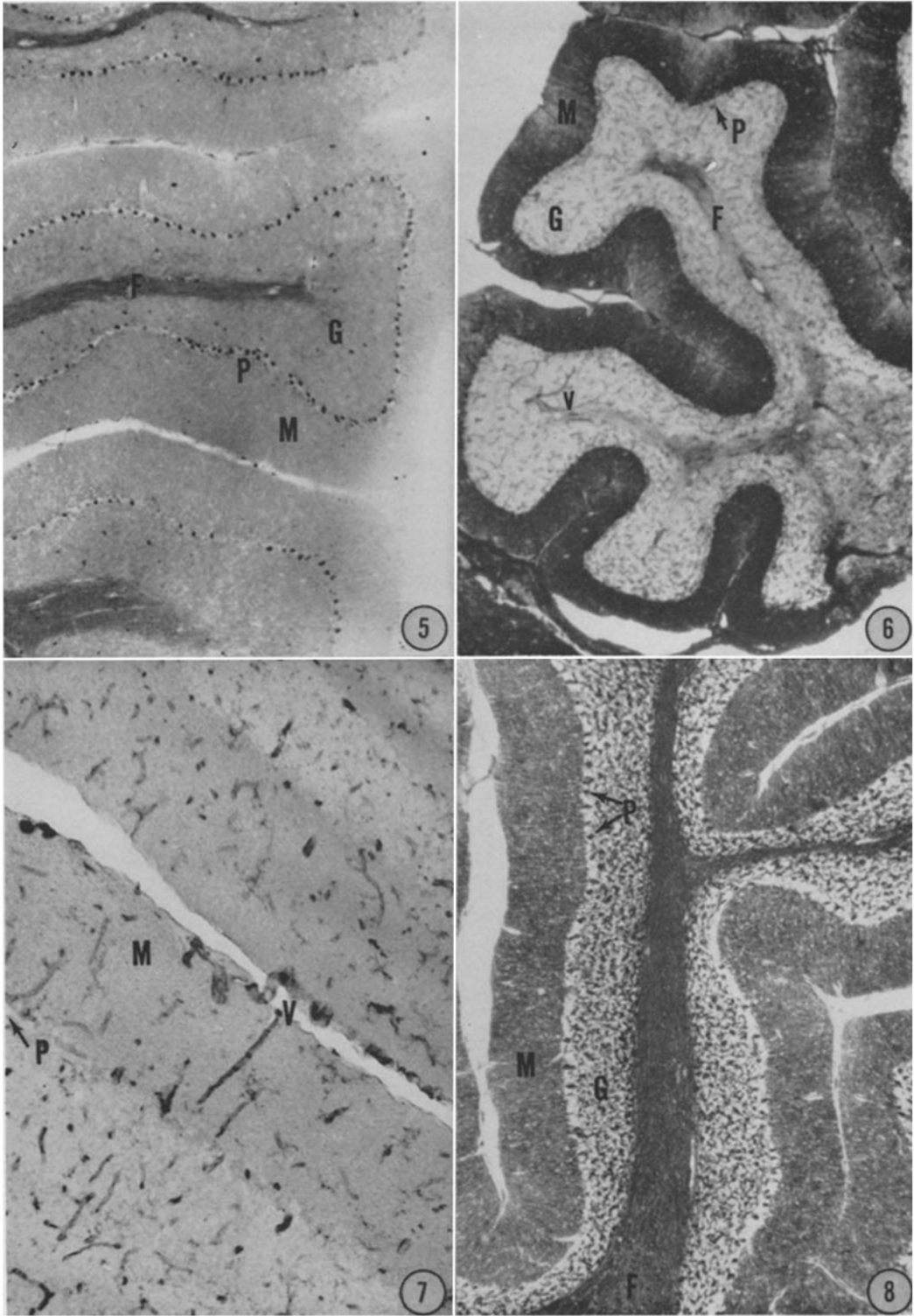
Since staining is limited to the blood vessels (*V*) and neuroglia (not seen at this magnification), Purkinje cells (*P*) and molecular layer (*M*) are hardly evident.

This is a polyvinyl alcohol section.

FIGURE 8

Cerebellum: DPNH-tetrazolium reductase activity; incubation time: 45 minutes. $\times 45$.

Staining is particularly prominent in the Purkinje cells (*P*), granular layer (*G*), and fiber tracts (*F*). The staining of the molecular layer (*M*) is less intense.



The staining procedures used are those employed in our laboratory for several years.

DPNH- and TPNH-Tetrazolium Reductase Activities: This is the procedure of Novikoff (20). Sections are rinsed in distilled water and incubated at 37°C. until their color reaches the desired intensities, generally 10 to 30 minutes, in the following freshly prepared mixture: DPNH or TPNH (Sigma Chemical Corp.) 4 mg.; 1.2 ml. H₂O; 0.8 ml. 0.1 M phosphate buffer, pH 7.4; 1 ml. "nitro-BI" (Dajac Division, Borden Chemical Co.), 1 mg./ml. The sections are then rinsed in distilled water and mounted in glycerogel.

Acid Phosphatase Activity: This is the method of Gomori (8). Sections are rinsed in distilled water and incubated for 20 to 45 minutes at 37°C. in an appropriate volume of the following mixture (which keeps for weeks in the refrigerator): 500 ml. 0.05 M acetate buffer, pH 5.0; 600 mg. lead nitrate; and 50 ml. 3 per cent sodium glycerophosphate (25 per cent alpha, 75 per cent beta). They are then rinsed in distilled water, placed in dilute ammonium sulfide for 1 to 2 minutes, washed well in distilled water, and mounted in glycerogel.

Activities of Adenosinetriphosphatase and Related Phosphatases: This is the method of Wachstein and Meisel (31). Sections are rinsed in distilled water and incubated at 37°C. for 10 to 30 minutes in a mixture, prepared just before use, which contains 25 mg.

adenosinetriphosphate, disodium salt (Sigma Chemical Corp.); 22 ml. distilled water; 20 ml. 0.2 M tris-maleate buffer, pH 7.2; 3 ml. 2 per cent lead nitrate; and 5 ml. 0.1 M magnesium sulfate. Following incubation, sections are treated as in the acid phosphatase method.

For related phosphatase activities, equal weights of adenosinediphosphate or adenosinemonophosphate (5'-adenylic acid) (Sigma Chemical Corp.) are substituted for the ATP. Incubation times are generally from 20 to 45 minutes.

Alkaline Phosphatase Activity: This is the method of Gomori (8). Sections are rinsed in distilled water and incubated for 30 minutes to 2 hours at 37°C. in the following freshly prepared mixture: 10 ml. 0.2 M propanediol buffer, pH 9.4; 5 ml. 2 per cent sodium glycerophosphate (25 per cent alpha, 75 per cent beta); 1 ml. 2 per cent calcium chloride; 0.5 ml. 5 per cent magnesium sulfate; 3.5 ml. distilled water. The sections are then rinsed well in distilled water, placed in 2 per cent cobalt nitrate for 2 minutes, washed well in two changes of distilled water, treated for 1 to 2 minutes with dilute ammonium sulfide, washed in distilled water, and mounted in glycerogel.

In all instances, parallel sections incubated in media lacking substrate serve as controls. Only the stain present in sections incubated with substrate

FIGURE 9

Interpeduncular nucleus: acid phosphatase activity; incubation time: 30 minutes. $\times 1700$.

Note the numerous large lysosomes in the cytoplasm of neuron cell bodies and in the cell processes. A few, less intensely stained lysosomes are present in the cytoplasm of neuroglia (G).

FIGURE 10

Cerebellum: acid phosphatase activity; incubation time: 30 minutes. $\times 720$.

Abundant lysosomes are present in the cytoplasm of Purkinje cells (P), including their apical dendrites. A moderate number of lysosomes are seen in neurons of the molecular layer (M) and granular layer (G).

FIGURE 11

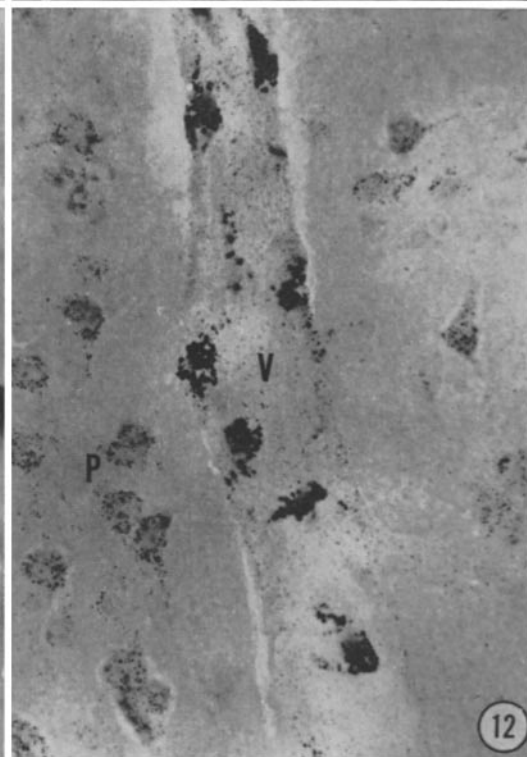
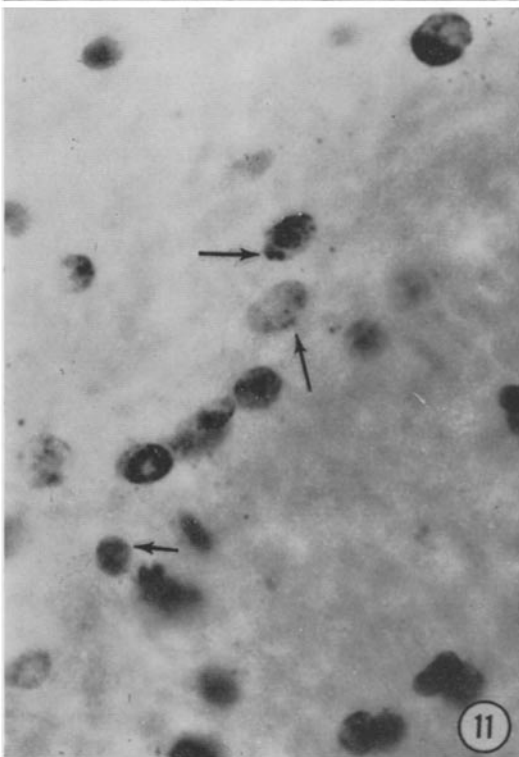
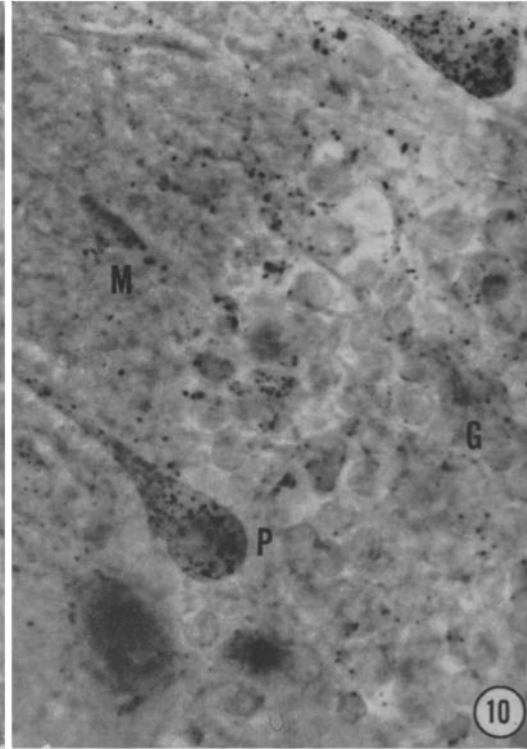
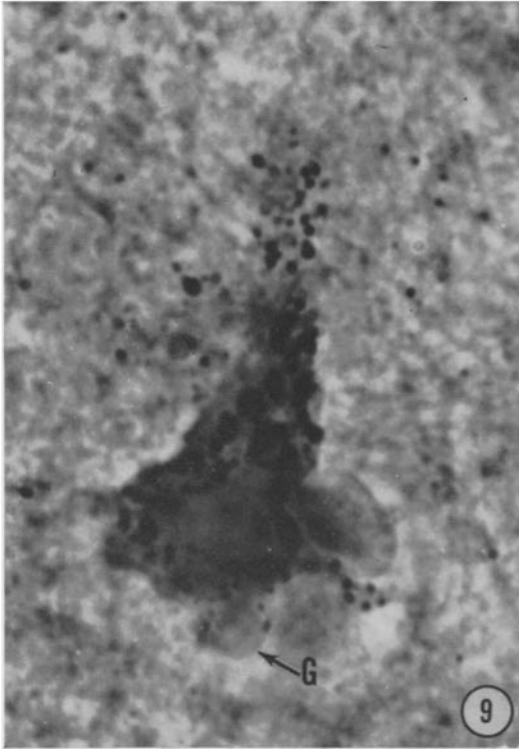
Corpus callosum: acid phosphatase activity; incubation time: 30 minutes. $\times 720$.

Several lysosomes (arrows) can be seen in the oligodendroglia. The nuclei appear black in the photograph but on the slide they are a deep brown.

FIGURE 12

Cerebral cortex: acid phosphatase activity; incubation time: 30 minutes. $\times 500$.

Large lysosomes are abundant in perinuclear cytoplasm of endothelial cells of the capillary (V). In the rest of the endothelial cell cytoplasm, they are less numerous and stain lightly, somewhat less lightly than in pyramidal cells (P).



and absent in sections incubated without substrate are described in the results. In almost all cases the background control color is negligible.

RESULTS

Generally the frozen sections yield preparations in which neuronal cytoarchitecture as well as blood vessels, ependyma, and choroid plexus, are well preserved. In contrast, the preservation of neuroglia is poor, except in patches where the freezing damage is apparently less extensive. Polyvinyl alcohol sections, although variable and sometimes difficult to cut, give good preservation of neuroglia as well as other cells. For preservation of cell membranes the polyvinyl alcohol sections are in most instances superior to the frozen sections.

Acid Phosphatase Activity: The "chemoarchitectonics" (29) of the brain are well demonstrated in the acid phosphatase preparations. All neurons stain, the larger ones generally more so than the smaller ones.

In the cerebrum, most prominent staining is found in the large cortical pyramidal cells (Fig. 1),

pyriform cortex, lamina cellularum mitralum of the olfactory bulb, fascia dentata, and pyramidal band of the hippocampus.

The larger neurons of the basal ganglia and the thalamic and hypothalamic neurons stain prominently. Moderate neuronal staining is noted throughout the brain stem, with the cranial nerve and interpeduncular nuclei staining most heavily.

The cerebellar architectonics are emphasized by darkly stained Purkinje cells, moderately stained granular layer, and minimally stained molecular layer (Fig. 5).

Minimal staining is present in white matter, major fiber tracts, and neuropil. This can in part be accounted for by the slight staining of astrocytes and oligodendroglia. Considerable staining is present in microglia, ependyma, and choroid plexus, and blood vessels.

On an intracellular level, the acid phosphatase activity in all cells is localized in cytoplasmic bodies presumed to be lysosomes. Varying in size from 0.3 to 0.7 μ , these cytoplasmic organelles are blackened by accumulated lead sulfide.

FIGURE 13

Cerebellum: activity with ATP as substrate; incubation time: 30 minutes. $\times 720$.

Note staining of: (1) plasma membrane of Purkinje cell and its apical dendrite (arrow); (2) the elements of the neuropil; and (3) the capillaries (*v*), some of which are seen in association with the Purkinje cells.

This is a polyvinyl alcohol section.

FIGURE 14

Cerebellum: activity with ADP as substrate; incubation time: 30 minutes. $\times 720$.

Stain is seen in the capillaries (*V*) and in the astrocyte (*G*) plasma membrane (arrow).

This is a polyvinyl alcohol section.

FIGURE 15

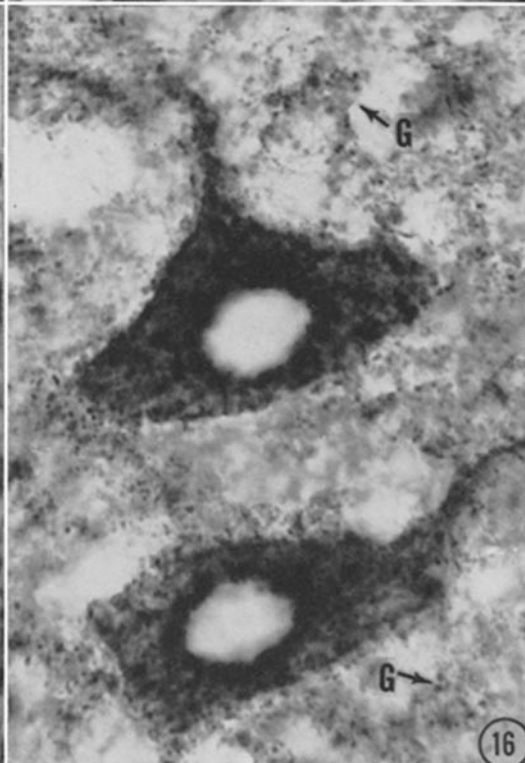
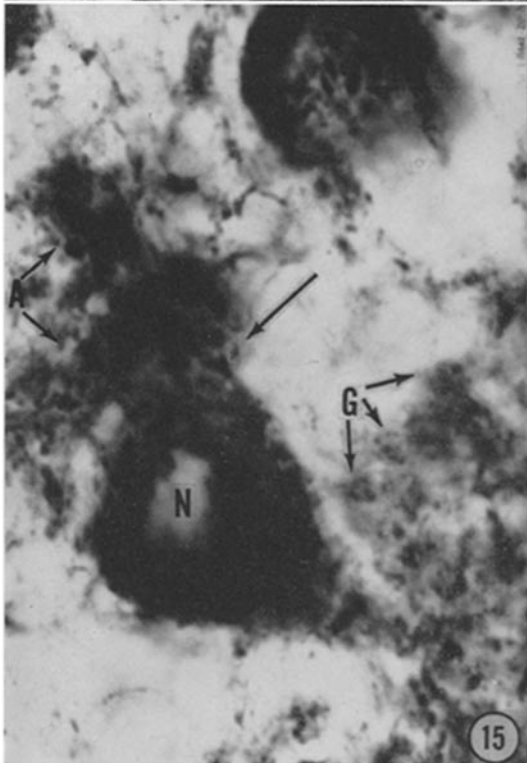
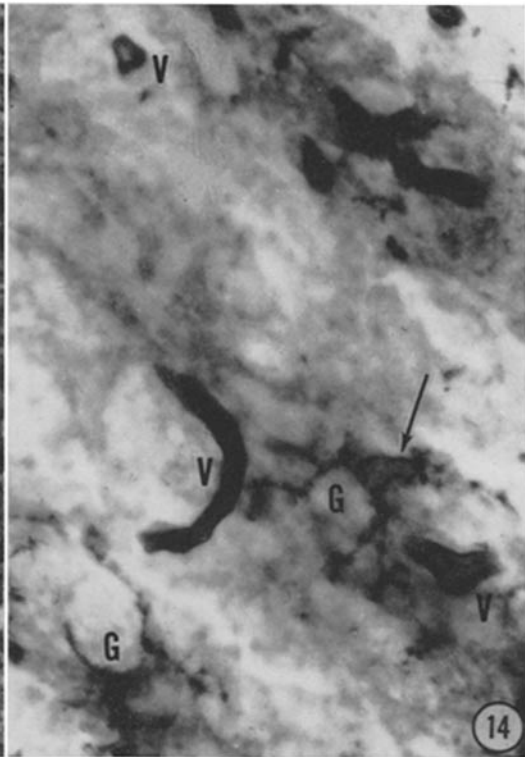
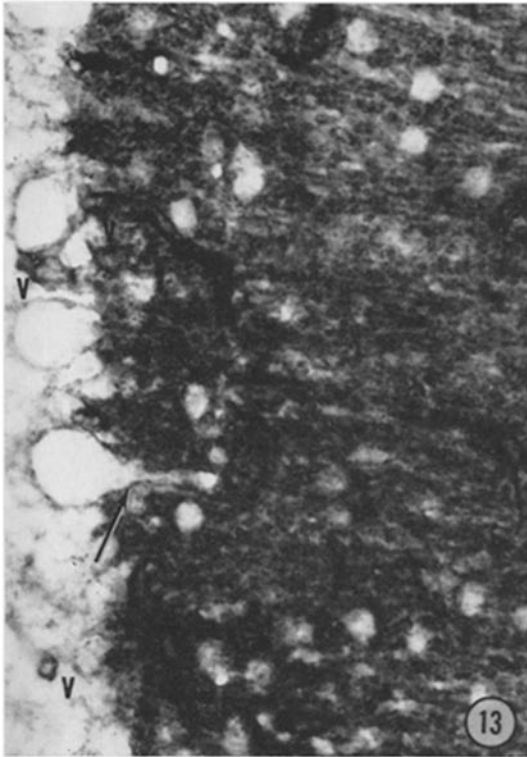
Cerebellum: DPNH-tetrazolium reductase activity; incubation time: 45 minutes. $\times 1800$.

In the Purkinje cell, the unstained nucleus (*N*) is surrounded by extensive formazan deposits. In regions (arrow) there are suggestions of stained Nissl substance clumps. Note formazan in the apical dendrites (*A*) of the Purkinje cell and in the neuroglia (*G*).

FIGURE 16

Nucleus rubor: TPNH-tetrazolium reductase activity; incubation time: 55 minutes. $\times 1000$.

Note, in the neurons, the unstained nuclei, and the absence of large clumps such as stained Nissl substance would show. The stained structures are probably mitochondria; note that they extend into the cell processes. The neuroglia (*G*) are also stained.



In general, larger neurons possess larger and more numerous lysosomes. The lysosomes appear to be randomly distributed in the cytoplasm. They are readily seen in the dendritic processes (Figs. 9 and 10), but their presence in axons is more difficult to establish. Their presence in axons is suggested by the linear lysosome arrangement sometimes seen in the fiber tracts.

Relatively few lysosomes are seen in the neuroglia (Figs. 9 and 11). The epithelial cells of ependyma and choroid plexus contain a great many lysosomes. These are frequently very large. They tend to be more numerous in the apical halves of the cells. This polarization is more readily observed in the ependymal cells (Fig. 17).

Large lysosomes are often noted in the endothelial cells of blood vessels, clustered in the perinuclear zones (Fig. 12). In the more peripheral parts of the cells the lysosomes are smaller and less intensely stained.

Nuclear and nucleolar staining is uncommon and inconstant. When present, the color is brown rather than black.

Alkaline Phosphatase Activity: At the incubation times used, only the capillaries give evidence of alkaline phosphatase activity (Fig. 3). Walls of

large blood vessels are negative, as are neurons and other brain elements.

Activities of Adenosinetriphosphatase and Related Enzymes: Because their cytoplasm is unstained in these preparations, the cell bodies of neurons are often conspicuous by their pale color (Fig. 13). In some neurons (e.g., those in the granular layer of the cerebellum) the cell membranes are also unstained. On the other hand, the membranes are darkly stained in other neurons, such as Purkinje cells (Fig. 13, arrow), pyramidal cells and neurons of the hippocampus. In such neurons the dendritic processes are also darkly stained whereas the axons are essentially unstained. In the neuropil, rich in arborizations and synaptic junctions, the dark color of the stained cell membranes precludes a definitive judgment regarding cytoplasmic staining. To the extent that such staining occurs it contributes to the color of layers like the molecular layer of the cerebellum (Figs. 6 and 13), polymorphic cell layer of the fascia dentata and plexiform layer of the cerebral cortex (Fig. 2). Neuroglia and capillaries contribute to the color of these layers since both are darkly stained in all parts of the brain. In the neuroglia the stain is localized in the cell membranes. In the capillaries we are unable to specify whether the stain is in endothelial

FIGURE 17

Ependymal cells (*E*), 3rd ventricle: acid phosphatase activity; incubation time: 30 minutes. $\times 720$.

The lysosomes are concentrated between the nuclei and luminal (*L*) surface. A few neurons (*N*) are visible.

FIGURE 18

Ependymal cells, aqueduct of Sylvius: ATPase activity; incubation time: 20 minutes. $\times 1800$.

Note staining of the plasma membranes (arrows) of the ependymal cells (*E*). The lumen of the aqueduct of Sylvius is seen at *L*.

FIGURE 19

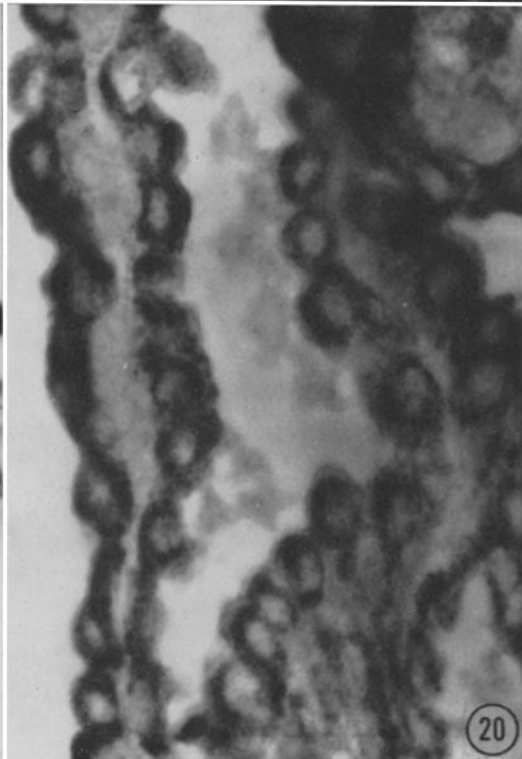
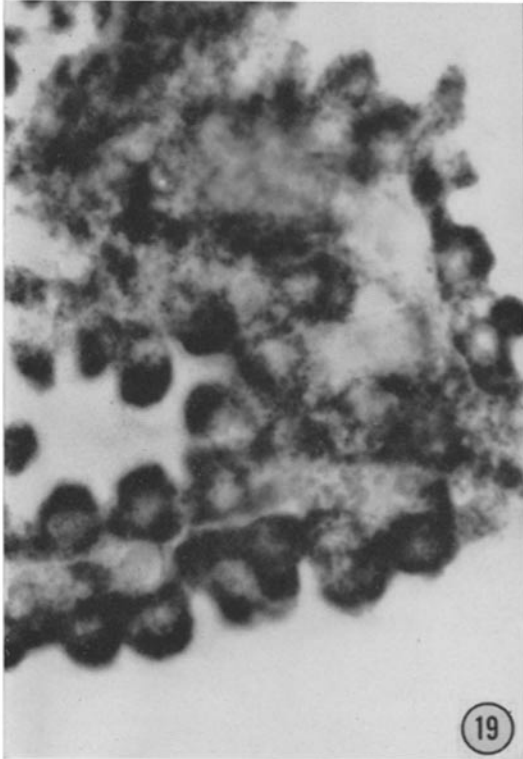
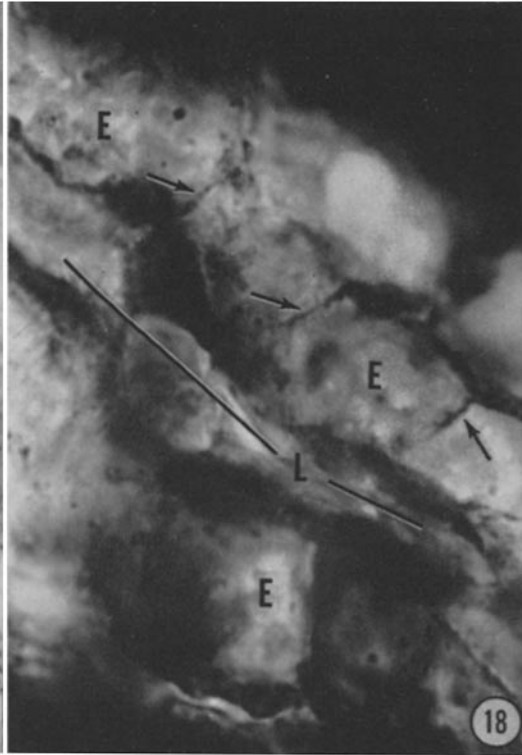
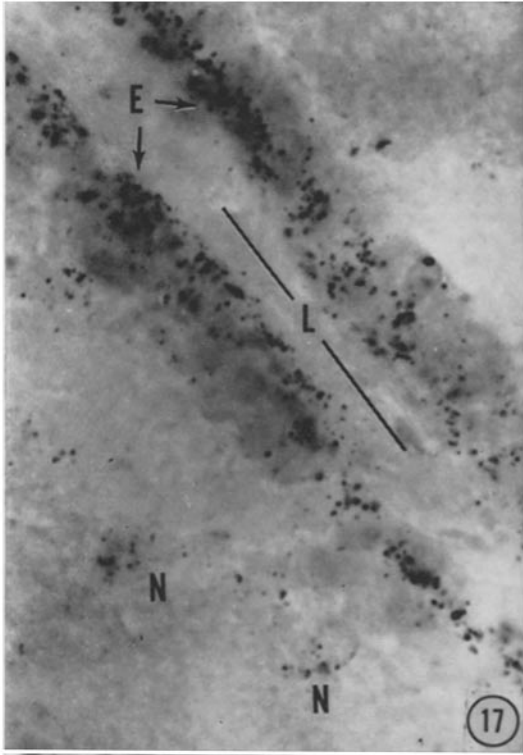
Choroid plexus: DPNH-tetrazolium reductase activity; incubation time: 45 minutes. $\times 720$.

The cytoplasmic formazan deposits in the choroid cells are too extensive to permit visualization of individual organelles.

FIGURE 20

Choroid plexus: TPNH-tetrazolium reductase activity; incubation time: 55 minutes. $\times 720$.

The stained structures in the choroid cells appear to be mitochondria.



cell membranes or basement membranes or both. In arterioles, the cell membranes of endothelial and muscle cells stain darkly. Fiber tracts show little or no stain.

Astrocytic membranes stain somewhat more prominently than those of the oligodendroglia. Since their processes are often readily followed in these preparations and because capillaries are strongly stained, the intimate association of glia and capillaries is readily apparent.

In epithelial cells of both ependyma and choroid plexus the cell membranes are deeply stained (Fig. 18).

Some diffuse cytoplasmic staining and minimal staining of nuclei and nucleoli are seen in neurons and in choroid and ependymal epithelia. However, the intensity of staining is too low to permit meaningful interpretation.

When ADP is substituted for ATP in the incubation medium, the cell membranes of neuroglia still stain as do the blood vessels (Fig. 14). In contrast, the plasma membranes of cell bodies and dendrites are unstained. As a result, the prominent staining of the neuropil characteristic of ATPase activity (Fig. 6) is missing with ADP (Fig. 7). However, with prolonged incubation in the ADP medium (3 hours or more) the neuropil is stained.

With A5'P as substrate none of the cell membranes gives evidence of activity.

DPNH- and TPNH-Tetrazolium Reductase Activities: The stain (*i.e.*, reduced ditetrazolium, or diformazan) that results from the activities of these oxidative enzymes gives excellent visualization of brain architectonics (Figs. 4 and 8). The same pattern is shown with both substrates, but the intensity of stain is much less with TPNH than DPNH.

Prominent staining is seen in the larger neurons of the cerebral cortex, the Purkinje and granule layers of the cerebellar cortex, and the neurons of cerebellar nuclei and cranial nerve nuclei. Moderate staining is present in the remaining neurons, neuroglia, blood vessels, and fiber tracts. The epithelia of ependyma and choroid plexus are heavily stained.

Within the neurons, diformazan deposits are much more extensive with DPNH than TPNH. As already described by one of us (16), the localization of TPNH-tetrazolium reductase activity appears to be chiefly mitochondrial, with no indication of staining of Nissl substance (Fig. 16).

In contrast, the DPNH-tetrazolium reductase activity of all cytoplasmic elements is so high that with the incubation times used it is difficult in most cases to distinguish either mitochondria or Nissl substance (Fig. 15). Both TPNH- and DPNH-tetrazolium reductase activities are present in dendritic processes. From the linear arrangement of formazan deposits in the fiber tracts this would also appear to be true of axons.

As in neurons, the DPNH-tetrazolium reductase activity is present in mitochondria and probably in other cytoplasmic structures of neuroglia (Fig. 15), epithelial cells of the ependyma and the choroid plexus (Fig. 19), and endothelial and smooth muscle cells of capillaries and arterioles. In these cells, as in neurons, TPNH-reductase activity results in apparently exclusively mitochondrial staining (Figs. 16 and 20). The stained mitochondria appear to be concentrated around the nuclei in choroid epithelial cells (Fig. 20) as in neurons (Fig. 16).

DISCUSSION

We have made no attempt to present a detailed anatomic atlas of the several enzyme activities in the rat brain. Rather, it has been our intention to illustrate the value of sections of formol-calcium-fixed tissue for studying both enzymatic "chemoarchitectonics" (29) and intracellular organelles. These organelles include structures of unquestioned physiological significance. The cell membranes are of obvious importance in transport in and out of cells and in nerve impulse conduction. Vital oxidative enzymes are localized in the mitochondria and also in the Nissl substance. The participation of lysosomes (5) in pinocytosis, phagocytosis, and other fundamental cellular activities has recently been indicated (4, 15, 16, 19).

The studies reported here add to the meagre information concerning the neuroglia (26). To the observations of Friede (7) and Potanos *et al.* (27) that these cells show succinic dehydrogenase activity can be added the presence of both DPNH- and TPNH-tetrazolium reductase activities. They also possess acid phosphatase-rich lysosomes. An ATPase-like enzyme appears to be localized in their plasma membranes. Whether the membrane contains a specific ATPase is not clear since staining also occurs with ADP, as in the case of the blood vessel endothelium. Such staining could

result from a single "apyrase," capable of hydrolyzing both high energy phosphate groups, or a combination of two specific enzymes, ATPase and ADPase (for similar situations in other tissues, see 17, 18 and 21).

In contrast, the phosphatase in cell membranes of some neurons appears to be a specific ATPase since the membranes are unstained when ADP is substituted for ATP. A similar situation is found in the membranes at the base of renal tubule cells (17) and this may imply that the presumed ATPase is related to a general function like molecular transport across membranes rather than to a peculiarly neuron function such as impulse conduction (*cf.* 13, 18).

We may speculate briefly concerning the lysosomes (5) of neurons, neuroglia, and capillary endothelial cells. From the observations of Novikoff and colleagues (15-19, 24), the general role consistent with their appearance in these cells is a close relationship to, sometimes an identity with, pinocytosis vacuoles (for a full discussion, see de Duve (4) and Novikoff (19)). In capillary endothelium the lysosomes appear to be concentrated to one side of the nucleus (Golgi zone) in a fashion reminiscent of the movement of pinocytosis vacuoles towards the Golgi zone in cultured HeLa cells (28). Their large size and apparently high level of acid phosphatase activity suggests that lysosomes are involved in the mechanisms of the blood-brain barrier.

The meaning of the polarized distribution of lysosomes in the cells of ependyma and choroid plexus is not clear; nor is their large size and apparently high level of activity. It may be relevant that Case (3) has recently described bodies in the electron micrographs of guinea pig choroid plexus that he suggests may be related to the uptake of materials from the ventricular fluid or to the storage of waste products of cell metabolism. Some of these probably correspond to lysosomes (15).¹ One of us (19) has noted a similar correspondence between large lysosomes in the superficial cells of rat bladder and bodies described by Walker (32) in electron micrographs of these cells. Walker considers that some of the

materials sequestered from the urine are segregated in these bodies.

The observation that Nissl substance has high DPNH-tetrazolium activities is consistent with observations on the basophilic material of liver, pancreas, and other cells (16, 20). It helps draw attention to a significant role of this substance in electron transport of the cell.

It should be indicated that observations with the enzymatic staining methods here employed may supplement the information obtained by application to the brain of the elegant techniques of quantitative histochemistry developed by Linderstrøm-Lang, Lowry, and others. Staining methods give essentially no information regarding quantitative levels of enzyme activities; and negative observations may be misleading, particularly in fixed tissues (*e.g.*, mitochondrial ATPase can not be demonstrated in formol-calcium-fixed tissue (22)). On the other hand, *positive* observations with these qualitative techniques give more *direct* evidence than that presently available with the quantitative techniques, on a histological level and particularly on a cytological level. As the name indicates, the quantitative techniques are still histo- rather than cytochemical (see 26). For example, our observations may fill the need noted recently by Hess and Pope (25) for the "more precise determination" of ATPase localization. Hess and Pope were discussing the calcium-activated ATPase activities which they measured in separated cytoarchitectonic layers of the rat cortex. The distribution pattern of calcium-activated ATPase activity closely paralleled that for acetylcholinesterase, leading to the conclusion that both enzymes are localized "in the cortical plexuses of axons and dendrites" (25) and "cytologically at the surface membranes of the cell bodies and processes" (26). It is highly likely that the enzyme activity we have demonstrated is the same as that studied by Hess and Pope (see 21).

Another illustration of the manner in which direct staining observations may supplement quantitative histochemical data can be cited. From studies on phagocytes (15, 16, 19) it may be anticipated that the staining method will help evaluate the relative contributions made to the acid phosphatase changes during Wallerian degeneration (10) by the lysosomes of invading macrophages and by those of neuroglia and neurons.

¹Since this was written, the report by V. M. Tennyson (*Anat. Rec.*, 1960, 136, 290) has come to our attention. She finds that the choroid plexus cells ingest thorium dioxide from the cerebrospinal fluid and segregate it in cytoplasmic vacuoles.

The simplicity of preparing either frozen sections or polyvinyl alcohol-embedded sections makes it possible to study easily the changes occurring in cells under varied physiological states and pathological circumstances. Thus, one of us (Novikoff, unpublished) has used DPNH-tetrazolium reductase activity to follow the changes in renal mitochondrial form and activity resulting from ligation of the renal vessels, and one of us

(Becker, unpublished) has employed acid phosphatase activity as a means of studying anoxia-induced changes in the lysosomes of brain cells. The role of lysosomes in necrobiosis has been discussed in chemical terms by de Duve (4) and in morphological terms by Novikoff (14-19).

We wish to thank Mr. L. Jay Walker for generous assistance in the preparation of the photomicrographs.

BIBLIOGRAPHY

1. BAKER, J. R., The histochemical recognition of lipine, *Quart. J. Micr. Sc.*, 1946, **87**, 441.
2. BOURNE, G. H., Histochemical demonstration of phosphatases in the central nervous system of the rat, *Exp. Cell Research*, 1958, suppl., **5**, 101.
3. CASE, N. M., Hemosiderin granules in the choroid plexus, *J. Biophysic. and Biochem. Cytol.*, 1959, **6**, 527.
4. DE DUVE, C., Lysosomes, a new group of cytoplasmic particles, in *Subcellular Particles*, (T. Hayashi, editor), New York, Ronald Press, 1959, 128.
5. DE DUVE, C., PRESSMAN, B. C., GIANETTO, R., WATTIAUX, R., and APPELMANS, F., Tissue fractionation studies. 6. Intracellular distribution patterns of enzymes in rat liver tissue, *Biochem. J.*, 1955, **60**, 604.
6. FEDER, N., Polyvinyl alcohol as an embedding medium for lipid and enzyme histochemistry, *J. Histochem. and Cytochem.*, 1959, **7**, 292.
7. FRIEDE, R. L., Histochemical investigations on succinic dehydrogenase in the central nervous system. I, II, *J. Neurochem.*, 1959, **4**, 101, 111.
8. GOMORI, G., *Microscopic Histochemistry: Principles and Practice*, Chicago, University of Chicago Press, 1952.
9. LANDOW, H., KABAT, E. A., and NEWMAN, W., Distribution of alkaline phosphatase in normal and neoplastic tissues of the nervous system, *Arch. Neurol. Psych.*, 1942, **48**, 518.
10. MCCAMAN, R. E., and ROBINS, E., Quantitative biochemical studies of Wallerian degeneration in the peripheral and central nervous systems. II. Twelve enzymes, *J. Neurochem.*, 1959, **5**, 32.
11. NAIDOO, D., and PRATT, O. E., The localization of some acid phosphatases in brain tissue, *J. Neurol. Neurosurg. and Psych.*, 1951, **14**, 287.
12. NOVIKOFF, A. B., Histochemical and cytochemical staining methods, in *Analytical Cytology*, (R. C. Mellors, editor), New York, McGraw-Hill Company, 1955, 2/1.
13. NOVIKOFF, A. B., The intracellular localization of chemical constituents, in *Analytical Cy-*
14. NOVIKOFF, A. B., The proximal tubule cell in experimental hydronephrosis, *J. Biophysic. and Biochem. Cytol.*, 1959, **6**, 136.
15. NOVIKOFF, A. B., Lysosomes and the physiology and pathology of cells, *Biol. Bull.*, 1959, **117**, 385.
16. NOVIKOFF, A. B., Biochemical and staining reactions of cytoplasmic constituents, in *Developing Cell Systems and their Control*, (D. Rudnick, editor), New York, Ronald Press, 1960, 167.
17. NOVIKOFF, A. B., The rat kidney: electron microscopic and cytochemical studies, in *Biology of Pyelonephritis*, (E. Quinn and E. Kass, editors), Boston, Little, Brown and Company, 1960, 113.
18. NOVIKOFF, A. B., Enzyme localization in tumor cells, in *Cell Physiology of Neoplasia*, (T. C. Hsu, editor), Texas, University of Texas Press, in press.
19. NOVIKOFF, A. B., Lysosomes and related particles, in *The Cell*, (J. Brachet and A. E. Mirsky, editors), New York, Academic Press, Inc., in press.
20. NOVIKOFF, A. B., Electron transport enzymes: biochemical and tetrazolium staining studies, *Proc. 1st Intl. Cong. Histochem. and Cytochem., Paris*, in press.
21. NOVIKOFF, A. B., DRUCKER, J., SHIN, W.-Y., and GOLDFISCHER, S., Further studies on the apparent adenosinetriphosphatase activity of cell membranes in formol-calcium-fixed tissues, *J. Histochem. and Cytochem.*, in press.
22. NOVIKOFF, A. B., HAUSMAN, D. H., and PODBER, E., The localization of ATPase in liver: *in situ* staining and cell fractionation studies, *J. Histochem. and Cytochem.*, 1958, **6**, 61.
23. NOVIKOFF, A. B., and MASEK, B., Survival of lactic dehydrogenase and DPNH-diaphorase activities after formol-calcium fixation, *J. Histochem. and Cytochem.*, 1958, **6**, 217.

24. NOVIKOFF, A. B., RUNLING, B., DRUCKER, J., and KAPLAN, S. E., Uptake of proteins and their intracellular fate: a cytochemical and electron microscopic study, *J. Histochem. and Cytochem.*, **8**, 319.
25. HESS, H. H., and POPE, A., Intralaminar distribution of adenosinetriphosphatase activity in rat cerebral cortex, *J. Neurochem.*, 1959, **3**, 287.
26. POPE, A., and HESS, H. H., Cytochemistry of neurones and neuroglia, in *Metabolism of the Nervous System*, (D. Richter, editor), London, Pergamon Press, 1957.
27. POTANOS, J. N., WOLF, A., and COWEN, D., Cytochemical localization of oxidative enzymes in human nerve cells and neuroglia, *J. Neuro-path. and Exp. Neurol.*, 1959, **18**, 627.
28. ROSE, G., Microkinetospheres and VP satellites of pinocytic cells observed in tissue cultures of Gey's strain HeLa with phase contrast cinematographic techniques, *J. Biophysic. and Biochem. Cytol.*, 1957, **3**, 697.
29. SCHARRER, E., and SINDEN, J., A contribution to the "chemoarchitectonics" of the optic tectum of the brain of the pigeon, *J. Comp. Neurol.*, 1949, **91**, 331.
30. SHIMIZU, N., and MORIKAWA, N., Histochemical studies of succinic dehydrogenase of the brain of mice, rats, guinea pigs and rabbits, *J. Histochem. and Cytochem.*, 1957, **5**, 334.
31. WACHSTEIN, M., and MEISEL, E., Histochemistry of hepatic phosphatases at a physiologic pH, *Am. J. Clin. Path.*, 1957, **27**, 13.
32. WALKER, B. E., Electron microscopic observations on transitional epithelium of the mouse urinary bladder, *J. Ultrastruct. Research*, 1960, **3**, 345.
33. WOLF, A., KABAT, E., and NEWMAN, W., Histochemical studies on tissue enzymes. III, *Am. J. Path.*, 1943, **19**, 423.
34. WOLFGRAM, F., and ROSE, A. S., The histochemical demonstration of dehydrogenases in neuroglia, *Exp. Cell Research*, 1959, **17**, 526.