

## Oculocutaneous Aspects of Rosacea

by P A J Starr MD FRCS  
and Angus Macdonald MB MRCP  
(Skin Department, St Mary's Hospital, London)

For over a hundred years it has been well recognized that rosacea, a common skin disease, may affect the eyes. A review of the early literature by Holloway (1910) gives Arlt (1864) the credit for first associating the ocular and cutaneous manifestations of the condition.

The incidence and nature of the eye lesions have been examined on various occasions in the past (Borrie 1953, Goldsmith 1953) but although detailed investigations have been analysed, as with the skin disease, no firm conclusions have been reached in respect of aetiology.

Standard clinical and histopathological descriptions of the skin disease are on the whole unhelpful in suggesting the causation. However, the generally accepted findings are: (1) Capillary dilatation with a diffuse dermal infiltrate (this corresponds with the erythematous, telangiectatic stage). (2) Pustule formation. (3) Sebaceous gland hypertrophy (corresponding to the phyma stage).

The eye changes are usually regarded as consisting of: (1) Hyperaemia of the lid margin with associated squamous blepharitis. (2) Conjunctival hyperaemia, most marked in the interpallebral fissure, and phlyctenule-like nodules without ulceration. (3) Fine punctate epithelial lesions of the cornea and subepithelial infiltrates, leaving a clear limbal zone. Opacities are initially superficial, but later may be at all stromal levels with accompanying vascularization.

The purpose of our investigation has been to examine the eye changes in a number of patients with cutaneous rosacea, to relate our findings to those previously reported, and to see whether close examination of the eye changes in skin patients would contribute to our knowledge of the aetiology of the condition as a whole. We present our findings only as a preliminary report of an investigation still in progress, from which, we hope, more definite information will later emerge.

### Method and Findings

During the past year we have examined the eyes of 57 patients suffering from rosacea of all degrees of severity. They were consecutive cases which had been referred to the Skin Department

of St Mary's Hospital, Paddington, for advice on their cutaneous condition. This was carefully documented, special note being taken of the areas of skin involved, the duration of the disease, possible aetiological factors, flushing factors and treatment. Eye symptoms and signs were also recorded with anatomical subdivision into lid margin, conjunctiva and cornea. Typical cases showed the characteristic cross distribution on the flush areas of forehead, nose, chin and cheeks. Generally erythema, telangiectasis, papules, pustules and hypertrophy occurred in sequence, but sometimes they were present at one and the same time in various parts of the skin of the face. In one case the hypertrophy of the skin of the nose was an entirely isolated finding. Lid margins frequently showed telangiectases, and spider naevi and other angiomatous malformations were often seen on the tarsal conjunctiva.

Table 1

Consecutive cases of rosacea seen at the Skin Clinic, St Mary's Hospital  
Degree of eye involvement and tendency to flushing

	No. of cases		Total
	Male	Female	
Total cases	30	27	57
Definite eye involvement	24	9	33
Corneal involvement	14	5	19
Strong flushing responses in cases with eye involvement	18 (75%)	9 (100%)	27
Strong flushing responses in cases without eye involvement	3 (50%)	7 (39%)	10

Telangiectases in the conjunctiva were of various forms and the majority of cases showed vessel dilatation in the interpallebral fissure, and limbal infiltrates, around which small blood vessels proliferate, were common. Histologically these infiltrates are composed of plasma cells, lymphocytes, endothelial cells and a few giant cells. One of the most characteristic changes was the 'arcade' of dilated vessels in the superficial limbal plexus. They were usually in the inferior quadrants and did not extend for any distance into the cornea. The earliest corneal involvement showed infiltration in the superficial stroma, with a 'lucid interval' between the greyish haze and lashes of invading blood vessels. Notably a number of corneae showed infiltration in the deeper layers of the stroma, and thinning of the overlying cornea was sometimes obvious in these instances. Focal corneal abscesses with secondary bacterial infection produced the severest symptoms of keratoconjunctivitis and led to permanent scarring. Our series of cases showed an equal sex incidence. Definite eye involvement was apparent in 58% of cases with 33% of the corneae showing some signs of rosacea (Table 1). This is markedly different from Borrie's (1953) findings of only 3%

of unselected cases showing gross corneal changes. It was particularly noteworthy that all the women and 75% of the men with eye signs had a very marked tendency to flush easily.

Ocular rosacea is a common disease which is frequently undiagnosed (Duke-Elder 1965). Recognition of the lid and conjunctival signs will show that it is a much less rare concomitant of facial rosacea than hitherto thought.

### Discussion

From the outset we were impressed by the frequency of vascular changes in the eyes and their similarity to those in the skin. Despite the lack of histological evidence of vasculitis, and the absence of a direct spatial relationship of vessels to the dermal lesions, we think that the erythema, telangiectasia and flushing cannot be discounted as secondary. Marks (1967) has analysed and discarded many current hypotheses, but he found that his group of cases differed significantly from controls in flushing more frequently, more readily and in response to a wider variety of stimulants.

It has been shown (Fox *et al.* 1962, Blair *et al.* 1961) that the vasomotor control of the skin differs greatly from one anatomical site to another. Some areas are normally in a state of vasoconstriction, and vasodilatation, when it occurs, does so by means of passive relaxation of the vessel walls. In some areas active vasodilatation predominates, and in others both mechanisms contribute.

The flush areas, consisting of the cheeks, forehead, scalp, neck and the V of the chest, are unique in depending almost entirely on an active vasodilator mechanism, there being little or no constrictor activity. This accounts for the minimal vasoconstriction in these areas in response to cooling, and for their exaggerated response to circulating vasodilator substances, such as histamine, as compared with other body skin.

In 1956 Hilton & Lewis showed that the vasodilatation, which accompanied secretory activity of the submandibular salivary gland, was due to the production by the gland of the vasoactive polypeptide bradykinin, and Fox & Hilton (1958) suggested that a similar mechanism might apply to active vasodilatation in the skin. They showed experimentally that there was a correlation between vasodilation, sweat gland activity and bradykinin formation, and suggested that the vasodilatation was entirely dependent on the bradykinin. This explained a finding which had

troubled previous workers, namely that, although sweat production could be suppressed by intra-arterial atropine, vasodilatation could not.

Further evidence in favour of this hypothesis comes from an observation made by Green *et al.* (1956) who showed that cats and dogs, having no eccrine sweat glands in the skin of their limbs, have no active vasodilator mechanism; it is also interesting to note that gustatory sweating occurs in a similar cutaneous distribution to the flush or active vasodilator areas.

Our observations were further stimulated by findings in patients with carcinoidosis under the care of St Mary's Hospital Medical Unit. In this disease a secretory tumour produces 5-hydroxytryptamin (5HT) and polypeptide vasodilator substances of which bradykinin is the most significant. It is beyond the scope of this paper to go into the biochemical details, but the most important features are summarized in Fig 1. This shows how the carcinoid tumour, on stimulation

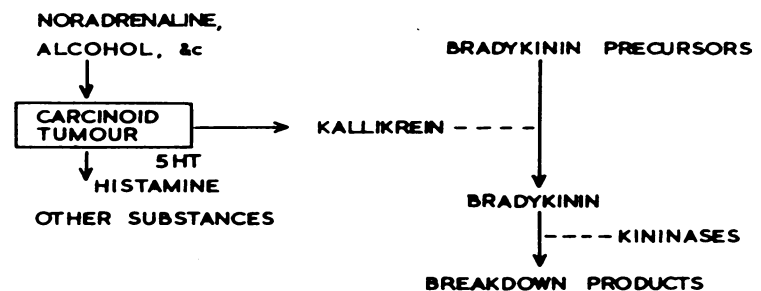


Fig 1 Diagrams showing the main metabolic pathways in carcinoidosis

by noradrenaline, alcohol, &c., can produce a number of substances. As far as flushing is concerned, the most important of these is the enzyme kallikrein which stimulates the production of bradykinin from inactive precursors in blood and tissue fluid. Bradykinin is itself rapidly broken down by kininases in blood and tissue fluid.

The majority of patients with carcinoidosis have erythematous, telangiectatic facies, some have papules, and in two reported cases (Calvert 1963, Mattingley 1956) classical changes of phyma rosacea have been found. In Calvert's case this was confirmed histologically.

Vascular changes in the eyes are very similar to those seen in rosacea. We have observed the development of gross conjunctival capillary engorgement, lid margin telangiectases, and a small hæmorrhage at the corneal limbus during the course of an induced carcinoid flush. It is possible that high circulating levels of 5HT or some other

nonvasodilator substance may stimulate these changes, but in the presence of the obviously dilated capillaries in the eyes and skin we feel that they are more likely to be related to repeated flushing. Rowell & Summerscales (1961) examined the 5-hydroxyindoleacetic acid (5HIAA) excretion of 21 rosacea patients and found it to be normal. The negative results are not really surprising as subsequent investigation has shown that 5HT does not produce the cutaneous flush even in carcinoid patients. Bradykinin levels in rosacea patients have not yet been measured.

With one of our rosacea patients in whom flushing was a prominent feature we carried out tests of various vasodilating agents. Rather as we expected, he flushed well with intravenous histamine and bradykinin, moderately with alcohol, and not at all with noradrenaline. This supported our view that in rosacea the receptors of the flushing mechanism are unduly sensitive to normal substances, rather than to abnormal humoral factors such as those circulating in carcinoidosis. We are developing a quantitative technique for measuring the flushing responses to dilator agents, but at present we have no results.

The part played by capillary dilatation in the aetiology of rosacea is to a certain extent open to speculation. We feel that the telangiectatic state is the end result of repeated flushing, leading to loss of integrity of the capillary walls and transudation of blood constituents into the tissue spaces of skin, conjunctiva or cornea. Secondary inflammatory lesions may result.

The basic question remains, what causes the initial dilatation? The following possibilities exist:

- (1) That the papular and hypertrophic changes in the skin are produced by the disease rosacea, and that the capillary dilatation is secondary. We think this unlikely in view of the vascular and hypertrophic changes seen in carcinoid patients.
- (2) That constitutional vasomotor instability *per se* is responsible for repeated vasodilatation which in time becomes permanent. This ignores the part played by factors which are well established as causing flushing responses.
- (3) That the dilatation is due to a circulating factor, similar though not identical to that in carcinoidosis.
- (4) That there is excessive release of, or tissue response to, a local vasodilator substance such as bradykinin.

It is possible to block pharmacologically some of the stages in the evolution of the carcinoid flush, but no effective bradykinin antagonist is known; it is likely that the mechanism of active vasodilatation, and its significance in rosacea will remain obscure until such an agent is available.

#### REFERENCES

- Arlt (1864) *Klin. Mbl. Augenheilk.* 2, 329  
 Blair D A, Glover W E & Roddie I C (1961) *J. appl. Physiol.* 16, 119  
 Borrie J P (1953) *Brit. J. Derm.* 65, 458  
 Calvert H T (1963) *Postgrad. med. J.* 39, 547  
 Duke-Elder S (1965) *System of Ophthalmology*. London; 8, 537  
 Fox R H, Goldsmith R & Kidd D J (1962) *J. Physiol. (Lond.)* 161, 298  
 Fox R H & Hilton S M (1958) *J. Physiol. (Lond.)* 142, 219  
 Goldsmith A J B (1953) *Brit. J. Derm.* 65, 448  
 Green H D, Howard W B & Kenan L F (1956) *Amer. J. Physiol.* 187, 469  
 Hilton S M & Lewis G P (1956) *J. Physiol. (Lond.)* 134, 471  
 Holloway T B (1910) *Arch. Ophthal.* 39, 321  
 Marks R (1967) *Brit. J. Derm.* 79, 638  
 Mattingley T W (1956) *Med. Ann. D.C.* 25, 304  
 Rowell N R & Summerscales J W (1961) *J. invest. Derm.* 36, 405

## Tetracyclines in the Treatment of Ocular Rosacea

by V J Marmion MRCPED FRCS ED  
*(Bristol Eye Hospital, Bristol)*

Ocular involvement in rosacea, which is characteristically a skin disorder, may be either a blepharoconjunctivitis or a keratitis, or very rarely an episcleritis. There is a high degree of correlation of the changes occurring in the eye with skin disease and treatment which is effective for the skin disorder, as suggested by Sneddon (1966), may therefore be of value in treatment of the ocular condition. The two facets of the ocular condition which have not previously been emphasized are the secondary complications of lid disease, that is, trichiasis and recurrent chalazia. The second aspect of the disease is the effect of trichiasis on the cornea and its relation to the keratitis which can be, and often is, an entity on its own.

A series of 23 patients were studied initially. Five of the patients with keratitis had no lid involvement. These patients were treated with oral oxytetracyclines 150 mg twice a day for six