

Bartonella (Rochalimaea) quintana Infection in a Seronegative Hemodialyzed Patient

MICHEL DRANCOURT,¹ VALÉRIE MOAL,² PHILIPPE BRUNET,² BERTRAND DUSSOL,²
YVON BERLAND,² AND DIDIER RAOULT^{1*}

Unité des Rickettsies, Faculté de Médecine, Centre National de la Recherche Scientifique, 13385 Marseille Cedex 05,¹
and Service de Néphrologie et Hémodialyse, Hôpital de Sainte-Marguerite, 13009 Marseille,² France

Received 6 December 1995/Returned for modification 11 January 1996/Accepted 22 February 1996

***Bartonella quintana* is a reemerging pathogen responsible for trench fever, endocarditis, bacteremia, and bacillary angiomatosis. We previously reported the first case of a patient with *B. quintana*-induced chronic adenomegaly, and here we present a report on a second patient. A hemodialyzed patient with Sjögren's syndrome presented with mediastinal adenomegalies and secondary pancytopenia. All diagnostic investigations remained negative, except that a *Bartonella*-like microorganism was isolated from a bone marrow biopsy. The isolate was identified as *B. quintana* by a specific mouse polyclonal antibody and by determination of a partial *gltA* (citrate synthase-encoding) gene and 16S rRNA gene sequences. DNA of the pathogen was also detected in the adenomegaly and in the serum of the patient by PCR amplification of the *gltA* gene. Anti-*B. quintana* antibodies were never detected in the patient's serum throughout the 12-month follow-up but were detected in the serum of the patient's cat. The patient's outcome was favorable after treatment with gentamicin. Chronic adenomegaly in seronegative patients is a new clinical entity due to *B. quintana*.**

The genus *Bartonella* contains eight extant species, four of which (*B. bacilliformis*, *B. quintana*, *B. henselae*, and *B. elizabethae*) are presently recognized as human pathogens. The clinical spectrum of infection associated with these species has recently undergone rapid expansion (15). *B. quintana* is responsible for trench fever (13, 14), endocarditis in homeless patients (1), bacteremia in alcoholic patients (11), and bacillary angiomatosis in immunocompromised patients (4). The only known reservoir for the species is humans, and although the bacterium is thought to be transmitted via *Pediculus humanis* lice, some patients have had no apparent exposure to this ectoparasite. We previously reported the first description of a patient with chronic adenopathy due to *B. quintana* infection (8), and in this article, we report on a second patient. Features common to both patients allow definition of this condition, which appears to be a new clinical entity.

MATERIALS AND METHODS

Case report. A 38-year-old woman presented with a fever of 39°C, a weight loss of 6 kg within 2 months, and a cough. She had had Sjögren's syndrome, treated with 7.5 mg of prednisolone per day, for 4 years and had undergone chronic hemodialysis for 7 months. Of possible relevance is the fact that she owned an adult cat and a flea-infected kitten, which had scratched her prior to admission. Pertinent laboratory data included 3.9×10^6 leukocytes per liter with 2.77×10^6 polymorphonuclear cells per liter, 189×10^6 platelets per liter, an erythrocyte sedimentation rate of 100 mm/h, hypergammaglobulinemia with 22.5 g of immunoglobulin G per liter, fibrinemia of 6.7 g/liter, and a C-reactive protein at a concentration of 40 mg/liter. Chest X-ray and computerized tomography scanning revealed mediastinal adenomegalies (Fig. 1). A mediastinoscopy was performed, and an adenopathy was biopsied. Histologic examination showed granulomatous inflammation with histiocytes and Langhans type giant cells surrounding necrotic zones with numerous polymorphonuclear cells (Fig. 2). Tests for pathogens, including mycobacteria and human immunodeficiency virus type 1, were negative, and the patient was treated orally with isoniazide, rifampin, Myambutol, and pyrimethamine. Immunologic explorations performed at that time disclosed a normal pattern of CD2/CD3, CD4, CD8, and CD19 lymphocytes. Five weeks later, the clinical findings were unchanged. An increase in steroid dosage led to the patient feeling less fatigued. Laboratory tests revealed

1.02×10^6 leukocytes per liter, with 0.35 polymorphonuclear cells per liter, on aspartate aminotransferase level of 200 U/liter (normal, <30 U/liter), and an alanine aminotransferase level of 105 U/liter (normal, <40 U/liter). Bone marrow aspirate and bone marrow biopsy revealed severe hypoplasia of the neutrophilic series, with a few myelocytes. Rifampin treatment was stopped because of presumptive diagnosis of bone marrow failure and hepatitis due to rifampin. Direct examination and culture of the bone marrow biopsy showed the presence of intramedullary *B. quintana*, and the treatment was changed to intravenous gentamicin given at 50 mg at the end of each hemodialysis course for 3 weeks; the steroid dosage was decreased to the initial dosage. At a 12-month follow-up examination, the patient was afebrile and her body weight had returned to normal.

Isolation and culture of the isolate. The blood sample, the bone marrow aspirate, and the homogenized bone marrow biopsy specimen were plated onto 5% sheep blood agar and incubated at 37°C in an atmosphere of 5% carbon dioxide and onto a human endothelial cell line (ECV 304) as previously reported (4).

Molecular detection and identification of the isolate. DNA was obtained from agar-grown single colonies of the isolate, from a frozen serum and whole blood sample, from a bone marrow aspirate and a bone marrow biopsy specimen, and from the cat's fleas by proteinase K-sodium dodecyl sulfate digestion followed by phenol-chloroform extraction and ethanol precipitation of nucleic acids. Fleas were not speciated prior to DNA extraction. A crude DNA extract was prepared from a fixed, paraffin-embedded mediastinal adenomegaly specimen by being boiled for 15 min in the presence of 20% Chelex 100 (12) prior to the procedure above. The sequence of the 16S rRNA gene of the agar-grown isolate was determined as previously reported (1). DNA extracts obtained from clinical material were used as templates in PCRs for the amplification of citrate synthase gene (*gltA*) fragments. The initial amplification employed *gltA* primers CS877p and CS1258n as previously described (10). Products from this reaction were then subjected to a second amplification with the *gltA* primers CSBH1 (5'-GCTA ATGAAGCATGCCTAAA-3') and CSBH2 (5'-AGCGTGATAGCAATATCA AG-3'), which were designed to amplify a 350-bp fragment within the products of the first PCR. These primers were chosen by reference to *gltA* gene sequence data for *Bartonella* spp. (2). Each set of reactions included a sterile water negative control, and the PCR products were analyzed with 1.5% agarose-ethidium bromide. An aliquot of each nested amplified product was digested with *TaqI* according to the recommendations of the supplier (New England Biolabs, Beverly, Mass.); a second aliquot was used as a template for cyclic, automatic sequencing with 5'-labelled fluorescein primer CSBH1, the Autoread kit (Pharmacia Biotech, Uppsala, Sweden), and the ALF DNA sequencer (Pharmacia).

Serologic studies. The patient's serum samples and one serum sample for the patient's cat and kitten were tested against two *B. quintana* Oklahoma antigen preparations. In one preparation, the bacteria were grown on 5% sheep blood agar and resuspended in formaldehyde. In the other preparation, the bacteria were propagated on the ECV 304 cell line, purified by low-speed centrifugation of the cell culture supernatant, and resuspended in formaldehyde. Also, the patient's serum specimens were tested against the patient's isolate grown on

* Corresponding author. Mailing address: Unité des Rickettsies, Faculté de Médecine, Centre National de La Recherche Scientifique, 27, Boulevard Jean Moulin, 13385 Marseille Cedex 05, France.

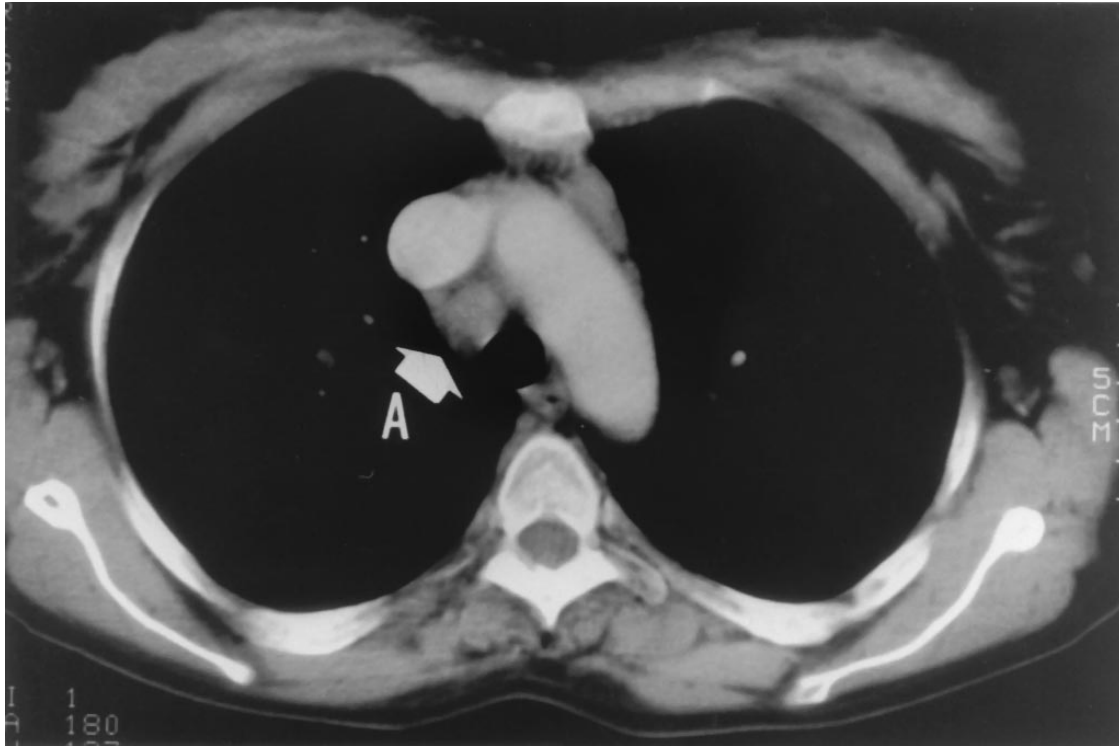

FIG. 1. Computerized tomography scan of the patient's chest showing mediastinal adenomegalies (A [arrow]).

sheep blood agar and in endothelial cells. Specific antibodies were detected against these four antigens by a microimmunofluorescence technique as previously described (6). Antibody estimations with *B. henselae* and *Afpia felis* were also performed, as previously reported (9).

RESULTS

Isolation and culture of the isolate. A *Bartonella*-like strain was isolated from the bone marrow biopsy after 14 days of cocultivation with endothelial cells. The isolate was subsequently subcultured onto sheep blood agar and into endothelial cells. Cultures inoculated with the blood sample and the bone marrow aspirate remained sterile. The isolate was a gram-negative bacillus, tests for the oxidase and catalase were negative, and the isolate reacted with a mouse polyclonal antibody specific for *B. quintana*. The entire 16S rRNA gene sequence of this isolate was identical to that reported for *B. quintana* Fuller in GenBank (accession number L01259).

Molecular detection of *Bartonella* DNA in clinical material. PCR products derived from amplification of *gltA* gene fragments were obtained from a serum sample drawn at the time of the patient's admission, from the mediastinal adenopathy biopsy, and from the isolate of *B. quintana*. Sequence analysis of these amplicons demonstrated that all were identical to each other and to the sequence previously reported for *B. quintana* (2).

Serologic studies. Four serum samples were collected, respectively, at the time of admission and at 4 weeks, 6 weeks, and 7.5 months after admission. No sample exhibited immunoglobulin G or immunoglobulin M antibodies specific for *B. quintana* Fuller, the patient's isolate, *B. henselae*, or *A. felis*. One serum sample from the patient's kitten was also nonreactive; however, the adult cat's serum exhibited an antibody titer of 1:50 against *B. quintana* and *B. henselae*.

DISCUSSION

The clinical spectrum of *B. quintana* infection currently includes trench fever (13, 14), endocarditis and bacteremia among homeless and alcoholic patients (1, 11), and bacillary angiomatosis (4). We previously described one patient with *B. quintana* chronic peripheral adenomegaly (8) and report here on a second patient with mediastinal adenomegaly. Salient features of both observations include middle-aged female patients, close contact with a kitten or cats, chronic adenopathy due to granulomatous inflammation without caseation, lymphopenia, bone marrow involvement, isolation of *B. quintana* from blood or bone marrow, lack of *B. quintana*-specific antibodies, and successful treatment with aminoglycosides. We have used microimmunofluorescence for 30 months with a seroprevalence of 0.6% among 21,000 serum samples and have detected high antibody titers in patients with *B. quintana* endocarditis (1). We cannot explain the lack of specific antibody in our patients with chronic adenomegaly, even though systemic infection was confirmed in both patients. In the patient reported herein, either treatment with steroids or debility due to chronic renal failure may have played a role. There is at present no consensus regarding the optimum antibiotic treatment of *Bartonella* infections, but a review of published cases and experimental data (5, 7) allows us to propose 10 days of treatment with gentamicin as an alternative to tetracyclines and prolonged treatment with macrolides. Finally, whereas the epidemiology of trench fever implies interhuman transmission via the body louse, it is remarkable that both patients in this report lived in "normal" hygienic conditions and had no evidence of infestation by body lice. Both, however, had close contact with cats, including a flea-infested kitten in one case. Cats and kittens are the reservoirs for *B. henselae* in the United

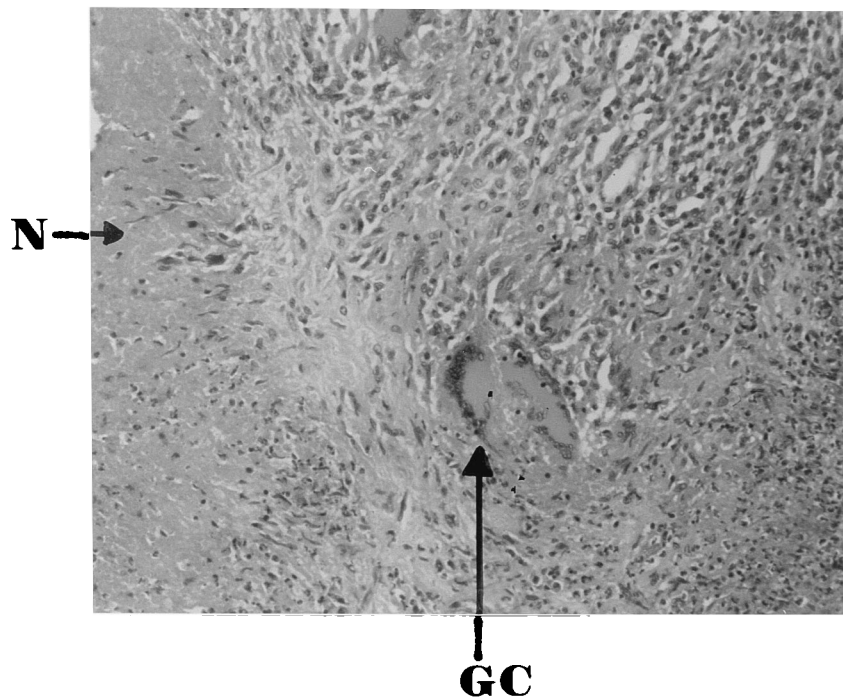


FIG. 2. Photomicrograph of the mediastinal adenomegaly showing granulomatous inflammation with Langhans' type giant cells (GC) and necrotic zones (N).

States (3), but there is no such evidence for *B. quintana* in France.

ACKNOWLEDGMENTS

This work was made possible by the Programme Hospitalier de Recherche Clinique, Assistance Publique à Marseille, 1993.

We acknowledge M. J. Payan for histologic examination of the clinical materials and R. Birtles for review of the manuscript.

REFERENCES

- Drancourt, M., J. L. Mainardi, P. Brouqui, F. Vandenesch, A. Carta, F. Lehnert, J. Etienne, F. Goldstein, J. Acar, and D. Raoult. 1995. *Bartonella (Rochalimaea) quintana* endocarditis in three homeless men. *N. Engl. J. Med.* **332**:419–423.
- Joblet, C., V. Roux, M. Drancourt, J. Gouvernet, and D. Raoult. 1995. Identification of *Bartonella (Rochalimaea)* species among fastidious gram-negative bacteria on the basis of the partial sequence of the citrate-synthase gene. *J. Clin. Microbiol.* **33**:1879–1883.
- Koehler, J. E., C. A. Glaser, and J. W. Tappero. 1994. *Rochalimaea henselae* infection: a new zoonosis with the domestic cat as reservoir. *JAMA* **271**:531–535.
- Koehler, J. E., F. D. Quinn, T. G. Berger, P. E. LeBoit, and J. W. Tappero. 1992. Isolation of *Rochalimaea* species from cutaneous and osseous lesions of bacillary angiomatosis. *N. Engl. J. Med.* **327**:1625–1631.
- Maurin, M., S. Gasquet, C. Ducco, and D. Raoult. 1995. MICs of 28 antibiotic compounds for 14 *Bartonella* (formerly *Rochalimaea*) isolates. *Antimicrob. Agents Chemother.* **39**:2387–2391.
- Maurin, M., V. Roux, A. Stein, F. Ferrier, R. Viraben, and D. Raoult. 1994. Isolation and characterization by immunofluorescence, sodium dodecyl sulfate-polyacrylamide gel electrophoresis, Western blot, restriction fragment length polymorphism-PCR, 16S rRNA gene sequencing, and pulsed-field gel electrophoresis of *Rochalimaea quintana* from a patient with bacillary angiomatosis. *J. Clin. Microbiol.* **32**:1166–1171.
- Musso, D., M. Drancourt, and D. Raoult. 1995. Lack of bactericidal effect of antibiotics except aminoglycosides on *Bartonella (Rochalimaea) henselae*. *J. Antimicrob. Chemother.* **36**:101–108.
- Raoult, D., M. Drancourt, A. Carta, and J. A. Gastaut. 1994. *Bartonella (Rochalimaea) quintana* isolation in patient with chronic adenopathy, lymphopenia, and a cat. *Lancet* **343**:977.
- Raoult, D., H. Tissot Dupont, and M. Enea-Mutilod. 1994. Positive predictive value of *Rochalimaea henselae* antibodies in the diagnosis of cat scratch disease (CSD). *Clin. Infect. Dis.* **19**:355.
- Regnery, R. L., B. E. Anderson, J. E. Clarridge III, M. C. Rodriguez-Barradas, D. C. Jones, and J. H. Carr. 1992. Characterization of a novel *Rochalimaea* species, *R. henselae* sp. nov., isolated from blood of a febrile, human immunodeficiency virus-positive patient. *J. Clin. Microbiol.* **30**:265–274.
- Spach, D. H., A. S. Kanter, M. J. Dougherty, A. M. Larson, M. B. Coyle, D. J. Brenner, B. Swaminathan, G. M. Matar, D. F. Welch, R. K. Root, and W. F. Stamm. 1995. *Bartonella (Rochalimaea) quintana* bacteremia in inner-city patients with chronic alcoholism. *N. Engl. J. Med.* **332**:424–428.
- Stein, A., and D. Raoult. 1992. A simple method for amplification of DNA from paraffin-embedded tissues. *Nucleic Acids Res.* **20**:5237–5238.
- Stein, A., and D. Raoult. 1995. Return of trench fever. *Lancet* **345**:450–451.
- Vinson, J. W. 1966. In vitro cultivation of the rickettsial agent of trench fever. *Bull. W. H. O.* **35**:155–164.
- Wong, M. T., M. J. Dolan, and C. P. Lattuada, Jr., et al. 1995. Neuroretinitis, aseptic meningitis, and lymphadenitis associated with *Bartonella (Rochalimaea) henselae* infection in immunocompetent patients and patients infected with human immunodeficiency virus type 1. *Clin. Infect. Dis.* **21**:352–360.