

## Kidney and Liver Transplants from a Donor Infected with *Naegleria fowleri*

M. H. KRAMER,<sup>1,2</sup> C. J. LERNER,<sup>3</sup> AND G. S. VISVESVARA<sup>2\*</sup>

Epidemic Intelligence Service, Epidemiology Program Office,<sup>1</sup> and Division of Parasitic Diseases, National Center for Infectious Diseases,<sup>2</sup> Centers for Disease Control and Prevention, Public Health Service, U.S. Department of Health and Human Services, Atlanta, Georgia 30341, and San Antonio Infectious Diseases Consultants, San Antonio, Texas 78229<sup>3</sup>

Received 12 November 1996/Returned for modification 13 December 1996/Accepted 14 January 1997

**We describe the first reported case of organ transplantation from a boy who had died of undiagnosed *Naegleria fowleri* infection. While no subsequent amebic infections occurred in the three organ recipients, our report illustrates the need for an improved strategy for evaluating the benefits and risks of transplanting tissues from persons whose illness was likely caused by an infectious agent.**

*Naegleria fowleri*, a small, free-living amoeboid flagellate, enters the nasal cavity by aspiration of water or inhalation of dust contaminated with trophozoites or cysts. It can invade the central nervous system via the olfactory neuroepithelium and cause the rare but usually fatal primary amebic meningoencephalitis, which clinically resembles acute bacterial meningitis (3). We describe here the first reported case of organ transplantation from a boy who had died of undiagnosed *N. fowleri* infection.

**Case report.** In July 1995, a previously healthy 11-year-old boy was admitted with a 3-day history of mild abdominal pain and mild headache and a 36-h history of nausea, vomiting, fever, and malaise. He was febrile (39.4°C) and lethargic without focal neurologic or meningeal signs; the respiratory rate was 36 breaths per min. His hemoglobin level was 13.8 g/dl, and his leukocyte count was  $22.4 \times 10^9$ /liter, with 86% neutrophils and 2% band forms. The cerebrospinal fluid was cloudy and contained  $3,930 \times 10^6$  leukocytes per liter (95% neutrophils),  $1,480 \times 10^6$  erythrocytes per liter, 0.8 mmol of

glucose per liter, and 837 mg of protein per dl; no microorganisms were seen on Gram stains. A chest radiograph was normal.

Ceftriaxone therapy was started for suspected bacterial meningitis, but the boy's condition rapidly deteriorated with increasing headache and obtundation. A ventriculostomy was performed to control increased intracranial pressure. Subsequently, he developed diabetes insipidus and died 34 h after admission; nuchal rigidity was never observed. His kidneys and liver were donated and transplanted the next morning. An autopsy was not performed.

On the following day, a newspaper report of a fatal case of primary amebic meningoencephalitis in another person prompted reexamination of the Gram stains from the boy's cerebrospinal fluid, and ameboid structures resembling jagged macrophages were found. The diagnosis of primary amebic meningoencephalitis was confirmed when cerebrospinal fluid tested positive for *N. fowleri* by trichrome and Giemsa staining (Fig. 1) and immunofluorescence staining with monoclonal antibody

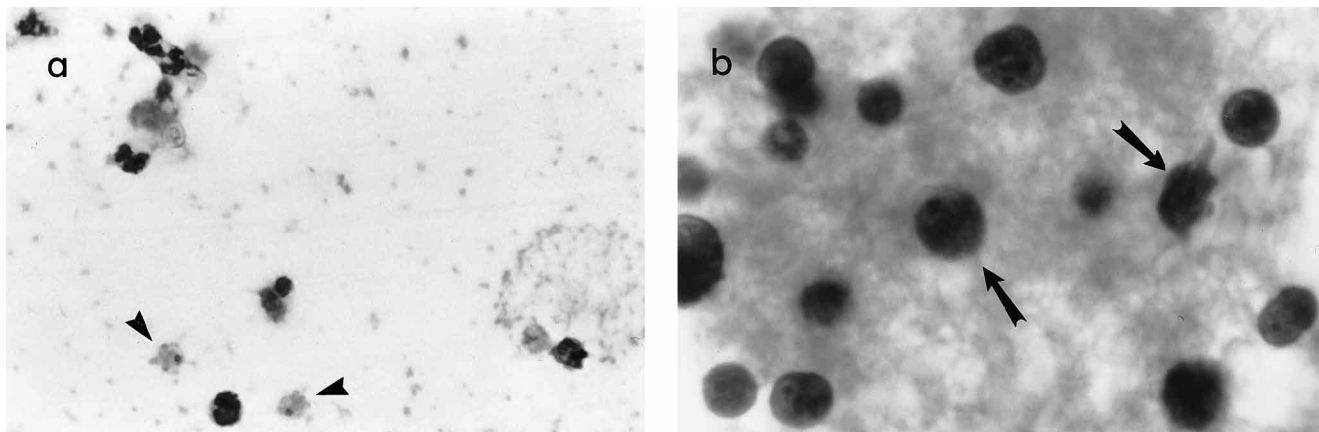


FIG. 1. Trophozoites (arrowheads and arrows) of *N. fowleri* from cerebrospinal fluid. (a) Giemsa stained; original magnification,  $\times 600$ . (b) Trichrome stained; original magnification,  $\times 1,250$ . Note the characteristic nuclear morphology of the trophozoites; pseudopodia (right trophozoite in panel b) are rarely seen in fixed smears. *N. fowleri* may be confused with degenerated leukocytes.

\* Corresponding author. Mailing address: CDC-DPD, MS F-13, 4770 Buford Hwy, NE, Atlanta, GA 30341. Phone: (770) 488-4417. Fax: (770) 488-4253.

IV-DI-30 (6). During the summer, the boy had frequently played near a small freshwater pond in his hometown in southeastern Texas; however, contact with pond water in the 2 weeks before his illness could not be confirmed.

None of the organ recipients, two adults and a school-aged child, received prophylactic antiamebic treatment. During the next 6 months, none of them showed signs of amebic infection and the transplanted organs functioned well. Lumbar puncture was not performed in any of the organ recipients.

**Discussion.** Treatment options for primary amebic meningoencephalitis are limited and include amphotericin B, miconazole, and rifampin (5). Hematogenous spread of *N. fowleri* to other organs is exceptional (in contrast to *Acanthamoeba* spp., which cause granulomatous amebic encephalitis after spreading hematogenously into the central nervous system from a primary focus, e.g., lung, skin, or uterus [3]). Therefore, no prophylactic treatment was given to the three transplant recipients. Of note, the Centers for Disease Control and Prevention are aware of another instance in which kidneys were transplanted before *N. fowleri* infection of the donor was determined (1).

The risk of transmission of *N. fowleri* by donor organs is unknown. Although most infections with *N. fowleri* appear to be confined to the central nervous system, one disseminated infection has been documented (2, 4). Presently, no practical

test is available to ensure that donor organs are free from amebae, and no prophylactic drug regimen to treat transplant recipients has been established. While no subsequent infections occurred in the recipients in this instance, our report illustrates the need for an improved strategy for evaluating the benefits and risks of transplanting tissues from persons whose illness was likely caused by an infectious agent.

We thank George A. Bannayan (Womens and Childrens Hospital, San Antonio, Tex.) and Sara V. Wallace (Centers for Disease Control and Prevention, Atlanta, Ga.) for laboratory support.

#### REFERENCES

1. Centers for Disease Control and Prevention. Unpublished data.
2. Derrick, E. H. 1948. A fatal case of generalized amoebiasis due to a protozoon closely resembling, if not identical with, *Iodamoeba butschlii*. Trans. R. Soc. Trop. Med. Hyg. 42:191-198.
3. Ma, P., G. S. Visvesvara, A. J. Martinez, F. H. Theodore, P. M. Daggett, and T. K. Sawyer. 1990. *Naegleria* and *Acanthamoeba* infections: review. Rev. Infect. Dis. 12:490-513.
4. McMillan, B. 1977. Diagnostic review of Derrick's case of generalized amoebiasis (? *Iodamoeba butschlii*). Pathology 9:76.
5. Seidel, J. S., P. Harmatz, G. S. Visvesvara, A. Cohen, J. Edwards, and J. Turner. 1982. Successful treatment of primary amebic meningoencephalitis. N. Engl. J. Med. 306:346-348.
6. Visvesvara, G. S., M. J. Peralta, F. H. Brandt, M. Wilson, C. Aloisio, and E. Franko. 1987. Production of monoclonal antibodies to *Naegleria fowleri*, agent of primary amebic meningoencephalitis. J. Clin. Microbiol. 25:1629-1634.