

**IMMEDIATE RECONSTRUCTION OF THE MANDIBLE BY
METALLIC IMPLANT FOLLOWING RESECTION
FOR NEOPLASM**

Hunterian Lecture delivered at the Royal College of Surgeons of England

on

12th May 1967

by

H. P. Cook, F.D.S.R.C.S.

Consultant Dental Surgeon, Royal Dental Hospital and Middlesex Hospital

THE REPLACEMENT OF natural tissues damaged by disease or trauma by means of foreign materials has been attempted by surgeons for many years, if not centuries. Many materials have been implanted, including gold, silver, tantalum, stainless steels of various composition, and acrylic resin, to name but a few. Failure has occurred after their use because of tissue irritation, metal corrosion, mechanical failure of the implant, infection, or extrusion following inadequate fixation.

The implantation of heterograft material interested John Hunter, and his attempts at implanting human teeth into the comb of the cock are well known. It is interesting to note that he chose a very vascular tissue as the recipient area, and in at least one of the Hunterian pathological specimens, the human canine tooth selected for implantation showed an incompletely formed apex. He appreciated that the larger apical foramen permitted a much greater chance of revascularization of the transplanted pulpal tissue.

Probably no one would disagree that the use of an implant implied that no suitable technique of replacement by a graft of human tissue was available or appropriate. In sites of anatomical complexity, such as the joints of the locomotor system, the use of a prefabricated implant to replace damaged articulating surfaces can produce a functional result which would be impossible otherwise. As would be expected from this, metallic implants have been most extensively used in orthopaedic surgery. The problem has been to discover a strong enough non-irritant material which can be adequately fixed to the bone and which remains tolerated by the body tissues indefinitely.

Cobalt chrome molybdenum alloy first appeared in the 1930s and became extensively used in orthopaedic surgery in the United States under the trade name of Vitallium. Currency restrictions prevented its use in this country until recent years, when a British product of the same composition was produced under the name of Vinertia. By this time cobalt chrome molybdenum alloy was firmly established by American orthopaedic surgeons, and in 1941 Venable and Stuck published a paper based on three years' experience with Vitallium. They asserted that the material was more inert in the tissues than any previous metal used and found that its strength and passivity perfectly suited it for the requirements of bone

surgery. Other workers in the field have confirmed their view and by 1956 Scales was able to write that he knew of no case in which an orthopaedic implant of cobalt chrome molybdenum had failed because of corrosion.

With a proved material available it was not long before attempts were made to replace resected segments of mandible using implants of the alloy, either alone or together with other material. Examination of the literature revealed that in many of the cases reported failure of the implant occurred after a short period of time for one reason or another. In some cases no follow-up assessment was included in the description.

McQuillan *et al.* (1945) described a single case of ameloblastoma treated by resection and replacement by cobalt chrome implant fixed by screws. This remained in position for one year. Replacement by means of a Tantalum implant following removal of a squamous carcinoma was reported by Bellinger (1947). Fixation was by means of wires, but no follow-up was mentioned.

Freeman (1948) reported two cases of squamous carcinoma and one sarcoma, which were treated after resection by replacement implants consisting of cobalt chrome fracture plates. Fixation was by means of wires and bolts, but no follow-up was mentioned. A number of benign tumours were described in a paper by Byars (1948) as being replaced after superperiosteal resections by means of stainless steel bars. The ends of these bars were impacted into the medullary portions of the remaining bone fragments to stabilize them, but again no follow-up assessment was given.

In two papers (1951 and 1954) one of the best results achieved was described by Castigliano. An anaplastic neoplasm was resected after a full course of radiotherapy, and replaced by a cobalt chrome implant fixed by means of screws. This implant functioned well for a period of five years.

One of the leading exponents in reconstructive surgery by cobalt chrome implants, Conley, published his first report on the subject in 1951. This described 10 cases in which the method was used, but no follow-up period was discussed. It is of interest that the implants used were of Conley's own design and until recently remained the only commercially available jaw implants. This author made the important observation that he did not consider the method a substitute for orthodox bone grafting. In his second paper of 1956 he reiterated this view and suggested that implants might be most useful in situations where a bone graft was inadmissible on account of the risk of infection.

Another advocate of metallic implants was Kleitsch (1951, 1952), who actually considered cobalt chrome reconstruction of the mandible preferable to bone grafting. He reported a case of ameloblastoma of the mandible treated by resection and replacement by an implant at a second operation. This initially failed and was removed to be replaced later by

IMMEDIATE RECONSTRUCTION OF THE MANDIBLE BY METALLIC IMPLANT

a second implant. In the 1952 publication a satisfactory two-year result was described.

Walsh (1954) described a series of eight cases of squamous carcinoma in which resected portions of mandible were replaced using bars of Ticonium, a cobalt chrome alloy containing 1.2 per cent beryllium. The bar was fixed to the cut bone ends by medullary impaction only. Except in one case recurrent disease appeared within one year to six months, making assessment of the technique difficult.

Replacement prostheses composed of acrylic resin have been described by Niebel *et al.* (1954) and Healey *et al.* (1954). Fixation in eight cases was by means of medullary impaction. Most of the appliances were removed in less than eight months, but in one case a successful follow-up of 16 months was achieved. Acrylic resin has obvious attractions as an implant material as it is easy to shape and fabricate. Unfortunately it also

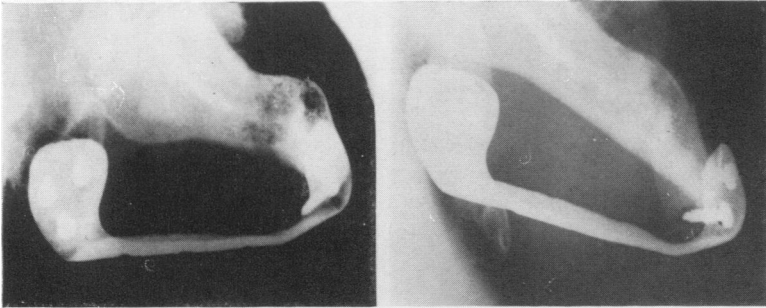


Fig. 1. Radiographs. Lateral oblique of mandible. Appearance immediately post-operative compared with appearance 17 months post-operative. Shows bone resorption around screws and loosening of appliance.

suffers from serious drawbacks. Fracture under load is likely, surface crazing is very common, and there is strong experimental evidence that the material is chemically irritant to the tissues. Polymer degradation is also known to occur.

A single case of ameloblastoma replaced by an acrylic prosthesis after resection was reported by Miglani (1961). A satisfactory follow-up after a period of one year was described. Another large series of 72 cases was reported by Nagao (1962). All were treated by hemimandibulectomy, and in 40 cases the replacement resin prosthesis was removed three months or less after insertion. Results obtained with cobalt chrome implants were slightly better, although an immediate failure rate of 20 per cent was given. The longest follow-up was over three years; also two cases were satisfactory over two years and four cases over one year.

Five cases of ameloblastoma of the mandible were reported by Genest (1956). These had been treated by resection and replacement by cobalt chrome implant. Fixation was described as being by means of screws, and

satisfactory follow-up periods varying from four years to two years were described.

Dewey and Moore (1962) described concurrently with Cook (1962) the method of fixation by means of bolts. All other methods for fixation of implants to the bone were rejected. Four patients were described fully in whom alveolar carcinomas were treated by excision and immediately reconstructed with cobalt chrome implants. Successful follow-up varied from eight years to one year.

Analysis of published reports allows certain conclusions to be drawn, which have been confirmed by personal experience. Mechanical fixation by means of any method other than bolting cannot be expected to allow good long-term results. Medullary impaction, wiring or fixation by screws alone are insufficient to fix implants firmly to bone for periods longer than a few months. Loosening, followed by extrusion, is likely to occur rapidly. There is no analogy between the fixation of mandibular implants and the Austin Moore type of hip prosthesis in which the load impacts the medullary nail more firmly into the femoral medulla (Fig. 1).

Materials such as stainless steel and acrylic resin could not be expected to give good long-term results because of their unsuitable physical properties. The mixing of metals and alloys with different composition as implants and fixation components produces a great risk of corrosion from electrolytic action. Recent work, however, by Down (1966) suggests that it may be safe to use titanium metal together with cobalt chrome molybdenum. The experimental electro-couple between these two metals produced a galvanic current $0.12 \mu\text{A}/3 \text{ cm.}^2$ over a period of 20 days. This was considered to be so small as to be a negligible factor in the production of electrolytic corrosion. Earlier work by Gross and Gold (1957) also suggested that titanium and cobalt chrome could be used with safety in combination. Experimental contiguous implantation of these metals in dogs resulted in no histological evidence of damage to either soft tissues or bone.

Although the authors of many of the papers analysed used metallic implants to replace benign lesions, it is felt that the method should usually be reserved for the surgical treatment of malignant conditions. In this circumstance the advantage of immediate reconstruction during the same operation as that carried out for ablation is most manifestly appreciated.

The desirable qualities for foreign materials implanted into the body have been well summarized by Scales (1958); to date cobalt chrome molybdenum appears to fulfil these conditions most adequately.

Chemical inertness

Cobalt chrome alloy when buried in the tissues has not been found to give rise to chemical irritation. It does not depend for its corrosion resistance upon a coherent surface layer of chromium oxide as is the case with stainless steels. During the last few years the element titanium has

IMMEDIATE RECONSTRUCTION OF THE MANDIBLE BY METALLIC IMPLANT

also been used as an implant metal. This does appear to depend for inertness upon an intact surface layer of titanium oxide.

Although there is no direct evidence that cobalt chrome implants are modified by adjacent tissues there is some evidence that the ionic concentration of cobalt and chromium is increased at such sites. This occurs in the absence of corrosion probably by means of ion migration. Using a spectro-chemical method of analysis Ferguson *et al.* (1962) demonstrated in rabbits that the embedding of metal implants in the tissues resulted in an increase of cobalt ions in the kidney, the spleen and the adjacent muscle. The phenomenon probably occurs in human subjects also but has not given rise to any clinical difficulty.

After removal of cobalt chrome implants the tissues adjacent appear unaltered from normal, and the appliance itself is clean and free from surface change, appearing no different from a brand new item. Titanium implants also appear unchanged after removal but the adjacent tissues often show blackening due to titanium oxide deposit. This does not appear to exert any harmful effect.

Electrolytic action

It has been thought for at least a decade that instruments used for insertion of the screws or nuts used to fix an implant should be of the identical alloy to the screws or nuts. This idea was based on work by Bowden *et al.* (1955), who demonstrated using radio-active isotopes that metal transference took place from instrument to bolt or screw by "slip" during tightening. An electrical potential was then set up between the dissimilar adherent metal particles and the bolt, and a small galvanic current was produced. This was thought to be capable of producing bone absorption. However, it appears in practice that the actual amount of metal transferred is so small that it disappears in solution in the tissues and never gives rise to electrolytic corrosion (Scales, 1966).

It also appears to be possible to implant mixed cobalt chrome plates or screws with titanium components without corrosion resulting. This is because the resulting back E.M.F. produced is above the level of 650 mV., this being the observed level above which corrosion does not occur. It is not safe, however, to mix stainless steel components with other metals.

Inflammatory reactions

Clinical results in orthopaedic surgery observed over the last 15 years have failed to demonstrate any inflammatory or foreign body reactions to cobalt chrome implants. In the case of mandibular resections the surgery required inevitably opens the tissues into the infected mouth cavity. Provided the mucosa and skin flaps are carefully closed over the implant clinical evidence of infection should not appear. A post-operative course of suitable antibiotic is prescribed to assist in preventing this complication.

Fabrication

Implants of cobalt chrome are made by casting using the “lost wax” method. A wax pattern is made of the correct shape and dimensions and then invested in a suitable investment. The implant is then cast by pouring molten alloy into the mould left by the evaporated wax so that the pattern is replaced by a metal casting.

Cobalt chrome is a very hard alloy which is difficult to machine although turning and cutting can be carried out on an industrial scale. There is also limitation upon the size of the casting which can be produced in a domestic dental laboratory because of the size of furnace and casting ring required. An induction method of melting the alloy is also essential to minimize carbonization and risk of casting defects.

Titanium is much easier to work than cobalt chrome and can be cut into shapes from sheeting. It is also susceptible to forging and turning but cannot be cast under ordinary laboratory conditions. Its greater ease of fabrication and its inertness when implanted in the tissues make it an attractive material for some implants. Unfortunately it cannot be used in situations requiring a metal-to-metal bearing, as contacting surfaces tend to seize. Its resistance to wear is also very much less than that of cobalt chrome alloy, as demonstrated by Scales *et al.* (1966).

Composition of Vitallium—synonym Vinertia—is given by Skinner and Phillips (1960).

	<i>Per cent</i>			
Chromium				30.5
Molybdenum				5.1
Tungsten	}			1.9
Iron				
Manganese				
Silicon				
Carbon				
Aluminium				
Cobalt				62.5

A wrought alloy has been produced in which the molybdenum content is replaced by nickel and tungsten, and is known as alloy WR 125. The composition of this alloy is:

	<i>Per cent</i>			
Chromium				19.5
Molybdenum				—
Nickel				10.0
Carbon				0.1
Silicon				1.0
Iron				2.0 max.
Tungsten				15.0
Cobalt				52.4

Indications for mandibular implants

The removal of segments or large portions of the mandible is necessary in the treatment of benign and malignant neoplasms involving the bone. Reconstruction usually in stages by bone grafting to replace the lost tissue

IMMEDIATE RECONSTRUCTION OF THE MANDIBLE BY METALLIC IMPLANT

has been successfully carried out for many years with excellent results in a large proportion of cases. Immediate reconstruction using a metallic implant provides a reasonable alternative when resection of a malignant neoplasm is carried out.

Reconstruction by bone grafting immediately following such a resection has not been widely practised because of the risk of losing such grafts either from infection or from infiltration by rapidly recurring neoplasm. An interval of approximately two years' freedom from disease is usually awaited before embarking on reconstruction.

Removal of a portion of the mandible which is not replaced at the same operation results in deformity of the lower portion of the face, impairment of the functions of chewing and swallowing, and difficulty in speech. The remaining unsupported portions of the mandible are pulled by muscle forces into abnormal positions, and as healing proceeds subsequent fibrosis may prevent their adequate repositioning when the time comes for reconstruction. These difficulties can be prevented if at the time of curative surgery it is possible to insert a metallic implant to bridge the gap between the bone ends.

Reconstruction by metallic implant is considered justifiable in those cases of malignant disease of the mandible in which it is anticipated that after proper surgical clearance of the disease sufficient normal tissue will remain to permit a sound and adequate closure over the implant. It is necessary, as always when treating malignant disease, not to be over-influenced by thoughts of reconstruction when planning radical surgery for its removal. Cure of the disease is the primary consideration and feasibility of replacement must be viewed in proper perspective.

If immediate reconstruction by implant is possible the gain by the patient is very considerable. Function is very little impaired as a functioning mandible is retained and as a result speech and mastication are affected to the minimum. The aesthetic result is immeasurably improved as the facial contour and symmetry are altered to the minimal extent. In many cases it is possible at a later date to fit a small dental prosthesis to replace the anterior teeth and hold forward the lower lip. These appliances are necessarily tooth borne, as it is unsafe to place dentures over tissue covering a buried implant. Any compression of such tissue by transmitted biting forces causes rapid breakdown of the soft tissue and exposure of the implant. It can be fairly argued that this is a notable disadvantage of implants in comparison with bone grafts.

Immediate insertion of an implant which is correctly attached provides a stable reconstruction which obviates in some cases the necessity for the re-opening of the tissues at a later date. Even if the implant should require removal after a period of time, nothing will have been lost. The mandibular fragments and the soft tissues will have been maintained in their correct anatomical positions, thus making further reconstruction easier and

more satisfactory. In several cases of this series the implants have been removed and replaced by bone grafts which have produced good results.

It is rarely possible to prognosticate with certainty concerning the behaviour of an individual neoplasm. It does not seem reasonable to argue with hindsight that if any individual tumour responds well to treatment an implant has therefore been unnecessary. It would seem precisely in the case of neoplasms of doubtful prognosis that an immediate implant has the most to offer.

Irradiation therapy

Implant reconstruction in tissues treated previously with gamma or X-rays has been considered unlikely to succeed by some surgeons. Conley (1951) was of this opinion certainly in relation to X-rays derived from a 250-kV. source. The resulting vascular damage in the treated area severely impairs tissue healing following surgery so that healing, especially on the mucosal surface, may fail altogether. This outcome is likely to be increased if diathermy is used extensively during the dissection.

Many mouth neoplasms are treated by a combination of pre-operative radiotherapy and later elective surgery as the method of choice. The likely success of immediate reconstruction will be very much influenced by the type of energy source employed in the irradiation therapy. The size and positioning of the individual fields and the dose distribution in the calculated volume of tissue treated must be accurately known.

The most successful results in this series have been obtained in patients who have not received irradiation as part of their treatment. This is not unexpected. In two patients the lesions were initially treated with a 15-curie telecobalt source by means of two small angled fields. In these cases subsequent surgery, including implant replacement, was successfully completed, there being no especial difficulty with healing. Examination of the isodose curves on the treatment plans reveals a high dose rate to the actual tumour and adjacent tissues on the 80 to 90 per cent curve. Thereafter the fall-off in dose rate is fairly rapid so that the skin and subcutaneous tissues receive only 70 per cent of the dose delivered, the actual dose being probably somewhat less for physical reasons. The blood supply to the outlying skin and connective tissue was not damaged to the same degree and healing after surgery was therefore satisfactory.

In other cases treatment was initially from a 1,000-curie source by means of two wedge fields at right angles to each other. The isodose curves show that as well as the tumour a large volume of tissue, including the overlying skin, has been treated to the 90 per cent dose level. For physical reasons the dose delivered is probably slightly higher. A large volume of tissue is therefore treated very homogeneously and all the blood vessels in the area are affected by endarteritis. The use of pairs of opposing fields may produce a similar effect.

IMMEDIATE RECONSTRUCTION OF THE MANDIBLE BY METALLIC IMPLANT

From the pure radiotherapy technique point of view treatments using wedge fields would be considered superior to their therapeutic effect to that achieved by small direct telecobalt fields for the reasons stated. However, should the therapy fail completely to control the neoplasm, as is often the case, surgery must be resorted to. This possibility ought not to

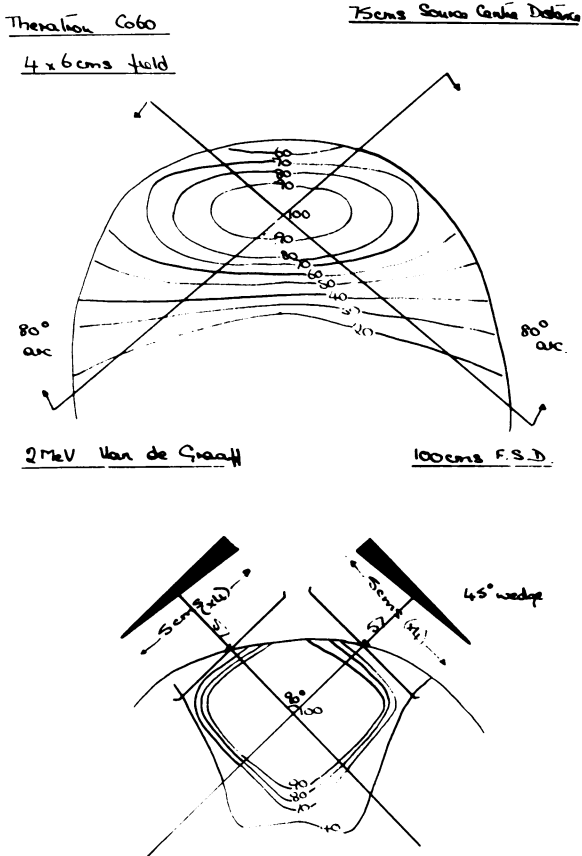


Fig. 2. Specimen radiotherapy plans. Comparison of isodose curves distribution in treatment by two wedge fields and arc rotation fields. Note tissue sparing effect on normal tissues with arc rotation.

be lost sight of when the case is being planned for treatment, especially if the affected site is known to have an unsatisfactory prognosis in terms of five-year survival. If the possibility of surgery is anticipated, the radiotherapy should be planned in such a way as to damage the blood supply of the normal tissue as little as possible. This can in many cases be achieved by means of arc rotation fields in which the source rotates through several fixed arcs. At the centre of these arcs, which is coincident with the situation of the tumour, there is a summation effect of the dose, but the

skin and overlying tissues receive only a part of the dose delivered to the tumour. The isodose curves of such a treatment plan show the tumour receiving 90 to 100 per cent of the dose delivered, whilst the skin and connective tissues receive 60 to 70 per cent of the dose. These tissues will therefore heal better after any subsequent surgery, whilst at the same time a technically very efficient form of therapy has been given (Fig. 2).

Construction of implants

In cases where a portion of the mandible only has been resected it has been possible to use as replacement an implant constructed using the patient's measurements and radiographs. Where hemimandibular replacement has been necessary, this has been achieved by the use of a stock appliance supplied in one size only. This fact allows only the very minimum of adjustment and it was for this reason that an attempt was made to produce a modified appliance. The large size of this implant has usually precluded its production in the domestic dental laboratory, and the lengthy delay which would be encountered in obtaining a bespoke appliance for each patient is not acceptable. The solution to the difficulty appeared to be either to produce an appliance of adjustable dimensions or one of components of variable size which could be assembled at the time of operation. The latter alternative has proved the most practical.

Mid-portion and body replacement

Replacement of the mid-portion and horizontal ramus has been carried out by implants produced in the dental laboratory. Measurements of the patient's lower jaw are taken pre-operatively with calipers, allowance being made for the thickness of the soft tissues. These values give a rough indication of the size of dried mandible to be selected. The patient is then radiographed using cephalostatic lateral, occlusal and sub-mento vertex views, using a target distance to give the minimum of image magnification. Identical views are taken of the dried specimen, and tracings from both sets of films are superimposed upon each other to verify that the dimensions of the natural and the dried mandible correspond. A duplicate model of the dried mandible is made in plaster from an alginate impression, and this model is used for construction of the implant.

The lines of section are marked on the model, and an implant made to replace this area which represents the segment of bone to be removed at operation. This implant consists of a bar, U-shaped in section, arranged to bridge the defect and joined at each end to a flat attachment plate containing two bolt holes for fixation. These allow attachment of the implant to the lateral aspects of the bone fragments.

In this way a sufficiently accurate implant is made and any minor discrepancy in size can be compensated for by adjusting the position of the attachment plates by sliding them on the bone fragments at operation. Sharp angles between the various parts of the casting must be avoided as

IMMEDIATE RECONSTRUCTION OF THE MANDIBLE BY METALLIC IMPLANT

they form points of mechanical weakness when the implant is under load. Metal fatigue develops easily at such points and encourages fractures to occur. Perforating holes are provided in the bar to allow the sewing of residual muscles and soft tissue to it.

Laboratory produced implants must be examined for casting faults before insertion into the body. This is done by radiographing the implant in various positions so that any defect will be seen as a linear shadow on the film. A dye penetrant ink should also be used to expose any faults in the surface quality of the implant. In spite of these precautions fracture did occur in one laboratory produced implant.

The same method has been used in the fabrication of the small replacement implants used in the experimental work on Rhesus monkeys.

Attempts are also being made to produce a range of stock implants which can be purchased from instrument suppliers. These are designed on

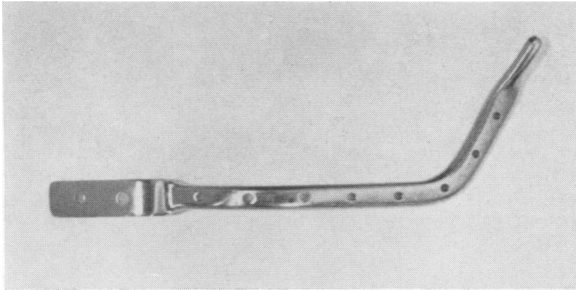


Fig. 3. Prototype of hemimandibular replacement implant in titanium.

the same basic pattern, but produced in titanium 130 to allow some moulding to individual requirements at the time of operation.

Hemimandibular replacement

In most instances it is not possible to make a "bespoke" implant for each patient for technical reasons, and the delay attendant on production. In many cases a stock hemimandibular implant made in only one size has been inserted. This has often proved difficult as the size of the mandible in individual patients varies considerably.

The stock appliance referred to was designed by J. J. Conley. The only possible adjustment with this appliance is obtained by sliding the attachment plate on the surface of the bone until it occupies the optimum position for that patient. Even this degree of flexibility cannot be obtained unless the posterior plate of the parallel-sided U-shaped fork is cut off using a diamond disc. The natural curves of the bone surfaces have prevented satisfactory adaptation of parallel plates to lie in snug contact with them.

Because of these shortcomings a new appliance was designed which consisted of components which could be assembled during the operation to make a prosthesis of the right dimensions. A random series of 25 dried mandibles were measured and average values of the various dimensions were calculated, including an average angle of inclination between body and ramus. Drawings were then prepared and an appliance designed within the average range of values which had been obtained.

The appliance consists of a ramus and a body portion which are jointed together at the angle point by two toothed coupling plates. Rigid fixation is achieved by tightening the connecting nut and bolt, once the correct angulation between the two parts has been obtained. The nut contains a hard nylon insert so that once tightened it cannot become loose as a result of vibration or repeated movements.

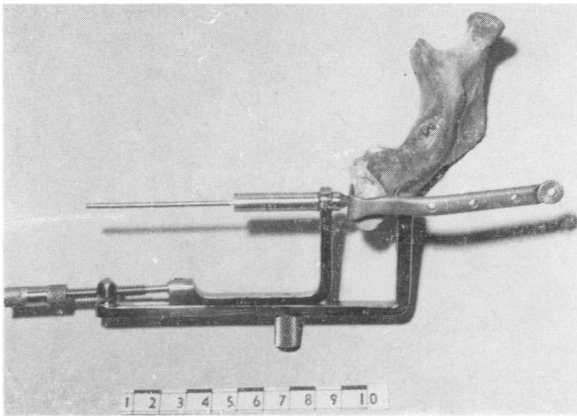


Fig. 4. Drill guide. Appliance holding attachment plate clamped to dried bone.

The form of the replacement bars is of an oval cylindrical rod, perforated at intervals by holes to allow tissues to be sewn on to the appliance. The condyle portion is designed as a regular sphere to act as an articulating surface. A single anterior attachment plate is used, and is designed with the correct curvature to fit accurately on to the bone surface. It contains two holes for the passage of bolts.

The possibility of using a hemimandibular implant composed of titanium 130 is also being explored as this material possesses greater flexibility than that found in cobalt chrome alloy (Fig. 3).

A special drill guide has been designed for use with attachment plates of implants. This clamps the plate to the bone during the reaming of the bolt holes so that no error in position can occur. The guide consists of a hollow tapered cylinder of cobalt chrome which is designed to fit a $\frac{3}{32}$ -inch drill of the same alloy. The drill passes down the centre of the cylinder and is met at its exit by a stop. The cylinder and the stop are

mounted on separate arms which can be moved in relation to one another by a screw which is turned and tightened in order to fix the guide on either surface of the mandible. There is an additional locking nut to fix the position of the drill guide cylinder in its correct position (Fig. 4). When a bolt hole has been reamed in the bone in the correct direction it is enlarged up to $\frac{9}{64}$ -inch diameter to accommodate the shaft of the standard $\frac{1}{8}$ -inch shaft Wilson spinal bolt. These bolt heads and nuts have a $\frac{5}{16}$ -inch hexagonal head and require appropriate box wrenches for their tightening.

No difficulties have been encountered during insertion of implants based in their construction upon the patients' measurements and radiographs. Some difficulties have arisen over the insertion of the standard size hemimandibulectomy implant. Once these have been overcome in relation to insertion and fixation later complications sometimes occur, particularly in relation to irradiated cases. These have included absorption of bone at the point of fixation with consequent loosening of the implant, breakdown of overlying mucous membrane or inadequate healing, and in two cases ulceration of the skin by the implant. Fracture of an implant is also possible.

Biological and biomechanical consideration

The importance of a low co-efficient of friction between the substances forming the articulating surfaces have been emphasized by Charnley (1961). If the frictional co-efficient is too high then a greater amount of muscle force is required to produce movements in the joint and this will be reflected in the efficiency of function seen clinically. In the case of the temporo-mandibular joint as compared with the hip joint the problem is simplified by the anatomy of the joint. The latter is divided into two synovial compartments by the presence of the intra-articular fibro-disc itself partially invested by synovial membrane. This membrane when lubricated by synovial fluid has a much lower co-efficient of friction than any known artificial bearing. The surface of the fibro-disc therefore provides an excellent articulating surface for a prosthetic condyle of cobalt chrome.

The intra-articular disc is carefully preserved during disarticulation, provided it is free from disease, and in this way the most natural type of low friction joint is obtained when the metal condyle is inserted. Post-operative movements should be the best it is possible to achieve. The size of the artificial condyle has in practice been reduced to about half the size of the average normal bone. This greatly facilitates insertion and, as the loading factor in this situation is relatively low in the absence of weight bearing, difficulties caused by wear have not been encountered.

Selection of patients and surgical feasibility

When a method of replacement involving the use of foreign material is applied, all possible causes of failure of a technical nature must be elimin-

ated. Selection of suitable cases must be made with care as attempts to use the method in unsuitable conditions will inevitably result in failure.

Only those cases should be attempted in which the lesion is sufficiently small to allow adequate clearance by surgery and still leave sufficient normal tissue to permit closure of the mucosa over the implant without tension.

The cases in this series which have been satisfactorily treated by the method fall into two groups. The first group contains primary malignant tumours of epithelial origin, which have usually been treated initially by radiotherapy. This has either been interstitial irradiation from needles or by gamma rays from an external telecobalt source. Initial healing or at least regression of the tumour has occurred, followed later by reactivation of disease. Surgical removal of the lesion including a portion of the mandible has been required. Squamous carcinomas of the alveolus, sulcus and mouth floor have been treated, and also two examples of mucous and salivary tumour.

The second group of cases includes a small number of primary carcinomata and also primary sarcomas arising from connective tissue for which the definitive treatment is surgical removal by hemimandibulectomy. In addition some large ameloblastomas which required extensive resection not replaceable by immediate bone grafting have been treated.

Technique of insertion and fixation

In this series partial or hemimandibulectomy has usually been carried out by standard submandibular approach. Where possible splitting of the lower lip has been avoided, as a linear mucosal incision appears to heal most satisfactorily. When a mid-portion resection of the mandible is required the incision has followed the lower border of the bone, extending on either side of the midline.

After the diseased portion of bone is removed the implant is inserted into the tissues and its size and fit tested. If this is satisfactory, fixation to the remaining fragment or fragments is carried out. When this is effectively completed the mucosa is closed on the oral surface of the implant, and a layer of connective tissue and muscle are next sewn over the implant so that it is cushioned.

The remaining muscles are sewn on to the appliance in as normal an anatomical position as possible, making use of the perforations present to allow passage of the catgut stitches. In many cases there is sufficient remaining masseter and medial pterygoid muscle to allow their firm suturing to the appliance. Post-operative function will be enhanced by the continuing action of these muscles.

In hemimandibular replacement the stability of the artificial joint depends largely upon the holding effect of these muscles. The artificial condyle is held firmly in the glenoid fossa by their tonic contraction. If a

large portion of these muscles has to be sacrificed because of their infiltration by disease the artificial joint will be much less stable. This difficulty can be overcome by attaching the upper end of the appliance to the zygomatic arch by means of a strip of fascia lata. This strip is passed through the upper hole in the ramus portion of the implant and then over and round the zygomatic arch. It is finally brought back upon itself and sewn one end to the other after a suitable tension has been obtained. This sling keeps the condyle head firmly located in the glenoid fossa without restricting the range of active movements desired.

When considering the fixation of replacement implants to the mandible it is important to have in mind the probable position of the bolt shafts in the bone and their relation to the roots of the standing teeth (Cook, 1962).

In some cases it is possible to place the bolts in such a way as to avoid these teeth roots. If there is any risk of standing tooth roots being damaged during drilling of bolt holes these teeth should be extracted in advance. If an accidentally damaged root remains in position infection of the bolt shaft would be very likely to occur.

A separate risk also exists in relation to any tooth in the fixation area even if the roots are not involved in an actual bolt hole. Any one of such teeth might at some future time be the seat of an alveolar abscess from a purely dental cause. The resulting osteitis would certainly jeopardize the fixation of the implant.

Technique of fixation

After completion of the resection the remaining muscles and periosteum are elevated from the bone at the proposed site of attachment on both medial and lateral surfaces. In hemimandibular replacement the genial tubercles usually need to be ground down flush to the bone surface with a diamond stone.

The main fixation of attachment plate to the bone has been by means of bolts which pass through the whole thickness of the bone of the mandible. Standard Wilson spinal bolts are used, with a hexagonal head size $\frac{5}{16}$ -inch and a shaft diameter of $\frac{1}{8}$ -inch. Various shaft lengths are available varying from $\frac{1}{2}$, $\frac{5}{8}$, $\frac{3}{4}$ or $\frac{7}{8}$ -inch, so that the most suitable length can be selected. The nuts incorporate a hard nylon insert so that once tightened they cannot become loosened by movement or vibration. For the tightening operation special box wrenches are required. It has been found an advantage to grind down the bolt heads to a more domed shape, so eliminating sharp corners but at the same time leaving just sufficient of the angles to be gripped by the wrench.

The aim has been to rely upon this strong fixation initially until such time as the attachment plates are overgrown by new bone formation. Radiographic studies in patients and experimental animals have confirmed this outcome. Long-term success of implants depends upon a stable

fixation which will resist the forces applied to it. It is only by obtaining a truly biological fixation of new bone around the implant that a permanent result can be expected.

When the site of attachment to the bone has been prepared the implant is placed in its correct position and firmly held by screwing the drill guide into place. The guide is supported and a $\frac{3}{32}$ -inch cobalt chrome drill held in a Desoutter drill is passed down the guide hole. A hole is then drilled through the bone until the drill meets the stop on the opposing arm of the guide. Cooling is essential during this manoeuvre and is obtained by means of a hand-operated saline spray. The drill guide is removed and the bolt hole enlarged to a track of $\frac{9}{64}$ -inch diameter using the appropriate drill.

It has been found most satisfactory to make one bolt hole on each fragment in turn so that the relationship of the implant to each fragment is fixed. A second bolt can then be inserted in each fragment by the same method if this is technically possible. Sometimes adequate access cannot be obtained to place a second bolt on the distal portion of the posterior fragment. In this case a Sherman coarse-thread self-tapping screw $\frac{9}{64}$ -inch diameter is acceptable. In hemimandibular implant fixation two bolts should always be used as the bone has been found to absorb from a screw thread so that the screw loosens and ultimately is displaced from the bone.

Post-operative fixation of the jaws has been found unnecessary and no form of dental splint has been applied. Gentle active movements of the jaws are encouraged at the patient's own inclination, and the range of mobility gradually increases. Some mandibular movement is present from the first, a fact which gives the patient great confidence.

The fixation of hemimandibular appliances requires special care, as the anterior part of the mandible is shaped like the arc of a circle. When bolts are passed through the thickness of the mandible at a point just beyond the midline, their shafts occupy a radial relationship to the circumference of this arc. The medial ends of the drill must of necessity converge together, so that even with a space of two centimetres between the holes on the lateral surface of the bone the average mandible allows only just sufficient room to place two $\frac{1}{16}$ -inch nuts side by side and flush on the bone surface. This may in turn result in difficulty in placing the holding wrench on the inner aspect of the bone. These points must be borne in mind when drilling the bolt holes, as inaccurately placed holes cannot be satisfactorily corrected once they are made.

Experimental study

Experimental work was carried out in the Rhesus monkey, *Macaca Mulatta*, in which surgically created defects in the mandible were replaced by means of cobalt chrome implants. The conditions of the experiments were planned to coincide as nearly as possible with those encountered in human patients. The Rhesus monkey was selected because anatomically

the mandible is similar to that of man. The teeth are also similar in morphology and number and the diet is comparable with man's.

Technically the portions of bone resected were the same as would be removed in surgical treatment of a neoplasm. The general design and construction of the replacement implants were similar to those used in patients but a good deal of miniaturization of components was necessary.

The object of the experiments was to reproduce as nearly as possible the type of procedure carried out in patients and to study the results of implant fixation in relation to bone reaction after a set period of time. The arbitrary period of one year was chosen, over which to study the fate of an implant.

Five young adult female animals of approximately seven kilograms were used, into which midline, body and hemimandibular implants were inserted. Two of these animals survived to be sacrificed after one year. One animal was sacrificed prematurely because of incomplete success. One animal was sacrificed post-operatively because of complete failure and one animal died post-operatively from anaesthetic overdose.

Method

At the first procedure the animal was anaesthetized using intramuscular pentobarbitone. Radiographs were taken of the skull and jaws, including left and right lateral skull, postero-anterior view of the skull and jaws, sub-mento vertex of skull and intra-oral lower occlusal view. These films were compared with identical views of various dried Rhesus monkey skulls and when the correct dried specimen was selected it was reproduced in plaster. This model was used to produce a cast cobalt chrome implant of appropriate size by the method already described.

At the second procedure the animal was anaesthetized and intubated using a nasal intra-tracheal tube. After shaving, cleansing and towelling the skin, the teeth in the future attachment and resection areas were extracted.

The final procedure was carried out after an interval of six to eight weeks, when the segment of bone was resected and replaced by the implant. This ensured that mucosal healing was complete before the resection was carried out as it was felt that such a small animal would not tolerate successfully a one-stage procedure.

Design and technique of fixation

The basic design of these appliances consisted of a perforated bar, dumb-bell in cross-section, attached to the bone by two flat attachment plates. Each plate contained holes for bolts $\frac{7}{8}$ -inch in diameter or $\frac{5}{8}$ -inch where a screw was to be used. The smallest available cobalt chrome bolt had a shaft diameter of $\frac{7}{8}$ -inch and a nut of $\frac{3}{16}$ -inch dimension. As these hexagonal nuts could not be supplied with an incorporated nylon insert it

was necessary to lock the position of the first nut after tightening with a second nut. For this purpose Wilson wrenches were produced to fit a $\frac{3}{16}$ -inch hexagonal nut.

Sometimes when it was impossible to insert two bolts, a screw was used instead of a second bolt. These were $\frac{5}{16}$ -inch diameter and 5 or 7 millimetres long, and were inserted with a suitable cobalt chrome screwdriver.

After insertion and fixation of the implant, the remaining connective tissues were sewn around the implant and the wound closed in layers.

Usually after recovery from the anaesthetic the animals did not interfere with the wound or the suturing. In two cases the animals did pick at the ends of the stitches and succeeded in pulling them out, causing complete breakdown of the skin wound. In spite of attempts at resuturing and antibiotic therapy these animals reached a state in which their wounds became infected and refused to heal. They were therefore destroyed prematurely.

Follow-up

The animals were anaesthetized at three-monthly intervals until final sacrifice, for clinical and radiographic assessment. The animals which survived the experimental period ate their diet well and without difficulty.

Radiographs of the mandible were taken every three months using the same views, lateral of skull and jaws, antero-posterior of jaws, submento vertex of skull and intra-oral lower occlusal of alveolus. From these films progress was assessed and deposition of new bone around the implants observed.

Following sacrifice of the animal after a period of one year the relevant tissues were studied with the naked eye, radiographically and histologically. The gross specimen of mandible and attached implant was removed and fixed in 10 per cent formal saline. After photographic and radiographic record the soft tissues were removed. Portions which had been in contact with or grown around the implant were examined histologically.

Method of preparation of hard tissue sections

It was planned to examine the site of attachment of the metal implant to the bone without disturbing their relationship to each other. It was decided to cut sections of the undecalcified bone and the metal implant *in situ*, so that their exact position as in life would be maintained. To achieve this it was necessary to develop a special method of cutting sections.

The block of tissue for examination was orientated and blocked in transparent methyl methacrylate. The resulting block was transparent so that the proposed plane of sectioning was clearly visible. The block was correctly orientated and cemented to a metallic plate using methacrylate dissolved in chloroform. This plate was placed on the movable magnetized staging of a "Centec" milling machine so that when switched on

IMMEDIATE RECONSTRUCTION OF THE MANDIBLE BY METALLIC IMPLANT

the stage moved slowly forwards carrying the block towards the revolving diamond cutting wheel.

The diamond wheel used was of special cutting disc type supplied by Impregnated Diamond Products Ltd. It was five inches in diameter to fit a spindle of one inch diameter which revolved at 2,800 revolutions per minute. Its thickness was $\frac{20}{1000}$ -inch and the diamond particle size was conveyed by No. 200c.

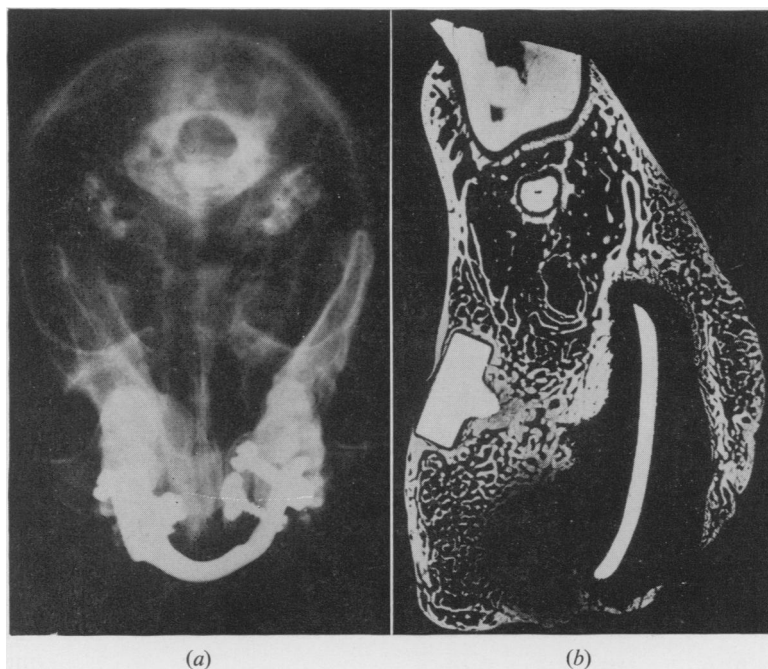


Fig. 5. (a) Rhesus monkey. Post-operative one year radiograph. Sub-mento vertex view. Shows midline replacement implant. Mandibular symmetry maintained. New deposits mainly on the left side. (b) Microradiograph. Hard tissue section (thickness approximately 100 microns) of cobalt chrome attachment plate and undecalcified bone cut in continuity. Bolt head and attachment plate incorporated in new bone after one year. Mag. $\times 3$.

During the cutting process a jet of coolant was sprayed continuously on the slowly moving block to prevent overheating. The average time taken to cut sections by this method was 10 to 15 minutes. These were of approximately 200μ thickness as it was found that attempts to obtain thinner sections usually resulted in fragmentation or loss of the metallic portion in the block. Some sections were further rubbed down by hand to a thickness of from 100 microns to 150 microns, which was a favourable thickness for examination by the micro-radiographic technique.

A ground section obtained by the above method was placed on a slide carrying a photographic emulsion and attached by Sellotape. This was

placed in a specially constructed metal cassette and exposed to a beam of X-rays. These rays were of low kilovoltage, from eight to ten kilovolts, and the period of exposure varied from one to one and a half hours, depending on the thickness of the section under examination. The resulting slide was developed and fixed in the ordinary manner, dried and protected by a cover slip. Enlarged photographic prints were then made, enabling the position of the implant in relation to new bone formation to be studied. The detail was sufficient to demonstrate new bone formation over the metal of the implant, position of the marrow spaces, and incorporation of the holding bolts and screws.

Animal results

The first animal was submitted to a midline mandibular resection extending from molar region to molar region. The prepared implant was inserted and fixed on each fragment by one 4.04 bolt with two nuts and one 7-mm. screw. Healing proceeded well except for some low-grade wound infection on the left side which gradually settled.

The animal was radiographed at three months, six months, nine months and one year post-operatively. These films showed that the implant remained in good position maintaining mandibular continuity and symmetry.

After nine months there was radiographic evidence of new bone formation over the left attachment plate, but some change in position on the right side.

At one year the position of the mandible was stable, and on the cut ends of both fragments considerable bone deposition had occurred (Fig. 5a).

These findings were confirmed on examination of the material after sacrifice. On the left side considerable overgrowth of the attachment plate by new bone had taken place. Two good sections were obtained cut transversely across the attachment by the method described and micro-radiographs made.

The metal attachment plate is cut transversely and is enclosed by new bone. The plate on insertion originally lay on the surface of the bone, and the remains of this surface can be identified at the top of the specimen. A long tongue of new bone extends over the plate from above and a rather smaller outgrowth from below. This new bone is not in contact with the plate and the space between them was no doubt occupied in life by soft tissue (Fig. 5b).

In another section the plane of cut has passed along the axis of a bolt shaft. The bolt head is well incorporated in new bone as in the previous section.

The third animal was submitted to left hemimandibulectomy and replacement of the lost tissue by a prepared implant. This was inserted

IMMEDIATE RECONSTRUCTION OF THE MANDIBLE BY METALLIC IMPLANT

without difficulty and fixed by two bolts. In the post-operative period difficulties with healing were experienced, and the animal was therefore sacrificed prematurely at 19 days.

Post-operative radiographs confirmed the proper fit and position of the implant. Also they demonstrated the functional behaviour of the artificial condyle and its possible position in the glenoid fossa.

Healthy soft tissues in direct contact with the metal were examined histologically. These sections showed new connective tissue containing young fibroblasts laying down fresh collagen fibres. There was an absence of inflammatory cells.

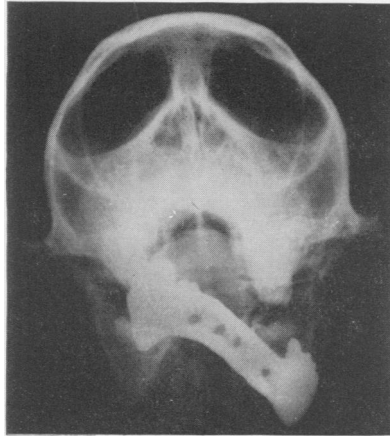

Fig. 6. Rhesus monkey post-operative 13 months. Radiograph. Occipito-mental. Shows left body replacement. Mandibular symmetry maintained.

The fourth animal was submitted to left mandibular body resection and replacement by implant. A resection of the left body of the mandible from midline to angle was carried out. The implant was inserted and fixed on each fragment by one bolt and one screw. Post-operative healing was quite uneventful.

Follow-up over the period of one year was assessed by radiographs taken at three-monthly intervals. These films demonstrated new bone formation at the anterior attachment plate at three months post-operation. In addition new bone was seen at seven months post-operation forming along the bar portion of the implant.

At no time did the implant become loose or alter its position in relation to the bone fragments. The symmetry of the mandibular arch was well maintained (Fig. 6).

Sections and microradiographs were prepared of both anterior and posterior attachment plates. These preparations showed that the attachment plates were held firmly in contact with the original outer surface of

the bone. A thin layer of new bone had grown over the outer surfaces of the metal plates and was in intimate contact with the metal. A section cut through the area of the connecting bar showed complete reformation of the lost mandible which had been surgically removed (Fig. 7*a*).

These sections demonstrated tolerance of the metal and incorporation of it by new bone to such an extent as to constitute a biological union between the natural tissue and the metal implant. The findings received

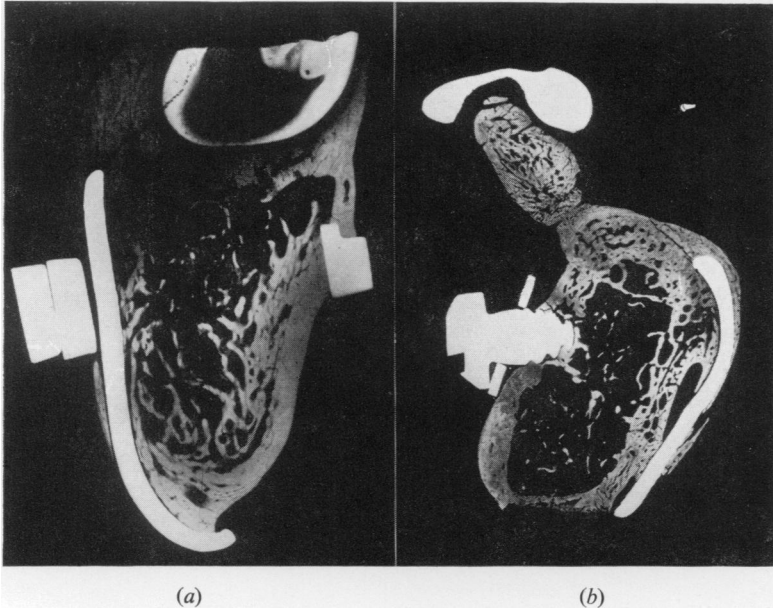


Fig. 7. (a) Microradiograph. Hard tissue section (thickness approximately 200 microns) of posterior attachment plate. New bone deposits on outer surface after 13 months. Mag. $\times 3.8$. (b) Microradiograph. Hard tissue section (thickness approximately 150 microns) of anterior attachment plate. New bone deposits on anterior surface after 13 months. Mag. $\times 2.8$.

indirect support by radiographic appearance of new bone formation around the implants inserted into some patients (Fig. 7*b*).

Some of the soft tissues in relation to the implant were blocked in paraffin wax and the resulting sections stained with haematoxylin and eosin. Examination of the skin and soft tissues overlying the anterior attachment plate showed a wide area of connective tissue containing some muscle fibres in the thickness of tissue between the skin and the implant. There was no evidence of inflammatory infiltration. Segments of unbroken oral epithelium which covered the bar portion of the implant were also examined. These likewise showed no inflammatory changes or suggestion of break in continuity.

Conclusions

On the whole the animal work confirmed the impression that fixation by means of a nut and bolt passed through the thickness of the bone is the only reliable method of attaching an implant to bone for a long period.

When rigid fixation is achieved the deposition of new bone over the attachment plates can be confidently anticipated.

Clinical results and discussion

Fifteen patients with mandibular neoplasms have been treated by restoration of the surgical defect using a metallic implant immediately inserted.

TABLE I

TYPE OF NEOPLASM	
Squamous cell carcinoma ..	9 cases
Fibro-sarcoma	1 case
Chondro-sarcoma	1 case
Ameloblastoma	2 cases
Mucous and salivary tumour ..	2 cases
Total	15 cases

TABLE II

TYPE OF TREATMENT	
Irradiation and surgery ..	8 cases
Surgery only	7 cases
Total	15 cases

TABLE III

TYPE OF OPERATION	
Hemi-mandibulectomy ..	7 cases
Two-thirds mandibulectomy ..	1 case
Mid-portion resection	3 cases
Unilateral body resection only	4 cases
Total	15 cases

TABLE IV

RESULTS	
<i>Numbers of years in situ</i>	
5 years or more	2 cases
2-3 years	4 cases
1-2 years	4 cases
Less than six months	5 cases
Total	15 cases

Nine patients had squamous cell carcinomas. One patient had a fibro-sarcoma, one patient had a chondro-sarcoma. Two patients had ameloblastomas and two patients mixed salivary tumours (Table I).

Of these patients eight were treated by both irradiation and surgery and seven by surgery only (Table II).

The type of operation carried out was in seven cases hemimandibulectomy, in one case two-thirds mandibulectomy, in three cases mid-portion resection, and in four cases resection of the body portion on one side only (Table III).

The success or otherwise of the method is gauged by the length of time during which the implants remained in position functioning well.

In two cases the duration was five years or more. In four cases the duration of success was two years and in four cases the implant was successful for one year. One of the latter patients died with the implant *in situ*. In the remaining five cases the implant was removed in less than six months,

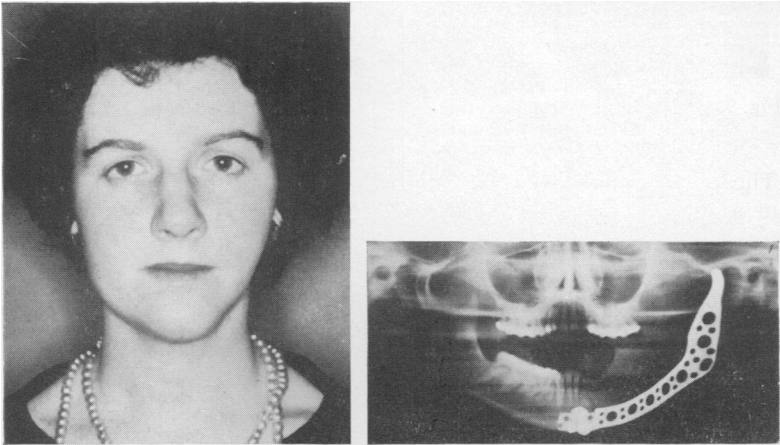

Fig. 8. Clinical photograph. Left hemimandibular replacement, 18 months post-operative, with roentgen radiograph of patient showing degree of opening movement.

except in one patient in whom the implant was inserted within six months of this report. One patient in this group committed suicide some time after removal of the implant. In three cases in which implants were removed satisfactory replacement by a bone graft was obtained at a later date. Two patients elected to have nothing further done (Table IV).

On the whole the immediate post-operative results obtained have been satisfying from both the aesthetic and functional points of view (Fig. 8).

It seems of interest to consider the effect of irradiation therapy on the probable success of an implant inserted during surgery at a later date. Of the six cases successful over a period of two years or more, five were not irradiated during treatment and one only was treated by irradiation and surgery (Fig. 9).

In the five cases in which the implant was in position for less than six months, four patients had been irradiated heavily by wedge or opposing telecobalt fields and one patient in whom the implant is still *in situ* was treated by surgery only.

IMMEDIATE RECONSTRUCTION OF THE MANDIBLE BY METALLIC IMPLANT

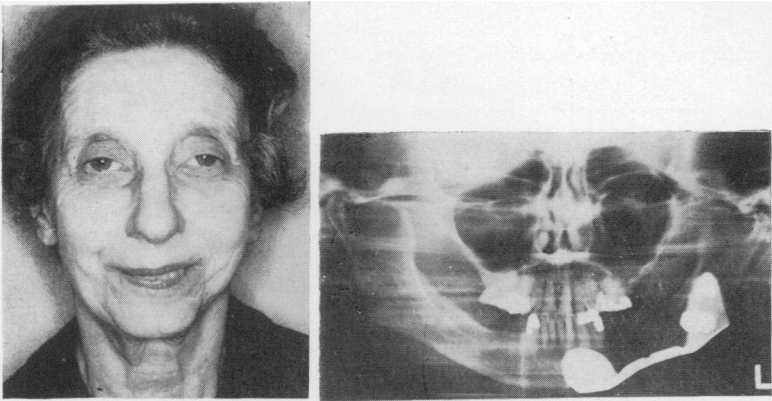

Fig. 9. Clinical photograph. Left body replacement, 18 months post-operative, with roentgenograph demonstrating implant.

These figures, although small in number, are sufficiently striking to indicate a higher chance of success when irradiation has not been used. Nevertheless with careful treatment planning, and anticipation, success with an implant after later surgery is not impossible (Fig. 10).

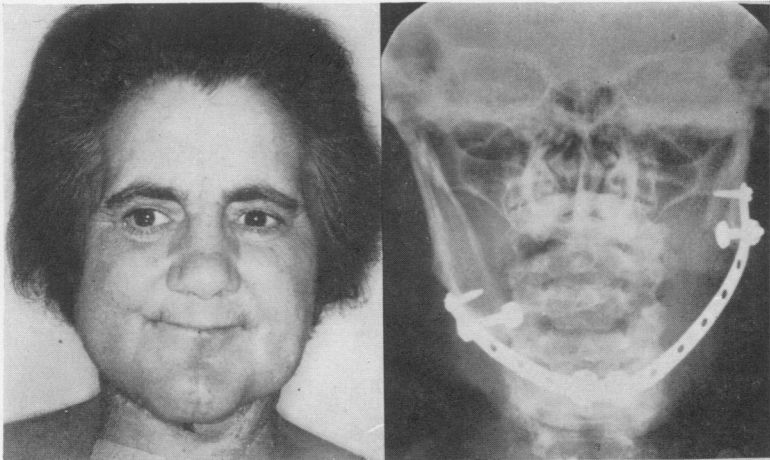


Fig. 10. Clinical photograph. Midline replacement, five weeks post-operative, with postero-anterior radiograph demonstrating implant.

The planning of treatment for patients with mandibular neoplasms should always include consideration of the probable outcome of such treatment. Surgery, chemotherapy, radiotherapy and reconstruction both immediate and late all make their contribution to the patient's cure and rehabilitation to normal living. If one part of the management is left out of consideration it is our patient who loses by it.

ACKNOWLEDGEMENTS

I am most greatly indebted to my colleague and friend, Mr. E. Stanley Lee, for his continued interest and encouragement in this work. His permission to refer to patients under his care into whom I have inserted implants is gratefully acknowledged. I am also grateful to colleagues at the Middlesex Hospital who have sought my collaboration.

Dr. John T. Scales, Department of Biomechanics, Royal National Orthopaedic Hospital, has given me much invaluable advice and I am deeply grateful to him.

The Institute of Clinical Research, the Middlesex Hospital, have provided me with experimental facilities and funds, and I am grateful to the Director, Professor Alan Kekwick, and many others in the Institute.

I am grateful to Professor R. B. Lucas and Dr. Sydney Blackman for facilities and help in the Departments of Pathology and Radiology respectively at the Royal Dental Hospital, and to the research committee for a grant of funds.

I received much help from Mr. J. Mercer, who helped me to cut the hard tissue sections.

Messrs. Deloro-Stellite have kindly made the appliances in Vinertia for me and I am most grateful to Mr. Medcraft for his technical advice and help.

I am also grateful to Dr. Kenneth Newton for advice over radiotherapy treatment plans.

Mr. R. Axton of the Middlesex Hospital kindly assembled the drill guide for me and made several brass prototypes, and Mr. Maurice Down has produced several prototypes in titanium.

I acknowledge a special debt to the Photographic Departments of the three hospitals with which I have been associated, the Middlesex, the Royal Dental and the Westminster, for the high quality of the work they have produced.

I acknowledge with gratitude the honour which this College has done me by awarding me this Hunterian Lecture.

REFERENCES

- BELLINGER, D. H. (1947) *J. oral Surg.* **5**, 108.
BOWDEN, F. P., WILLIAMSON, J. B. P., and LAING, P. G. (1955) *J. Bone Jt. Surg.* **37B**, 676.
BYARS, L. T. (1948) *Ann. Surg.* **127**, 863.
CASTIGLIANO, S. G. (1954) *Amer. J. Surg.* **88**, 490.
_____ and GROSS, P. P. (1951) *J. oral Surg.* **9**, 31.
CHARNLEY, J. J. (1961) *Lancet*, **1**, 1129.
CONLEY, J. J. (1951) *Plast. reconstr. Surg.* **8**, 150.
_____ (1956) *J. oral Surg.* **14**, 325.
COOK, H. P. (1962) *Radiology*, **13**, 4.
DEWEY, A. R., and MOORE, J. W. (1962) *J. oral Surg.* **20**, 34.
DOWN, G. M. (1966) *J. Inst. Brit. Surg. Tech.* **1**, 25.

IMMEDIATE RECONSTRUCTION OF THE MANDIBLE BY METALLIC IMPLANT

- FERGUSON, A. B., AKAHOSHI, Y., LAING, P. G., and HODGE, E. S. (1962) *J. Bone Jt. Surg.* **44A**, 323.
- FREEMAN, B. S. (1948) *Plast. reconstr. Surg.* **3**, 73.
- GENEST, A. (1956) *Amer. J. Surg.* **92**, 904.
- GROSS, P. P., and GOLD, L. (1957) *Oral Surg.* **10**, 769.
- HEALEY, M. J., SUDBAY, J. L., NIEBEL, H. H., HOFFMAN, B. M., and DUVAL, M. K. (1954) *Surg. Gynec. Obstet.* **98**, 395.
- KLEITSCH, W. P. (1951) *Plast. reconstr. Surg.* **7**, 244.
- (1952) *Plast. reconstr. Surg.* **10**, 444.
- MCQUILLAN, A. S., WINTER, L., and LIFTON, J. C. (1945) *Amer. J. Surg.*, N.S. **69**, 318.
- MIGLANI, D. C. (1961) *J. oral Surg.* **19**, 341.
- NAGAO, Y. (1962) *Int. Cong. Oral Surg.* **1**, London.
- NIEBEL, H. H., HEALEY, M. J., NEWMAN, E. W., and HOFFMAN, B. M. (1954) *J. Amer. dent. Ass.* **49**, 1.
- SCALES, J. T. (1956) *J. Bone Jt. Surg.* **38B**, 754.
- (1958) in L. GILLIS, editor, *Modern trends in surgical materials*, p. 70. London, Butterworth.
- (1966) *J. Inst. Brit. Surg. Tech.* **1**, 52.
- DUFF-BARCLAY, I., and WILSON, J. N. (1966) *Proc. Roy. Soc. Med.* **59**, 948.
- SKINNER, R. W., and PHILLIPS, R. W. (1960) *The Science of Dental Materials*, 5th edition. Philadelphia, Saunders.
- VENABLE, C. S., and STUCK, W. G. (1941) *Ann. Surg.* **114**, 309.
- WALSH, T. S. (1954) *Cancer*, **7**, 1002.

DONATIONS

DURING THE PAST few weeks the following generous donations have been received:

£4,023	6s. 5d.	Mr. and Mrs. A. F. W. Hurlstone (towards the conversion of "Homefield")
£1,000	£856	Samuel Ayrton, Esq.
	17s. 7d.	Bond Street Galleries (7-yr. covenant, £6 per month + tax)
£560		Rentokil Group Ltd. (7-yr. covenant, £80 p.a. less tax) (further gift)
£297	17s. 7d.	Shipton Automation Limited (7-yr. covenant, £25 p.a. + tax)
£200		Legacy from the late Mr. H. A. Phillips
£160	13s. 10d.	Total monies donated in memory of the late Miss G. Sandes, F.R.C.S., by her friends.
£105		Equity and Law Life Assurance Society Limited
		Wilde, Sapte and Company (further gift)
£100		The Trustees of the H. J. Joel Discretionary Trust (further gift)
		Bertie Black Foundation (further gift)
£85		In memory of the late Mr. Roy Ward David, towards cancer research
£34	0s. 10d.	Laing and Cruickshank Service Company Limited (further gift)
£25		W. T. King, Esq. (further gift)
£20		Anonymous
£15		Dr. E. M. Robertson (towards cancer research)
		The Lindsay Club
£11		C. F. Edmonds, Esq. (for cancer research in memory of his late father)
£10	10s.	British Pens Limited
		The Mabel Peatfield Charities Company Limited (further gift)
£8		J. E. Hoyle, Esq. (for research into cerebral and coronary thrombosis)