

Letters to the Editor

Gastro-duodenal injury associated with intake of 100–325 mg aspirin daily

Sir,
Oren *et al.* drew attention to the ulcerogenic and haemorrhagic side effects of aspirin in doses ranging from 100 to 325 mg/day.¹ In our experience, life-threatening gastric complications can occur even with maintenance doses of 75 mg/day. An example is an 82 year old woman with a history of gastroenterostomy for duodenal ulcer, at the age of 55, followed by truncal vagotomy at the age of 65, for anastomotic ulcer giving rise to haematemesis. At the age of 81 her haemoglobin level was 14.9 g/dl. She was taking aspirin 75 mg day for ischaemic heart disease and she had no dyspepsia. Ten months later, she was admitted with haematemesis and a haemoglobin of 9.9 g/dl. In view of continuing bleeding, she was referred to Miss M.T. Morrell, F.R.C.S., who performed a gastrostomy which revealed multiple gastric erosions, the largest of which were underrun. Aspirin was discontinued and she had no recurrence of bleeding. The lesson from this case is that the modest doses of aspirin currently recommended for ischaemic heart disease² and for transient ischaemic attacks³ also carry the risk of life-threatening gastropathy, even in patients with hypochlorhydria.

O.M.P. Jolobe
N.S. Price

Department of Medicine for the Elderly,
Tameside General Hospital,
Fountain Street,
Ashton-under-Lyne,
Lancashire OL6 9RW, UK.

References

- Oren, R., Ligumsky, M., Lysy, J. *et al.* Gastro-duodenal injury associated with intake of 100–325 mg aspirin daily. *Postgrad Med J* 1993, **69**: 712–714.
- Nyman, I., Larsson, H., Wallentin, L. *et al.* Prevention of serious cardiac events by low-dose aspirin in patients with silent myocardial ischaemia. *Lancet* 1992, **340**: 497–501.
- The SALT Collaborative Group. Swedish aspirin low-dose trial (SALT) of 75 mg aspirin as secondary prophylaxis after cerebrovascular ischaemic events. *Lancet* 1991, **338**: 1345–1349.

Bone density measurement in osteogenesis imperfecta may well be important

Sir,
We read with interest the article by Colin Paterson and Patricia Mole.¹

The authors have shown that, in a sample of 61 patients with osteogenesis imperfecta (OI), 70% of patients with type I or type IV OI had bone mineral content (BMC) or bone mineral density (BMD) values at the non-dominant forearm, measured by single photon absorptiometry (SPA), within 2 s.d. of the mean for age- and sex-matched normal volunteers. The authors therefore advise caution in using bone density studies to 'exclude' OI.

We wish to make three points in relation to this study. Firstly SPA is no longer the preferred method of bone densitometry. Although there is some correlation between it and measurements at other sites, it is not sufficient to predict fractures at the hip and spine.² Direct measurements at these sites by dual energy X-ray absorptiometry (DXA) are needed.

Secondly, in interpreting results of any investigations, one needs to differentiate clearly between statistical significance and clinical significance of the values. In the case of bone density studies it can be especially misleading to label somebody normal just because the result lies within the 2 s.d. band. The difficulties in defining 'normality' for a continuous variable like bone density, which has a varying fracture risk at all levels with no cut-off, are shown by the observation that for every reduction in the BMD by 1 s.d., the risk of fracture at that site increases 2–3 fold.³ Most of the patients described in this paper have Z-scores worse than –1. They as individuals therefore do carry an increased risk of fractures because of this low bone density, quite apart from the risk secondary to their abnormal collagen structure. While we do agree with the general principle that bone densitometry studies should not be used for diagnostic purposes in OI, it may, however, indicate whether to investigate further an undiagnosed young person sustaining a low-trauma fracture. Our own data support this contention.

We have previously reported a prospective study of 18 patients from eight known families with OI in Cornwall.⁴ We identified 3(6) families (affected family members) with Sillence type I OI, 1(1) with type III OI and 4(11) with type IV OI. The affected members were eight men (age 9–79) and 10 women (age 4–66, six postmenopausal). All patients underwent BMD measurements by DXA of their lumbar spine (L₁–L₄). The mean Z value spine in this group was –2.45 (range –4.0 to –0.6). If we accept that anybody with bone density within ± 2 s.d. of the mean to be 'normal', then eight out of 18 patients (44.4%) could be termed as having 'normal' bone density (Figure 1). However, no patients had a Z-score above –0.5, only one of our patients had Z-score between –0.5 and –1, seven patients had Z-scores between –1.5 and –2, and 10 patients had Z-scores worse than –2.

The third point that we wish to make is in relation to the process of mineralization of collagen matrix. Histomorphometric and electron microscopic studies on the OI

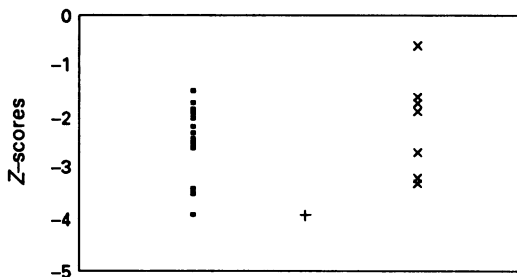


Figure 1 Patients with osteogenesis imperfecta. Bone mineral density in the lumbar spine measured by dual-energy X-ray absorptiometry. (Classification according to Sillence). ■ = Type I; + = type III; × = type IV.

bone have shown that the defective collagen fibrils can be non-mineralized or that the crystals of hydroxyapatite are irregularly arranged.⁵ This supports the theories of mineralization of the organic matrix of bone which suggest that normal collagen is required to form a normally mineralized bone. In OI low BMD values are therefore highly likely in spite of having a normal calcium metabolism.

While we are not suggesting that OI should be diagnosed on the basis of bone density results, we certainly feel that in somebody with no obvious precipitating factor for osteoporosis and with spine BMD worse than -1.5 , the possibility of as yet undiagnosed OI should be considered. Serial bone density studies in OI can also be extremely useful in monitoring disease progression as well as assessing the response to any treatment. In our opinion therefore, bone densitometry has an important place in the management of OI.

A.A. Deodhar

A.D. Woolf

*Duke of Cornwall Rheumatology Unit,
Royal Cornwall Hospital (City),*

Truro,

TR1 2HZ, UK.

References

1. Paterson, C.R. & Mole, P.A. Bone density in osteogenesis imperfecta may well be normal. *Postgrad Med J* 1994, **70**: 104–107.
2. Wahner, H.W. & Fogleman, I. Dual energy X-ray absorptiometry on appendicular bones. In: *The Evaluation of Osteoporosis: Dual Energy X-ray Absorptiometry in Clinical Practice*. Martin Dunitz, London, 1994, pp. 178–195.
3. Ross, P.D., Davis, J.W., Epstein, R.S. & Wasnich, R.D. Pre-existing fractures and bone mass predict vertebral fracture incidence in women. *Ann Intern Med* 1991, **114**: 919–923.
4. Deodhar, A.A. & Woolf, A.D. Bone mineral density measurement by DEXA in osteogenesis imperfecta: a study of eight families in Cornwall. In: Ring, E.F.J. (ed.) *Current Research in Osteoporosis and Bone Mineral Measurement*, Vol. II. British Institute of Radiology, London, 1992, pp. 60–61.
5. Cassella, J.P. & Yousuf Ali, S. Abnormal collagen and mineral formation in osteogenesis imperfecta. *Bone Mineral* 1992, **17**: 123–128.

Dapsone in Henoch–Schönlein purpura

Sir,

Dapsone appears to be of especial value in cutaneous leukocytoclastic vasculitis.¹ Encouraged by the reported cases of Henoch–Schönlein purpura (HSP) treated with dapsone with good effect,^{1–3} I studied the role of dapsone in six patients with HSP (two men and four women, median age 37 years, range 18–54) between December 1991 and October 1993.

All patients presented with the characteristic skin lesions with abdominal pain, fever, arthritis of ankle joints following upper respiratory tract infections and showed on skin biopsy leukocytoclastic vasculitis. One 54 year old woman presented with haematuria and raised blood urea nitrogen and creatinine concentrations while a 32 year old man showed haematuria (Table I). Within 24 hours of starting treatment with dapsone 100 mg/day,

four of six patients showed clearance of ankle pain and swelling followed by lower limb purpura by 3–4 days. Haematuria subsided in the two patients within 4 days. Dapsone dose was reduced over the next 2 months (50 mg/day) and then stopped in three patients (nos. 1, 3,4) and in two patients (nos. 5 and 6) over the next 4 months. Patient no. 2 had no recurrence of purpura or rash with just 2 weeks of dapsone 100 mg/day and remains off treatment 9 months later.

Corticosteroids are of limited value in conditions characterized by leukocytoclastic vasculitis.¹ Dapsone, on the other hand, appears to be effective, cheap and safe in relatively small doses.¹ The mechanism of action of dapsone in leukocytoclastic vasculitis is unknown.¹ There is evidence that it has an antioxidant scavenger effect and may also suppress the generation of toxic free radicals in polymorphonuclear neutrophils.¹ In addition, it inhibits prostaglandin PGD₂ production⁴ and the synthesis of IgG and IgA antibodies.⁵ The latter two properties of dapsone may be of particular importance for its use in HSP in which IgA production is primarily disturbed due to immunodysregulation and disturbances in prostaglandin metabolism contribute to the inflammatory process.⁶

In a condition with no treatment of proven value,⁷ there appears to be enough evidence to justify a trial of dapsone in HSP for symptom relief, and for the possible life-threatening complications of gut purpura and severe glomerulonephritis.¹

Results of this uncontrolled study support those of Hoffbrand,¹ Ledermann and Hoffbrand,² and Chamouard and colleagues.³ They also suggest that the effect of dapsone in HSP should be more widely appreciated and that there is no geographic prejudice for the role of dapsone in the treatment of Henoch–Schönlein purpura.

Acknowledgements

The author thanks Dr Sachi Diwan and Dr S.K. Sethi for technical help and helpful comments.

P.S.A. Sarma

Department of Medicine,

Jawaharlal Nehru Hospital and Research Centre,

Bhilainagar-9,

Madhya Pradesh – 490 006, India.

References

1. Hoffbrand, B.I. Dapsone in Henoch–Schönlein purpura – worth a trial. *Postgrad Med J* 1991, **67**: 961–962.
2. Ledermann, J.A. & Hoffbrand, B.I. Dapsone in allergic vasculitis: its use in Henoch–Schönlein disease following vaccination. *J R Soc Med* 1983, **76**: 613–614.
3. Chamouard, P., Baumann, R., Thomas, G. & Weill, J.P. Intert de la dapsone dans le traitement des manifestations digestives du purpura rhumatoïde de l'adulte. *Ann Med Interne* 1987, **138**: 599–560.
4. Ruzica, T., Wasserman, S.I., Soter, N.A. *et al.* Inhibition of rat mast cell arachidonic acid cyclo-oxygenase by dapsone. *J Allergy Clin Immunol* 1983, **72**: 365–370.
5. Melsome, R., Harboe, M., Myrvang, B. *et al.* Immunoglobulin class specific antibodies to *M. leprae* in leprosy patients, including the intermediate group and healthy contacts as a step in development of methods for serodiagnosis of leprosy. *Clin Exp Immunol* 1982, **47**: 225–233.