

Multiple sclerosis presenting as late functional deterioration after poliomyelitis

E Chroni, RS Howard, CP Panayiotopoulos, GT Spencer

Summary

We describe five patients with previous poliomyelitis who developed multiple sclerosis (two laboratory supported definite and three clinically definite). The initial symptoms of functional deterioration developed a mean of 30 years following poliomyelitis. Initial functional deterioration was due to progressive limb weakness or impaired mobility and in three cases this led to an initial diagnosis of post-polio muscular atrophy. The clinical diagnosis became apparent with the subsequent development of characteristic clinical features, including optic nerve, brainstem, cerebellum, and spinal cord involvement. The occurrence of multiple sclerosis in these patients emphasises that late functional deterioration may be apparently unrelated to previous poliomyelitis. Furthermore, characteristic clinical features may be masked by the severe pre-existing neuromuscular and orthopaedic impairment leading to diagnostic delay and confusion with the ill-defined clinical syndrome of progressive post-polio muscular atrophy.

Keywords: multiple sclerosis, poliomyelitis

Introduction

Many patients with previous poliomyelitis develop post-polio syndromes (PPS) in which late functional deterioration follows a period of relative stability.¹ New weakness or atrophy may occur in the absence of any underlying cause in progressive post-polio muscular atrophy (PPMA) which is a form of PPS. However, because of their existing disability, post-polio patients are also particularly susceptible to the effects of intercurrent orthopaedic, neurological, respiratory or general medical factors.² Diagnostic difficulty can arise because the characteristic features of secondary causes of deterioration may be masked by the pre-existing impairments leading to an erroneous diagnosis of PPMA. We report five cases from a personal series of 589 patients (GTS) in whom post-polio deterioration was due to multiple sclerosis (MS).

Case reports

Patient 1

A 25-year-old woman developed poliomyelitis during pregnancy. She was extensively paralysed during the acute illness but did not receive ventilatory support. Following rehabilitation she was left wheelchair-bound, with severe upper limb weakness and flaccid paraplegia. At the age of 40 she developed progressive increasing weakness of the right hand and arm manifest as a loss of ability to feed herself, comb her hair or brush her teeth. Over the next eight years she had episodes of diplopia, upper limb spasticity, weakness and hyperreflexia. She was referred because of post-polio deterioration at which time she had bilateral internuclear ophthalmoplegia, vertical nystagmus, optic disc pallor, left relative afferent pupillary defect, bilateral upper limb spasticity and weakness in addition to the pre-existing wasting, spasticity and proprioceptive loss in the right leg. She subsequently developed progressive bulbar failure before her death from aspiration pneumonia in 1986. The diagnosis of MS was clinical and based on the occurrence of clear episodes of relapsing and remitting neurological symptoms and signs.

Patient 2

A 42-year-old woman had developed acute paralytic poliomyelitis when aged three months. She was extensively paralysed during the acute illness and received artificial ventilation with an Iron Lung for six months. She was left with severe upper limb weakness, flaccid paraplegia and was wheelchair-bound. She had a transient episode of painful visual loss from the left eye when aged 25 years. Nine years later she developed progressive weakness of both arms, frequency and urge incontinence. In addition to the preceding severe flaccid weakness there were myoclonic jerks of the right arm and reduced spinothalamic sensory appreciation below the clavicle on the left. Visual- and brainstem-evoked potentials were normal but there was delayed central motor conduction bilaterally. She developed episodic increasing weakness and paraesthesia of both arms with clear functional deterioration, urinary incontinence and chronic constipation. In addition to the severe upper limb weakness and flaccid paraplegia there was a low thoracic level to vibration sense and joint position sense appreciation. A diagnosis of clinically definite MS was made. Magnetic resonance imaging

Lane-Fox Unit and Departments of Neurophysiology and Neurology, Guy's and St. Thomas' Hospital Trust, St Thomas' Campus, London, UK
E Chroni
RS Howard
CP Panayiotopoulos
GT Spencer

Correspondence to
Dr RS Howard, Department of Neurology, Guy's and St Thomas' Trust, St Thomas' Campus, London SE1 7EH, UK

Accepted 27 July 1994

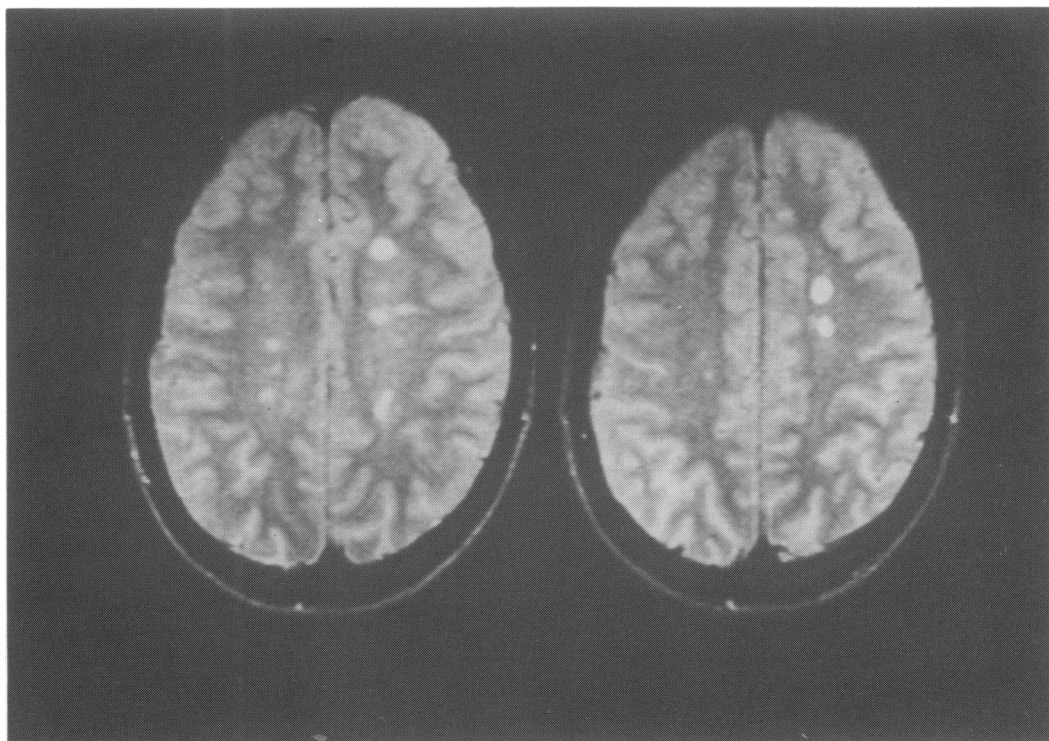


Figure 3 Multiple sclerosis presenting as late functional deterioration after poliomyelitis

(MRI) showed multiple high-signal periventricular lesions on T2-weighted images.

Patient 3

A 48-year-old woman was referred for further investigation of post-polio functional deterioration. She had poliomyelitis at the age of 8 years and was left with severe flaccid weakness of the right leg which was subsequently amputated. She remained wheelchair-bound. Between the ages of 39 and 40 she had three episodes of weakness of the right arm and leg. Examination showed a right facial weakness, asymmetrical bilateral wasting without fasciculations, variable flaccid weakness predominantly in a pyramidal distribution on the right with pathologically brisk reflexes and a global flaccid weakness of the left leg. Visual- and auditory-evoked potentials were normal, somatosensory-evoked potentials showed delay following left arm stimulation and an absent response on the right. Cerebrospinal fluid (CSF) showed positive oligoclonal bands and MRI showed multiple small focal areas of high signal on T2-weighted images in a predominantly periventricular distribution.

Patient 4

A 44-year-old man developed polio when aged 18 months, leaving him with flaccid leg weakness. He was referred at the age of 42 years having developed intermittent diplopia, left foot drop and increasing incoordination of the left leg. On examination there was horizontal nystagmus, mild distal weakness of the left hand, left-sided ataxia and dysdiadochokinesis, absent abdominal reflexes, severe flaccid right leg weakness and moderate pyramidal weakness of the left leg with left-sided hyperreflexia

and an extensor plantar response. Visual-evoked potentials showed delayed latency bilaterally and central motor stimulation showed delay in the central motor pathways on the left. MRI of the cervical cord showed significant narrowing at the C6-7 interspace but T2-weighted images showed multiple high signal lesions in a predominantly periventricular distribution.

Patient 5

A 43-year-old woman had developed polio when aged five years and was left with a flaccid paraparesis although she was able to walk short distances with leg calipers. At the age of 40 years she developed transient episodes of weakness and numbness affecting the left leg. The following year she had an episode of transverse myelitis with complete sensory loss below the waist and urinary incontinence and frequency. There was a T7 sensory level to all modalities. There was deterioration in the paraparesis and both plantar responses were extensor. Investigation showed positive oligoclonal bands in the CSF, MRI brain scan showed multiple areas of high signal in a periventricular distribution on the T2-weighted images. She has subsequently developed an episode of left optic neuritis.

Discussion

The Lane Fox unit is a national referral centre for patients with previous poliomyelitis and this population of 589 patients forms a selected group because of the severe nature of their underlying disability and late functional deterioration.² In the present series of five

Post-polio syndromes

- post-polio muscular atrophy
- syringomyelia
- radiculopathy/myelopathy due to cervical spondylosis

Learning points/summary box

- late functional deterioration may be unrelated to previous poliomyelitis
- characteristic clinical features may be masked by pre-existing neurological signs

patients with multiple sclerosis (two laboratory-supported definite and three clinically definite³) initial functional deterioration was due to progressive limb weakness or impaired mobility and in three cases this led to an initial diagnosis of PPMA. The clinical diagnosis became apparent with the subsequent development of characteristic clinical features including optic nerve, brainstem, cerebellum and spinal cord involvement. One patient had relapsing and remitting multiple sclerosis and the remaining four secondary progressive MS.⁴ In one patient a diagnosis of clinically definite MS was made and no further investigations were undertaken because of her severe disability. In the remaining four patients, oligoclonal bands were present in two of the three patients in whom lumbar puncture was performed, evoked potentials were abnormal in four and MRI scan showed multiple periventricular white matter lesions in four patients.

A number of neurological disorders may cause late deterioration in patients with previous poliomyelitis (see box).^{6,7} Other neurological disorders described in patients with previous poliomyelitis include cerebrovascular disease, epilepsy, cerebral and spinal tumours; however, there is no suggestion of an increased prevalence of these disorders.² Salazar-Grueso⁸ described neurological disorders in 6/21 patients, including one patient with clinically definite MS. The presence of upper motor neurone signs has also been noted in 13/150 patients seen in a post-polio clinic.⁹

These included corticobulbar swallowing difficulties, spastic paraparesis, hyperreflexia and extensor plantar responses. The cause of these signs was attributed to a polioencephalitis accompanying the original poliomyelitis or as part of the progressive post-polio syndrome. Martyn *et al*^{10,11} argue that subclinical infection with poliomyelitis might be severe enough to deplete motor neurones and that motor neurone disease might then develop as a consequence of further motor neurone loss due to ageing or a second insult. However, analysis of morbidity and mortality rates for motor neurone disease in Scotland shows no evidence that motor neurone disease is caused by early asymptomatic polio infection or that polio vaccination offers protection against this condition.¹² Furthermore in a literature review Armon *et al*¹³ suggested the paucity of reports of classical amyotrophic lateral sclerosis developing in survivors of paralytic poliomyelitis might indicate that antecedent poliomyelitis has a protective role against the development of amyotrophic lateral sclerosis.

The occurrence of MS in these patients emphasises that late functional deterioration apparently may be unrelated to previous poliomyelitis. Furthermore characteristic clinical features may be masked by the severe pre-existing neuromuscular and orthopaedic impairment leading to diagnostic delay and confusion with the ill-defined clinical syndrome of progressive post-polio muscular atrophy.

- 1 Dalakas MC, Elder G, Hallett M, *et al*. A long-term follow-up study of patients with post-poliomyelitis neuromuscular syndromes. *N Engl J Med* 1986; 314: 959-63.
- 2 Howard RS, Wiles CM, Spencer GT. The late sequelae of poliomyelitis. *Q J Med* 1988; 251: 219-32.
- 3 McDonald WI, Silberberg DH. The diagnosis of multiple sclerosis. In: WI McDonald, DA Silberberg, eds. *Multiple sclerosis*. London: Butterworth, 1986; pp 1-11.
- 4 Thompson AJ, Kermod AG, MacManus DG, *et al*. Patterns of disease activity in multiple sclerosis: clinical and magnetic resonance imaging study. *BMJ* 1990; 300: 631-4.
- 5 Pezeshkpour GH, Dalakas MC. Long term changes in the spinal cords of patients with old poliomyelitis: signs of continuous disease activity. *Arch Neurol* 1988; 45: 505-8.
- 6 Feve A, Wallays C, Nicolle MH, Guillard A. Syringomyelia as a late complication of paralytic poliomyelitis. *Neurology* 1992; 42: 1421-2.
- 7 Carroll SD. Syringomyelia as a possible complication of poliomyelitis. *Neurology* 1967; 17: 213-5.

- 8 Salazar-Grueso EF, Grimaldi LME, Roos RP, Variakojis R, Jubelt B, Cashman NR. Isoelectric focusing studies of serum and cerebrospinal fluid in patients with antecedent poliomyelitis. *Ann Neurol* 1989; 26: 709-13.
- 9 Salazar-Grueso EF, Cashman NR, Maselli R, Roos RP. Upper motor neurone (UMN) findings in patients with antecedent poliomyelitis. *Neurology* 1987; 37: 215.
- 10 Martyn CN, Barker DJP, Osmond C. Motoneurone disease and postpoliomyelitis in England and Wales. *Lancet* 1988; i: 1319-22.
- 11 Martyn CN. Poliovirus and motor neurone disease. *J Neurol* 1990; 237: 336-8.
- 12 Swingler RJ, Fraser H, Warlow CP. Motor neurone disease and polio in Scotland. *J Neurol Neurosurg Psychiatry* 1992; 55: 1116-20.
- 13 Armon C, Daube JR, Windebank AJ, Kurland LT. How frequently does classic amyotrophic lateral sclerosis develop in survivors of poliomyelitis? *Neurology* 1990; 40: 172-4.