

IgA nephropathy in hereditary angioedema

Jayashri Srinivasan and Peter Beck

Department of Medicine, Llandough Hospital, Penarth, South Glamorgan CF6 1XX, UK

Summary: Hereditary angioedema is an autosomal dominant disorder of the complement system in which there is a deficiency of the inhibitor of the activated first component of complement. We have previously reported on three generations of a family with classic hereditary angioedema. Three members of this family have now developed IgA nephropathy. The association of hereditary angioedema with various immunoregulatory disorders has been previously reported but this is the first report of IgA nephropathy in association with this condition.

Introduction

Hereditary angioedema is an inherited disorder in which there is a quantitative or functional deficiency of the inhibitor of the activated first component of complement, C1 inhibitor (C1-INH). It is characterized by recurrent attacks of non-pitting oedema of the extremities, face, larynx and abdomen including the bowel mucosa. An association of hereditary angioedema with various immunoregulatory disorders including systemic lupus erythematosus, lupus-like disease, Sjögren's syndrome, autoimmune thyroid disease, inflammatory bowel disorder,¹ IgA deficiency,² mesangiocapillary glomerulonephritis³ and coronary arteritis⁴ has been described. The use of the attenuated androgen danazol in preventing recurrent attacks of angioedema in hereditary angioedema was first described in 1976⁵ and this drug is widely used as long-term maintenance therapy in this condition. IgA nephropathy, one of the commonest forms of nephropathy, is characterized by recurrent attacks of gross or microscopic haematuria and is diagnosed on renal biopsy by the presence of prominent IgA deposits in the mesangium by immunofluorescent techniques. We describe three members of a family with hereditary angioedema on danazol prophylaxis who have developed IgA nephropathy, an association not previously reported.

The family

The pedigree of the family is shown in Figure 1 and has been described in some detail in a family study of hereditary angio-neurotic oedema.⁶ In this

report, case 1 appears at IV.2, case 2 at III.2, and cases 3 and 4 at IV.3 and IV.4, respectively.

Following the presentation of case 1 with painless haematuria in 1989, and the discovery that this was due to IgA nephropathy, we decided to review the other members of the family for haematuria and to check their renal function.

Case reports

Case 1

A 19 year old Caucasian male presented in 1973 with recurrent attacks of abdominal colic, facial and laryngeal oedema. He was diagnosed as having classic hereditary angioedema as his serum C1 inhibitor and C4 were low and he had a positive family history, his grandmother and father being known to have hereditary angioedema. An attack of severe laryngeal oedema in 1978 required temporary tracheotomy and ventilation. After initial

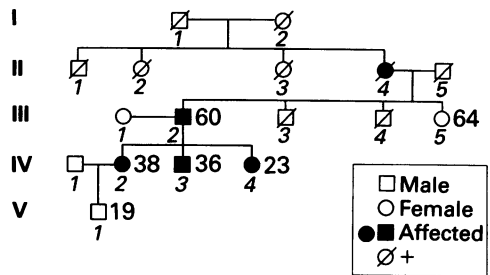


Figure 1 Family pedigree: 'affected' refers to hereditary angioedema. Cases 1–4 are IV.2, III.2, IV.3 and IV.4, respectively.

Correspondence: P. Beck, M.A., M.D., F.R.C.P.
Accepted: 21 July 1992

prophylaxis with epsilon amino caproic acid, he was switched to androgen therapy. He was started on danazol in 1982 and this resulted in a dramatic improvement in his symptoms; he has had no documented attacks of angioedema since 1983. In 1989, at the age of 35 he presented with a 3 month history of intermittent painless haematuria and low back pain. Investigations included microscopic examination of his urine which revealed 30 red blood cells per high-power field, the majority of which were dysmorphic; urinary casts or white blood cells were not seen and no organisms were isolated on culture. Plasma urea and electrolytes, creatinine and full blood count were normal. His glomerular filtration rate measured by creatinine clearance was 102 ml/min; he had proteinuria of 4.2 g/l with a selectivity index of 0.13. Complement profile revealed a low serum C4 and C1 inhibitor with a normal C3. His serum immunoglobulins including IgA were normal and auto-antibodies were not detected. Renal biopsy showed glomerular mesangial proliferation and thickening with some segmental accentuation; the tubules showed patchy atrophy and there was an associated mild focal interstitial inflammatory infiltrate. Immunofluorescence showed strong mesangial staining for IgA with associated C3 extending into the glomerular basement membrane, diagnostic of IgA nephropathy. His renal function has remained stable over the last year and apart from occasional haematuria he has remained asymptomatic.

Case 2

Patient 2, who is the father of patient 1, had recurrent symptoms of abdominal pain, laryngeal and cutaneous oedema since the age of 5 and he was diagnosed as having hereditary angioedema in 1969 when aged 41. He had recurrent symptoms from his angioedema until he was commenced on danazol in 1982 and he has had no serious attacks of angioedema since. He initially noticed haematuria in 1981 and had been under the care of a urologist and various investigations including intravenous urography and cystoscopy revealed no abnormality. He continued to have episodic haematuria but remained quite well. Following the diagnosis of IgA nephropathy in his son, further investigations were undertaken; his plasma urea and electrolytes, creatinine and full blood count were normal; urinalysis showed microscopic haematuria but no significant proteinuria. Immunoelectrophoresis including serum IgA was normal; autoantibody screen was negative and complement profile showed reduced C1 esterase inhibitor, C4 and C2. Renal biopsy showed immunofluorescence features consistent with IgA nephropathy, that is, focal IgA with C3 and fibrinogen

deposition in the mesangium. He continues to have occasional haematuria but his plasma urea, electrolytes and creatinine are normal and he remains well.

Case 3

Patient 3 is the sister of the first patient and the daughter of the second. She was diagnosed as having C1 inhibitor deficiency in 1967 but only began to develop troublesome symptoms of angioedema in 1971 during pregnancy. She was initially started on epsilon amino caproic acid and once she had completed her family she was started on danazol in 1983. Apart from a few mild attacks of angioedema she has remained well. Following the diagnosis of IgA nephropathy in her family she was investigated. She did not give a history of haematuria but urinalysis showed microscopic haematuria with no significant proteinuria; her urea, electrolytes and creatinine, full blood count, serum IgA were normal; autoantibody screen was negative and complement profile was consistent with hereditary angioedema. Renal biopsy was diagnostic of IgA nephropathy. She continues to be asymptomatic, her renal biochemistry remains normal and she has noticed no macroscopic haematuria.

Case 4

Patient 4 is another sister of the first patient and the daughter of the second. She had mild cutaneous oedema at the age of 24 during her first pregnancy in 1990 and serum complement analysis confirmed the diagnosis of C1 inhibitor deficiency and hereditary angioedema. Her symptoms are mild and she is not on any prophylactic therapy. She does not give a history of haematuria and her urinalysis was normal. Her serum urea and electrolytes, creatinine, full blood count and serum IgA were normal and autoantibody screen was negative. In the absence of signs or symptoms of nephropathy she was not offered a renal biopsy.

Although there is no evidence of linkage between hereditary angioedema and HLA phenotypes,⁷ occasional HLA associations with IgA nephropathy have been reported.^{8,9} The HLA phenotypes of this family were therefore examined and the results are given here:

- Case 1 (IV.2) HLA-A2,11;B51,W60;Cw3,X;DR1,W13;DQw1
- Case 2 (III.2) HLA-A2,X;B51,W50;Cw6,X;DR1,7;DQw1,2
- Case 3 (IV.3) HLA-A2,29;B51,44;CwX;DR1,7;DQw1,2
- Case 4 (IV.4) HLA-A2,29;B51,44;CwX;DR1,7;DQw1,2

Discussion

Angioneurotic oedema (as it was then called) was first described in 1881 by Quincke and its familial incidence was reported by Sir William Osler in 1888.¹⁰ A deficiency of C1 inhibitor was recognized to be the pathological basis of the disorder in 1963¹¹ and an acquired form was described in 1972.¹²

Hereditary angioedema (HAE) is inherited as an autosomal co-dominant trait with equal sex and racial distribution. Major advances in understanding the molecular and genetic basis of the disease have been made in recent years and are well summarized in a recent review by Oltvai and colleagues.¹³ The C1 inhibitor gene has been localized to chromosome 11 (q11–q13) and the underlying molecular pathology relates to changes in the DNA sequence of one allele, with a predisposition of the gene to deletions and insertions being proposed.

Two types of hereditary angioedema have been described;¹⁴ the common Type I, which affects approximately 85% of patients, is characterized by a quantitative deficiency of structurally and functionally normal C1 inhibitor and the variant Type II, affecting 15%, has a quantitative defect of inhibitor function, although the actual circulating levels may be normal or even slightly elevated. In the Type I disorder the deficiency appears to be due to an apparent lack of function of the one C1 inhibitor allele in the genome. Restriction fragment length polymorphism (RFLP) analysis has shown that this co-segregates with the disease in those families in whom it is detected but an abnormal RFLP is found in only 15–12% of Type I patients and partial deletions or insertions within the C1 inhibitor gene have been found in most of them. In the Type II cases, various point mutations affecting the active binding site of the enzyme have been described.¹³

As well as angioedema due to inherited C1 inhibitor deficiency, a similar clinical syndrome occurring in older patients, with no family history, has been described.¹⁵ Subsequent studies have shown that there are also two types of the acquired disorder, the more common being found in patients with B cell lympho-proliferative disorders where antibodies to C1 inhibitor appear to arise through molecular mimicry with anti-idiotypic antibodies while, rarely, autoantibodies directed against an epitope very adjacent to the active binding site of the protein have been described with no associated lympho-proliferative disorder.¹³

The C1 inhibitor protein is a member of the serine inhibitors ('serpins') whose main target proteases are the C1r and C1s subunits of the C1 complex and, although inhibition of plasmin, kallikrein, factor XI and factor XII occurs, only inhibition of C1, Factor XII and kallikrein are

thought to be physiologically important.¹³

The mechanism of the production of angioedema in the presence of C1 inhibitor deficiency is still something of an enigma. Various theories exist involving the cleavage of the C1 complex, either spontaneously or via Factor XII activation (which later can activate C1 directly or via plasmin) leading to generation of kinin-like peptides, possibly derived from, and certainly requiring C2; or via the production of bradykinin via kallikrein and high molecular weight kininogen.^{13,16–18}

Various immunoregulatory disorders have been associated with hereditary angioedema including system lupus erythematosus, thyroiditis, Sjögren's syndrome, inflammatory bowel disease, IgA deficiency,² coronary arteritis⁴ and with mesangiocapillary nephritis.³ The increased incidence of these diseases in patients with hereditary angioedema remains unexplained. Complement is involved in immune clearance, immunoregulation, viral lysis and immune complex solubilization.¹⁹ The latter is thought to be an important function of the complement system and failure of solubilization of immune complexes could result in their deposition in tissues and lead to such immunoregulatory disorders. Hereditary angioedema is not HLA linked⁷ and it has been reported that the patients with hereditary angioedema who developed autoimmune diseases did not share one particular HLA or DR type but rather developed the autoimmune disease known to be associated with their particular haplotype.¹ Therefore it appears that additional predisposing factors such as HLA haplotype were required for the development of autoimmune diseases in patients with hereditary angioedema.

The role of androgen therapy in reducing the frequency and the severity of acute attacks in hereditary angioedema is well established and attenuated androgens such as danazol form the mainstay of prophylaxis in hereditary angioedema.⁵ Danazol increases the serum levels of C1 inhibitor in all phenotypes of this condition presumably because the androgen increases the synthesis of the deficient or defective protein. Long-term danazol has been shown to be associated with various adverse effects including neuromuscular dysfunction, headaches, transient elevation of hepatic enzymes, menstrual irregularities in women and of particular relevance to this case, microscopic haematuria.¹² In this study, 13% of patients with hereditary angioedema on long-term therapy with danazol developed haematuria without impairment of renal function. Haemorrhagic cystitis was found to be present in some of these and in two patients renal biopsy revealed mild mesangial proliferation. The haematuria resolved with reduction of the dose of danazol.

Another study,¹ looking into the clinical immunoregulatory diseases associated with hereditary angioedema, found that in the majority any urinary abnormality – haematuria, active urinary sediment and proteinuria – developed before starting danazol therapy. This study also reported on five patients with renal disease associated with hereditary angioedema; four of these patients developed the urinary abnormality before danazol therapy was instituted. Renal biopsy showed membraneproliferative glomerulonephritis in two and mild mesangial disease in the other three but in no case was IgA nephropathy found. Danazol therapy has been definitively associated with haematuria, but not with IgA nephropathy. On the contrary danazol has been used in the treatment of IgA nephropathy and one study has shown that danazol may increase the solubilization of glomerular immune complexes and reduce proteinuria in IgA nephropathy.²⁰

IgA nephropathy was first described by Berger and Hinglais in 1968²¹ and it is now thought to be one of the commonest forms of glomerulonephritis.²² The diagnostic immunopathologic pattern is the presence of mesangial deposits of IgA with C3 and properdin and sometimes other immunoglobulins, IgM and IgG. The pathogenesis of IgA nephropathy is not known but IgA containing immune complexes of IgA aggregates are thought to be involved. Their deposition in the renal mesangium followed by complement activation and release of other mediators including proteases and prostaglandins are postulated to mediate the glomerular injury.²³ There is considerable evidence for the role of complement in the pathogenesis of IgA nephropathy. The finding of the alternative pathway component properdin with C3 and membrane attack complex (C5b-9), with the relative absence of the classical pathway components C1q and C4, has been suggested as evidence for the importance of alternative pathway activation in the pathogenesis of IgA nephropathy.²³ A genetic predisposition of IgA nephropathy has been suggested by the familial clustering of the disease noticed by some studies.²⁴ No HLA haplotype has consistently been associated with IgA nephropathy, although in some countries, primarily Japan and France, an association with HLA DR4 and B35, respectively, has been

reported.^{8,9} as reported above, none of our patients showed these HLA haplotypes.

This is the first report of IgA nephropathy occurring in association with hereditary angioedema. In this family with hereditary angioedema and IgA nephropathy it is possible that the complement deficiency predisposed to the development of this disease. IgA nephropathy has been reported in three patients with a familial partial deficiency of a single complement protein – C2, properdin or H.²⁵ An increased frequency of the homozygous C4 null phenotype has been described in some patients with IgA nephropathy.¹³ Complement is involved in various immunological processes including immunoregulation, immune clearance and immune complex solubilization and it has been suggested that these partial complement deficiencies inhibit the clearance of normally innocuous IgA-containing immune complexes from the circulation or the glomerular mesangium.¹⁵ The deficiency of the early components of the classical complement pathway that occurs in hereditary angioedema has been associated with various autoimmune diseases, although the mechanisms of this association is poorly defined. Although the complement activation in IgA nephropathy is thought to be predominantly via the alternative pathway, there is some evidence that classical pathway activation may not be uncommon.²³ The occurrence of IgA nephropathy in this family with hereditary angioedema may therefore imply a greater role for classical complement pathway activation in the pathogenesis of this nephropathy.

We think that the occurrence of IgA nephropathy in this family with hereditary angioedema is unlikely to be a coincidence. In our opinion it is likely that the underlying complement deficiency predisposed to its occurrence and we suggest that IgA nephropathy be added to the list of immunoregulatory disorders associated with hereditary angioedema.

Acknowledgements

We are grateful to Dr David Fisher of Cardiff Royal Infirmary for performing the renal biopsies and to Dr David Griffiths, Cardiff Royal Infirmary, for the pathology reports.

References

1. Brickman, C.M., Tsokos, G.C., Balow, J.E. *et al.* Immunoregulatory disorders associated with hereditary angioedema. 1. Clinical manifestations of autoimmune disease. *J Allergy Clin Immunol* 1986, **77**: 749–757.
2. Bond, W.R., Herrod, H.G. & Duberstein, L.E. Hereditary angioedema: association with IgA deficiency and otolaryngologic disorders. *Laryngoscope* 1981, **91**: 417–421.
3. Plaza, J., Malasit, P. & Kerr, D.N.S. Hereditary angioedema with mesangiocapillary glomerulonephritis. *Postgrad Med J* 1977, **53**: 627–630.
4. Harrington, T.M., Torretti, D., Pytko, V.F. & Plotkin, G.R. Hereditary angioedema and coronary arteritis. *Am J Med Sci* 1984, **287**: 50–52.

5. Gelfand, J.A., Sherins, R.J., Alling, D.W. & Frank, M.M. Treatment of hereditary angioedema with danazol: reversal of clinical and biochemical abnormalities. *N Engl J Med* 1976, **295**: 1444–1448.
6. Beck, P., Wills, D., Davies, G.T., Lachmann, P.J. & Sussman, M. A family study of hereditary angioedema. *Q J Med* 1973, **166**: 317–339.
7. Tiwari, J.L. & Terasaki, P.I. *HLA and Disease Associations*. Springer Verlag, New York, 1985, p. 455.
8. Hiki, Y., Kobayashi, Y., Tateno, S. *et al.* Strong association of HLA DR4 with benign IgA nephropathy. *Nephron* 1982, **32**: 222–226.
9. Berthoux, F.C., Genin, C., LePetit, J.C. *et al.* Immunogenetique des glomerulonephrites a depts d'IgA. *Nephrologie* 1983, **4**: 283–287.
10. Osler, W. Hereditary angio-neurotic oedema. *Am J Med Sci* 1988, **95**: 362–372.
11. Donaldson, V.H. & Evans, R.R. A biochemical abnormality in hereditary angioedema: absence of serum inhibitor of C1 esterase. *Am J Med* 1963, **35**: 37–44.
12. Hosea, S.W., Santaella, M.L., Brown, E.J. *et al.* Long term therapy of hereditary angioedema with danazol. *Ann Intern Med* 1980, **93**: 809–812.
13. Oltvai, Z.N., Wong, E.C.C., Atkinson, J.P. & Tung, K.S.K. C1 inhibitor deficiency: molecular and immunologic basis of hereditary and acquired angioedema. *Lab Invest* 1991, **65**: 381–388.
14. Rosen, F.S., Charache, P., Pensky, J. & Donaldson, V. Hereditary angioedema: two genetic variants. *Science* 1965, **148**: 957–958.
15. Caldwell, J.R., Ruddy, S., Schur, P.H. & Austen, K.F. Acquired C1 inhibitor deficiency in lymphosarcoma. *Clin Immunol Immunopath* 1972, **1**: 39–42.
16. Donaldson, V.H., Ratnoff, O.D., Da Silva, W.D. & Rosen, F.S. Permeability increasing activity in hereditary angio-neurotic oedema plasma. II. Mechanism of formation of and partial characterisation. *J Clin Invest* 1969, **48**: 642–653.
17. Schapira, M., Silver, L.D., Scott, C.F. *et al.* Prekallikrein activation and high molecular weight kininogen consumption in hereditary angioedema. *N Engl J Med* 1983, **308**: 1050–1053.
18. Fields, T., Ghebrehiwet, B. & Kaplan, A.P. Kinin formation in hereditary angioedema plasma: evidence against kinin derivation from C2 and in support of spontaneous formation of bradykinin. *J Allergy Clin Immunol* 1983, **72**: 54–60.
19. Kijlstra, A., Van Es, L.A. & Daha, M.R. Effects of C1 on the size of soluble immune aggregates and their processing by macrophages. *J Immunol* 1979, **123**: 640–645.
20. Tomino, Y., Sakai, H., Miura, M. *et al.* Effect of danazol on solubilisation of immune deposits in patients with IgA nephropathy. *Am J Kidney Dis* 1984, **IV** (2): 135–140.
21. Berger, J. & Hinglais, N. Les depots intracapillaires d'IgA-IgG. *J Urol Nephrol* 1968, **74**: 694–695.
22. D'Amico, G. The commonest glomerulonephritis in the world: IgA nephropathy. *Q J Med* 1987, **245**: 709–727.
23. Wyatt, R.J. & Julian, B.A. Activation of complement in IgA nephropathy. *Am J Kidney Dis* 1988, **5**: 437–442.
24. Julian, B.J., Quiggins, P.A., Thompson, J.S. *et al.* Familial IgA nephropathy. *N Engl J Med* 1985, **312**: 202–208.
25. Wyatt, R.J., Julian, B.A., Bhathena, D. *et al.* IgA nephropathy: presentation, clinical course and prognosis in children and adults. *Am J Kidney Dis* 1984, **4**: 192–200.