

PAPERS

Rheumatic symptoms in primary hyperparathyroidism

M. HELLIWELL
M.B., M.R.C.P.

Department of Rheumatology, Salisbury General Infirmary, Fisherton Street, Salisbury, Wiltshire

Summary

In a retrospective survey of 34 patients with primary hyperparathyroidism (HPT), 18 (53%) complained of musculo-skeletal symptoms during the 12 months before the diagnosis was made and 9 (26%) attended at some time for either a rheumatological or orthopaedic consultation. Myalgia was the most frequently reported symptom which occurred in 41% of patients. Arthralgia, mainly affecting the large joints was present in 11 (32%) patients, 2 of whom had an erosive synovitis mimicking rheumatoid arthritis. Radiological abnormalities were seen in 8 patients. Clinicians should be aware of the variety and frequency of musculo-skeletal symptoms associated with HPT and should consider including serum calcium measurements when investigating rheumatic complaints.

KEY WORDS: hyperparathyroidism, myalgia, arthralgia.

Introduction

Primary hyperparathyroidism (HPT) is now thought to be a relatively common condition with an estimated prevalence of around 0.1% in adults (Watson, 1974). Renal symptoms are by far the commonest form of presentation although musculo-skeletal complaints, usually diffuse aches and pains, occur in 14-16% of cases (Watson, 1974; Pyrah, Hodgkinson and Anderson, 1966). Several authors have drawn attention to specific rheumatic disorders in HPT, which include an erosive arthritis (Bywaters, Dixon and Scott, 1968; Resnick, 1974), periarticular calcification with inflammation (Zvaifler, Reeve and Black, 1962) and co-existing gouty arthritis (Scott, Dixon and Bywaters, 1964). However, the true incidence of these and other rheumatic conditions associated with HPT remains unknown as most series have either consisted of selected case reports or have been confined to one particular aspect of joint disease

such as chondrocalcinosis (Glass and Grahame, 1976). The purpose of this study was to examine the overall frequency and nature of rheumatic disorders in a group of patients with HPT presenting to a district general hospital, and also to determine the effect of treatment.

Patients and methods

The hospital records of 34 patients with proven primary HPT who presented to the Salisbury Group Hospitals in the 10 year period 1972-1982 were studied in detail. All patients had been indexed by the Chemical Pathology Department on referral for investigation of hypercalcaemia. The patients comprised 27 females and 7 males, aged 26 to 82 years (mean age 54.7 years) at the time of diagnosis. Existing X-rays were traced and relevant films examined. In addition, a questionnaire with special reference to musculo-skeletal complaints and the response to parathyroidectomy was sent to the 28 patients still living; 22 patients replied. Rheumatic symptoms which had been present only in the 12 month period preceding the diagnosis of HPT were considered to be of significance.

Of the 34 patients identified, all had persistent hypercalcaemia with serum calcium levels ranging from 2.64 mmol/litre to 4.52 mmol/litre (mean 3.02 mmol/litre). Parathyroid hormone (PTH) assays were performed in 20 cases; without exception these values were either absolutely or inappropriately raised. Thirty patients underwent surgical exploration of the parathyroid glands. Single adenomas were found in 28 cases and multiple in one. A further patient had a parathyroid carcinoma. Three patients did not have operations because of their age or general ill-health. The remaining patient is awaiting neck exploration.

Results

Pre-existing medical conditions were present in 6 patients of whom one had an established diagnosis of seropositive rheumatoid arthritis (RA). This patient had an apparent deterioration of her rheumatoid disease with a marked decrease in grip-strength recordings which coincided with the development of hypercalcaemia. However, for the purpose of this study, the worsening of joint symptoms and the presence of bone erosions on X-ray were judged to be solely due to rheumatoid arthritis. One patient had co-existing thyrotoxicosis, diabetes mellitus and a carcinoid tumour. Thyroid disease was present in a further 2 patients and the remaining 2 had coeliac disease and discoid lupus erythematosus respectively.

Musculo-skeletal symptoms (Table 1)

Myalgia was the most common rheumatic symptom and occurred in 14 (41%) patients. In virtually all cases, the muscle pains affected the proximal muscles of both the upper and lower limbs. In 3 patients, the combination of shoulder pains, upper arm tenderness and malaise led to a provisional diagnosis of polymyalgia rheumatica before the discovery of hypercalcaemia. However, all 3 subjects were below 55 years of age and in none was the erythrocyte sedimentation rate (ESR) raised. Proximal muscle weakness was present in 10 (29%) patients and was usually associated with myalgia. The occurrence and severity of muscle symptoms did not correlate with the degree of hypercalcaemia.

TABLE 1. The nature, frequency and distribution of symptoms in 18 patients with rheumatic complaints associated with primary hyperparathyroidism

Musculo-skeletal symptoms	Number of patients
Muscle pains	14 (41%)
Muscle weakness	10 (29%)
Arthralgia	11 (32%)
Knees	7
Wrists	3
Shoulder	3
Hands*	2
Ankles	2
Hip	1
Feet	1
Joint effusions (knees)	1
Carpal tunnel syndrome	2
Gout	2

*Two patients with erosive synovitis.

Eleven (32%) patients suffered with arthralgia. The distribution of the affected joints is shown in Table 1. In 3 patients, raised ESR values made the distinction from rheumatoid arthritis difficult despite negative latex tests.

Two patients had symptoms which suggested a

carpal tunnel syndrome. These symptoms persisted following parathyroidectomy and both came to surgical decompression. In neither was there evidence of chondrocalcinosis of the wrist. One patient presented with gout and was found to have hypercalcaemia and renal failure. Postoperatively another patient suffered an episode of acute pain in the right first metatarsophalangeal joint which responded to colchicine. Both patients had raised serum urate levels.

In all, 9 patients attended for a rheumatological or orthopaedic consultation during the 12 month period preceding the diagnosis of hypercalcaemia. Of 15 patients with musculo-skeletal complaints who returned the questionnaire forms, 11 improved following parathyroidectomy. Myalgia was the principal complaint and in the majority of cases the response following surgery was dramatic. In 3 patients, arthralgia was unrelieved and has worsened. Two of these patients had radiological evidence of chondrocalcinosis while the third now has clinical and serological evidence of systemic lupus erythematosus, 2 years after her operation. The remaining patient did not have surgery and continues to have mild muscle pains.

Radiological findings

X-rays were available for review in 21 patients. Twenty patients had hand X-rays and abnormalities were seen in 8 (Table 2). Subperiosteal resorption of the phalanges was an uncommon feature, being present in only 2 cases. Multiple bony cysts suggesting osteitis fibrosa cystica were seen in one patient. Five out of the seven patients with pains in the knees had X-rays of these joints; chondrocalcinosis (Fig. 1) was visible in two.

TABLE 2. Radiological findings in 21 patients with primary hyperparathyroidism whose X-rays were available for scrutiny

Radiological appearances	Number of patients
Hand X-rays	
Demineralisation of bone	2
Bone erosions	2
Subperiosteal bone resorption	2
Cystic changes	1
Chondrocalcinosis (wrist)	1
Other findings	
Chondrocalcinosis—knees	2
—pubic symphysis	1
Ligament calcification	1

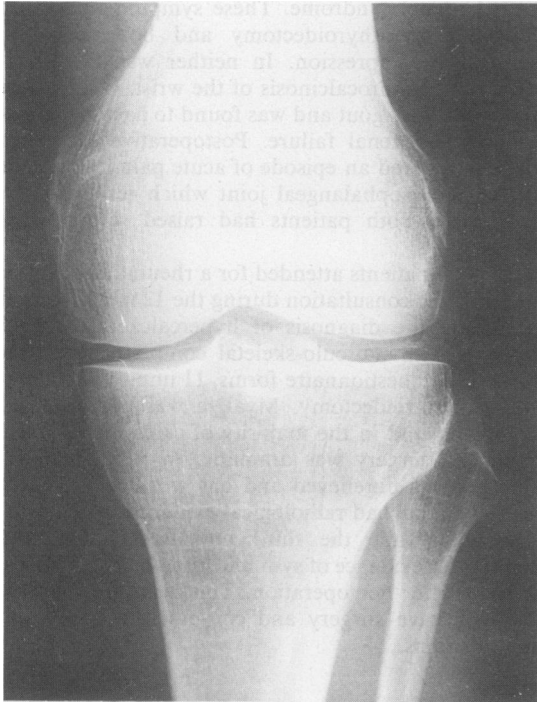


FIG. 1. Chondrocalcinosis, most pronounced in the lateral compartment of the left knee.

Biochemical findings

Evidence of renal impairment, judged by a raised serum urea and creatinine, was present in 9 (26%) patients. Twenty-one patients had measurement of serum uric acid concentrations, which were raised (greater than 0.42 mmol/litre) in 10 (47%). In 4 patients with hyperuricaemia, the renal function was normal. Elevated alkaline phosphatase values (greater than 90 u./l) occurred in 11 (32%) cases, of whom 7 had rheumatic symptoms or radiological bone disease.

Among the patients with joint symptoms, 2 had clinical synovitis with radiological evidence of bone erosions; one such case is described.

Case report

A 55-year-old woman presented in September 1976 with a 6 week history of pain and swelling of both knees and the metacarpophalangeal (MCP) joints of the left hand with morning stiffness of one hour. On examination there was synovitis of the index and middle finger MCP joints and effusions of both knees. No nodules were palpable. Cultures of the knee aspirates were negative and no crystals were

seen on polarising light microscopy. Initial investigations showed ESR 63 mm/hr with negative latex and antinuclear factor tests. X-rays of the hands showed erosions at the base of the proximal phalanx of the left index finger (Fig. 2). An initial diagnosis of rheumatoid arthritis was made and the patient was treated with aspirin. One month later, she was admitted with pain and instability of the right knee which, on X-ray, showed upward displacement of the patella with calcification in the inferior patella ligament (Fig. 3). At operation, there was separation of the ligament from the inferior pole of the patella and this was repaired. Hypertrophy of the synovium was also noted and biopsies showed changes of a non-specific chronic synovitis. Further biochemical investigations revealed hypercalcaemia (serum calcium 4.12 mmol/litre), a raised alkaline phosphatase and renal impairment; 2 subsequent PTH assays were both markedly elevated. In March 1977, she underwent exploration of the parathyroid glands and a large right inferior adenoma was removed. Since operation, she has experienced no further joint symptoms although her renal function has deteriorated.

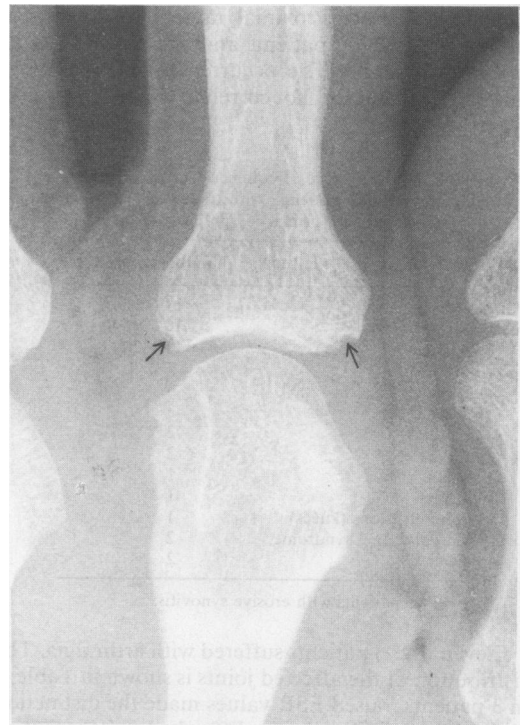


FIG. 2. Small erosions at the base of the proximal phalanx of the left index finger (arrowed).

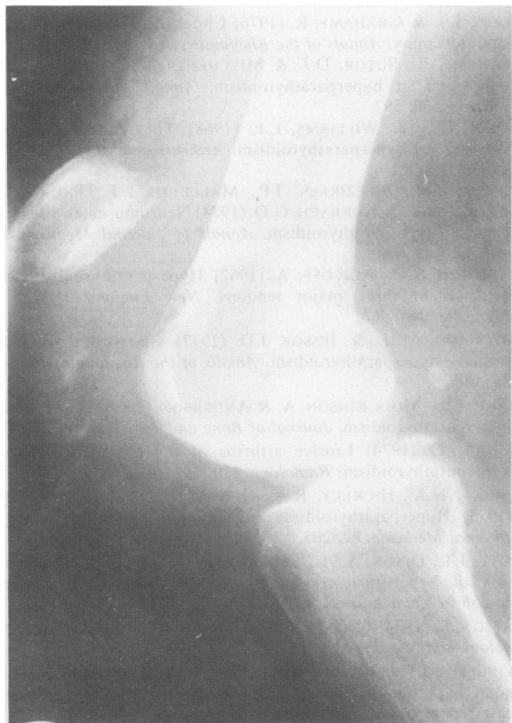


FIG. 3. Displacement of the patella with calcification in the inferior patella ligament.

Discussion

This study emphasises the frequency with which rheumatic complaints occur in HPT. Although the survey was retrospective, it was possible to substantiate the accuracy of case notes by postal questionnaire in 22 of the 28 patients still alive. Furthermore, 10 patients with articular symptoms as their main complaint have been followed up personally by the author. Diffuse muscle and joint pains predominated, but a small proportion of patients presented with musculo-skeletal manifestations which were initially difficult to distinguish from other rheumatic diseases. The association of an erosive arthritis is well recognised and may simulate rheumatoid arthritis (Bywaters *et al.*, 1968; Resnick, 1974). Furthermore, HPT and rheumatoid arthritis may coexist (Lipson and Williams 1968; Crisp, Helliwell and Grahame, 1982) with an apparent worsening of the rheumatoid process suggesting a possible adverse effect of excessive PTH. Bywaters and his colleagues (1968) described 3 patients who presented with erosive bone disease and knee effusions. Histology of these erosions showed subchondral bone microfractures and collapse and it was suggested that the effusions were

a consequence of traumatic synovitis. However, in a further 19 cases briefly reported in the same series, 5 patients had ESR values of greater than 20 mm/hr. In this study, both the patients with bone erosions had an elevated ESR and in one a synovial biopsy showed changes of a chronic synovitis, suggesting an inflammatory element in the pathogenesis of these lesions. Ligament or tendon calcification with avulsion, which developed in one patient, has been noted previously (Preston and Adicoff, 1962) and is most likely due to bone resorption at the sites of attachment rather than the deleterious effect of PTH on these structures.

The reported incidence of muscle disorders in HPT varies considerably. In one prospective study, Patten *et al.* (1974) found weakness, fatiguability and muscle atrophy in 14 out of 16 patients. In addition, 6 patients complained of muscle pains. As in the present study, the severity of muscle symptoms bore no relation to the serum calcium levels and all patients described a subjective improvement within a few days following parathyroidectomy. A major finding on muscle biopsy was of atrophy of muscle fibres suggesting an accompanying neuropathic lesion. Others (Frame *et al.*, 1968), have reported muscle necrosis with an inflammatory infiltrate consistent with myositis.

Chondrocalcinosis has been reported in up to 40% of patients with HPT and may account for the arthralgia experienced by some subjects. Glass and Grahame (1976) found that only 2 out of 12 patients with joint symptoms improved following parathyroidectomy and that in some cases symptomatic chondrocalcinosis first appeared some time after operation. The reason for this is unclear, although the later development of chondrocalcinosis does not seem to be related to pre-operative serum calcium levels (Pritchard and Jessop, 1977). Acute synovitis due to pyrophosphate arthropathy is considered to be a rare phenomenon (Glass and Grahame, 1976; Pritchard and Jessop, 1977) but may be precipitated by parathyroidectomy (Bilezikian *et al.*, 1973).

There have been several reports of hyperuricaemia and gout in HPT. In one series of 12 patients, 11 were hyperuricaemic and 5 had clinical gout (Scott, Dixon and Bywaters, 1964). In not all cases was hyperuricaemia explicable by renal impairment and it was suggested that calcium deposition within the renal tubules was responsible for impaired uric acid secretion. Subsequently Grahame, Sutor and Mitchener (1971) were able to demonstrate the deposition of calcium pyrophosphate crystals in the renal substance of a patient with HPT.

Only one case of carpal tunnel syndrome and HPT has been reported previously in a patient with extensive chondrocalcinosis of the wrist (Weinstein, Dick and Grantham, 1968). Both patients reported

here had no radiological evidence of chondrocalcinosis, suggesting a purely fortuitous relationship between the 2 conditions. Lastly, it is of interest to note that the co-existence of thyroid disease and carcinoid tumour with HPT has been previously described (Ackerman and Arribas, 1976; Samaan *et al.*, 1975).

In conclusion, the recognition of the rheumatic manifestations of HPT is of some importance as many of the symptoms are curable by parathyroidectomy. HPT deserves consideration in the differential diagnosis of musculo-skeletal conditions.

Acknowledgments

I am indebted to Dr J. R. H. Pinkerton and Dr G. F. Batstone for access to their diagnostic files.

References

- ACKERMAN, N.B. & ARRIBAS, R.F. (1976) Hyperparathyroidism and co-existing hyperthyroidism. *American Journal of Surgery*, **132**, 660.
- BILEZIKIAN, J.P., CONNOR, D.B., APTKAR, R., FREIJANES, J., AURBACH, G.D., PACHES, W.N., WELLS, S.A. & DECK, J.R. (1973) Pseudogout after parathyroidectomy. *Lancet*, **i**, 445.
- BYWATERS, E.G.L., DIXON, A.ST.J. & SCOTT, J.T. (1968) Joint lesions of hyperparathyroidism. *Annals of the Rheumatic Diseases*, **22**, 171.
- CRISP, A.J., HELLIWELL, M. & GRAHAME, R. (1982) The effect of primary hyperparathyroidism on the course of rheumatoid arthritis. *Rheumatology and Rehabilitation*, (in press).
- FRAME, B., HEINZE, E.G., BLOCK, M.A. & MANSON, G.A. (1968) Myopathy in primary hyperparathyroidism. *Annals of Internal Medicine*, **68**, 1022.
- GLASS, J.S. & GRAHAME, R. (1976) Chondrocalcinosis after parathyroidectomy. *Annals of the Rheumatic Diseases*, **35**, 521.
- GRAHAME, R., SUTOR, D.J. & MITCHENER, M.G. (1971) Crystal deposition in hyperparathyroidism. *Annals of the Rheumatic Diseases*, **30**, 597.
- LIPSON, R.L. & WILLIAMS, L.E. (1968) The 'connective tissue disorder' of hyperparathyroidism. *Arthritis and Rheumatism*, **11**, 198.
- PATTEN, B.M., BILEZIKIAN, J.P., MALLETTE, L.E., PRINCE, A., ENGEL, W.K. & AURBACH, G.D. (1974) Neuromuscular disease in primary hyperparathyroidism. *Annals of Internal Medicine*, **80**, 182.
- PRESTON, F.S. & ADICOFF, A. (1962) Hyperparathyroidism with avulsion of three major tendons. *New England Journal of Medicine*, **266**, 968.
- PRITCHARD, M.H. & JESSOP, J.D. (1977) Chondrocalcinosis in primary hyperparathyroidism. *Annals of the Rheumatic Diseases*, **36**, 146.
- PYRAH, L.N., HODGKINSON, A. & ANDERSON, C.K. (1966) Primary hyperparathyroidism. *Journal of Bone and Joint Surgery*, **53**, 275.
- RESNICK, D. (1974) Erosive arthritis of the hand and wrist in hyperparathyroidism. *Radiology*, **110**, 263.
- SAMAAN, N.A., HICKLEY, R.A., DEDNER, T.D. & IBANEZ, M.L. (1975) Hyperparathyroidism and carcinoid tumour. *Annals of Internal Medicine*, **82**, 205.
- SCOTT, J.T., DIXON, A.ST.J. & BYWATERS, E.G.L. (1964) Association of hyperuricaemia and gout with hyperparathyroidism. *British Medical Journal*, **1**, 1070.
- WATSON, L. (1974) Primary hyperparathyroidism. *Clinical Endocrinology and Metabolism*, **3**, 215.
- WEINSTEIN, J.D., DICK, H.M. & GRANTHAM, S.A. (1968) Pseudogout, hyperparathyroidism and the carpal tunnel syndrome—a case report. *Journal of Bone and Joint Surgery*, **50**, 1669.
- ZVAIFLER, N.J., REEFE, W.E. & BLACK, R.L. (1962) Articular manifestations in primary hyperparathyroidism. *Arthritis and Rheumatism*, **5**, 237.

(Accepted 13 September 1982)