

Disulfiram-induced hepatitis—report of a case and review of the literature

LENNART NÄSSBERGER
M.D.

Department of Internal Medicine, University Hospital, S-581 85 Linköping, Sweden

Summary

Disulfiram has been used as an adjunct to the treatment of chronic alcoholism since 1948. We report a young woman who developed clinical, biochemical and histopathological signs of a liver hypersensitivity reaction. A review of the literature is also presented.

KEY WORDS: disulfiram, hepatitis, hypersensitivity.

Introduction

Disulfiram, tetraethylthiuram disulphide was introduced in 1948 (Hald and Jacobsen, 1948) as an adjunct to the treatment of chronic alcoholism. The following year it was suggested that disulfiram might cause liver damage (Knutsen, 1949) and further evidence for its hepatotoxicity has since been published. Disulfiram has also been used as a chelating agent in the treatment of nickel dermatitis and in a few of these patients elevated serum transaminases have been recorded (Kristensen, 1981; Kristensen and Christensen, 1981).

The purpose of this article is to report the case of a young woman who developed hypersensitivity liver damage following oral disulfiram administration and review the published reports of disulfiram-induced liver disease.

Case report

The patient is a 32-year-old woman in whom retroperitoneal fibrosis was diagnosed in February 1978. It resolved completely on corticosteroid treatment. Due to an increasing alcohol consumption disulfiram treatment was started in August 1981. The dosage was 400 mg every 2nd day. Two months later she noticed small acneform eruptions on her legs, which later became generalized, and pruritus. One month later she developed chills and fever.

The patient was admitted in January 1982 and the disulfiram treatment was stopped. A generalized erythema with desquamated areas on the skin was seen. Laboratory analyses revealed an iron-deficient anaemia, elevated serum aspartate aminotransferase

5.0 μ kat/litre* (normal <0.70), alanine aminotransferase 3.8 μ kat/litre (normal <0.70) and alkaline phosphatase 24.85 μ kat/litre (normal <5.0). Serum lactic dihydrogenase was elevated 10.8 μ kat/litre (normal <7.5), but returned to normal level after 2-3 weeks. The serum bilirubin was normal and remained so. The erythrocyte sedimentation rate was normal throughout. Initially eosinophilia was present (12%) with a white cell count between 10.3 and 18×10^9 /litre. Serum amylase was normal. Increased IgA 4.1 g/litre (normal 1.2-3.5), IgG 14.5 g/litre (normal 7.0-14.0) and hypoalbuminaemia (30 g/litre) existed. Plasma haptoglobin was 3.0 g/litre (normal 0.45-2.7). Hepatitis B surface antigen, Wasserman reaction and Coombs' test were negative. Antibodies against smooth muscle and mitochondrium type M₁ were positive at 1/25. Scintigraphy revealed no hepatomegaly. The patient was transferred to the dermatology department, because of the severe dermatopathy, which persisted for about 6 months. A skin biopsy showed a non-specific dermatitis with infiltration of eosinophils.

A liver biopsy showed preserved lobular architecture (Fig. 1). The most distinctive alterations were found in the portal tracts, which were enlarged. There was mono and polymorphonuclear cell infiltration with eosinophils, slight proliferation of the bile ducts and increased fibrosis in some of the portal tracts. Connective tissue septa extended from the tracts but did not link with other septa.

Seven months later serum transaminases and alkaline phosphatase were normal. Antibodies against smooth muscle and mitochondrium were negative. The serum IgG and IgA levels were normal. The patient refused a further liver biopsy.

Discussion

A disulfiram hypersensitivity reaction was diagnosed in this patient on the basis of extrahepatic allergic manifestations namely rash, fever and eosinophilia. The liver biopsy showed inflammation of portal tracts with eosinophils, but absence of paren-

*kat = $6 \times 10^3 \mu$.

TABLE 1. Summary of clinical and laboratory data of disulfiram-induced liver damage reported in the literature.

Reference	Duration of treatment	Jaundice	Pruritus	Coma	Rash (1) Fever (2) Eosinophilia (3)	ASAT	ALAT	ALP	Bilirubin
Knutson, 1949	4 weeks*	+	+	+	1	-	-	-	-
Keeffe & Smith, 1974	10 days	+	-	-	1	↑	-	↑	↑
Eisen & Ginsberg, 1975	4 weeks	+	+	-	-	↑	↑	↑	↑
Ranek & Buch Andreasen, 1977	2 weeks	+	-	-	2,3	-	↑	↑	↑
	6 months*	+	-	+	-	-	↑	↑	↑
	4 weeks*	+	-	+	-	-	↑	↑	↑
	8 weeks*	+	-	+	-	-	↑	↑	↑
	3 weeks*	+	-	+	-	-	↑	↑	↑
	12 weeks*	+	-	+	-	-	↑	↑	↑
Morris <i>et al.</i> , 1978	3 weeks	+	-	-	3	↑	-	↑	↑
Vazquez & Pardo, 1979	12 months	-	-	-	-	→	→	→	→
	?	-	-	-	-	→	→	→	→
Minden, 1979	9 months	-	-	-	-	→	→	↑	→
Kristensen, 1981	8 weeks	-	-	-	-	↑	↑	↑	-
Holm-Bentzen <i>et al.</i> , 1981	12 weeks*†	+	-	+	-	↑	-	↑	↑
Kobborg & Sögaard, 1981	6 weeks	+	-	-	-	↑	↑	↑	↑
Kristensen & Christensen, 1981	8 weeks	-	-	-	-	↑	↑	↑	-
	8 weeks	-	-	-	-	↑	↑	↑	-
	8 weeks	-	-	-	-	↑	↑	↑	-
Wise, 1981‡									

ASAT = aspartate aminotransferase; ALAT = alanine aminotransferase; ALP = alkaline phosphatase.

+: The symptom present; -: the symptom absent or not recorded; →: normal value; ↑: pathological value.

*The patient died.

†Further two patients were recorded, they developed coma and died.

‡Three patients reported to the author from the North Little Rock Veterans Administration Alcohol Treatment and Rehabilitation Unit.

chymal damage. No other drugs had been given. There was a possible predisposition to developing hypersensitivity reactions in that retroperitoneal fibrosis might be included in the group of hypersensitivity disorders and may cause sclerosing cholangitis (Bartholomew *et al.*, 1963; Hellstrom and Perez-Stable, 1966). However, neither the liver biopsy nor the clinical course was compatible with this latter diagnosis. Five patients have been challenged with disulfiram and all developed sign of hepatic involvement again (Kristensen, 1981, Keeffe and Smith, 1974; Eisen and Ginsberg, 1975; Ranek and Buch Andreasen, 1977; Morris *et al.*, 1978). Challenge with the drug in our patient has not been performed because of the severe dermatopathy.

Since the first report of disulfiram-induced liver damage in 1949, a further 20 cases have been reported. Nine patients developed hepatic coma and died (Knutson, 1949, Ranek and Buch Andreasen, 1977; Kobborg and Sögaard, 1981). Extrahepatic manifestations seem to be scanty. Mitochondrial antibodies have not been recorded in any of these cases. The commonest clinical and laboratory data are summarized in Table 1.

Goyer and Mayor (1979) studied 50 men during hospitalization in an in-patient alcoholism rehabilitation unit. They failed to show a significant differences in liver laboratory parameters between disulfiram-treated subjects and controls.

From a histopathological viewpoint infiltration of

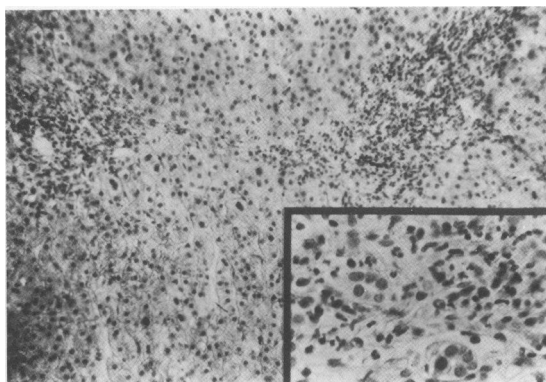


FIG. 1. Shows enlarged portal tracts with inflammatory cell infiltrates but otherwise normal liver structure, van Gieson ($\times 50$). Inset: higher power view of a portal tract with two bile canaliculi and mono- and polymorphonuclear cells including a few eosinophils. H&E ($\times 320$).

inflammatory cells in the portal tracts has been found to be a common sign. In 3 cases focal necrosis (Ranek and Buch Andreasen, 1977; Morris *et al.*, 1978) were present and in one mild cytoplasmic degeneration (Keeffe and Smith, 1974). In a Spanish report of 3 chronic alcoholic patients treated with disulfiram, hepatocytes were found to contain inclusions rich in filaments and scarce in glycogen granules. They were interpreted to be identical to Lafora's bodies (Vazquez and Pardo-Minan, 1979).

The diagnosis can be considered established if other hepatic diseases are excluded or readministration of disulfiram reproduces the symptoms. Patients with known allergic history perhaps may be more prone to develop drug-induced liver hypersensitivity reaction. In such patients serum transaminases and alkaline phosphatases should be measured at short intervals. Disulfiram-induced hepatitis may be ex-

tremely rare or alternatively, disulfiram-related hepatic disease may have been overlooked because of the high prevalence of alcoholic liver disease in the population treated with disulfiram.

References

- BARTHOLOMEW, L.G., CAIN, J.C., WOOLNER, L.B., UTZ, D.C. & FERRIS, D.O. (1963) Sclerosing cholangitis: its possible association with Riedel's struma and fibrous retroperitonitis. Report of two cases. *New England Journal of Medicine*, **8**, 269.
- EISEN, H. & GINSBERG, A.L. (1975) Disulfiram hepatotoxicity. *Annals of Internal Medicine*, **83**, 673.
- GOYER, P.F. & MAYOR, L.F. (1979) Hepatotoxicity in disulfiram-treated patients. *Journal of Studies on Alcohol*, **40**, 133.
- HALD, J. & JACOBSEN, E. (1948) A drug sensitising the organism to ethyl alcohol. *Lancet*, *ii*, 1001.
- HELLSTROM, R. & PEREZ-STABLE, E.C. (1966) Retroperitoneal fibrosis with disseminated vasculitis and intrahepatic sclerosing cholangitis. *American Journal of Medicine*, **40**, 184.
- HOLM-BENTZEN, M., ALMBJERG, F. & RANEK, L. (1981) Medikamentelle Leverskader. *Ugeskrift for Laege*, **143**, 1213.
- KEEFFE, E.B. & SMITH, F.W. (1974) Disulfiram hypersensitivity. *Journal of the American Medical Association*, **230**, 435.
- KNUTSEN, B. (1949) Komplikasjoner ved Antabus-Behandling. *Tidsskrift for Norsk Laegeforening*, **69**, 436.
- KOBBERG, N. & SØGAARD, P.E. (1981) Disulfiram hepatitis. *Ugeskrift for Laege*, **143**, 624.
- KRISTENSEN, M.E. (1981) Toxic hepatitis induced by disulfiram in a non-alcoholic. *Acta Medica Scandinavica*, **209**, 335.
- KRISTENSEN, M.E. & CHRISTENSEN, O.B. (1981) Antabusbehandling av nickelallergiska patienter med kroniskt vesikulöst handeksem. *Svenska Läkaresällskapets Riksstämman, Stockholm December 1981*.
- MORRIS, S.J., KANNER, R., CHIPRUT, R.O. & SCHIFF, E.R. (1978) Disulfiram hepatitis. *Gastroenterology*, **75**, 100.
- RANEK, L. & BUCH ANDREASEN, P. (1977) Disulfiram hepatotoxicity. *British Medical Journal*, **2**, 94.
- VAZQUEZ, J.J. & PARDO-MINDAN, J. (1979) Livercell injury (bodies similar to Lafora's) in alcoholics treated with disulfiram (Antabuse). *Histopathology*, **3**, 377.
- WISE, J.D. (1979) Disulfiram toxicity. A review of the literature. *Journal of the Arkansas Medical Society*, **78**, 87.

(Accepted 28 July 1983)