

Takayasu's disease in Arabs

M.A. Sattar¹, A.G. White², B. Eklof² and F.F. Fenech¹

Departments of ¹Medicine and ²Surgery, Faculty of Medicine, Kuwait University, Kuwait, Arabian Gulf

Summary: Four cases of Takayasu's disease in female Arabs are reported. All patients had classical features of the disease. Typing for HLA phenotype showed that all patients had HLA A2, A9, BW35 and DR7 antigens, suggesting an immunogenetic basis for the disease. As far as we know, this is the first report of Takayasu's disease in this ethnic group.

Introduction

Takayasu's disease is a rare inflammatory disease affecting large arteries and often leading to segmental vessel and subsequent occlusive or aneurysmal sequelae. The characteristic clinical feature is pulselessness, due to obstruction of the carotid, subclavian or other branches from the aortic arch. It was first described as non-specific arteritis by Savory (1856) and Kussmaul (1872). In 1908, Takayasu described the typical ocular features of the disease which were confirmed by Ohnishi & Kagoshima (1908). However, it was Shimizu & Sano (1951) who described in detail the clinical features of this disorder.

The disease has a worldwide distribution and its cause remains, as yet, unknown. In 1975, an epidemiological study in Japan showed that there were 2148 patients with Takayasu's disease and that females made up to 89% of the patients (Committee Report, 1975). The disease most often occurs in Asian or in South American countries; its incidence in Western countries is low (Herrera *et al.*, 1977; Ishikawa, 1978), and most of the patients reported from Western countries are of Asian origin (Coccamise & Whiteman, 1952). Takayasu's disease has, as far as we know, not been reported in Arabs and we describe here four cases of Takayasu's disease in this ethnic group. In addition to the usual investigations, we performed HLA typing in order to gain further insight into the racial differences which might be operating in this disease.

Case reports

Case 1

A 19 year old Kuwaiti girl presented in December 1982 with recent onset of headache, palpitations and weakness of the left upper limb on physical exertion.

Examination disclosed a well nourished and well developed young girl. The left radial and brachial pulses were absent. The blood pressure in the right arm was 230/130 mm Hg and in the right and the left thighs 130/70 and 120/60 mm Hg respectively. Systolic bruits were heard over the neck, subclavian and in the umbilical region over the left renal artery. The optic fundi showed no abnormality.

Among the significant laboratory findings were ESR (Westergren) 87 mm in an hour and a raised antistreptolysin 0 titre (ASOT) of 1250 IU/dl (normal up to 200 IU/dl). Chest X-ray and electrocardiogram (ECG) were within normal limits. Aortography showed stenosis of the left subclavian artery after the origin of the vertebral artery, irregular narrowing of the descending aorta with 'string of pearls appearance', up to T6-T12 level, a considerable narrowing at L1-L2 and stenosis of the left renal artery (Figure 1).

Case 2

A 26 year old Palestinian woman presented in January 1983, with gradual onset of bitemporal headache, pain behind both eyes and attacks of dizziness and syncope of 8 months duration.

Physical examination revealed a thinly built woman. There was complete absence of carotid, subclavian and radial pulsations bilaterally and de-

Correspondence: M.A. Sattar, M.B.B.S., M.R.C.P., Department of Medicine, Faculty of Medicine, Kuwait University, P.O. Box 24923, Safat, Kuwait, Arabian Gulf
Accepted: 1 November 1984

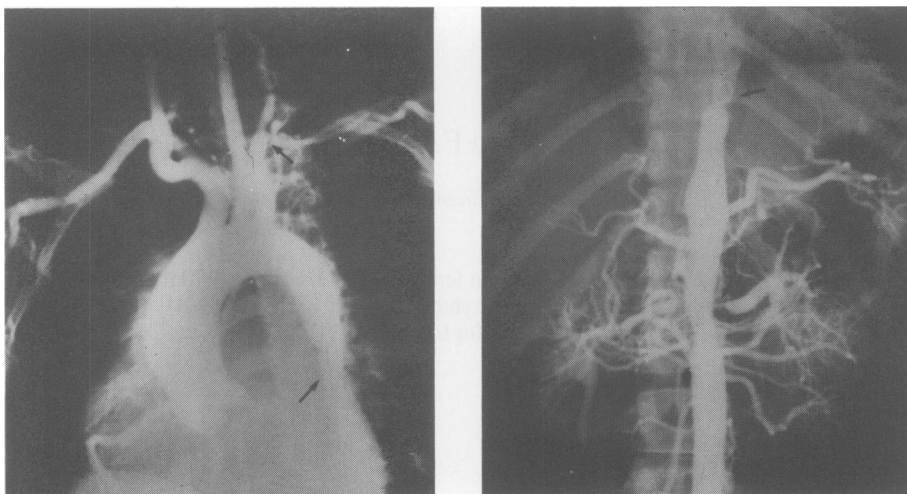


Figure 1 Case 1. Aortogram showing left subclavian artery stenosis after the origin of the vertebral artery 'string of pearls' appearance of descending thoracic aorta, T6 to T12; considerable narrowing at L1 and L2 and the left renal artery stenosis. (Arrows refer to site of narrowing and complete obstruction of the vessel.)

creased pulsations in both lower limbs. Blood pressure in the lower extremities was 110/70 mm Hg bilaterally. The optic fundi showed dilatation and increased pulsation and abnormal distribution of the vessels, but no haemorrhages or microaneurysms.

There was a raised ESR (Westergren) of 56 mm in an hour. Chest X-ray and ECG were normal. Aortography demonstrated a complete occlusion of brachiocephalic and left common carotid artery with stenosis of left subclavian artery.

Case 3

A 23 year old Palestinian woman was seen in April 1983, complaining of syncopal attacks on exercise, palpitations and weakness of both arms on effort.

Physical examination showed her to be of average height and build. Both radial and brachial pulses were absent bilaterally. No blood pressure could be recorded in the upper extremities; in the right and the left lower limbs the pressure was 110/70 and 90/60 mm Hg respectively. Systolic bruits were audible over both supraclavicular fossae.

The ESR (Westergren) was 24 mm in an hour. X-ray of the chest showed no abnormality and ECG was normal. Aortography demonstrated an occlusion of the right and left subclavian arteries after the origin of the vertebral arteries.

Case 4

A 36 year old Egyptian woman was seen in October 1983 with recurrent attacks of low back pain and exercise claudication of the left arm of two years

duration. The left radial and brachial pulsations were absent and pulsations in the left lower extremity were weak. The blood pressure in the right arm was 190/110 mm Hg and in the left and right thighs 90/50 and 110/70 mm Hg respectively. A systolic bruit was audible over the left supraclavicular fossa. The ocular fundi were normal.

The ESR (Westergren) was 47 mm in an hour. A chest X-ray showed no abnormality and there was minimal left ventricular hypertrophy in the ECG. Aortogram showed a complete occlusion of the left subclavian artery after its origin and also irregularity of thoraco-abdominal aorta between T7-L3.

Investigations

The investigations carried out to exclude other caused of vasculitis were, C-reactive protein (CRP), rheumatoid factor (RF), lupus erythematosus cell (LE cell), antinuclear factor (ANF), serum complement levels (C₃ and C₄), serum proteins, including immuno-

Table I HLA phenotypes in Takayasu's disease

Case no.	HLA				
	A	B	CW	DR	MT
1	2, 9	17, W35	4	2, 7	1, 2, 3, 4
2	2, 9	21, W35	4	5, 7	3, 4
3	2, 9	12, W35	4	2, 7	1, 3, 4
4	2, 9	W35	4	2, 7	2, 4

globulins; all were within normal limits. All patients were negative for hepatitis B surface antigen (HBsA), tuberculin test, VDRL and had a normal coagulation profile.

Arterial biopsies were performed in 3 of the 4 patients (case 1, 2 and 4); one prior to surgery and 2 during operation; all showed features of panarteritis, a picture consistent with a diagnosis of Takayasu's arteritis.

HLA – typing

Typing for HLA-A, B, and C antigens was carried out using a conventional 2 stage micro-lymphocytotoxicity technique (Terasaki & Park, 1978). Typing for HLA-DR antigen was undertaken using a modified 2 colour fluorescence technique (Van Rood *et al.*, 1976) using a commercial antisera (UCLA, Tissue typing laboratory, Los Angeles, California).

The results of typing for HLA-A, B, C and DR antigens are shown in Table I. The 4 patients were not related to each other and were of different nationalities, but all of them exhibit the antigens HLA-A2, A9, BW35, CW4 and DR7, as part of their HLA phenotype. From local population studies, the chances of finding 4 individuals with this combination of antigens (A2, A9, BW35 and CW4) is of the order of at least 1 in 800 (0.123%). Although the numbers reported here are too small to make any conclusion, it indicates that HLA typing would be worth performing in a large series of patients.

Progress

Patients were given, in the early stages, 30 mg prednisolone twice a day, and this induced a significant clinical remission. The ESR and raised white cell count were normal within 1 month of starting treatment. Corticosteroids were tailed off over the next 6 months to a maintenance dose of 5 mg on alternate days. Though the disease had gone into remission, there was no return of pulsations in the blocked arteries. In view of the serious nature of the lesions, reconstructive vascular surgery was carried out in 3 patients (case 1, 2 and 4), the fourth patient (case 3) refused surgery. The patients have now been followed up for 9 months and all are relatively asymptomatic including the one who refused operation; she has however had to be maintained on 5 mg of corticosteroids on alternate days.

Discussion

Since the description of this disease by Takayasu (1908) and Ohnishi & Kagoshima (1908), the

aetiology has been extensively investigated (Shimizu & Sano, 1948; Coccamise & Whiteman, 1952; Judge *et al.*, 1962; Nasu, 1963, Committee report, 1975; Herrera *et al.*, 1977). All hypotheses, including autoimmunity, have been based on non-hereditary factors. Recent studies on HLA antigen frequency (Numano *et al.*, 1979) have suggested that genetic factors may play an important role in the pathogenesis of this disease. Numano *et al.* (1982) have shown that HLA antigens are closely associated with Takayasu's disease. Family and population studies in Japan have revealed a significant association between the disease and the HLA antigens, A9, A10 and BW52, as compared to findings in healthy Japanese (Isohisa *et al.*, 1978; Naito *et al.*, 1978). Furthermore, studies of HLA-D antigens revealed a close relationship between HLA DW12 antigen and this disease (Numano, 1980). It appears therefore that some of the genetic factors involved in Takayasu's disease are located close to HLA-A, B, and D loci. As the association is stronger with HLA BW52 than HLA DW12, the genes predisposing to disease susceptibility are closer to the HLA-B locus than to HLA-D and have a dominant character. It is also suggested that the degree of association between these genes and immune responsiveness may determine the characteristic features of Takayasu's disease. Yokota *et al.* (1981) reported a close association of MT1 in their patients and suggested that these genes may be related to the underlying immunological mechanism involved in the pathogenesis of this disease. In view of the high frequency of HLA BW52 and DW12, it is postulated that a combination of HLA BW52 and DW12 may be a causative factor in the expression of this disease and of its characteristic clinical features. Furthermore, Numano *et al.* (1983) observed that patients with HLA BW52, HLA DW12, HLA DR12 and MT1 suffered a more severe disease.

Although we have only studied 4 patients, it is of interest to note that all had HLA-A2, A9, BW35 and DR7. Because of the different ethnic origin of our patients some differences in antigen pattern may be expected. The association with HLA-A9 has been described in Japanese and would indicate that this antigen might be universally associated with the condition in a similar manner to the strong association found between ankylosing spondylitis and HLA B27 in all ethnic groups tested so far (Brewerton *et al.*, 1973). Obviously more patients and family studies are necessary to further elucidate these genetic factors.

Acknowledgements

We would like to thank Professor Kazim Behbahani, Professor of Microbiology and Dr Al-Saffar for their help in HLA DR typing as well as Miss Basma Ghoutti and Mr George Varughese for technical assistance.

References

- BREWERTON, D.A., CAFFREY, M., HART, F.D., JAMES, D.C.O., NICHOLLS, A. & STURROCK, D. (1973). Ankylosing spondylitis. *Lancet*, **i**, 904.
- COCCAMISE, W.C. & WHITEMAN, J.F. (1952). Pulseless disease – a preliminary case report. *American Heart Journal*, **44**, 629.
- COMMITTEE REPORT – Clinical and pathological studies of Takayasu's disease – a report by the Ministry of Health and Welfare, Japan, 1975.
- HERRERA, E.L., TORRES, G.S., MARCUSHAMER, J., MISPIRETA, J., HORWITZ, S. & VELA, J.E. (1977). Takayasu's arteritis a clinical study of 107 cases. *American Heart Journal*, **93**, 94.
- ISHIKAWA, K. (1978). Natural history and classification of occlusive thromboaropathy (Takayasu's disease). *Circulation*, **57**, 27.
- ISOHISA, I., NUMANO, F., MAEZAWA, H. & SASAZUKI, T. (1978). HLA-BW52, in Takayasu's disease. *Tissue Antigen*, **12**, 246.
- JUDGE, R.D., CURRIER, R.D., GRACIE, W. A. & FIGLEY, M. M. (1962). Takayasu's arteritis and the aortic arch syndrome. *American Journal of Medicine*, **32**, 379.
- KUSSMAUL, A. (1872). Zwei fälle von spontaner all mahlicher verschliessung grosser. Halsarterion stamme. *Deutsches Archiv für Klinische Medizin*, **24**, 461.
- NAITO, S., ARAKAWA, K., SAITA, S., TOYODA, K. & TAKESHITA, A. (1978). Takayasu's disease: association with HLA-B5. *Tissue Antigen*, **12**, 143.
- NASU, T. (1963). Pathology of pulseless disease. *Angiology*, **14**, 225.
- NUMANO, F. (1980). Genetic factors in Takayasu's disease. *Japanese Medical Journal*, **19**, 68.
- NUMANO, F., ISOHISA, I., EGAMI, M., OHTA, M. & SASAZUKI, T. (1983). HLA-DR, MT and MB antigens in Takayasu's disease. *Tissue Antigens*, **21**, 208.
- NUMANO, F., ISOHISA, I., MAEZAWA, H. & JUJI, T. (1979). HLA antigens in Takayasu's disease. *American Heart Journal*, **98**, 153.
- NUMANO, F., OHTA, N. & SASAZUKI, T. (1982). HLA and clinical manifestations in Takayasu's disease. *Japanese Circulation Journal*, **46**, 683.
- OHNISHI, K. & KAGOSHIMU, K. (1908). Case with unusual changes of the central vessels in the retina. *Acta Societatis ophthalmologicae japonicae*, **12**, 555.
- SAVORY, W.S. (1856). A case of a young woman in whom the main arteries of both upper extremities and of the left side of the neck were throughout completely obliterated. *Medico-Chirurgical Transactions*, **39**, 205.
- SHIMIZU, K. & SANO, K. (1951). Pulseless disease. *Journal of Neuroophthalmology and Clinical Neurology*, **1**, 37.
- TAKAYASU, M. (1908). Case with unusual changes of central vessels in the retina. *Acta Society Ophthalmology of Japan*, **12**, 554.
- TERASAKI, P.I. & PARK, M.S. (1978). Microlymphocytotoxicity test. In *NIAID Manual of tissue typing techniques*. 1976–77, Bethesda, Maryland. U.S. Dept. of Health, Education and Welfare 1978: 69–80 [DHEW. Pub. No. (NIH) 76–54].
- VAN ROOD, J.J., VAN LEEMAN, A. & PLOEM, J.S. (1976). Simultaneous detection of two cell population by two colour fluorescence and application to the replication of B-cell determinants. *Nature*, **262**, 795.
- YOKOTA, A., TANABE, T. & YASUDA, K. (1981). Association of HLA-D region antigen with aortitis syndrome. In *Proceedings of 2nd German-Japanese Congress of Angiology*, March 15–20. 1981, Tokyo, p. 235.