

A case of multiple endocrine adenomatosis with primary amenorrhoea

M. VANDEWEGHE
M.D.

K. BRAXEL
M.D.

J. SCHUTYSER
M.D.*

A. VERMEULEN
M.D.

*Department of Endocrine and Metabolic Diseases, Academical Hospital, Ghent, and
Department of Internal Medicine, Kliniek Maria's Voorzienigheid, Kortrijk, Belgium

Summary

A well documented sporadic case of multiple endocrine adenomatosis (MEA) type I, with the pituitary tumour presenting as a prolactinoma, is described in a 28-year-old female. Primary amenorrhoea, resulting from hyperprolactinaemia, was the first symptom of the polyglandular neoplasia. A gastrinoma was removed from the head of the pancreas and latent hyperparathyroidism appeared to be present. Treatment with bromocriptine was poorly tolerated; neurosurgical intervention was refused by the patient. The possibility that a serum prolactin determination may be useful in detecting pituitary involvement in MEA deserves consideration.

Introduction

Prolactin-producing pituitary adenomas have been recognized as responsible for a number of cases of galactorrhoea and/or amenorrhoea in women and of sexual impotence in man (Peake *et al.*, 1969; Forsyth *et al.*, 1971; Tolis *et al.*, 1974; Malarkey and Johnson, 1976). On the other hand, more than 200 cases of multiple endocrine adenomatosis (MEA) type I have been reported since the original description of Wermer (1954). So far as the authors know, a well documented case of the MEA syndrome in which the pituitary tumour presents as a prolactinoma, with primary amenorrhoea and galactorrhoea, has not yet been described in the literature.

Case report

A 28-year-old female with gastrointestinal complaints was first seen at the authors' department in Belgium in January 1975.

In October 1969 a gastroenterostomy with vagotomy had been performed in another hospital for recurrent duodenal ulcer. No clinical improvement was obtained, as the patient reported persistent

epigastric pain, vomiting and heartburn, with a weight-loss of 20 kg over the last 6 years. The upper abdomen was tender on palpation; there were no other physical abnormalities; acromegalic features were absent. Apart from a raised sedimentation rate, a mild iron deficiency anaemia and borderline serum calcium and phosphorus levels, routine laboratory tests revealed no abnormal findings. On radiographic investigation a neostomal ulcer was demonstrated, with an atonic aspect of the duodenum and an inflammatory picture of the jejunum. Gastroscopy revealed coarse hypertrophic folds in the corpus; excessive residual gastric juice was evident. On gastric fluid examination the basic acid output/peak acid output ratio of 1:1 was found, which is strongly suggestive of Zollinger-Ellison syndrome (Marks *et al.*, 1961; Stremple, 1975). The gastrin level in plasma reached 4400 pg/ml. Secretin provoked a 25% elevation of gastrin levels, which is considered to be diagnostic for Zollinger-Ellison syndrome (Thompson *et al.*, 1972). A protein meal induced only a slight rise of the gastrin level, ruling out the diagnosis of antral G-cell hyperplasia (Hansky, 1974). On arteriography a tumoural process in the head of the pancreas was suspected. These data indicated that the patient was suffering from Zollinger-Ellison syndrome due to a gastrinoma. On laparotomy, a tumoural mass with a diameter of 1.5 cm was removed from the head of the pancreas and subsequently a total gastrectomy was performed; metastatic lesions in the liver or in the regional glands were not seen. On microscopic examination a 'carcinoid' tumour with solid aggregates (gastrinoma) was found (Fig. 1a and b).

Clinical recovery was uneventful; gastrin levels diminished postoperatively, but remained above normal levels.

Further inquiries revealed that the patient had presented with primary amenorrhoea, associated with a period of galactorrhoea from 1965 to end of 1967. Previous investigations in another hospital had

Correspondence: Dr M. Vandeweghe, Department of Endocrine and Metabolic Diseases, Akademisch Ziekenhuis, 9000-Gent-Belgium.

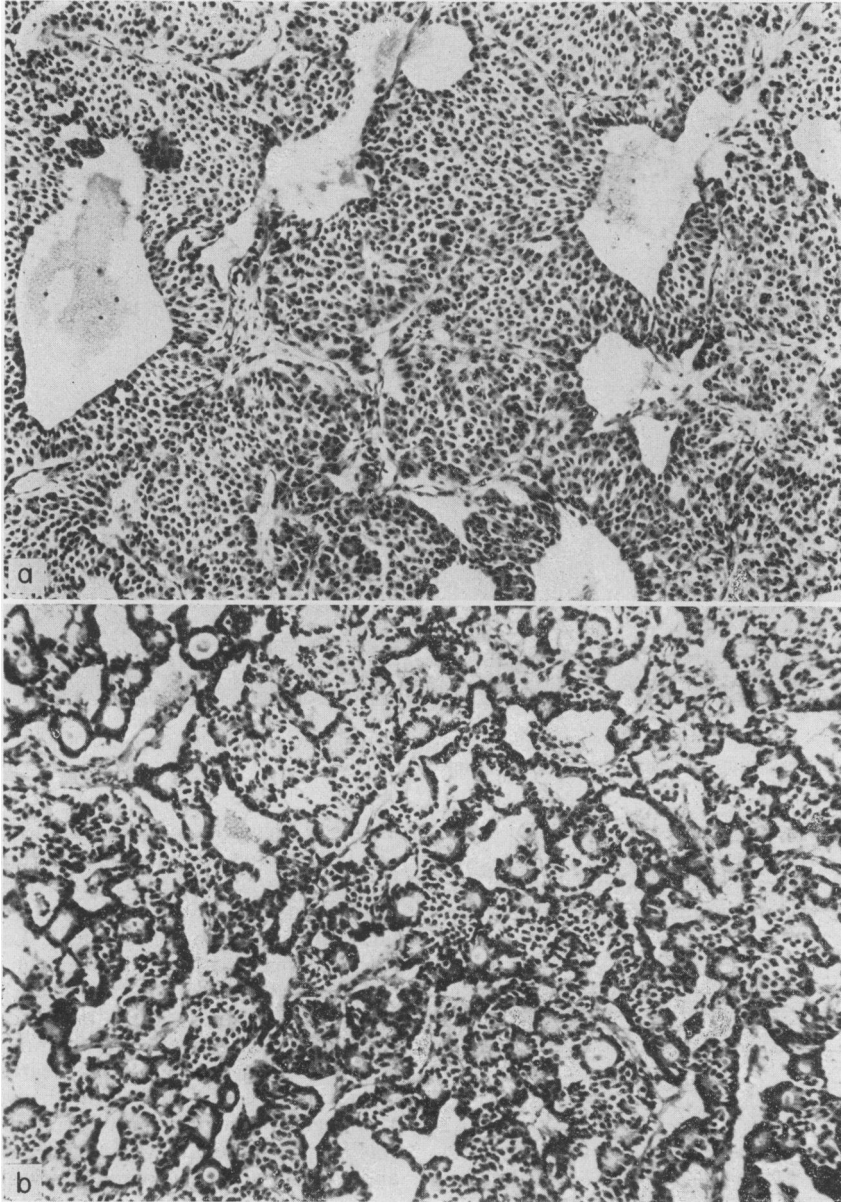


FIG. 1. (a and b) 'Carcinoid' tumour with solid aggregates of small cells. In some places glandular differentiation is seen ($\times 160$).

revealed an enlarged sella turcica and indicated 'probable Forbes-Albright syndrome'; at that time prolactin assays were not yet available. A gynaecological examination revealed no gross abnormalities; no milky fluid could be expressed from the breasts. On chromosomal investigation a normal female karyotype was demonstrated. Oestradiol and oestrone levels were 3.6 and 3.8 ng/100 ml respec-

tively; basal levels of LH and FSH were in the normal range. A complete investigation of pituitary function (Table 1) showed no abnormalities where secretion of ACTH, TSH, HGH, LH and FSH was concerned. Basal prolactin levels appeared to be very much increased, without any reaction upon stimulation. A radiographic examination of the skull (Fig. 2) showed manifest sellar enlargement with a

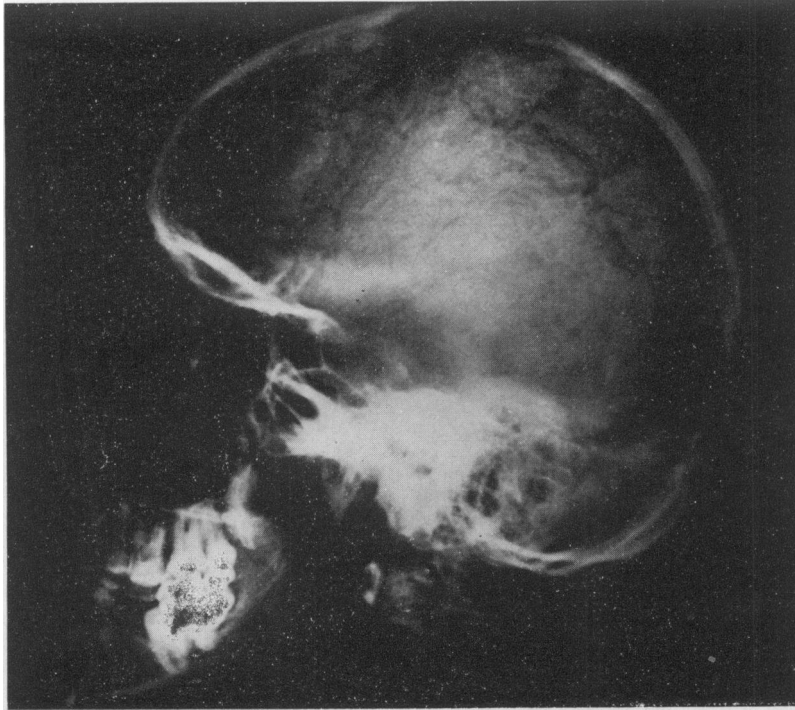


FIG. 2. Lateral view of skull demonstrates manifest sellar enlargement with a beginning of destruction of the dorsum.

beginning of destruction of the dorsum; visual fields were normal. On pneumo-encephalography, the presence of an 'empty sella syndrome' could be ruled out; there was no suprasellar extension of the tumoural process.

TABLE 1. Investigation of pituitary function*

	basal	20 min	40 min	60 min	120 min
LH (ng/ml)	5.6	37.0	37.1	32.4	20.4
FSH (ng/ml)	2.7	4.8	5.1	5.9	2.3
TSH (μ u./ml)†	4.4	29.2	—	21.2	—
HGH (ng/ml)	<0.1	—	—	37.8	—
Prolactin (ng/ml)	965	835	—	955	—
Cortisol (nmol/l)	234.5	—	—	730.0	—

* After simultaneous i.v. injection of 0.15 u. insulin/kg body-weight, 200 μ g TRF and 100 μ g LHRF.

† Thyroxine and T₃ levels in plasma were normal.

A treatment with bromocriptine at a daily dosage of 2 \times 2.5 mg was started; it resulted in a significant lowering of prolactin levels (from 900–1000 ng/ml to 200–300 ng/ml). A further increase in dosage however appeared impossible, because of severe gastrointestinal side effects. Human growth hormone levels remained normal; there was no rise of HGH after TRF stimulation. Prolactin levels remained

distinctly elevated and normal menstrual function did not resume. In May 1976, progression of the tumour was evident on sellar tomographies; a neurosurgical intervention was advised but has so far been refused by the patient. Levels of serum calcium appeared to be in the high normal range (2.55 to 2.68 mmol/l), with one clearly elevated value (2.78 mmol/l); serum phosphorus concentrations were rather low (0.55–1.03 mmol/l). The basal levels of serum PTH were clearly elevated on several occasions, oscillating between 410 and 1260 pg/ml. The tubular resorption of phosphate was slightly lowered. Radiography of the skeleton and an intravenous urography revealed no abnormalities.

Review of the family history was negative, and more complete investigation was declined by the patient.

Assay methods

LH, FSH, HGH, prolactin, gastrin and TSH were measured by radioimmunoassay, using the commercial CEA-IRE-SORIN (Belgium) kits; for FSH and LH the references used were MRC 68/39 and MRC 68/40 respectively and the results expressed in ng/ml. PTH was measured according to Bouillon,

Koninckx and De Moor (1974). Oestradiol and oestrone were measured as published previously (Vermeulen and Verdonck, 1976). Cortisol was measured by fluorimetry using the Mattingly method (Mattingly, 1962).

Discussion

The patient presented in this communication appears to have had a gastrin-producing pancreatic islet tumour (Zollinger–Ellison syndrome) and hyperparathyroidism. Although pathological confirmation has not been obtained, there can be little doubt on clinical and biochemical grounds (galactorrhoea-amenorrhoea; enlarged sella turcica; excessive hyperprolactinaemia) (Jacobs and Daughaday, 1973; Frantz *et al.*, 1973) that a prolactin-secreting pituitary tumour is present. It is unlikely that the hyperprolactinaemia is due to a non-secreting pituitary tumour, involving the pituitary stalk and resulting in a diminished quantity of 'prolactin-inhibiting factor' reaching the pituitary, because of the very high prolactin levels and the absence of suprasellar extension of the tumour. The 'empty sella syndrome', a rare cause of substantial hyperprolactinaemia (Tah-Hsiung *et al.*, 1976), was excluded by pneumoencephalography. Sönksen *et al.* (1976) described a case of acromegaly secondary to a carcinoid tumour; the acromegaly remitted when the carcinoid was removed. In view of this, the possibility of the prolactin-secreting pituitary tumour in the present patient being secondary to the abdominal (carcinoid) tumour should not be ruled out, because the fact that the prolactin levels did not diminish after surgery indicates that the tumour may not have been completely removed.

In the majority of cases of MEA type I, the pituitary tumour has been reported as being 'functionless', whereas about 30% are associated with acromegaly (Croisier, Azerad and Lubetzke, 1971; Newsome, 1974); Cushing's syndrome due to bilateral adrenal hyperplasia was seen in only 5% of cases (Newsome, 1974). A 'mixed adenoma', secreting growth hormone and prolactin (Corenblum *et al.*, 1976), could be ruled out in the present case as the growth hormone levels remained normal.

On careful search of the literature several similar, but less well documented, cases can be found. Jacobs and Daughaday (1973) reported three patients with MEA type I with frankly elevated prolactin levels; clinical data, however, were not provided. Franks, Jacobs and Nabarro (1975) mentioned two patients with a pituitary tumour associated with MEA, who had a raised serum prolactin concentration. Croughs *et al.* (1972) described a 28-year-old woman, presenting with galactorrhoea and amenorrhoea. Detailed analysis revealed that she was

suffering from hyperparathyroidism and Cushing's syndrome due to an adrenal adenoma, and that she harboured an asymptomatic glucagonoma; data about prolactin, LH and FSH levels were absent. However, as galactorrhoea had appeared only after previous use of oral contraceptives, X-ray films of the sella turcica remained normal, and pregnancy could be induced by the use of clomiphene (Editorial, 1976; Jacobs *et al.*, 1976; Mrouek and Siler-Khodr, 1976), it appears rather improbable that a prolactinoma could have been present. In a review of 169 patients with MEA type I, Croisier *et al.* (1971) found two cases with galactorrhoea, but no further data were provided. Very recently, Tourniaire *et al.* (1976) reported the case of a 20-year-old woman with a proved prolactinoma and concomitant hyperparathyroidism; a family history of peptic ulcer disease and renal calculi was mentioned.

In MEA type I syndrome, the occurrence of the endocrine tumours at widely separated intervals is not unusual (Caughey *et al.*, 1971). First clinical evidence of the disorder can be the development of a pancreatic islet tumour (Vance *et al.*, 1972), symptomatic hyperparathyroidism (Boey *et al.*, 1975) or (secondary) amenorrhoea (Caughey *et al.*, 1971; Kolodny and Griboff, 1964). In the present case, primary amenorrhoea, resulting from hyperprolactinaemia, appeared to be the first symptom of the polyglandular neoplasia. Therefore it might be a valid suggestion to perform prolactin determination in all cases of recurrent peptic ulceration and hyperparathyroidism, even when menstrual disturbances or signs of hypogonadism are not present.

Although classically, the familial occurrence has been heavily stressed in the literature – the syndrome being inherited as an autosomal dominant trait (Wermer, 1963) – it appears that sporadic cases account for nearly 50% of the reported patients (Croisier *et al.*, 1971). Results of screening tests in asymptomatic family members indicate that, in addition to reviewing the patient's history for peptic ulcer disease, hypoglycaemia, renal calculi and other symptoms, the most useful laboratory study is the measurement of serum calcium (Snyder, Scurry and Deiss, 1972). Clinical hyperparathyroidism may be surprisingly mild, and its full development may take several decades (Wermer, 1974). Hyperprolactinaemia is present in about 25% of patients with pituitary tumours not associated with polyendocrine involvement (Fournier, Desjardins and Friesen, 1974). Since it has been shown that pituitary tumours, which were formerly thought to be functionless, are often prolactin-secreting (Child *et al.*, 1975; Franks *et al.*, 1976), the possibility of a serum prolactin determination being useful in detecting pituitary involvement in MEA deserves further consideration.

Acknowledgments

We wish to thank Dr C. Ramboer (Kliniek Maria's Voorzienigheid) for referral of the patient, Dr R. Bouillon (Rega Instituut, Akademisch Ziekenhuis, Leuven) and Dr M. Dhondt (Department of Gynaecology, Akademisch Ziekenhuis, Gent) for performing the radioimmunoassays of PTH and prolactin respectively.

References

- BOEY, J.H., COOKE, T.J.C., GILBERT, J.M., SWEENEY, E.C. & TAYLOR, S. (1975) Occurrence of other endocrine tumours in primary hyperparathyroidism. *Lancet*, *ii*, 781.
- BOULLON, R., KONINCKX, P. & DE MOOR, P. (1974) In: *Radioimmunoassay and Related Procedures in Medicine*, vol. 1, p. 353. International Atomic Energy Agency, Vienna.
- CAUGHEY, J.E., PARENDEH, G., COHEN, L.B. & VAMEGHI, M. (1971) Multiple endocrine adenomatosis with metabolic myopathy. *New Zealand Medical Journal*, *74*, 28.
- CHILD, D.F., NADER, S., MASHITER, K., KJELD, M., BANKS, L. & FRASER, R.T. (1975) Prolactin studies in 'functionless' pituitary tumours. *British Medical Journal*, *1*, 604.
- CORENBLUM, B., SIREK, A.M.T., HORVATH, E., KOVACS, K. & EZRIN, C. (1976) Human mixed somatotrophic and lactotrophic pituitary adenomas. *Journal of Clinical Endocrinology and Metabolism*, *42*, 857.
- CROISIER, J.C., AZERAD, E. & LUBETZKI, J. (1971) L'adénomatose polyendocrinienne (Syndrome de Wermer); À propos d'une observation personnelle; Revue de la littérature. *Semaine des hôpitaux de Paris*, *47*, 494.
- CROUGHS, R.J.M., HULSMANS, H.A.M., ISRAEL, D.E., HACKENG, W.H.L. & SCHOPMAN, W. (1972) Glucagonoma as a part of the polyglandular adenoma syndrome. *American Journal of Medicine*, *52*, 690.
- EDITORIAL (1976) Prolactin and amenorrhea. *New England Journal of Medicine*, *295*, 954.
- FORSYTH, I.A., BESSER, G.M., EDWARDS, C.R.W., FRANCIS, L. & MYRES, R.P. (1971) Plasma prolactin activity in inappropriate lactation. *British Medical Journal*, *3*, 225.
- FOURNIER, P.J.R., DESJARDINS, P.D. & FRIESEN, H.G. (1974) Current understanding of human prolactin physiology and its diagnostic and therapeutic applications: a review. *American Journal of Obstetrics and Gynecology*, *118*, 337.
- FRANKS, S., JACOBS, H.S. & NABARRO, J.D.N. (1975) Studies of prolactin secretion in pituitary disease. *Journal of Endocrinology*, *67*, 55P.
- FRANKS, S.F., JACOBS, H.S. & NABARRO, J.D.N. (1976) Pituitary prolactinomas. Incidence in 56 patients with chromophobe adenoma: clinical features, treatment. *Abstracts of the Vth International Congress of Endocrinology*, Hamburg, p. 41.
- FRANTZ, A.G., HABIF, D.V., HYMAN, G.A., SUH, H.K., SASSIN, I.F., ZIMMERMAN, E.A., NOEL, G.L. & KLEINBERG, D.L. (1973) In: Pasteels, J.L. & Robijn, C. (Eds) *International Symposium on Human Prolactin*, p. 273. Excerpta Medica, Amsterdam.
- HANSKY, J. (1974) Clinical aspects of gastrin physiology. *Medical Clinics of North America*, *58*, 1217.
- JACOBS, H.S. & DAUGHADAY, W. (1973) In: Pasteels, & L.J. Robijn, C. (Eds) *International Symposium on Human Prolactin*, p. 189. Excerpta Medica, Amsterdam.
- JACOBS, H.S., FRANKS, S., MURRAY, M.A.F., HULL, M.G.R., STEELE, S.J. & NABARRO, J.D.N. (1976) Clinical and endocrine features of hyperprolactinaemic amenorrhoea. *Clinical Endocrinology*, *5*, 439.
- KOLODNY, H.D. & GRIBOFF, S.I. (1964) Multiple endocrine adenomatosis. *Journal of the Mount Sinai Hospital*, *31*, 179.
- MALARKEY, W.B. & JOHNSON, J.C. (1976) Pituitary tumours and hyperprolactinemia. *Archives of Internal Medicine*, *136*, 40.
- MARKS, I.N., SELZER, G., LOUW, J.H. & BANK, S. (1961) Zollinger-Elison syndrome in a Bantu woman, with isolation of gastrin-like substance from the primary and secondary tumors. *Gastroenterology*, *41*, 77.
- MATTINGLY, D. (1962) A simple fluorimetric method for the estimation of free 11-hydroxycorticoids in human plasma. *Journal of Clinical Pathology*, *15*, 374.
- MROUEH, A.M. & SILER-KHODR, T.M. (1976) Ovarian refractoriness to gonadotrophins in cases of inappropriate lactation: restoration of ovarian function with bromocriptine. *Journal of Clinical Endocrinology and Metabolism*, *43*, 1398.
- NEWSOME, H.H. (1974) Multiple endocrine adenomatosis. *Surgical Clinics of North America*, *54*, 387.
- PEAKE, G.T., MCKEEL, D.W., JARETT, L. & DAUGHADAY, W.H. (1969) Ultrastructural, histologic and hormonal characterization of a prolactin-rich human pituitary tumour. *Journal of Clinical Endocrinology and Metabolism*, *39*, 1383.
- SNYDER, N., SCURRY, M.T. & DEISS JR, W.P. (1972) Five families with multiple endocrine adenomatosis. *Annals of Internal Medicine*, *76*, 53.
- SÖNKSEN, P.H., AYRES, A.B., BRAIMBRIDGE, M., CORRIN, B., DAVIES, D.R., JEREMIAH, G.M., OATEN, S.W., LOWY, C. & WEST, T.E.T. (1976) Acromegaly caused by pulmonary carcinoid tumours. *Clinical Endocrinology*, *5*, 503.
- STREMPLE, J.F. (1975) Gastrinomas. *Surgical Clinics of North America*, *55*, 303.
- TAH-HSIUNG, H., SHAPIRO, J.R., TYSON, J.E., LEDDY, A.L. & PAZ-GUEVARA, A.T. (1976) Hyperprolactinemia associated with empty sella syndrome. *Journal of the American Medical Association*, *235*, 2002.
- THOMPSON, J.C., REEDER, D.D., BUNCHMAN, H.H., BECKER, H.D. & BRANDT, E.N. (1972) Effect of secretin on circulating gastrin. *Annals of Surgery*, *176*, 384.
- TOLIS, G., SOMMA, M., VAN CAMPENHOUT, J. & FRIESEN, H. (1974) Prolactin secretion in 65 patients with galactorrhea. *American Journal of Obstetrics and Gynecology*, *118*, 91.
- TOURNAIRE, J., TROUILLES, J., MAILLET, P., DAVID, L., PALLO, D., TRAN MINH, V. & BRESSOT, C. (1976) Polyadénomatose endocrinienne associant un adénome hypophysaire à prolactine et un adénome parathyroïdien intrathyroïdien. *Annales d'Endocrinologie*. Paris, *37*, 465.
- VANCE, J.E., STOLL, R.W., KITABCHI, A.E., BUCHANAN, K.D., HOLLANDER, D. & WILLIAMS, R.H. (1972) Familial nesidioblastosis as the predominant manifestation of multiple endocrine adenomatosis. *American Journal of Medicine*, *52*, 211.
- VERMEULEN, A. & VERDONCK, L. (1976) Radioimmunoassay of 17 β -hydroxy, 5 α -androstane-3-one, 4-androstene-3,17, dehydroepiandrosterone, 17-hydroxy-progesterone and progesterone and its application to human male plasma. *Journal of Steroid Biochemistry*, *7*, 1.
- WERMER, P. (1954) Genetic aspects of adenomatosis of endocrine glands. *American Journal of Medicine*, *16*, 363.
- WERMER, P. (1963) Endocrine adenomatosis and peptic ulcer in a large kindred. *American Journal of Medicine*, *35*, 205.
- WERMER, P. (1974) Multiple endocrine adenomatosis; multiple hormone-producing tumours, a familial syndrome. *Clinics in Gastroenterology*, *3*, 671.