

Clinical associations of vitiligo

RODNEY P. R. DAWBER
M.B., M.R.C.P.(Lond.)

University Department of Dermatology, Royal Victoria Infirmary,
Newcastle upon Tyne

Summary

Vitiligo, a common skin condition, has been reported in association with thyroid disease, pernicious anaemia, carcinoma of the stomach, Addison's disease and diabetes mellitus.

Some subjects with vitiligo can be shown to possess circulating antibodies to thyroid gland, thyroglobulin, gastric parietal cells and adrenal gland, even in the absence of disease.

Vitiligo is evidently another 'skin-marker of internal disease'.

Introduction

Vitiligo is a common skin condition, occurring in approximately 1% of the general population (Lerner, 1959). Ormsby & Montgomery (1954) have defined it as: 'as acquired cutaneous achromia characterized by variously sized or shaped, single or multiple patches of milk white colour usually presenting hyperpigmented borders and a tendency to enlarge peripherally. Absence of pigment is the only symptom and the skin presents no textural changes and is clinically normal in every way except for a sensitivity to solar irradiation'. It affects the sexes equally and 35% of cases give a positive family history (Dawber, personal series, 1969); peak incidence is in the second and third decades of life. Patients often present in the summer months because increasing pigmentation of the normal skin accentuates the vitiliginous pallor; it is not uncommon under these circumstances for the patient to insist that the tanned skin is abnormal. In pale-skinned individuals demarcation of the area of involvement may be difficult; the exact extent can then be defined by exposing the skin to ultraviolet radiation (Fig. 1).

The cause of vitiligo remains obscure; recently however, attention has been given to its association with certain internal diseases.

Present address: St John's Hospital for Diseases of the Skin, London, W.C.2.

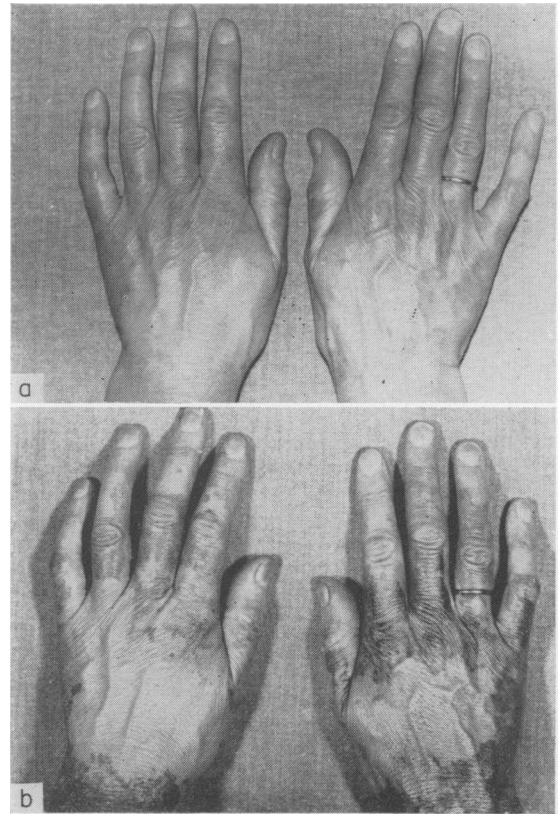


FIG. 1 (a). Vitiligo of hands barely visible with ordinary light. (b) Same patient as in (a) photographed under ultraviolet radiation; the vitiligo is more clearly seen. This patient also has diabetes mellitus.

Associated conditions

Thyroid disease

Several reports have occurred suggesting an association between thyrotoxicosis and vitiligo (Habermann, 1933; Lerner, 1959) but only recently has unequivocal evidence been forthcoming (Cunliffe *et al.*, 1968). Vitiligo has also been demon-

strated in patients with hypothyroidism (Lerner, 1955; Morgans, 1964).

Pernicious anaemia

Ishida (1954) showed that many subjects with vitiligo secrete less gastric acid than normal; other studies revealed that achlorhydria was present in a significant number (Francis, 1931). A close clinical relationship between pernicious anaemia and vitiligo has since been established (Allison & Curtis, 1955); Dawber (1970) found 9% of patients with pernicious anaemia have vitiligo.

Carcinoma of stomach

The author has recently observed a patient with vitiligo and carcinoma of the body of the stomach (Wright, Venables & Dawber, 1970). This has not previously been described, but in view of the association of vitiligo with achlorhydria and pernicious anaemia, an association with carcinoma of the stomach might almost be predicted. Further work will be necessary to confirm this finding.

Addison's disease

In his original description of this disease, Addison (1855) demonstrated one patient with predominant hyperpigmentation but also many areas of typical vitiligo. This relationship has since been confirmed (Dunlop, 1963).

Diabetes mellitus

The first reference to the occurrence of vitiligo with diabetes was the description of two such cases by Lerner (1959). Cunliffe *et al.* (1968) demonstrated a high incidence of diabetes in the family members of subjects with vitiligo. In a study of 512 mature-onset diabetics, twenty-five were found to have concomitant vitiligo (Dawber, 1968). The clinical association of 'juvenile' diabetes and vitiligo has not so far been proven.

Discussion

Thyrototoxicosis, myxoedema, pernicious anaemia and Addison's disease have been designated organ-specific autoimmune diseases; autoimmunity may be aetiologically important in diabetes. Subjects with vitiligo having no clinical or laboratory evidence of these diseases have been shown to possess circulating antibodies to thyroid gland and thyroglobulin (Cunliffe *et al.*, 1968), gastric parietal cells (Bor, Feiweil & Chanarin, 1969) and adrenal gland (Brostoff, Bor & Feiweil, 1969). These subjects appear to be predisposed to disease of the stomach, thyroid and adrenal glands, although close follow-up studies will be required to confirm this.

The onset of vitiligo is typically in young adult life; Lerner (1959) found that 89% noted its onset before 40 years of age. In patients with diabetes and vitiligo it has been found that only 24% developed vitiligo before 40 years of age (Dawber, 1968). Similar results were found in pernicious anaemia and vitiligo (Dawber, 1970). Late-onset vitiligo would thus appear to have a closer association with both diabetes and pernicious anaemia than vitiligo occurring at an earlier age.

Vitiligo is evidently another 'skin-marker of internal disease'. Patients with vitiligo appear to be predisposed to the development of thyroid disease, Addison's disease, pernicious anaemia, carcinoma of the stomach and diabetes mellitus and should thus be observed perhaps annually to exclude these diseases.

Acknowledgments

Thanks are due to Professor S. Shuster and Dr C. J. Stevenson for invaluable constructive criticism.

References

- ADDISON, T. (1855) *On the Constitutional and Local Effects of the Disease of the Supra-renal Capsule*, Plate XI. S. Highly, London.
- ALLISON, J.R. & CURTIS, A.C. (1955) Vitiligo and pernicious anaemia. *Archives of Dermatology*, **72**, 407.
- BOR, S., FEIWEIL, M. & CHANARIN, I. (1969) Vitiligo and its aetiological relationship to organ-specific auto-immune disease. *British Journal of Dermatology*, **81**, 83.
- BROSTOFF, J., BOR, S. & FEIWEIL, M. (1969) Vitiligo and auto-immunity. *Lancet*, *ii*, 177.
- CUNLIFFE, W.J., HALL, R., NEWELL, D.J. & STEVENSON, G.J. (1968) Vitiligo, thyroid disease and auto-immunity. *British Journal of Dermatology*, **80**, 135.
- DAWBER, R.P.R. (1968) Vitiligo in mature-onset diabetes mellitus. *British Journal of Dermatology*, **80**, 275.
- DAWBER, R.P.R. (1970) Integumentary associations of pernicious anaemia. *British Journal of Dermatology*, **82**, (*In press*).
- DUNLOP, D. (1963) 86 cases of Addison's disease. *British Medical Journal*, **2**, 887.
- FRANCIS, H.W. (1931) Achlorhydria as an aetiological factor in vitiligo. *Nebraska State Medical Journal*, **16**, 25.
- HABERMANN, R. (1933) *Handbuch der Haut und Geschlechtskrankheiten*, Vol. 2, p. 896. Springer-Verlag, Berlin.
- ISHIDA, K. (1954) Studies on gastric acidity in various skin diseases. *Japanese Journal of Dermatology and Venerology*, **64**, 145.
- LERNER, A.B. (1955) *Vitiligo*, Transactions, Pacific Dermatology association, p. 25.
- LERNER, A.B. (1959) Vitiligo. *Journal of Investigative Dermatology*, **32**, 285.
- MORGANS, M.E. (1964) *The Thyroid Gland*, Vol. 2, p. 159. Butterworth, London.
- ORMSBY, O.S. & MONTGOMERY, H. (1954) *Diseases of Skin*, 8th edn., p. 721. Lea & Febiger, Philadelphia.
- WRIGHT, P., VENABLES, C.W. & DAWBER, R.P.R. (1970) Vitiligo and carcinoma of stomach. *British Medical Journal*, (*In press*).