

Management of symptomatic liver cysts

A Pitale, A K Bohra, T Diamond

Accepted 29 May 2002

SUMMARY

Non-parasitic liver cysts are seen in up to 5% of the population. They become symptomatic when they are large and can cause pain, nausea, vomiting, early satiety and obstructive jaundice. Treatment modalities include percutaneous drainage, open deroofing, hepatic resection and lately, laparoscopic deroofing. We assessed our management of eleven symptomatic patients over the last five years between May 1996 and August 2001. Two of these had mild symptoms and were kept under review. The remaining nine were treated surgically. Of these, eight were treated by laparotomy and open deroofing with argon laser coagulation of the cut edges while one was treated with left hepatic resection. Three of these had been previously treated with laparoscopic deroofing at other hospitals and had been referred after having developed recurrent symptomatic cysts. Two patients developed post-operative complications - bile leakage that resolved with conservative management. The patients were followed up for a median period of twelve months ranging from 3-62 months. One patient died of liver failure 12 months after surgery. There was no symptomatic recurrence. We conclude that open cyst deroofing gives marked symptomatic relief with a very low complication rate. In today's era of laparoscopic surgery, it has a definite role in the management of symptomatic liver cysts, more so in recurrent cysts following laparoscopic treatment.

INTRODUCTION

Non-parasitic liver cysts are seen in up to 5% of the population.¹ These usually tend to be asymptomatic. When the whole liver is involved, Polycystic Liver Disease (PCLD) is presumed to exist.² Large cysts may cause symptoms, predominantly pain. Nausea, vomiting, obstructive jaundice and early satiety may be caused by the pressure effects of large cysts.³ Different treatment modalities have been used. They include percutaneous drainage, open deroofing, laparoscopic deroofing and hepatic resection. This study assesses our management of symptomatic liver cysts over the last five years.

METHODS

Between May 1996 and August 2001, nine patients underwent surgery for histologically proven non-parasitic cysts of the liver. Two patients with mild symptoms have not been operated on and have been kept under review. Patients were identified from the hepatobiliary database and records were reviewed for clinical presentation, preoperative investigations, surgery and follow-

up. CT scanning was performed in all patients to determine the extent of the disease and to help exclude parasitic cysts. Of the nine patients who underwent surgical treatment eight were treated by laparotomy and open deroofing while one was treated by left hepatic resection for extensive involvement of the left lobe by a large multilocular cyst. The major aim of surgery was to remove as much of the cyst wall as possible to prevent recurrence. A CUSA (Cavitron Ultra Sonic Aspirator) was used for liver resection. Three patients underwent synchronous cholecystectomy for coexistent gallstones.

RESULTS

Eleven patients with symptomatic cysts (9 women, 2 men) with a median age of 55 years (age range 49-81 yrs) were identified from the records. The

Mater Hospital Trust, Crumlin Road, Belfast BT14 6AB.

A Pitale, MBBS, MS, FRCS, Senior House Officer

A K Bohra, MBBS, MS, FRCS, Specialist Registrar

T Diamond, MD, FRCS, FRCSI, Consultant Surgeon

Correspondence to Mr Diamond

TABLE
Demography, clinical features, procedure and outcome

<i>Patient No.</i>	<i>Age Year/Sex</i>	<i>Presenting Symptoms</i>	<i>Previous Treatment</i>	<i>Procedure</i>	<i>Follow-up/ Results</i>
1	80/F	Pain, Nausea	Nil	Open cyst deroofing	3 months Symptom free
2	55/F	Pain	Nil	Open cyst deroofing	60 months Symptom free
3	49.5/F	Pain, Nausea	Nil	Open cyst deroofing+ Cholecyste- ctomy	47 months Symptom free
4	81/m	Pain	P.C.Aspiration, Laparoscopic deroofing	Open deroofing	22 months Symptom free
5	53/F	Pain, Nausea & vomiting	Laparoscopic deroofing	Open cyst deroofing	62 months Symptom free
6	78/F	Abdominal distension	PC. Aspiration, Laparoscopic deroofing	Open cyst deroofing+ Cholecyste- ctomy	10 months Symptom free
7	61/F	Pain, Abdominal distension	Nil	Left hepatic resection	62 months Symptom free
8	49/F	Pain	Nil	Open deroofing+ Cholecyste- ctomy	10 months Symptom free
9	51/F	Abdominal wall/ vein distension+ leg oedema due to IVC obstruction	Nil	Open cyst deroofing	12 months Died of liver failure
10	54/F	Mild Pain	Nil	Conservative Management	8 months
11	69/F	Mild Pain	Nil	Conservative Management	11 months

(P.C.: Per Cutaneous)

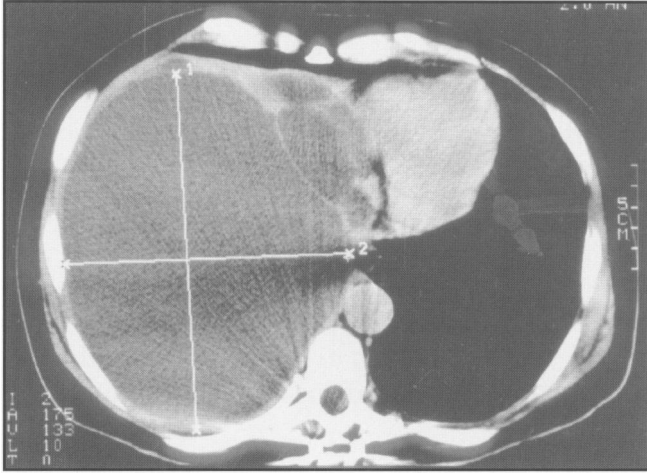


Fig 1. CT scan demonstrating multiple liver cysts in a patient with PCLD and one very large cyst. Surgical deroofing/cyst excision in such a patient achieves a very significant reduction on the mass effect and good symptom relief.

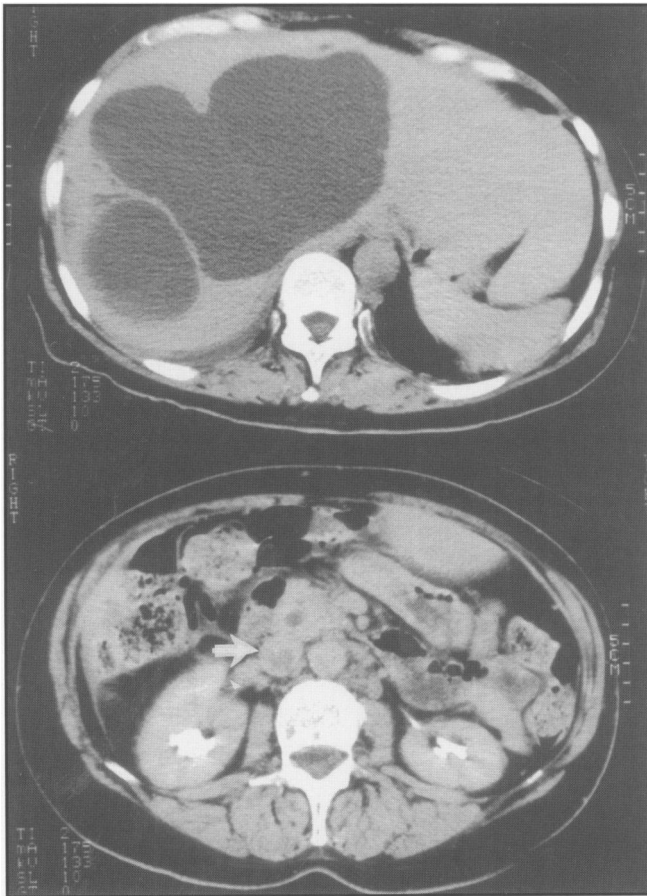


Fig 2. A large, centrally located cyst with vena caval compression and caval thrombosis.

main presenting complaints were pain (82%), abdominal distension (27.2%), nausea and/or vomiting (36.3%) (Table). Liver function tests were abnormal in 20% of patients. One patient with PCLD presented following a road traffic

accident. She sustained a spinal fracture but also developed a large haemorrhage into a liver cyst (Fig. 1). One patient with a very large cyst involving the right lobe and segment IV of the left lobe developed a thrombosis in the inferior vena cava (Fig. 2). One patient had polycystic liver disease and two had polycystic disease of both the liver and the kidneys. One patient with PCLD and mild symptoms has been treated conservatively. Of the nine patients treated surgically, two had undergone previous repeated aspirations followed by laparoscopic deroofing and one patient had undergone laparoscopic deroofing alone. These procedures had been carried out at other hospitals and all three patients developed recurrent symptomatic cysts. Two patients had a postoperative complication – bile leakage that resolved with conservative management.

Patients have been followed up for a median period of twelve months ranging from 3 - 62 months. One patient with polycystic liver disease (PCLD) was admitted twelve months after surgery with jaundice and deteriorating general health and died of liver failure. There has been no symptomatic recurrence of cysts in the other patients.

DISCUSSION

Simple liver cysts are thought to arise as a congenital aberration of bile duct development. The dominant cyst is usually accompanied by several smaller cysts.¹ When however, the whole liver is involved, PCLD is presumed to exist, which has a close association with polycystic disease of the kidneys.²

Liver cysts are normally asymptomatic and are usually detected incidentally during abdominal imaging.¹ Symptoms appear to be due to pressure effects with pain as the predominant feature. The stomach or duodenum may be compressed by the enlarged liver giving rise to nausea, vomiting and early satiety.³

It has been observed that symptomatic liver cysts occur ten times more commonly in women, usually at age 50-60 years with pain as the predominant symptom.¹ Our experience was similar with symptoms occurring more commonly in women (4:1) with an age range of 50-60 years and with pain as the predominant symptom. Most symptomatic liver cysts are benign but carcinoma arising in the wall of a cyst has been reported.⁴

Different treatment modalities have been used. Percutaneous aspiration appears to be a simple option. It is, however, associated with a high recurrence rate.⁵ Percutaneous aspiration with introduction of sclerosing agents has shown good results.⁶⁻⁷ Larssen *et al* injected alcohol in ten patients. There was reaccumulation of fluid in eight patients and this resolved over the next few months with no need for further alcohol sclerotherapy.⁶ The rate of symptomatic recurrence seems to be definitely reduced after percutaneous sclerotherapy.⁸

The technique of open cyst deroofing or fenestration was first described by Lin *et al* in 1968.⁹ It has been recommended by several groups and has been applied successfully for simple liver cysts.^{10,11} We have found it to be particularly successful when there are only one or several large cysts and a significant reduction in the 'mass' effect of the cysts can be achieved. For multiple smaller cysts (eg, 2-5 cms) as occurs usually in PCLD, deroofing/fenestration is not as effective, as the fibrous architecture of the liver and cysts remains intact and a significant reduction of the volume cannot be achieved. For these patients, resection is perhaps more appropriate.

More radical approaches like hepatic resection have been advocated for treatment of large cysts. It has been shown that hepatic resection is safe and effective and that symptomatic relief is complete and permanent except in cases of diffuse polycystic disease of the liver.¹² Total cystectomy and liver transplantation have been advocated in PCLD.^{13,14}

Laparoscopic deroofing of the liver cysts was first described in 1991.¹⁵ It has been advocated as the treatment of choice.¹⁶ Studies indicate that laparoscopic deroofing results in permanent cure in the majority of cases.¹⁷ Zacherl *et al* operated on eleven patients and only one developed recurrence.¹⁷ Klingler *et al* have reviewed the studies on laparoscopic treatment of liver cysts and pointed out that most studies have not quoted a recurrence rate.¹⁸ They advocate that recurrence should be made the end point and have cautioned that the general application of the minimally invasive technique should await a thorough evaluation of the operative complications and outcome in terms of cyst recurrence.¹⁸ Certainly, in our series, one third of the patients who required surgery had a previously failed laparoscopic procedure.

In conclusion, in view of the above findings, with no recurrence, marked symptomatic improvement and minimal complications after open deroofing, we conclude that open deroofing of liver cysts has a definite role in the management of patients with symptomatic liver cysts in this era of laparoscopic surgery and more so in the treatment of recurrent cysts after laparoscopic treatment.

REFERENCES

1. Caremani M, Vincenti A, Benci A, Sassoli S, Tacconi D. Echographic epidemiology of non-parasitic hepatic cysts. *J Clin Ultrasound* 1996; **21**(2): 115-8.
2. European PKD Consortium. The polycystic kidney disease 1 gene encodes a 14kb transcript and lies within a duplicated region on chromosome 16. *Cell* 1994; **77**: 881-94.
3. Lai E C, Wong J. Symptomatic non-parasitic cysts of the liver. *World J Surg* 1990; **14**(4): 452-6.
4. Kasai Y, Sasaki E, Tamaki A, Koshino I, Kawanishi N, Hata Y. Carcinoma arising in the cyst of the liver; report of three cases. *Jpn J Surg* 1977; **7**(2): 65-72.
5. Sanchez H, Gagner M, Rossi R L, Jenkins R L, Lewis W D, Munson J L, et al. Surgical management of nonparasitic cystic liver disease. *Am J Surg* 1991; **161**(1): 113-8.
6. Larssen T B, Viste A, Jensen D K, Sondenna K, Rokke O, Horn A. Single-session alcohol sclerotherapy in benign symptomatic hepatic cysts. *Acta Radiol* 1997; **38**(6): 993-7.
7. Polysalov V N, Oleshchuk N V. Puncture sclerosing treatment of nonparasitic liver cysts. Article in Russian. *Vestn Khir Im I-I-Grekova* 1997; **156**(5): 78-80.
8. Montorsi M, Torzilli G, Fumagalli U, Bora s, Rostai R, De Simone M, et al. Percutaneous alcohol sclerotherapy of simple liver cysts. Results from a multicentre survey in Italy. *HPB Surgery* 1994; **8**(2): 89-94.
9. Lin T Y, Chen C C, Wang S M. Treatment of non-parasitic cystic disease of the liver: a new approach to therapy of the polycystic liver. *Ann Surg* 1968; **168**(5): 921-7.
10. Doty J E, Tompkins R K. Management of cystic disease of the liver. *Surg Clin North Am* 1989; **69**(2): 285-95.
11. Edwards J D, Eckhauser F E, Knol J A, Strodel W E, Appelman H D. Optimizing surgical management of symptomatic solitary hepatic cysts. *Am Surg* 1987; **53**(9): 510-4.
12. Madariaga J R, Iwatsuki S, Starzi T E, Todo S, Selby R, Zetti G. Hepatic resection for cystic lesions of the liver. *Ann Surg* 1993; **218**(5): 610-4.
13. Que F, Nagorney D, Gross J B, Torres V E. Liver resection and cyst fenestration in the treatment of severe polycystic liver disease. *Gastroenterology* 1995; **108**(2): 487-4.

14. Starzi T E, Reyes J, Tzakis A, Miele L, Todo S, Gordon R. Liver transplantation for polycystic liver disease. *Arch Surg* 1990; **125(5)**: 575-7.
15. Paterson-Brown S, Garden O J. Laser-assisted laparoscopic excision of liver cyst. *Br J Surg* 1991; **78(9)**: 1047.
16. Diez J, Decoud J, Gutierrez L, Suhl A, Merello J. Laparoscopic treatment of symptomatic cysts of the liver. *Br J Surg* 1998; **85(1)**: 25-7.
17. Zacherl J, Scheuba C, Imhof M, Jakesz R, Fugger R. Long-term results after laparoscopic unroofing of solitary symptomatic congenital liver cysts. *Surg Endosc* 2000; **14(1)**: 59-62.
18. Klingler P J, Gadenstatter M, Schmid T, Bodner E, Schwelberger H G. Treatment of hepatic cysts in the era of laparoscopic surgery. *Br J Surg* 1997; **84(4)**: 438-44.