

Treatment of chronic experimental *Trypanosoma cruzi* infections in mice with MK-436, a 2-substituted 5-nitroimidazole

S.G. Andrade,¹ R.C. Silva,² & C.M.G. Santiago²

The antiprotozoal drug 3-(1-methyl-5-nitroimidazol-2-yl)-3a, 4,5,6,7,7a-hexahydro-1,2-benzisoxazole (MK-436) is highly efficacious for treating mice chronically infected with different strains of Trypanosoma cruzi. The compound was administered by gavage in two daily doses of 250 mg per kg body weight to 130 mice that had been infected for 90 to 400 days with either type II or III strains of T. cruzi. The following parasitological cure tests were carried out: xenodiagnosis, haemoculture, and inoculation of blood into newborn mice. Indirect immunofluorescence tests and histopathological studies were also performed.

The results indicate that the drug is highly efficacious against chronic infection caused by both type II (cure rate, 90%) and type III strains (cure rate, 95.7%). Histopathological examinations showed complete clearance of the cardiac and muscular lesions in 36% of the mice infected with type II strains and a decrease in the intensity and extension of the lesions in mice infected with type III strains. Indirect immunofluorescence tests were persistently positive for all the mice 3–6 months after the treatment.

Of the several compounds that are effective in treating the acute phase of experimental infection with *Trypanosoma cruzi* (1–6), some produce high cure rates among mice. However, it has been difficult to evaluate the cure rate of chronic infections since during this phase the level of parasites both in peripheral blood and in cells is low, and the results of indirect immunofluorescence antibody tests (IFAT) may be persistently positive in animals that exhibit parasitological cure (7).

Murray et al. have described the efficacy of two 2-substituted 5-nitroimidazoles (MK-436 and L 634, 549) during the early and late (8 weeks) phase of *T. cruzi* infections (6). Also Andrade et al. have shown that administration of MK-436 to mice acutely infected with different strains of *T. cruzi* results in high cure rates (7). Even those strains that are highly resistant to benzimidazole and nifurtimox (2) are susceptible to MK-436.

We report here the results of an investigation to determine the effectiveness of MK-436 against chronic infection with different strains of *T. cruzi*, as well as the influence of treatment with MK-436 on tissue lesions and on the outcome of serological tests.

Materials and methods

As test animals, 130 chronically infected Swiss mice that had survived virulent infection with *T. cruzi* for

90–400 days were used. The mice had previously been inoculated intraperitoneally with the blood of infected mice that contained 1×10^4 to 5×10^4 blood trypomastigotes from different strains of *T. cruzi* (Table 1). Strains were characterized biologically as type II or type III according to a procedure described by Andrade (8) and following recommendations made by WHO (9). Infection with type II strain results in slowly increasing parasitaemia, with peaks between the 12th and 20th days of infection, predominance of broad parasite forms in circulating blood, and myocardiotropism; on the other hand, infection with type III strain leads to a slower increase in parasitaemia, with peaks around the 20th to 30th days of infection, predominance of broad parasite forms, and an intense skeletal muscle tropism (8).

The mice were divided into the following groups: 80 that received chemotherapy and 50 that remained as untreated controls. Only results from the 67 mice that received treatment and the 47 untreated mice which survived until the end of the experiments and were evaluated parasitologically, serologically, and histopathologically were used (Table 1).

Treatment

Mice were administered MK-436 (3-(1-methyl-5-nitroimidazol-2-yl)-3a,4,5,6,7,7a-hexahydro-1,2-benzisoxazole)^(6,7) by gavage in two daily doses of 250 mg

¹ Associate Professor, Universidade Federal da Bahia, Centro de Pesquisas Gonçalo Moniz, Rua Valdemar Falcão, 121-Brotas, Salvador, Bahia, Brazil. Requests for reprints should be sent to this address.

² Biologists, Universidade Federal da Bahia, Centro de Pesquisas Gonçalo Moniz, Salvador, Bahia, Brazil.

Reprint No. 5007

Bulletin of the World Health Organization, 67 (5): 509–514 (1989)

* Merck, Sharp & Dohme Research Laboratories, Rahway, NJ 07065, USA.

Table 1: General data on the mice that were chronically infected with different strains of *Trypanosoma cruzi* and given chemotherapy with MK-436

Strain of <i>T. cruzi</i>	No. of mice treated	No. of controls	Parasitological cure rate (%)	No. serologically negative by IFAT
Type II ^a	44	25	90	0
Type III ^b	23	22	95.7	0
Total	67	47	—	—

^a Strains: 10-Mont, 12-Mont, 15-Mont, 16-Mont, 18-Mont, 20-Mont, 22-Mont, and 24-Mont (Montalvania strains); 02-Coteg. (Cotegipe strain); 05-Mam and 13-Mam (Mambai strains); and 12-SF (São Felipe strain).

^b Strains: 13-Mont, 19-Mont (Montalvania strains); Bolivian strain; and Colombian strain.

per kg body weight. The duration of treatment was 30 days for 47 mice and 60 days for 20.

Evaluation of the results

Before being killed for histopathological study, parasitological and serological tests were carried out on the mice that were treated with MK-436. Parasitological cure tests, consisting of xenodiagnosis with five 4th–5th stage *Rhodnius prolixus* nymphs, direct examination of peripheral blood, inoculation of 0.1-ml samples of this blood into five newborn mice, and haemoculture, were performed 30–90 days after the treatment. Serological evaluations were carried out using IFAT, as described by Camargo (10), with cultured forms of *T. cruzi* as antigens, serum dilutions from 1:10 to 1:80, and antimouse IgG fluorescein conjugate at a dilution of 1:80.

Results

The parasitological cure rates and serological responses are shown in Table 1. No significant differences in the proportions of parasitological tests that were negative were detected between mice treated for 30 or 60 days. Cure rates of 90% were achieved for infections with the type II strain and of 95.7% for those with type III strain (Table 1). All of the treated mice had positive IFAT results, with titres that varied from 1:10 to 1:80, as evaluated 3 to 6 months after treatment.

Histopathological findings

The severity of myocarditis and myositis was graded on a three-point scale: +, for mild and focal perivascular, interstitial, or subepicardic mononuclear infiltration; ++, for moderate, diffuse, and focal inflammatory lesions, as well as focal destruction of muscle cells; and +++, for diffuse and severe inflammatory changes with extensive lesions of muscle fibres and dense focal mononuclear infiltration. Necrotizing arteriolitis, both in the skeletal muscle and myocardium, was also detected in various grade categories.

In the untreated control mice, the histopathological lesions ranged from mild and focal (+) to diffuse and severe (+++), as shown in Table 2. Myocardial lesions predominated in infections with type II strain and skeletal muscle involvement with type III. Type III infections exhibited predominantly arteriolar lesions (Fig. 1a–f).

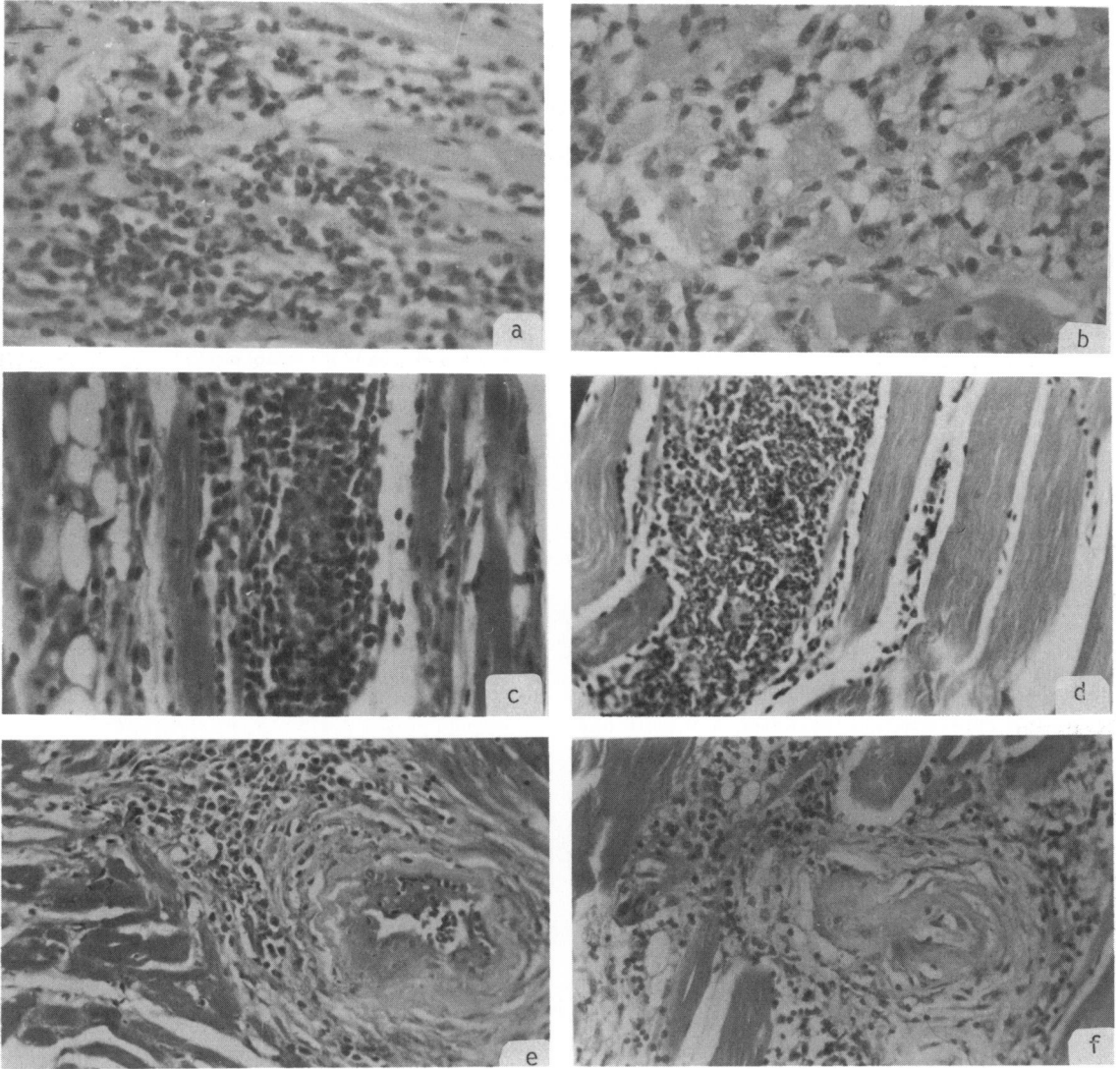
Table 2: Distribution of tissue lesions in untreated control mice that were chronically infected with type III strains of *Trypanosoma cruzi*

Strain code ^b	Degree of inflammatory lesions ^a		
	Myocarditis	Myositis	Arteriollitis
Bol-1	+	+++	+++
Bol-2	+	+++	+++
Bol-3	+	++	+
Bol-4	+	+	—
Bol-5	++	+++	+++
Bol-6	+	+++	+++
Bol-7	+	+	++
Bol-8	+	+++	+++
Bol-9	+	+	+
Col-1	++	+++	++
Col-2	++	++	—
Col-3	+	++	—
Col-4	++	++	++
Col-5	+	++	—
Col-6	++	++	—
Col-7	+	+	—
Col-8	++	+	—
Col-9	++	++	—
Col-10	++	++	—
Mont-1	++	+	—
Mont-2	+	++	++
Mont-3	++	+	—

^a (+): mild and focal perivascular, interstitial, or subepicardic mononuclear infiltration; (++) moderate, diffuse, and focal inflammatory lesions, as well as focal destruction of muscle cells; (+++): diffuse and severe inflammatory changes with extensive lesions of muscle fibres and dense focal mononuclear infiltration; and (—): no inflammatory lesion.

^b Bol-1–9: Bolivian strains; Col-1–10: Colombian strains; and Mont-1 and Mont-2 = 13-Montalvania strain, and Mont-3 = 19-Montalvania strain.

Fig. 1. Histopathological lesions observed in the untreated control mice: (a) and (b) myocardium, showing diffuse infiltration of mononuclear cells; (c) and (d) skeletal muscle, showing destruction of muscle fibres, marked infiltration of focal inflammatory cells, and interstitial fatty infiltration; and (e) and (f) focal necrotizing arteriolitis in the myocardium and skeletal muscle, respectively.



Treated mice

Of mice that were infected with type II strains, complete clearance of the cardiac and muscular lesions occurred in 36% (16 out of 44); mild and focal lesions (+) were present in 52% (23 out of 44); moderate alterations (++) in 9% (4 out of 44); and necrotizing arteriolitis in 8.6%. All the mice infected with type III strains (Table 3) that were treated exhibited mild (59%) or moderate lesions (41%), while mild to moderate

necrotizing arteriolitis was detected in 22% of such mice (Fig. 2a-c). All the mice infected with type II strains without cardiac or skeletal muscle lesions were parasitologically negative.

As shown in Table 3, the persistence of inflammatory lesions in the myocardium or in skeletal muscle was most prominent in the mice infected with type III strains; such lesions were mild to moderate,

Table 3: Frequency of histopathological lesions of the myocardium and skeletal muscle in mice that were chronically infected with *Trypanosoma cruzi* and treated with MK-436, compared with untreated infected controls

Grade of lesion*	Infection with type II strain		Infection with type III strain	
	Untreated controls (%)	Treated mice (%)	Untreated controls (%)	Treated mice (%)
+	46.0	52.0	13.6	59.0
++	38.4	9.0	50.0	41.0
+++	15.4	0.0	27.0	0
Necrotizing arteriolitis	46.0	8.6	50.0	22.0
No lesions	0	36.0	0	0

* For explanation, see footnote a, Table 2.

generally perivascular and with a focal distribution. Persistent arteriolar lesions were exhibited by a significant proportion of treated mice, mostly those infected with type III strains, but only in two of 22 mice was the severity moderate (++) (Table 4 and Fig. 2c).

Comments

The results reported here confirm the curative efficacy of MK-436 against experimental *T. cruzi* infections (9), even for those in the chronic phase. Parasitological cure rates were high, both for infections with type II (90%) and type III strains (95.7%). It should be noted that strains characterized biologically as type III were highly resistant to treatment with either benznidazole or nifurtimox during the acute phase of infection (2). All treated and parasitologically cured mice exhibited persistently positive IFAT results. As previously suggested (2,9), negative parasitological tests are the most acceptable cure criterion. However, Cançado has postulated that only negative results in serological tests provide evidence of cure from Chagas disease after chemotherapy (11). For example, among chronic human cases of Chagas disease that were treated either with benznidazole or nifurtimox, Cançado reported cure rates that were very low or zero with persistently positive serological tests (11). However, follow-up studies on some of the treated patients surprisingly found that they were serologically negative 5 years after treatment. Both the data we have reported here and the above-mentioned clinical results (11) indicate that positive post-treatment serological tests may be transient and dependent on the presence of residual antigenic stimulation. To investigate this further, we immunolabelled specific *T. cruzi* antigens with peroxidase and demonstrated by immunoelectronmicroscopy that it binds to the dendritic cells of the spleen (12). The results were positive 3 to 6 months after treatment for mice that were parasitologically cured and that had positive IFAT results. The index of cure, obtained independently of negative serological tests, therefore indicates that chronic *T. cruzi* infections can be cured by chemotherapy with MK-436.

The importance of these observations is empha-

Fig. 2. Histopathological lesions observed in some treated and parasitologically cured mice: (a) mild focal myocarditis; (b) fibrosis and focal mononuclear infiltration of cardiac muscle; and (c) focal arteriolitis (grade ++) in the skeletal muscle, observed in two of 22 treated mice infected with type III (Bolivian) strain.

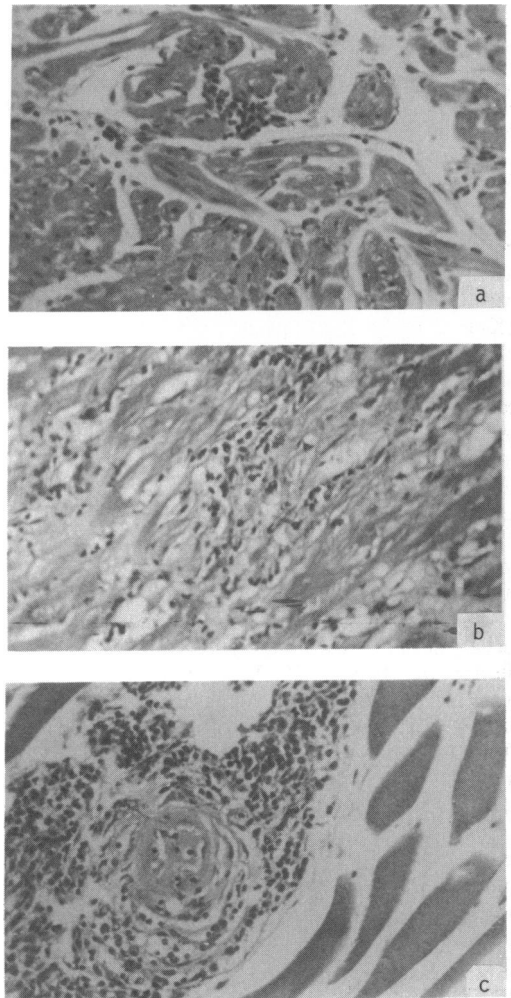


Table 4: Distribution of tissue lesions in mice chronically infected with type III strains of *Trypanosoma cruzi* and treated with MK-436

Identification	Degree of inflammatory lesions ^a			Result of parasitological test
	Myocarditis	Myositis	Arteriolitis	
Cr-MK-Col-1	++	++	++	-ve
Cr-MK-Col-2	+	-	-	-ve
Cr-MK-Col-3	-	-	-	-ve
Cr-MK-Col-4	++	+	-	-ve
Cr-MK-Col-5	++	+	+	+ve
Cr-MK-Col-6	+	-	-	-ve
Cr-MK-Col-7	+	+	-	-ve
Cr-MK-Col-8	+	-	-	-ve
Cr-MK-Bol-1	+	+	+	-ve
Cr-MK-Bol-2	++	++	-	-ve
Cr-MK-Bol-3	+	-	-	-ve
Cr-MK-Bol-4	++	-	-	-ve
Cr-MK-Bol-5	+	-	-	-ve
Cr-MK-Bol-8	+	+	-	-ve
Cr-MK-Bol-9	++	+	-	-ve
Cr-MK-Bol-10	+	++	++	-ve
Cr-MK-Bol-11	+	-	-	-ve
Cr-MK-Bol-12	+	++	+	-ve
Cr-MK-Bol-13	-	+	-	-ve
Cr-MK-Mont-12	++	+	-	-ve
Cr-MK-Mont-15	+	-	-	-ve
Cr-MK-Mont-16	+	+	-	-ve

^a For explanation, see footnote a, Table 2.

sized by the fact that histopathological lesions in untreated controls totally or partly subsided in a significant proportion of mice that were treated with MK-436. A similar regression has previously been described by Andrade & Andrade for nifurtimox. (13)

Although mild-to-moderate inflammatory lesions occurred in some treated and apparently cured mice, mainly those infected with type III strains of *T. cruzi*, they were never severe. The presence of persistent necrotizing arteriolitis in treated mice, a frequent finding in those that are chronically infected with *T. cruzi* (13, 14), has been interpreted as evidence for the presence of circulating immunocomplexes, probably caused by prolonged antigenic stimulation.

In Chagas disease delayed-type hypersensitivity mechanisms are involved in the development of chronic inflammatory lesions (15). In view of the results of the present investigation, such mechanisms are apparently correlated with patent parasitism, since parasitological cure may determine clearance of inflammatory lesions or its partial regression. This inflammatory process in infected and untreated mice (12) appears as a diffuse and focal mononuclear infiltration, with predominance of macrophages, as confirmed by electronmicroscopy (14), and is associated with active fibrosis, a typical feature of chronic Chagas disease myocarditis. In delayed-type hypersensitivity, enhanced collagen synthesis is observed (16). It is therefore important that parasitological cure of a proportion of

chronically infected mice also causes histopathological lesions to regress or disappear, even when serological tests are persistently positive.

Acknowledgements

This investigation was supported financially by the UNDP/World Bank/WHO Special Programme for Research and Training in Tropical Diseases and by the National Council for Scientific and Technological Development (CNPq), Brazil. Merck, Sharp & Dohme Research Laboratories, Rahway, NJ, USA, are thanked for supplying samples of MK-436.

Résumé

Traitement des infections expérimentales chroniques à *Trypanosoma cruzi* chez la souris avec le MK-436, un dérivé du nitro-5 imidazole

Le traitement des infections à *Trypanosoma cruzi* en phase chronique présente des difficultés et les données disponibles sont rares et se prêtent mal à l'évaluation. Certains composés ont fait la preuve de leur efficacité antiparasitaire dans la phase aiguë de la maladie, que ce soit chez l'homme ou chez l'animal d'expérience. Parmi ceux-ci, le MK-

436 (un nitro-5 imidazole substitué en position 2) qui n'a fait l'objet jusqu'ici que d'essais expérimentaux, a un effet trypanosomicide certain *in vivo* et il donne un taux de guérison élevé chez les souris présentant une infection aiguë à *T. cruzi*. L'étude décrite ici a permis de vérifier expérimentalement l'efficacité de cette substance dans la phase chronique de l'infection chez la souris et d'évaluer son effet sur les lésions histopathologiques.

Dans cette étude, 130 souris présentant une infection chronique à *T. cruzi* ont été traitées avec le MK-436. L'infection durait depuis 90 à 400 jours et avait été provoquée par l'inoculation de 1×10^4 à 5×10^4 trypomastigotes sanguins. Les souches de *T. cruzi* ayant servi à infecter les souris avaient été précédemment identifiées comme appartenant au type II ou au type III, d'après leurs caractéristiques biologiques. Le médicament a été administré par gavage en deux doses journalières de 250 mg/kg de poids corporel. Les résultats ont été évalués par des épreuves parasitologiques (xénodiagnostic, inoculation secondaire à des souris nouveau-nées et hémoculture), ainsi que par des épreuves d'immunofluorescence indirecte et par des examens histopathologiques.

Le taux de guérison parasitologique a été de 90% chez les souris infectées avec la souche de type II et de 95,7% chez celles infectées avec la souche de type III. Les résultats des épreuves d'immunofluorescence indirecte étaient encore positifs 3 à 6 mois après le traitement. Par comparaison avec les témoins non traités, les lésions histopathologiques ont complètement disparu après traitement chez 36% des souris infectées avec la souche de type II. Des lésions histopathologiques de gravité faible à modérée, notamment des infiltrations du myocarde et des muscles squelettiques ainsi qu'une artériolite nécrosante ont persisté chez certains animaux traités, surtout parmi ceux qui avaient été infectés avec la souche de type III.

Cette étude montre qu'un traitement par le MK-436 peut amener la guérison parasitologique et la régression des lésions cardiaques chez des souris présentant une infection chronique à *T. cruzi*.

References

1. Brener, Z. Recent advances in chemotherapy of Chagas disease. *Memórias do Instituto Oswaldo Cruz*, **79** (suppl.): 149–155 (1984).
2. Andrade, S.G. et al. Evaluation of chemotherapy with benznidazole and nifurtimox in mice infected with *Trypanosoma cruzi* strains of different types. *Bulletin of the World Health Organization*, **63**: 721–726 (1985).
3. Avila, J.L. & Avila, A. *Trypanosoma cruzi*: allopurinol in the treatment of mice with experimental acute Chagas' disease. *Experimental parasitology*, **51**: 204–208 (1981).
4. McCabe, R.E. et al. Ketoconazole inhibition of intracellular multiplication of *T. cruzi* and protection of mice against lethal infection with the organism. *Journal of infectious diseases*, **150**: 594–601 (1984).
5. Filardi, L. & Brener, Z. A nitroimidazole-thiazole derivative with curative action in experimental *Trypanosoma cruzi* infections. *Annals of tropical medicine and parasitology*, **76**: 293–297 (1982).
6. Murray, P.K. et al. *Trypanosoma cruzi*: efficacy of the 2-substituted 5-nitroimidazoles MK-436 and L634,549 in tissue culture and mice. *American journal of tropical medicine and hygiene*, **32**: 1242–1250 (1983).
7. Andrade, S.G. et al. Therapeutic action of MK-436 (2,5-nitroimidazole) on *Trypanosoma cruzi* in mice: a parasitological, serological, histopathological and ultrastructural study. *Bulletin of the World Health Organization*, **65**: 625–633 (1987).
8. Andrade, S.G. Morphological and behavioural characterization of *T. cruzi* strains. *Revista da Sociedade Brasileira de Medicina Tropical*, **18**: 39–46 (1985).
9. WHO research activities of the Scientific Working Groups (SWG) in Chagas' disease—1982–1985. *Memórias do Instituto Oswaldo Cruz*, **81** (suppl.): 199–244 (1986).
10. Camargo, M.E. Fluorescent antibodies test for the diagnosis of American trypanosomiasis: technical modification employing preserved culture forms of *Trypanosoma cruzi* in a slide test. *Revista do Instituto de Medicina Tropical de São Paulo*, **8**: 227–234 (1966).
11. Cançado, R. [Specific treatment]. In: Cançado, R. & Chuster, M., ed. *Cardiopatía chagásica*. Belo Horizonte, Fundação Carlos Chagas, 1985, pp. 327–355 (in Portuguese).
12. Andrade, S.G. et al. *Trypanosoma cruzi* antigens detected by immunoelectronmicroscopy in the spleen of mice serologically positive but parasitologically cured by chemotherapy. (Preliminary report). *Revista da Sociedade Brasileira de Medicina Tropical*, **21**: 41–42 (1988).
13. Andrade, S.G. & Andrade, Z.A. [Anatomopathological aspects and therapeutic response in chronic experimental Chagas disease]. *Revista do Instituto de Medicina Tropical de São Paulo*, **23**: 245–250 (1976) (in Portuguese).
14. Andrade, S.G. & Grimaud, J.A. Chronic murine myocarditis due to *Trypanosoma cruzi* — an ultrastructural study and immunochemical characterization of the cardiac interstitial matrix. *Memórias do Instituto Oswaldo Cruz*, **81**: 29–41 (1986).
15. Andrade, Z.A. et al. Enhancement of chronic *Trypanosoma cruzi* myocarditis in dogs treated with low doses of cyclophosphamide. *American journal of pathology*, **127**: 467–473 (1987).
16. Boros, D.L. et al. The artificial granuloma. III. Collagen synthesis during the cell-mediated granulomatous response as determined in explanted granulomas. *Clinical immunology and immunopathology*, **18**: 276–286 (1981).