

## Feline Leukemia Virus Infection as a Potentiating Cofactor for the Primary and Secondary Stages of Experimentally Induced Feline Immunodeficiency Virus Infection

NIELS C. PEDERSEN,<sup>1\*</sup> MICHAEL TORTEN,<sup>2</sup> BRUCE RIDEOUT,<sup>1</sup> ELIZABETH SPARGER,<sup>1</sup> TULLIA TONACHINI,<sup>1</sup> PAUL A. LUCIW,<sup>3</sup> CHRISTOPHER ACKLEY,<sup>4</sup> NORMAN LEVY,<sup>3</sup> AND JANET YAMAMOTO<sup>1</sup>

*Departments of Medicine, School of Veterinary Medicine,<sup>1</sup> and Medical Pathology, School of Medicine,<sup>3</sup> University of California, Davis, California 95616; The Israel Institute of Biological Research, School of Medicine, Tel Aviv University, Tel Aviv, Israel<sup>2</sup>; and the Cellular Immunobiology Unit of the Tumor Institute, Departments of Pediatrics and Microbiology, University of Alabama, Birmingham, Alabama 35294<sup>4</sup>*

Received 2 August 1989/Accepted 5 October 1989

**Preexistent feline leukemia virus (FeLV) infection greatly potentiated the severity of the transient primary and chronic secondary stages of feline immunodeficiency virus (FIV) infection. Of 10 FeLV-FIV carrier cats, 5 died of experimentally induced FIV infection, compared with 2 deaths in 10 cats infected only with FeLV and 1 death in 7 cats infected only with FIV. FIV-infected cats with preexistent FeLV infections developed severe depression, anorexia, fever, diarrhea, dehydration, weight loss, and leukopenia 4 to 6 weeks after infection and were moribund within 2 weeks of the onset of signs, whereas cats infected only with FIV developed much milder self-limiting gross and hematologic abnormalities. Pathologic findings in dually infected cats that died were similar to those observed previously in cats dying from uncomplicated primary FIV infection but were much more widespread and severe. Coinfection of asymptomatic FeLV carrier cats with FIV did not increase the levels of FeLV p27 antigen present in their blood over that seen in cats infected with FeLV alone. The amount of proviral FIV DNA was much higher, however, in dually infected cats than in cats infected only with FIV; there was a greater expression of FIV DNA in lymphoid tissues, where the genome was normally detected, and in nonlymphoid tissues, where FIV DNA was not usually found. Dually infected cats that recovered from the primary stage of FIV infection remained more leukopenic than cats infected with FIV or FeLV alone, and their CD4<sup>+</sup>/CD8<sup>+</sup> T-lymphocyte ratios were inverted. One of these cats developed what was considered to be an opportunistic infection. It was concluded, therefore, that a preexistent FeLV infection in some way enhanced the expression and spread of FIV in the body and increased the severity of both the resulting transient primary and chronic secondary stages of FIV infection. This study also demonstrated the usefulness of the FIV model in studying the role of incidental infectious diseases as cofactors for immunodeficiency-causing lentiviruses.**

There is a great deal of interest in identifying cofactors that might accelerate the development of the acquired immunodeficiency syndrome (AIDS) stage of human immunodeficiency virus (HIV) infection in asymptomatic individuals (58). Some studies indicate that time itself is the sole cofactor for the progression of HIV infection to the AIDS stage (20). Time alone does not explain the differences that occur in both the rate of transmission and the clinical expression of HIV-related disease in various geographic regions of the world, races, and risk groups, however (5, 7, 30, 43, 53, 57). One theory is that recurrent immune stimulation, mainly from incidental infectious diseases, will accelerate the decline of the immune system and the onset of AIDS in HIV-infected people (6, 23, 29, 45, 49, 62).

Although the theory that incidental infectious diseases may act as cofactors in HIV infection is highly plausible, it is a difficult postulate to prove. People with AIDS have both serologic and microbiologic evidence of increased exposure to a number of common and opportunistic infectious agents (7, 12, 24, 26, 33, 42, 55). It is difficult to ascertain, however, whether these various coinfections contribute anything to the progressive decline of the immune system. Venereal infections are thought to increase the transmission of HIV infection by rendering the mucous membranes more susceptible to virus or virus-infected cell penetration and by

increasing the levels of infected lymphocytes in the semen (18, 43, 44, 59). Whether this increased exposure alters the course of the subsequent HIV infection is unknown. Most HIV-infected people are coinfecting with hepatitis B virus, but there is no evidence that either disease is made worse (24). In fact, one individual with active hepatitis had a remission of liver disease when superinfected with HIV (34). There is currently a great deal of interest in coinfection of AIDS patients with human herpesvirus 6, a newly recognized T-lymphotropic virus (26). The significance of this observation is unknown, because many normal HIV-infected and noninfected people have also been exposed to this virus. Cytomegalovirus infection is one of the most common coinfections in HIV-infected people and has been suggested as a cofactor for the development of AIDS and Kaposi's sarcoma (12). Normal people acutely infected with cytomegalovirus have many abnormalities in various *in vitro* immunologic parameters (48). There is no evidence that cytomegalovirus infection augments the immunosuppression caused by HIV-1 infection *in vivo*, however (33). It has been theorized, but not scientifically proven, that mycobacterial infections in developing countries might enhance the progression of HIV infection to AIDS (6, 23). Indeed, as many as one-fourth of Africans with disease syndromes that meet the World Health Organization or Bangui criteria for HIV-induced AIDS have no serological evidence of HIV infection (7, 11). This suggests that diseases, or combinations of

\* Corresponding author.

diseases, other than HIV infection may induce AIDS-like conditions. If infections other than HIV can cause AIDS-like syndromes, it stands to reason that they may also act additively or synergistically with HIV infection to cause a more severe disease syndrome than either alone.

Although circumstantial evidence indicates that other infectious diseases may act as cofactors for HIV infection, it is a difficult theory to experimentally prove in people. Several animal models of HIV infection are available that might be applicable to such cofactor studies. Simian immunodeficiency virus (SIV) infection is very close to the human disease, but monkeys are at short supply, and pathogen-free populations are nonexistent. Feline immunodeficiency virus (FIV) has a pathogenesis similar to that of HIV infection (37, 61), and because cats are both plentiful and available in specific-pathogen-free (SPF) status, they might prove to be an ideal model for infectious disease cofactor studies.

Infection with FIV is usually associated with direct inoculation of the virus into the body via bites (60), and there is a distinct transient initial stage of infection that follows exposure by several weeks (61). After recovery from this initial disease, afflicted cats enter into a long asymptomatic stage of the infection that lasts for months or years before other signs appear. The terminal secondary or AIDS stage of FIV infection is associated with a number of chronic common and opportunistic-type infections (19, 60). Like HIV infection of humans, other infectious diseases may interact with FIV infection in the field to cause a more severe disease syndrome. One common interaction in nature is between FIV infection and other retroviruses such as feline leukemia virus (FeLV) (15, 19, 60). About 10 to 15% of the cats that are clinically ill with FIV infection are coinfecting with FeLV (19, 60). FeLV is of particular significance because it can also induce immunodeficiency (16, 51).

Since two different immunodeficiency-causing retroviruses infect cats, we were interested in seeing whether coinfection with both viruses would lead to any alterations in the disease over that observed with either virus alone. To this end, groups of asymptomatic FeLV-infected and uninfected cats were experimentally created. A portion of each group was then experimentally coinfecting with FIV, and the subsequent disease course was monitored in all of the animals.

## MATERIALS AND METHODS

**Experimental animals.** SPF domestic cats were obtained from the breeding colony of the Feline Retrovirus Research Laboratory, University of California, Davis. Animals were housed in facilities of the Animal Resource Services at that institution.

**Naturally FIV infected cats.** Cats with naturally acquired FIV infection that were FeLV p27 antigenemia negative and suffering from terminal AIDS-like disease were seen in the Veterinary Medical Teaching Hospital, School of Veterinary Medicine, University of California, Davis. Tissues were taken at the time of necropsy for later gene amplification studies.

**Experimentally induced FeLV and FIV infections.** Cats were experimentally infected with the CT600 strain of FeLV as previously described (38, 39). The CT600 strain was originally isolated from a leopard cat (46) and was selected for this study because of its proven ability to activate latent or subclinical feline infectious peritonitis virus infection (35). Feline infectious peritonitis is an opportunistic-type disease caused by a coronavirus (36). After infection, FeLV p27

TABLE 1. Vital statistics and experimental design of FIV-FeLV cofactor study

Group	Cat no.	Sex <sup>a</sup>	Infection status	Study	Age (mo) at time of:	
					Infection with:	
					FeLV	FIV
1	3325	F	Noninfected	14		
	3335	F	Noninfected	14		
	3337	F	Noninfected	14		
2	3328	F	FIV	14		14
	3392	F	FIV	14		14
	3401	M	FIV	13		13
	3408	M	FIV	13		13
	3394	M	FIV	13		13
	3399	M	FIV	17		17
	3411	M	FIV	15		15
3	3383	F	FeLV	14	10	
	3384	F	FeLV	14	10	
	3385	M	FeLV	14	10	
	3387	F	FeLV	14	10	
	3390	F	FeLV	14	10	
	3395	F	FeLV	11	7	
	3400	M	FeLV	11	7	
	3402	F	FeLV	11	7	
	3406	M	FeLV	11	7	
	3410	M	FeLV	9	5	
4	3378	F	FeLV + FIV	11	7	11
	3386	F	FeLV + FIV	14	10	14
	3389	F	FeLV + FIV	14	10	14
	3391	F	FeLV + FIV	14	10	14
	3397	F	FeLV + FIV	14	10	14
	3398	M	FeLV + FIV	11	7	11
	3403	M	FeLV + FIV	11	7	11
	3404	F	FeLV + FIV	11	7	11
	3405	F	FeLV + FIV	11	7	11
	3407	M	FeLV + FIV	11	7	11

<sup>a</sup> F, Female; M, male.

antigenemia was monitored by an antigen-capture enzyme-linked immunosorbent assay (ELISA) (27). About one-third of the experimentally infected cats either were never detectably viremic after infection or were transiently antigenemic for 1 to 4 weeks. These cats made a full recovery and were still nonantigenemic 4 to 6 months later. Two-thirds of the FeLV-infected cats remained persistently antigenemic and were still antigenemic 4 months later, at the beginning of the study described here. Previous studies have shown that such cats will almost always remain life-long carriers of FeLV and die of a number of FeLV-related diseases within 3 years (40).

FIV infection was induced by inoculating each cat intravenously with 0.5 ml of whole heparinized blood collected from a chronic FIV carrier cat. The donor cat (no. 39) was selected from a larger number of infected cats because it showed signs of persistent leukopenia and had an inverted CD4<sup>+</sup>/CD8<sup>+</sup> T-cell ratio even though it was otherwise asymptomatic.

**Experimental design.** A total of 30 cats were selected for the study and assigned to one of four experimental groups (Table 1). Twenty of the cats had been experimentally infected with FeLV and were chronic asymptomatic carriers for 4 months. Seven cats were age-, litter-, and sex-matched FeLV-recovered animals that had been aviremic for the same period of time, and three animals were never exposed to FeLV or other pathogens. All 30 cats in the experiment were observed daily for clinical signs of disease over a period of almost 9 months after FIV infection. Rectal tem-

peratures were taken daily for the first 8 weeks of the experiment and at 2- to 7-day intervals thereafter. Blood was taken by jugular vein phlebotomy every week.

**Complete blood counts.** Complete blood counts included electronic total leukocyte (WBC) and erythrocyte counts, microhematocrit, total blood platelet count by hemacytometer, and WBC differential from Wright-Leishman-stained blood smears.

**FeLV antigen and FIV antibody tests.** The presence of the 27,000-dalton major core protein of FeLV was measured in serum by an antigen-capture ELISA (27). FeLV p27, used for preparation of a standard ELISA curve, was purified by immunoaffinity column chromatography by procedures previously described (39) except that mouse monoclonal antibodies to FeLV p27 were used for antigen capture. Antibodies to FIV were measured by an indirect immunofluorescence assay, using Crandell feline kidney cells chronically infected with the Petaluma strain of FIV as a substrate (60).

**Measurement of CD4<sup>+</sup> and CD8<sup>+</sup> feline T cells.** Mouse monoclonal antibodies to feline CD4<sup>+</sup> (C. D. Ackley, E. A. Hoover, and M. D. Cooper, submitted for publication) and CD8<sup>+</sup> (22) T-cell surface markers were kindly provided by Max Cooper, University of Alabama, Birmingham. Peripheral blood mononuclear cell fractions were isolated from 5 ml of heparinized blood by Ficoll-Hypaque gradient purification and then screened for CD4<sup>+</sup> and CD8<sup>+</sup> cell surface markers by fluorescence-activated cytometry (22; Ackley et al., submitted).

**Gross and microscopic pathology.** Cats were euthanized with an overdose of intravenous barbiturate when they failed to respond to routine symptomatic supportive therapy (fluid and electrolyte replacement and systemic antibiotics) and it became apparent that their disease course would probably be terminal without extreme therapeutic measures. Tissues were fixed in Carson fixative and processed routinely for histopathology. Fixed tissue sections were stained with hematoxylin and eosin. Special stains, when necessary, consisted of Brown and Brenn, Fite acid fast, periodic acid-Schiff, and Gomori methenamine.

**Detection of FIV DNA by gene amplification techniques.** Oligonucleotides were synthesized in a gene assembler, using  $\beta$ -cyanomethyl phosphoramidite chemistry on a support matrix of Monobeads (Pharmacia LKB Biotechnology, Inc., Piscataway, N.J.) optimized for 0.2  $\mu$ M synthesis scale. The sequences of the oligonucleotide primers used in the polymerase chain reaction (PCR) and as probes for Southern blots were chosen from FIV sequence data (56). The sequence of FIV was derived from cloned Petaluma strain FIV grown on Crandell feline kidney cells. The primers were taken from the *gag* region between base pairs 929 and 1394. Two sets of primer pairs were synthesized. The first primer pair (1 and 2) amplified a sequence containing 327 base pairs (929 to 1255) of the genome, and the second primer pair (3 and 4) amplified the adjacent sequences of 159 base pairs (1239 to 1394). By using primers 1 and 4 in combination, it was possible to amplify both sequences (929 to 1394). The oligonucleotides were purified by elution from a polyacrylamide gel as previously described (4, 28). Radiolabeling of the 5' end of the oligonucleotide probes was done by using 20 pM probe, 20 U of T4 polynucleotide kinase, and 100  $\mu$ Ci of [<sup>32</sup>P]ATP at 5,000 Ci/mmol in a total volume of 30  $\mu$ l. Unincorporated [<sup>32</sup>P]ATP was removed by passage over Sephadex G-50 by a spun column procedure (28).

DNA was prepared from various frozen tissues taken at

postmortem or at biopsy. The tissue samples, weighing 0.2 to 1.2 g, were cut into small pieces, added to 3 ml of Tris hydrochloride-EDTA-NaCl (TEN) buffer, and passed through a Dounce homogenizer. After homogenization, 3 ml of TEN containing 1% sodium dodecyl sulfate and 200 U of proteinase K per ml was added (final volume,  $\pm$ 7.0 ml). Digestion continued for 24 h at 50°C. After primary digestion and light vortex stirring, proteinase K and sodium dodecyl sulfate were added to final concentrations of 300  $\mu$ g/ml and 2%, respectively. Digestion was continued for an additional 16 h, followed by boiling for 10 min to destroy kinase activity. DNA was isolated from two repetitive cycles of phenol-chloroform extraction and cold ethanol precipitation (4, 28). A 1- $\mu$ l sample of DNA containing 200 ng of DNA was used for PCR amplification. Control DNA from FeLV-infected and noninfected feline embryonic lung cells was prepared in the same manner.

A sample containing 200 ng of purified DNA was subjected to 30 cycles of PCR amplification (32). Amplifications were performed in a DNA thermal cycler (Perkin-Elmer Cetus, Norwalk, Conn.). Denaturation was at 94°C for 1 min, renaturation was at 55°C for 1 min, and elongation was at 72°C for 1.5 min. The enzyme used for amplification was a thermostable DNA polymerase (*Taq*) (52).

Radiolabeled probes were used to identify amplified DNA products. Two specific probes were prepared from each of the two sets of primers. Probe A represented base pairs 1108 to 1141, and probe B represented base pairs 1277 to 1306. An 18- $\mu$ l amount of each amplified sample was electrophoresed at 97 V in a 1.5% NuSieve GTG agarose-1.5% agarose gel (FMC Bioproducts, Rockland, Maine) in 50 mM Tris borate-10 mM EDTA (TBE) buffer (pH 7.5). Amplified DNA bands were visualized with ethidium bromide staining and compared for sequence length against DNA markers from a  $\phi$ X174 replicative-form DNA *Hae*III digest (New England BioLabs, Inc., Beverly, Mass.). After denaturation and neutralization of DNA in the agarose gel, the PCR reaction products were transferred to a 0.2- $\mu$ m-pore-size nitrocellulose sheet for Southern blotting. Specific identification of oligonucleotide sequences with <sup>32</sup>P-labeled probes (A and B) was done under previously described conditions (4, 28). Prehybridization was done at 47°C for 2 h, and hybridization was done at 55°C for 16 h.

## RESULTS

**Clinical signs of illness.** Group 1 cats that were not infected with either FIV or FeLV remained normal in all respects for the duration of the study (Table 1). Group 2 cats, which were infected only with FIV, developed a variable leukopenia (Fig. 1) and mild to moderate fever (103.5 to 105°F [39.7 to 40.6°C]) beginning 4 to 6 weeks after inoculation. The leukopenia was associated mainly with an absolute neutropenia and was most severe in cat 3394. One cat (no. 3394) developed a marked generalized lymphadenopathy, one developed a mild lymphadenopathy, and one had equivocal lymphadenopathy. Cat 3394 was euthanized on day 54 because of high fever, complete anorexia, and extreme depression of 10 days' duration. The six surviving cats remained otherwise normal in appetite, general condition, and attitude for the remainder of the study.

Group 3 cats, which were infected only with FeLV, remained normal throughout the study except for cats 3400 and 3410. There were no signs of fever, depression, or anorexia, and the WBC counts and hematocrits remained stable (Fig. 1). Cat 3410 developed bilateral panophthalmitis

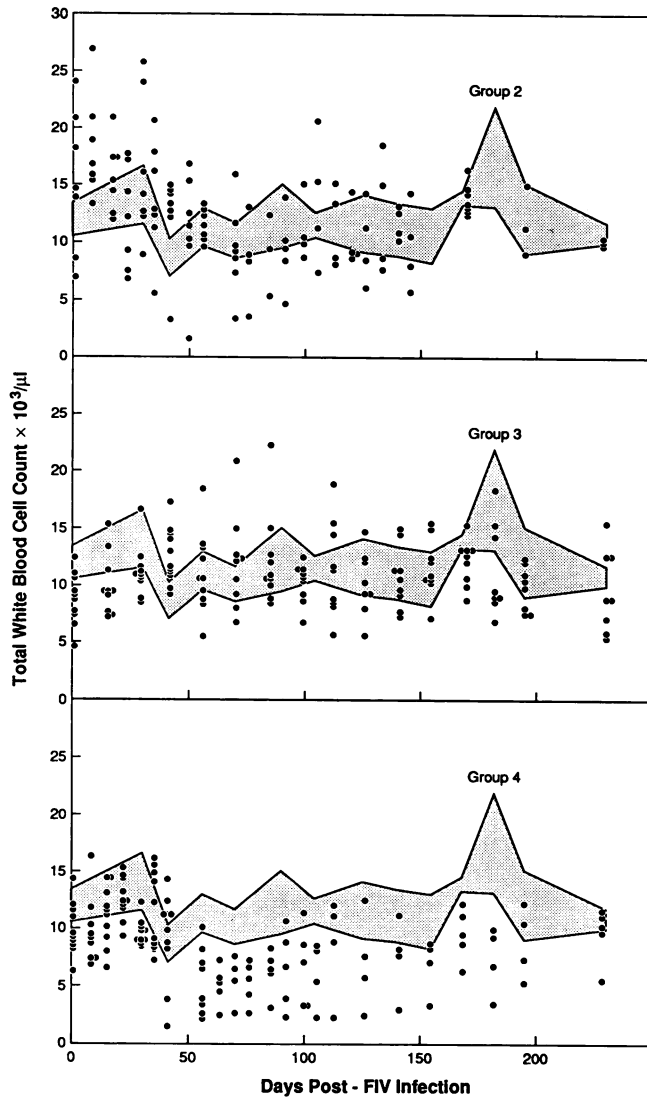


FIG. 1. Total WBC counts of cats infected with FIV (group 2), FeLV (group 3), or FIV and FeLV (group 4) compared with WBC counts (mean  $\pm$  1 SD; shaded area) of noninfected cats (group 1).

shortly after the beginning of the study. This progressed to glaucoma with cataractous changes in the lens, corneal edema, and blindness; terminally, the cat developed a mild nonresponsive anemia. The cat was euthanatized on day 104 of the study; except for the ocular disease, it was clinically normal at the time of death. Cat 3400 became progressively more anemic and thrombocytopenic with time (data not shown). It was euthanatized on day 168 of the study because of severe anemia (pcv 7%) and lethargy, but it was still outwardly in good flesh.

Cats in group 4 that were infected with both FeLV and FIV developed a much more severe illness than did cats infected with FIV alone. Five of the ten cats developed a high fever (104.5 to 106.0°F [40.3 to 41.1°C]), anorexia, abdominal pain on palpation, inflamed gums, and severe diarrhea. Lymphadenopathy was not noticeably increased, although this was hard to determine because of a preexistent mild to moderate lymphadenopathy associated with their initial FeLV infection. Despite supportive treatment with subcutaneous fluids and antibiotics, their conditions contin-

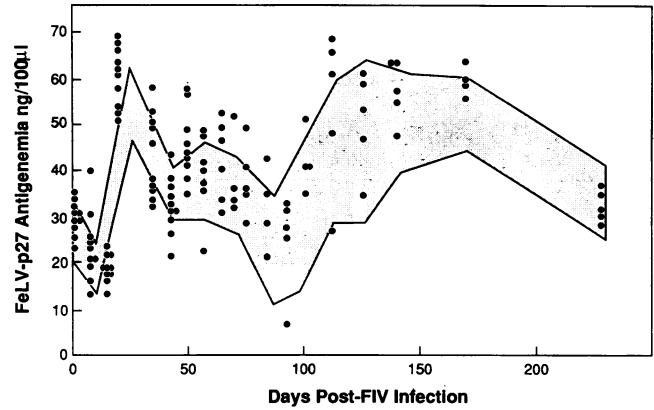


FIG. 2. Levels of FeLV p27 antigen in blood of cats infected with both FIV and FeLV (group 4) compared with levels (mean  $\pm$  1 SD; shaded area) of cats infected with FeLV alone (group 3).

ued to deteriorate over the next 7 to 14 days. These five cats had the most severe hematologic abnormalities (severe leukopenia) of all of the cats (Fig. 1). Four of these cats (no. 3404, 3405, 3386, and 3389) were euthanatized and one cat (no. 3407) died; three of the cats were clinically jaundiced at the time of death. All five of the dually infected cats that survived the initial phase of FIV infection were alive and in apparent normal health up to day 255. At that time, cat 3397 became acutely febrile, depressed, and anorectic. The right tarsal joint was acutely swollen, and the synovial fluid contained many nondegenerated neutrophils. Although blood cultures for bacteria were negative, the cat responded after 8 days of intensive antibiotic and parenteral fluid therapy.

**FeLV p27 antigenemia and FIV antibody response.** The levels of FeLV p27 antigenemia in group 3 and 4 cats remained the same during the entire study period (Fig. 2). Antibodies to FIV appeared in the blood of all cats in groups 2 and 4 beginning 2 to 6 weeks after infection (data not shown).

**Pathologic findings.** All five cats from group 4 (dually infected) that died during the primary phase of FIV infection had similar lesions, the most consistent of which was a mixed transmural inflammatory infiltrate of the cecum and colon, limited primarily to the region of the cecocolic junction (Table 2). Focally extensive necrosis of the cecal mucosa and underlying lymphoid patches was present in three of five of the cats. Fibrin thrombi were evident in vessels within and surrounding these necrotic areas. Bacterial cultures of the cecum from cat 3404 were negative for *Salmonella* sp. and mycobacteria. The palatine tonsils and the retropharyngeal and cecal lymph nodes also frequently contained large areas of coagulation necrosis with thrombosis. In general, most lymph nodes had many secondary follicles throughout the cortex and in medullary cords, with moderate plasmacytosis. The follicles were often ill defined because of variable cellularity in the mantle zones. Bone marrow consistently showed a marked left shift of myeloid elements, with 40 to 70% cellularity. One animal (no. 3405) had ulcerative gingivitis and focal stomatitis, which were characterized histologically by thrombosis and necrosis with mixed inflammatory infiltrates. Another animal (no. 3389) had severe nephritis characterized by vacuolitis and venous thrombosis, with mixed inflammatory infiltrates centered around the arcuate vessels. Bacterial cultures of kidney yielded no significant growth.

TABLE 2. Histopathologic lesions in cats that succumbed from FIV or combined FeLV and FIV infections during the project period

Infection	Cat no.	Time to death (days)	Lesions <sup>a</sup>									
			Typhlocolitis		Enteritis	Tonsillitis	Tonsillitis with necrosis	Lymph node necrosis	Marrow left shift	Gingivitis	Stomatitis	Nephritis <sup>b</sup>
			Mural inflammation	Mucosal necrosis								
FeLV + FIV	3404	42	+++	+++	-	+++	+++	-	++++	-	-	-
	3407	52	+++	++++	-	++++	++++	++++	++++	-	-	+
	3405	52	++++	++++	-	++++	++++	++++	NE	+++	-	-
	3386	52	+++	-	-	-	-	+++	++++	-	-	-
	3389	56	++	-	-	-	-	+++	++++	-	-	+++
FIV	3394	54	-	-	+	+	-	-	+++	+	+	++

<sup>a</sup> +++++, Severe; +++, moderately severe; ++, mild; +, minimal; -, negative; NE, not examined.

<sup>b</sup> Nephritis in cat 3389 was pleocellular and associated with vasculitis; lesions in cats 3407 and 3394 were interstitial and lymphocytic.

The single animal (no. 3394) from group 2 (FIV only) that died had moderate gingivitis-stomatitis, mild tonsillitis, and marked left shift in the bone marrow similar to findings for the dually infected cats, but intestinal lesions were limited to occasional crypt abscesses in the small intestine (Table 2). This animal also had focal ulcerative dermatitis of the left medial thigh and mild subacute interstitial nephritis. Bacterial cultures of the skin lesion yielded mixed growth. Mycobacterial cultures were negative.

The two group 3 cats (no. 3400 and 3410), which were infected only with FeLV, had lesions that differed considerably in nature and distribution from those of the group 2 and 4 cats described above (Table 3). Both cats had severe bone marrow hypoplasia, which was accompanied by myelofibrosis in cat 3400. Intestinal lesions were limited to multifocal herniation and abscessation of cecal crypts in cat 3400 and a few aggregations of fibrin and neutrophils within the cecal lumen of cat 3410. In addition, cat 3410 had marked follicular lymphoid hyperplasia and marked pyogranulomatous inflammation of the eyes, liver, spleen, and myocardium. The lesions bore some resemblance to those seen in cats with feline infectious peritonitis. The lesions were not associated with vasculitis, however, and tissues were negative for coronavirus antigens. Serum samples were also negative for coronavirus antibodies throughout the time of the study and at death (data not shown). Bacterial cultures of pericardial fluid were negative.

Tissue sections from all of the seven cats that were autopsied were specially stained for microorganisms. Gram-positive cocci were identified in superficial portions of necrotic tonsil and cecal mucosa of some cats, and few mixed bacteria were within renal vessels of cat 3389. All other tissues were negative.

**Tissue distribution of FIV DNA.** FIV genomic DNA, as determined by the PCR gene amplification technique, was identified only in FIV-infected cats in groups 2 and 4 (Table 4). No genomic DNA was identified in tissues of normal SPF cats or in cats infected only with FeLV. Genomic DNA was readily detected in peripheral (popliteal) and mesenteric lymph node tissues taken from cats experimentally infected with FIV alone or cats infected with both FIV and FeLV (Table 4). The quantity of FIV DNA appeared to be much greater, however, in the latter group of animals (Table 4 and Fig. 3). FIV genomic DNA was not detectable in nonlymphoid tissues (kidney, brain, and liver) of cats experimentally infected just with FIV but was detected in the same nonlymphoid tissues of cats with combined FIV and FeLV infections (Table 4 and Fig. 3). As a further control, tissues

from 2 cats (group 5) that had naturally acquired infection and terminal AIDS-like disease were also assayed; FIV genomic DNA was seen in detectable levels only in lymphoid tissues (Table 4).

**CD4<sup>+</sup>/CD8<sup>+</sup> T-lymphocyte ratio.** T-lymphocyte subsets were determined for surviving cats in all four groups at day 240 of the study (Table 5). There was no statistical differences in a two-tailed test between the mean CD4<sup>+</sup>/CD8<sup>+</sup> T-lymphocyte ratios of noninfected cats and cats infected with either FeLV or FIV alone ( $P \geq 0.5$ ). The CD4<sup>+</sup>/CD8<sup>+</sup> T-lymphocyte ratios for dually infected cats were below 0.70 in four of five cats, and the mean ratio for the group was significantly less (80% confidence limit; two-tailed test) than those of the other groups ( $P \leq 0.17$ ).

## DISCUSSION

Recent seroepidemiologic studies indicated that cats coinfecting with both FIV and FeLV either died at a younger age, had more severe disease, or lived for a shorter period of time than did cats infected with FIV alone (15, 19, 60). These field observations were the basis for the hypothesis that FeLV might act as a cofactor for FIV infection.

Preexisting FeLV infection enhanced both the transient primary and chronic secondary stages of FIV infection. The primary stage of FIV infection in cats has been previously described (61). It is analogous to the transient mononucleosis-like disease seen in the primary phase of HIV-1 infection of humans (8). Most experimentally infected cats recover from the transient primary stage of FIV infection within 2 weeks or so; the mortality in an earlier study was less than 10% (61). The 50% mortality seen in dually infected cats reported here was considerably higher than the 14 and 20% mortalities observed in matched control cats in the same study that were infected with FIV or FeLV, respectively.

The enhancement of disease caused by dual FeLV-FIV infection may be analogous to that observed for dual HIV-1 and human T-lymphotropic virus type I (HTLV-I) infections of humans. HTLV-I causes a certain type of lymphosarcoma and a neurologic disorder called tropical spastic paresis (25) and is also mildly immunosuppressive (13). Humans infected with both HIV and HTLV develop AIDS over a much shorter period of time and have a higher mortality than do individuals infected only with HIV-1 (2). A similar disease potentiation has been seen in African patients infected with both HIV-1 and HIV-2 (11).

It is uncertain whether a severe primary disease syndrome analogous to that seen in dually infected cats in this study

TABLE 4. Distribution and relative quantity of FIV proviral DNA in various tissues from normal cats, cats infected with either FIV or FeLV, and cats infected with both FeLV and FIV

Group	Cat no.	Infecting agent(s)	Distribution <sup>a</sup>				
			Lymph nodes		Kidney	Liver	Brain
			Peri- pheral	Mesen- teric			
1	3325	None	- <sup>b</sup>	-	-	-	-
	3335	None	-	-	-	-	-
2	3383	FIV alone	+	ND	-	ND	ND
	3401	FIV alone	+	+	-	ND	ND
3	3394	FIV alone	+	+	-	-	-
	3400	FeLV alone	-	-	-	-	-
4	3389	FIV + FeLV	++	++	+	+	+
	3405	FIV + FeLV	+	+	+	+	-
5	3404	FIV + FeLV	++	++	+	ND	+
	3386	FIV + FeLV	++	++	+	ND	+
5	1	FIV alone <sup>b</sup>	+	+	-	-	-
	2	FIV alone <sup>b</sup>	+	+	-	-	-

<sup>a</sup> ++, Heavy band; +, light but definite band; -, negative; ND, not done.  
<sup>b</sup> Naturally acquired FIV infection with terminal AIDS-like disease.

occurs in nature. The disease seen in dually infected cats reported here bears some resemblance, however, to the panleukopenialike syndrome that occurs among older parvovirus-immunized cats in nature (47). Interestingly, many of the cats with this syndrome were found to be infected with FeLV. Unfortunately, FIV was not identified at the time of the earlier reports of the panleukopenialike syndrome.

The secondary, or chronic immunosuppressive, stage of FIV infection is often associated with hematological abnormalities such as anemia and leukopenia (19, 60), similar to HIV infection of humans (41). This stage of FIV infection is analogous to the AIDS stage of HIV-1 infection in humans and also occurs months or years after the transient primary stage of illness (19, 61). In nature, the secondary stage of FIV infection is associated with chronic opportunistic infections of the oral cavity, upper respiratory tract, and gastrointestinal tract (19, 60).

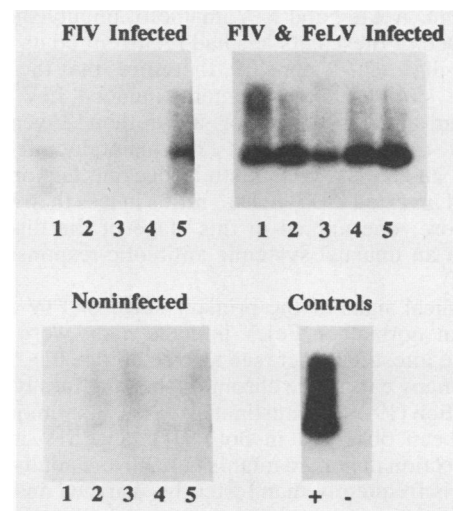


FIG. 3. Presence of PCR-amplified FIV DNA in tissues from cats infected with FIV (no. 3394) or FeLV and FIV (no. 3407) and in FIV-infected and noninfected Crandell feline kidney cells (+ and - controls). Lanes 1 through 5 contain DNA originating from the popliteal lymph node, brain, liver, kidney, and mesenteric lymph node, respectively.

TABLE 3. Histopathologic lesions in cats infected with FeLV alone that succumbed during the study period

Cat no.	Time to death (days)	Lesions <sup>a</sup>							
		Typhlocolitis	Typhlocolitis with crypt abscesses	Marrow changes	Ophthalmitis	Hepatitis	Splenitis	Myocarditis	Pneumonia
3400	168	-	+	++++ (myelofibrosis)	-	-	-	-	-
3410	104	+ (exudative and not mural)	-	++++ (hypoplasia)	+++ (pyogranulomatous)	+	+	+	+ (acute, bronchial)

<sup>a</sup> Symbols are as in Table 2. For all other lesions examined (see Table 2), both cats were negative.

TABLE 5. CD4<sup>+</sup>/CD8<sup>+</sup> peripheral blood T-cell ratio of normal SPF cats and SPF cats experimentally infected with FeLV, FeLV or both<sup>a</sup>

Group	Cat no.	Infecting agent(s)	CD4 <sup>+</sup> /CD8 <sup>+</sup> ratio (mean ± 1 SD)
1	3325	None	1.52
	3335	None	1.71
	3337	None	0.91
			(1.38 ± 0.42)
2	3388	FIV alone	1.14
	3392	FIV alone	0.74
	3399	FIV alone	1.69
	3401	FIV alone	0.88
	3408	FIV alone	1.01
	3411	FIV alone	1.81
			(1.21 ± 0.44)
3	3383	FeLV alone	1.37
	3384	FeLV alone	1.84
	3385	FeLV alone	1.18
	3387	FeLV alone	1.74
	3390	FeLV alone	1.57
	3395	FeLV alone	1.15
	3402	FeLV alone	0.90
	3406	FeLV alone	0.83
			(1.28 ± 0.34)
4	3378	FIV + FeLV	1.17
	3391	FIV + FeLV	0.51
	3397	FIV + FeLV	0.67
	3398	FIV + FeLV	0.54
	3403	FIV + FeLV	0.45
			(0.67 ± 0.29)

<sup>a</sup> Determined at one point 8 months after the beginning of the study.

Laboratory studies of the chronic secondary stage of FIV infection have been initiated; SPF cats experimentally infected with FIV and kept in a pathogen-free environment for up to 14 months showed minimal signs of disease once the transient primary phase of infection passed (61). Many of these same cats have now been observed for 36 months (at the time of writing), and although none of them have developed a distinct AIDS-like illness, several are now leukopenic and have depressed CD4<sup>+</sup>/CD8<sup>+</sup> T-lymphocyte ratios (C. D. Ackley and J. Yamamoto, unpublished observation). One of these cats has had recurrent bouts of severe fever and diarrhea. It appears, therefore, that the immunodeficiency stage of experimentally induced FIV infection may occur after a period of more than 2 years. It is significant, therefore, that cats experimentally infected with both FIV and FeLV in this study became leukopenic and developed inverted CD4<sup>+</sup>/CD8<sup>+</sup> ratios in less than 8 months. Furthermore, one animal in this stage of the disease also developed an unusual systemic antibiotic-responsive infection.

The clinical signs of the primary stage of FIV infection, whether in normal or FeLV-infected cats, were centered around the intestinal tract (see also reference 61). The same is true of many cats in the chronic stage of naturally acquired FIV infection (19, 60). Intestinal disease is not unique to FIV and has been observed in both HIV and SIV infections. HIV-1 infection in human infants (14, 30) and adults in Africa (5, 7, 44) is frequently manifested by diarrhea and wasting. In many of these cases, no other secondary or opportunistic infections are found in the bowel (7). SIV infection in rhesus macaques takes several clinical courses; a portion of experimentally infected animals fail to make detectable levels of antibodies immediately after infection, become persistently antigenemic, and die within several months (3, 63). The

survivors have good antibody responses and remain healthy and nonantigenemic for months or years. The monkeys with the more acute form appear to be less immunologically responsive and usually develop chronic diarrhea, encephalitis, and wasting (3). Like the human disease, the enteritis is not always associated with other pathogens (3). One strain of SIV is the sole cause of an acute, rapidly progressive, and often fatal enteritis in pigtail macaques, a genetically susceptible species (H. M. McClure, D. C. Anderson, A. Ansari, and P. Fultz, Proc. V Int. Conf. AIDS, p. 594, 1989). It is not surprising, therefore, that potentiated FIV infection in FeLV-compromised cats would also severely affect the bowel.

The precise mechanism of enhancement of FIV disease by the asymptomatic FeLV carrier state was not determined but could involve four basic mechanisms: (i) interaction of FeLV and FIV at the level of host immunity, (ii) interaction of FeLV and FIV at the cellular level, (iii) intracellular interaction between FeLV and FIV, or (iv) production of mixed or pseudotype virions containing FeLV and FIV proteins and genomes. There was no evidence that FIV enhancement occurred at the host level. FeLV is known to be immunosuppressive (16, 51), however, and it is possible that subclinical levels of FeLV-induced immunosuppression prevented the host from responding normally to the subsequent FIV infection. The only evidence against this possibility was the relatively normal CD4<sup>+</sup>/CD8<sup>+</sup> T-lymphocyte ratios in the blood of cats infected only with FeLV. Interaction at the cellular level was also a possibility. The preexisting FeLV infection could have altered the relative levels of FIV-susceptible target cells or enhanced the elaboration of certain cell surface receptors, thus allowing the initial FIV infection to spread much more rapidly. Certain serotypes of turkey herpesviruses can enhance the incidence of avian leukosis virus-induced lymphomas by effects of the herpesvirus on tumor-sensitive bursal cells (1). The preexisting FeLV infection may have enhanced FIV infectivity or replication by some intracellular interaction. FeLV infects many different lymphoid and nonlymphoid tissues in the body (54), and FIV will coinfect FeLV-infected lymphoid cells in vitro (61). Lymphoid cells chronically infected with HTLV-I are more susceptible to infection in vitro with HIV-1, and coinfecting cells produce higher levels of HIV-1 (10). There is a similar enhancing effect between genes or gene products of herpesviruses (herpes simplex virus, cytomegalovirus, human herpesvirus 6, and Epstein-Barr virus) and genes in the long-terminal-repeat regions of HIV-1 (9, 17, 21, 31). The *tat* protein of HTLV-I will also activate HIV gene expression in vitro (54). Whether FeLV encodes genes that transactivate FIV remains to be determined. The question of intracellular genetic recombination between heterologous retroviruses of the same species is of interest because cells coinfecting with FeLV and FIV may produce pseudotypes that have different cell tropisms. Such a mechanism may account for the presence of FIV DNA in normally nontargeted tissues, such as liver and kidney, of coinfecting cats in this study.

#### ACKNOWLEDGMENTS

This study was supported by Public Health Service grants CA-AI25802-03 and AI25802-01 from the National Institutes of Health and by the Purina Corp., St. Louis, Mo.

We are indebted to N. Delemus, K. Floyd, C. Allison, R. Dickover, J. Higgins, and K. Shaw for excellent technical assistance.



## ADDENDUM

Cat 3397 was euthanatized on day 375. Postmortem examination revealed severe mesenteric lymphadenitis, mural enteritis of the adjacent jejunum, perforation of the bowel, and diffuse peritonitis. *Streptococcus canis*, a normal inhabitant of the oropharynx and distal genitourinary tract, was cultured from abdominal exudate. All other surviving cats were normal at this time.

## LITERATURE CITED

- Bacon, L. D., R. L. Witter, and A. M. Fadly. 1989. Augmentation of retrovirus-induced lymphoid leukosis by Marek's disease herpesvirus in white leghorns. *J. Virol.* 63:504-512.
- Bartholomew, C., W. Blattner, and F. Cleghorn. 1987. Progression to AIDS in homosexual men co-infected with HIV and HTLV-I in Trinidad. *Lancet* ii:1469.
- Baskin, G. B., M. Murphey-Corb, E. A. Watson, and L. N. Martin. 1988. Necropsy findings in rhesus monkeys experimentally infected with cultured simian immunodeficiency virus (SIV)/delta. *Vet. Pathol.* 25:456-467.
- Berger, S. L., and A. R. Kimmel. 1987. Guide to molecular cloning techniques. *Methods Enzymol.* 152:432-442.
- Carswell, J. W. 1988. Clinical manifestations of AIDS in tropical countries. *Trop. Doc.* 18:147-150.
- Collins, F. M. 1986. Mycobacterium avium-complex infections and development of the acquired immunodeficiency syndrome: casual opportunist or casual cofactor. *Int. J. Lepr.* 54:458-474.
- Conlon, C. P. 1988. Clinical aspects of HIV infection in developing countries. *Br. Med. Bull.* 44:101-114.
- Cooper, D. A., J. Gold, P. Maclean, B. Donovan, R. Finlayson, T. G. Barnes, H. M. Michelmore, P. Brooke, and R. Penny. 1985. Acute AIDS retrovirus infection. *Lancet* i:537-540.
- Davis, M. G., S. C. Kenny, J. Kamine, J. S. Pagano, and E.-S. Huang. 1987. Immediate-early gene region of human cytomegalovirus trans-activates the promoter of human immunodeficiency virus. *Proc. Natl. Acad. Sci. USA* 84:8642-8646.
- DeRossi, A., G. Franchini, A. Aldovini, A. Del Mistro, L. Chicco-Bianchi, R. C. Gallo, and F. Wong-Staal. 1986. Differential response to cytopathic effects of human T-lymphotropic virus type III (HTLV-III) superinfection in T4 (helper) and T8 (suppressor) T-cell clones transformed by HTLV-I. *Proc. Natl. Acad. Sci. USA* 83:4297-4301.
- de Thé, G. 1988. HIV-1 and HIV-2 epidemiology and disease association in Ivory Coast, p. 51-54. *In* M. Girard and L. Valette (ed.), *Proceedings of the 2nd colloque des cent gardes, retroviruses of human A.I.D.S. and related animal diseases.* Pasteur Vaccins, Lyons, France.
- Drew, W. L. 1986. Is cytomegalovirus a cofactor in the pathogenesis of AIDS and Kaposi's sarcoma. *Mt. Sinai J. Med.* 53:622-626.
- Essex, M., M. F. McLane, N. Tachibana, D. P. Francis, and T. H. Lee. 1984. Seroepidemiology of human T-cell leukaemia virus: its relation to immunosuppression and the acquired immune deficiency syndrome, p. 355-362. *In* R. C. Gallo, M. E. Essex, and L. Gross (ed.), *Human T-cell leukemia/lymphoma virus.* Cold Spring Harbor Laboratory, Cold Spring Harbor, N.Y.
- Fost, N. C., G. Merenstein, S. K. Schonberg, G. B. Scott, M. W. Sklaire, E. H. Wender, and J. R. Allen. 1988. Task force on pediatric AIDS. Perinatal human immunodeficiency virus infection. *Pediatrics* 82:941-944.
- Grindhem, C. B., W. T. Corbett, B. E. Ammerman, and M. T. Tomkins. 1989. Seroepidemiologic survey of feline immunodeficiency virus infection in cats of Wake County, North Carolina. *J. Am. Vet. Med. Assoc.* 194:226-228.
- Hardy, W. D., Jr. 1982. Immunopathology induced by the feline leukemia virus. *Springer Semin. Immunopathol.* 5:75-105.
- Horvatt, R. T., C. Wood, and N. Balachandrian. 1989. Transactivation of human immunodeficiency virus by human herpesvirus 6. *J. Virol.* 63:970-973.
- Hudson, C. P., A. J. M. Hennis, P. Kataaha, G. Lloyd, A. T. Moore, G. M. Sutehall, R. Whetstone, T. Wreghiti, and A. Karpos. 1988. Risk factors for the spread of AIDS in rural Africa: evidence from a comparative seroepidemiological survey of AIDS, hepatitis B and syphilis in Southwestern Uganda. *AIDS* 2:255-260.
- Ishida, T., T. Wahizu, K. Toriyabe, S. Motoyoshi, I. Tomoda, and N. C. Pedersen. 1989. Feline immunodeficiency virus infection in cats of Japan. *J. Am. Vet. Med. Assoc.* 194:221-225.
- Jason, J., L. Kung-Jong, M. V. Ragni, N. A. Hessel, and W. W. Darrow. 1989. Risk of developing AIDS in HIV-infected cohorts of hemophilic and homosexual men. *J. Am. Med. Assoc.* 261:725-727.
- Kenney, S., J. Kamine, D. Markovitz, R. Fenrick, and J. Pagano. 1988. An Epstein-Barr virus immediate-early gene product trans-activates gene expression from the human immunodeficiency virus long terminal repeat. *Proc. Natl. Acad. Sci. USA* 85:1652-1656.
- Klotz, F. W., and M. D. Cooper. 1986. A feline thymocyte antigen defined by a monoclonal antibody (FT2) identifies a subpopulation of non-helper cells capable of specific cytotoxicity. *J. Immunol.* 136:2510-2514.
- Lamoureux, G., L. Davignon, R. Turcotte, M. Laverdière, E. Mankiewicz, and M. C. Walker. 1987. Is prior mycobacterial infection a common predisposing factor to AIDS in Haitians and Africans? *Ann. Inst. Pasteur Immunol.* 138:521-529.
- Laure, F., D. Zagury, A. G. Saimot, R. C. Gallo, B. H. Hahn, and C. Brechot. 1985. Hepatitis B virus DNA sequences in lymphoid cells from patients with AIDS and AIDS-related complex. *Science* 229:561-566.
- Levine, P. H., and W. A. Blattner. 1987. The epidemiology of diseases associated with HTLV-I and HTLV-II. *Infect. Dis. Clin. North Am.* 1:501-510.
- Lopez, C., P. Pellett, J. Stewart, C. Goldsmith, K. Sanderlin, J. Black, D. Warfield, and P. Feorino. 1989. Characteristics of human herpesvirus-6. *J. Infect. Dis.* 157:1271-1273.
- Lutz, H., N. C. Pedersen, R. Durbin, and G. H. Theilen. 1983. Monoclonal antibodies to three epitopic regions of feline leukemia virus p27 and their use in enzyme-linked immunosorbent assay of p27. *J. Immunol. Methods* 56:209-220.
- Maniatis, T., E. F. Fritsch, and J. Sambrook. 1982. *Molecular cloning: a laboratory manual.* Cold Spring Harbor Laboratory, Cold Spring Harbor, N.Y.
- Margolick, J. B., D. J. Volkman, T. M. Folks, and A. S. Fauci. Amplification of HTLV-III/LAV infection by antigen-induced activation of T cells and direct suppression by virus of lymphocyte blastogenic responses. *J. Immunol.* 138:1719-1723.
- Mok, J. W., C. Giaquinto, A. DeRossi, I. Grosch-Wörner, A. E. Ades, and C. S. Peckham. 1987. Infants born to mothers seropositive for human immunodeficiency virus. *Lancet* i:1164-1171.
- Mosca, J. D., D. P. Bednarik, N. B. K. Raj, C. A. Rosen, J. G. Sodroski, W. A. Haseltine, G. S. Hayward, and P. M. Pitha. 1987. Activation of human immunodeficiency virus by herpesvirus infection: identification of a region within the long terminal repeat that responds to a trans-acting factor encoded by herpes simplex virus 1. *Proc. Natl. Acad. Sci. USA* 84:7408-7412.
- Mullis, K. B., and F. A. Faloon. 1987. Specific synthesis of DNA in vitro via a polymerase catalyzed chain reaction. *Methods Enzymol.* 155:335-350.
- Okubo, S., and K. Yasunaga. 1988. Significance of viral coinfections by HIV, HTLV-1, Epstein-Barr virus and cytomegalovirus for immunological conditions in Japanese hemophiliacs. *AIDS* 2:318-319.
- Pastore, G., T. Santantonio, L. Monno, M. Milella, N. Luchena, and G. Angarano. 1988. Effects of HIV superinfection on HBV replication in a chronic HBsAg carrier with liver disease. *J. Hepatol.* 7:164-168.
- Pedersen, N. C. 1987. Virologic and immunologic aspects of feline infectious peritonitis virus infection. *Adv. Exp. Biol. Med.* 218:529-550.
- Pedersen, N. C. 1988. *Feline infectious diseases.* American Veterinary Publications, Goleta, Calif.
- Pedersen, N. C., E. Ho, M. L. Brown, and J. K. Yamamoto.



1987. Isolation of a T-lymphotropic virus from domestic cats with an immunodeficiency-like syndrome. *Science* **235**:790-793.
38. Pedersen, N. C., L. Johnson, and R. L. Ott. 1985. Evaluation of a commercial feline leukemia virus vaccine for immunogenicity and efficacy. *Feline Pract.* **15**(6):7-20.
  39. Pedersen, N. C., L. Johnson, and G. H. Theilen. 1986. Possible immunoenhancement of persistent viremia by feline leukemia virus envelope glycoprotein in challenge-exposure situations where whole inactivated virus vaccines were protective. *Vet. Immunol. Immunopathol.* **11**:123-148.
  40. Pedersen, N. C., G. Theilen, M. A. Keane, L. Fairbanks, T. Mason, B. Orser, C. H. Chen, and C. Allison. 1977. Studies of naturally transmitted feline leukemia virus infection. *Am. J. Vet. Res.* **38**:1523-1531.
  41. Perkocho, L. A., and G. M. Rodgers. 1988. Hematologic aspects of human immunodeficiency virus infection: laboratory and clinical considerations. *Am. J. Hematol.* **29**:94-105.
  42. Pinching, A. J. 1988. Clinical aspects of AIDS and HIV infection in the developed world. *Br. Med. J.* **44**:89-90.
  43. Piot, P., and M. Caraël. 1988. Epidemiological and sociological aspects of HIV-infection in developing countries. *Br. Med. Bull.* **44**:68-88.
  44. Quinn, T. C., J. M. Mann, J. W. Curran, and P. Piot. 1987. AIDS in Africa: An epidemiologic paradigm. *Science* **234**:955-963.
  45. Quinn, T. C., P. Piot, J. B. McCormick, F. M. Feinsod, H. Taelman, B. Kapita, W. Stevens, and A. S. Fauci. 1987. Serologic and immunologic studies in patients with AIDS in North America and Africa. The potential role of infectious agents as cofactors in human immunodeficiency virus infection. *J. Am. Med. Assoc.* **257**:2617-2621.
  46. Rasheed, S., and M. B. Gardner. 1981. Isolation of feline leukemia virus from a leopard cat cell line and search for retrovirus in wild felidae. *J. Natl. Cancer Inst.* **67**:759-768.
  47. Reinacher, M. 1987. Feline leukemia virus-associated enteritis: a condition with features of panleukopenia. *Vet. Pathol.* **24**:1-4.
  48. Rook, A. H. 1988. Interactions of cytomegalovirus with the human immune system. *Rev. Infect. Dis.* **10**(Suppl. 3):S460-S467.
  49. Rosenberg, Z. F., and A. S. Fauci. 1989. Immunopathogenic mechanisms of HIV infection. *Clin. Immunol. Immunopathol.* **50**:5149-5156.
  50. Royko, J., E. A. Hoover, L. E. Mathes, R. G. Olsen, and J. P. Schaller. 1979. Pathogenesis of experimental feline leukemia virus infection. *J. Natl. Cancer Inst.* **63**:759-768.
  51. Royko, J., and R. G. Olsen. 1984. The immunobiology of feline leukemia virus infection. *Vet. Immunol. Immunopathol.* **6**:107-165.
  52. Saiki, R. K., D. H. Gelfand, S. Stoffel, S. J. Scharf, R. Higuchi, and G. G. T. Horn. 1988. Primer-directed enzymatic amplification of DNA with a thermostable DNA polymerase. *Science* **239**:487-491.
  53. Selik, R. M., K. G. Castro, and M. Pappaioanou. 1988. Racial/ethnic differences in the risk of AIDS in the United States. *Am. J. Public Health* **78**:1539-1545.
  54. Siekevitz, M., S. H. Josephs, M. Dukovich, N. Peffer, F. Wong-Staal, and W. C. Greene. 1987. Activation of the HIV-1 LTR by T cell mitogens and the trans-activator protein of HTLV-I. *Science* **238**:1575-1578.
  55. Sunderham, G., R. J. McDonald, T. Maniatis, J. Cleske, R. Kapila, and L. B. Reichman. 1986. Tuberculosis as a manifestation of the acquired immunodeficiency syndrome (AIDS). *J. Am. Med. Assoc.* **256**:362-366.
  56. Talbott, R. L., E. E. Sparger, K. M. Lovelace, W. M. Fitch, N. C. Pedersen, P. A. Luciw, and J. H. Elder. 1989. Nucleotide sequence and genomic organization of feline immunodeficiency virus. *Proc. Natl. Acad. Sci. USA* **86**:5743-5747.
  57. Van De Perre, P., N. Clumeck, M. Steens, G. Zassis, M. Caraël, R. Lagasse, S. DeWit, I. T. LaFontaine, P. DeMol, and J. P. Butzler. 1987. Seroepidemiological study on sexually transmitted diseases and hepatitis B in African promiscuous heterosexuals in relation to HIV infection. *Eur. J. Epidemiol.* **3**:14-18.
  58. Watkins, J. D., C. Conway-Welch, J. J. Creedon, T. L. Crenshaw, R. M. DeVes, K. M. Gebbie, B. J. Lee 3rd, F. Lilly, J. C. O'Connor, B. J. Primm, et al. 1988. Interim report of the presidential commission on the human immunodeficiency virus epidemic. Chairman's recommendations—part I. *J. AIDS* **1**:69-103.
  59. Wolff, H., and D. J. Anderson. 1988. Male genital tract inflammation associated with increased numbers of potential human immunodeficiency virus host cells in semen. *Andrologia* **20**:404-410.
  60. Yamamoto, J. K., H. Hansen, E. W. Ho, T. Y. Morishita, T. Okuda, T. R. Sawa, R. M. Nakamura, and N. C. Pedersen. 1989. Epidemiologic and clinical aspects of feline immunodeficiency virus infection in cats from the Continental United States and Canada and possible mode of transmission. *J. Am. Vet. Med. Assoc.* **194**:213-220.
  61. Yamamoto, J. K., E. Sparger, E. W. Ho, P. R. Andersen, T. P. O'Connor, C. P. Mandell, L. Lowenstine, R. Munn, and N. C. Pedersen. 1988. Pathogenesis of experimentally induced feline immunodeficiency virus infection of cats. *Am. J. Vet. Res.* **49**:1246-1258.
  62. Zagury, D., J. Bernard, R. Leonard, R. Cheynier, M. Feldman, P. S. Sarin, and R. C. Gallo. 1986. Long term cultures of HTLV-III-infected cells; a model of cytopathology of T-cell depletion in AIDS. *Science* **231**:850-853.
  63. Zhang, J., L. N. Martin, E. A. Watson, R. C. Monelaro, M. West, L. Epstein, and M. Murphy-Corb. 1988. Simian immunodeficiency virus/delta-induced immunodeficiency disease in rhesus monkeys: relation of antibody response and antigenemia. *J. Infect. Dis.* **158**:1277-1286.