

Polyradiculoneuritis and *Mycoplasma pneumoniae* infection

S. HOLT
M.B., M.R.C.P.

M. M. KHAN
M.B., M.R.C.P.

R. G. CHARLES
B.Sc., M.B., M.R.C.P.

E. J. EPSTEIN
M.D., F.R.C.P.

Liverpool Regional Cardiac Centre, Sefton General Hospital, Liverpool L15 2HE

Summary

A patient with severe *Mycoplasma pneumoniae* developed polyradiculoneuritis and respiratory failure. The acute phase of the illness was complicated by a myocarditis, and recovery of neurological function was slow. Residual left hemidiaphragmatic paralysis was present 1 year after the onset of the illness.

Introduction

Mycoplasma pneumoniae is a common respiratory pathogen, with wide geographical prevalence (Hayflick and Chanock, 1965). This organism usually gives rise to a mild respiratory illness but is capable of producing a wide variety of clinical syndromes (Lambert, 1969; Noah, 1974). Neurological sequelae of *M. pneumoniae* infection are uncommon. In a review of 700 cases of *M. pneumoniae* infection sixteen patients (2%) had central nervous system disease (Noah, 1974). Several patterns of involvement, including encephalitis, meningitis, psychosis, hemiplegia, cerebellar ataxia, transverse myelitis and polyradiculoneuritis, have been described (Lerer and Kalavsky, 1973).

The authors have recently encountered a patient with severe *Mycoplasma pneumoniae*, who developed concurrent polyradiculoneuritis and myocarditis.

Case report

A 34-year-old factory worker was admitted to hospital with a 9-day history of intermittent cough, productive of mucopurulent, blood-stained sputum, headache and generalized myalgia. Clinical examination revealed a rectal temperature of 39.4°C, the pulse was regular at 100 beats/min, blood pressure was 18.6/10.6 kPa and the heart sounds were normal. He exhibited mild respiratory distress, respiratory rate 30/min, and there was dullness to percussion with bronchial breath sounds in both

lower lung fields. Treatment was initiated with tetracycline B.P. (0.5 g p.o. every 6 hr), but he remained pyrexial and unwell until 3 days after admission when he developed a loud pleuropericardial friction rub. At this stage he had a sinus tachycardia of 110 beats/min, a normal blood pressure of 17.3/10.6 kPa, no cardiac murmurs were audible and there was no cardiac failure.

On the fifth day after admission he complained of paraesthesiae in the hands and he developed sensory and motor impairment in the arms and legs. Mild symmetrical proximal and distal muscle weakness with diminished tendon reflexes and blunting to pin prick were present in the limbs. Over the ensuing 3 days the neurological deficit progressed, culminating in respiratory embarrassment. Examination at this stage revealed total loss of power and sensation in the limbs with areflexia. There was weakness of the left facial muscles and slight neck stiffness, but no sensory level was demonstrable. Tachypnoea, cyanosis, inability to cough, and poor respiratory excursion, necessitated endotracheal intubation and positive pressure ventilation. Intramuscular ACTH 40 u. twice daily was added to his existing treatment.

Partial return of motor function occurred in the upper limbs after 6 days of assisted respiration, he was breathing unassisted 4 days later and walking with aid at 3 weeks. During the recovery phase he continued to complain of generalized muscle pain. Eight months after the onset of this illness residual weakness of the left forearm, winging of the right scapula, ballooning of the right abdominal wall and left hemidiaphragmatic paralysis were present. No focal neurological signs were detectable 1 year after the onset of the illness.

Investigation

On admission Hb was 13.7 g/dl, WBC $4.0 \times 10^9/l$, polymorphs 83%, lymphocytes 8%, monocytes 8%, and eosinophils 1% with an ESR of 117. Coombs' direct antiglobulin test, the Monospot test for

heterophile antibody, screening for cold agglutinins and antibodies against *Streptococcus* MG were negative. No bacteria were isolated from throat swab, urine, faeces, blood and cerebrospinal fluid (CSF). The CSF fluid was clear, with normal dynamics and contained two lymphocytes/ml, protein of 0.85 g/l and a glucose of 3.5 mmol/l. Chest X-ray on admission showed extensive bilateral patchy consolidation (Fig. 1). These changes gradually resolved over a period of 6 weeks. Serial electrocardiographic (ECG) recordings demonstrated T wave flattening with ST segment arching and recovery to normal over a period of four weeks in leads II, III, aVF, V₁ and V₂. The ECG changes were coincidental with a moderate rise in serum aspartate and alanine transferase enzymes.

Serum collected at 1, 2, 3 and 4 weeks after admission was tested for complement fixation antibodies against *M. pneumoniae*. The first three specimens were antecomplementary but serum at 4 weeks showed a titre of 1 in 1280 against *Mycoplasma*. The titre remained elevated at the level at 7 months, falling to 1 in 640 at 9 months and 1 in 40 at 11 months after the onset of the illness. No viral organisms were recovered from CSF, blood and throat swab in a wide range of primary and secondary tissue

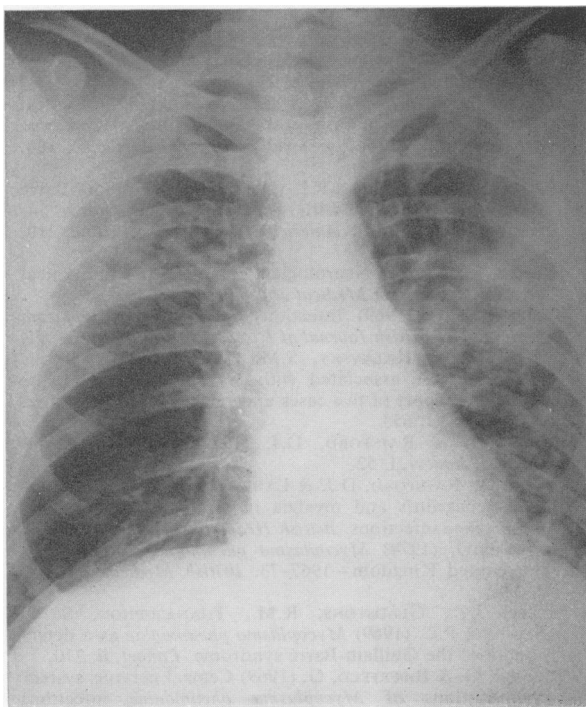


FIG. 1. Chest X-ray showing bilateral patchy consolidation.

cultures and no serum antibody titres against other neurotropic viruses were demonstrable. Coxsackie and echovirus titres were not sought. Lung function tests performed 4 months after the onset of the illness showed a mild restrictive impairment of ventilatory capacity with a gas transfer factor at the lower limit of normal. Pulmonary function tests at 12 months had returned to normal. Chest X-ray 1 year after the illness showed a left hemidiaphragmatic elevation with clear lung fields (Fig. 2). Paradoxical diaphragmatic movement was demonstrable during radiological screening.

Discussion

It has been estimated that up to 7% of patients with *M. pneumoniae* respiratory disease may develop neurological complications (Stern and Biberfeld, 1969). CNS sequelae of this infection are usually associated with preceding or concurrent respiratory disease (Hodges, Fass and Saslaw, 1972). Lerer and Kalavsky (1973) reviewing a group of reported patients with neurological complications of *M. pneumoniae* infection found that twenty-eight of forty-eight patients (58%) had preceding bronchitis or pneumonia and ten of forty-eight (21%) had antecedent upper respiratory tract symptoms. The interval between the onset of respiratory involvement and neurological sequelae in this series was between 3 and 23 days, mean of 10.1 days, and corresponds with the latent interval of 14 days in the present patient.

A temporal association between primary atypical pneumonia and polyradiculoneuritis was first reported 30 years ago (Holmes, 1947). With the advent of widely available serological tests for *M. pneumoniae* a causal relationship between *Mycoplasma* infection and the development of neurological complications has been established (Hodges *et al.*, 1972). Steele *et al.* (1969) described four children with polyradiculoneuritis in association with high complement fixation titres against *M. pneumoniae*. In two patients they were able to culture *Mycoplasma* from posterior pharyngeal aspirates. Hodges and Perkins (1969) reported a patient similar to the present one who developed severe paralysis with sensory deficit in association with *M. pneumoniae*. Their patient required ventilatory support but neurological recovery occurred more rapidly than in the present case. The finding of residual hemidiaphragmatic paralysis in the present patient is of interest and has, to the authors' knowledge, not been previously reported as a sequel of polyradiculoneuritis. The incidence of residual neurological lesions following central nervous system complications of *M. pneumoniae* infection is difficult to ascertain. Ten out of fifty patients with neurological complications of this infection reviewed by Lerer and Kalavsky (1973) had

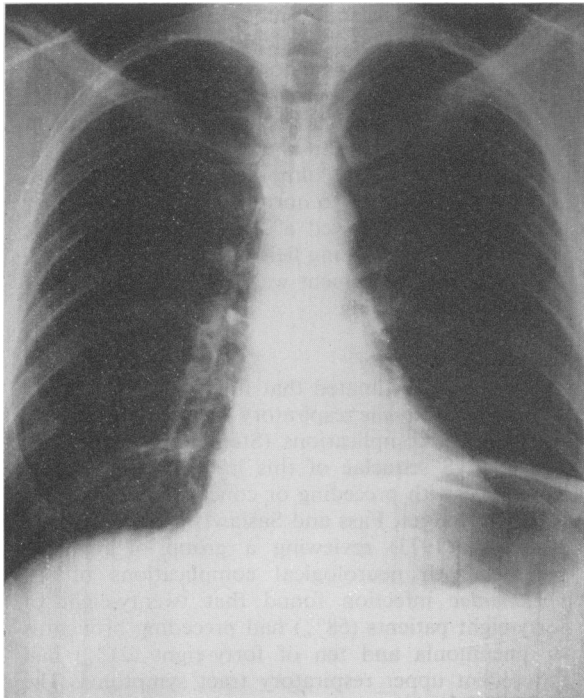


FIG. 2. Chest X-ray showing clear lung fields with left hemidiaphragmatic elevation.

incomplete neurological recovery. All ten patients were included under the diagnostic groups of focal encephalitis, transverse myelitis and radiculoneuritis. In this present patient, there was an initial phase of rapid improvement and a slower phase of recovery to normal. It is believed that the early phase of improvement in patients with radiculoneuropathy correlates with re-myelination of affected peripheral nerves and the slower phase may be due to re-innervation of partially denervated muscle. Detailed nerve conduction studies performed 1 year after the onset of the respiratory symptoms, in the present patient, were within normal limits.

It is felt that the complement fixation titre against *M. pneumoniae* of 1 in 1280 falling after 11 months to 1 in 40, in association with severe pneumonia and concurrent polyradiculoneuritis is evidence to suggest a causal relationship in this case. The present patient had extremely high initial levels of complement fixation antibodies against *M. pneumoniae*, which were elevated for 9 months, in the absence of cold agglutinins and antibodies against *Streptococcus MG*. It is recognized that high levels of antibody against *Mycoplasma* may persist in the serum for

several months following *Mycoplasma* infection but usually decrease or disappear within 8–18 months (Lambert, 1969). Although no correlation between peak serum titres of antibody and extent or severity of neurological involvement can be demonstrated (Lerer and Kalavsky, 1973) the association of high persistent antibody levels and severe clinical manifestations in the present patient is striking.

Mycoplasma myocarditis, first reported by Lewes and Rainford (1970), is frequently associated with myalgia and electrocardiographic changes in right ventricular and septal leads, which may persist for a few days to many months (Lewes, Rainford and Lane, 1974). It has been suggested that *M. pneumoniae* may be a common cause of symptomless myocarditis and serial electrocardiographic and enzyme studies are advisable in patients with this infection. In the present patient a loud pericardial friction developed coincidental with cardiographic changes. The electrocardiograph returned to normal 6 weeks after the onset of the respiratory symptoms.

The study of this patient aids in the understanding of the protean clinical manifestations of *M. pneumoniae* infection and re-emphasizes the importance of specific serological testing for this organism in patients with acute polyradiculoneuritis.

References

- HAYFLICK, L. & CHANOCK, R.M. (1965) *Mycoplasma* species of man. *Bacteriology Review*, **29**, 185.
- HODGES, G.R., FASS, R.J. & SASLAW, S. (1972) Central nervous system disease associated with *Mycoplasma pneumoniae* infection. *Archives of Internal Medicine*, **130**, 277.
- HODGES, G.R. & PERKINS, R.L. (1969) Landry-Guillain-Barré syndrome associated with *Mycoplasma pneumoniae* infection. *Journal of the American Medical Association*, **210**, 2088.
- HOLMES, J.M. (1947) Neurological complications in atypical pneumonia. *British Medical Journal*, **1**, 218.
- LAMBERT, H.P. (1969) Infections caused by *Mycoplasma pneumoniae*. *British Journal of Diseases of the Chest*, **63**, 71.
- LERER, R.J. & KALAVSKY, S.M. (1973) Central nervous system disease associated with *Mycoplasma pneumoniae* infection: report of five cases and review of the literature. *Pediatrics*, **52**, 658.
- LEWES, D. & RAINFORD, D.J. (1970) Echoviruses and carditis. *Lancet*, **i**, 52.
- LEWES, D., RAINFORD, D.J. & LANE, W.F. (1974) Symptomless myocarditis and myalgia in viral and *Mycoplasma pneumoniae* infections. *British Heart Journal*, **36**, 924.
- NOAH, N.D. (1974) *Mycoplasma pneumoniae* infection in the United Kingdom—1967–73. *British Medical Journal*, **2**, 544.
- STEELE, J.C., GLADSTONE, R.M., THANASOPHON, S. & FLEMING, P.C. (1969) *Mycoplasma pneumoniae* as a determinant of the Guillain-Barré syndrome. *Lancet*, **ii**, 710.
- STERNER, G. & BIBERFELD, G. (1969) Central nervous system complications of *Mycoplasma pneumoniae* infection. *Scandinavian Journal of Infectious Disease*, **1**, 203.