

umbilicus, he said 'because the patient does not need it and I certainly do not like cutting through it.'

Be that as it may, the approach described in the article is not new, and is a good one. However, the name 'perimedial' is equally confusing as the 'lateral midline'. It will be far clearer if we called it simply, 'paraumbilical midline incision'.

DILIP RAJE FRCS

Senior Lecturer and Consultant

University Hospital of the West Indies

Kingston, Jamaica

I was interested to read Hampson and Rainsbury's account of 'the perimedial incision' (*Annals*, January 1990, vol 72, p64) for access to the peritoneal cavity.

The disadvantage of the method described is theoretical only since it exposes undercut skin and subcutaneous adipose tissue on the medial flap for the whole length of the laparotomy wound, which could result in ischaemia and delayed healing.

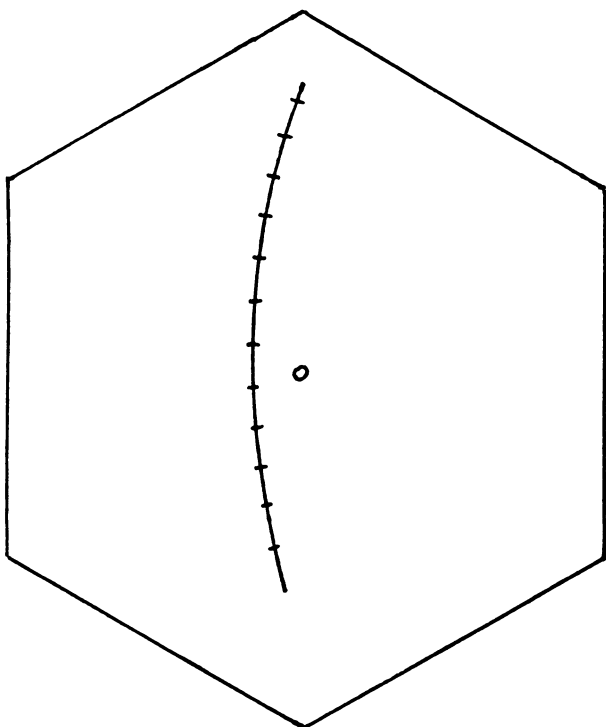


Figure 1. The banana incision for laparotomy.

I favour an approach I have termed 'the banana incision' (Fig. 1) which, like the perimedial, avoids both the untidy close skirting of the umbilicus necessary in a midline incision and the necessary reflection of the rectus muscle laterally in the traditional paramedian approach.

The banana incision is, as its name implies, a vertical curvilinear incision through the skin. It is performed in one sweep from midline cranially to midline caudally, curving away from the umbilicus in an arc of large radius, angling the subcutaneous part of the incision towards the linea alba. Less undercutting of the medial flap occurs than with the perimedial incision, but otherwise both techniques have the advantages of simplicity and cosmesis.

GRAHAM LAYER MA FRCS

Senior Surgical Registrar

St Thomas' Hospital  
London

### A randomised controlled trial of medroxyprogesterone acetate in mastalgia

We read with interest the above article by Mansel *et al.* (*Annals*, March 1990, vol 72, p71). As they point out, there is little firm evidence for a hormonal basis to cyclical mastalgia and less for a rational hormonally based treatment. Hypnotherapy has been used with success by ourselves and others (1) in conditions with uncertain aetiologies such as irritable bowel. We have recently treated five women with severe cyclical mastalgia with hypnotherapy. They were referred after assessment in a general surgical clinic. These patients were aged between 20 and 30 years and each had cyclical pain and tenderness sufficient to interfere with their daily life. They had failed to respond to danazol (4/5) or had intolerable side-effects (1/5).

The initial hypnotherapy interview lasted 30–35 min and subsequent sessions lasted 10–25 min. Relief of all symptoms was achieved at the first session in each of the women. The ultimate aim was to teach the patients autohypnosis and this was successfully achieved on average by the fourth session. On average, each episode of hypnosis provided an analgesic effect which lasted from 2 to 24 h, although one patient was symptom free for 2 weeks.

There are no apparent side-effects from this modality of treatment.

The mean length of follow-up is now 6 months. Autohypnosis is still successful in all of the five in abolishing pain and tenderness. No further reinforcing sessions have been needed.

The age group of these patients makes them ideal subjects for hypnotherapy and our initial successes have encouraged us to assess this modality more formally in a prospective trial.

A SEREWEL MB BCH

Clinical Assistant in Anaesthetics

J A HAGGIE MD FRCS

Surgical Registrar

D CADE FRCS

Consultant Surgeon

Leighton Hospital  
Crewe, Cheshire

### Reference

1 Whorwell PJ. Diagnosis and management of irritable bowel syndrome. *J R Soc Med* 1989;82:613–14.

### Optimal operative treatment in acute septic complications of diverticular disease

The article by Messrs Corder and Williams (*Annals*, March 1990, vol 72, p82) suggested that emergency colonic resection for peritonitis is a recent development. No references earlier than 1981 were given. In fact, good results of the emergency resection were reported in 1958, four patients (1); 1964, 13 patients (2); 1966, 110 patients (3); and 1968, 25 patients (4).

JOHN DAWSON MS FRCS

Consultant Surgeon

King's College Hospital  
London

### References

1 Ryan P. Emergency resection and anastomosis for perforated sigmoid diverticulitis. *Br J Surg* 1958;45:611.

2 Large JM. Treatment of perforated diverticulitis. *Lancet* 1964;1:413.