

be part of a general intestinal tubercle or secondary to caseating lymph nodes in the pre-aortic and paraduodenal areas. Actinomycotic infections are exceptionally rare.

The Duodenal Cap in Infancy and Children

Radiological examination of the stomach and duodenum in infancy is commonly initiated to exclude or confirm pyloric musculature hypertrophy or congenital duodenal stenosis. The latter condition is rare in the first part of the duodenum but considerable dilatation may occur at this site secondary to stenosis in other portions of the loop. Several cases of duodenal ulceration in infancy radiologically diagnosed (as opposed to autopsy findings) have been reported. The writer has not been in a position to see such cases but has noted a number of patients in the age group 16 to 18 with duodenal ulceration who date

their symptoms from three or four years earlier.

Summary

The technique of radiological examination of the first part of the duodenum has been discussed and the findings in duodenal ulceration have been described. The benefit to be obtained from liaison between radiologist and clinician has been stressed.

Acknowledgments

I wish to thank Sister J. Hathway and the Radiographic Staff at the Royal Northern Hospital for their cheerful assistance at all times. The illustrations are selected from routine examinations personally performed, with the exception of Fig. 18, for which I am indebted to Dr. M. I. Wray.

MAMMARY TUBERCULOSIS

Critical Discussion with an Illustrative Case

By DUNCAN M. FORREST, F.R.C.S., and RAYMOND PARKES, M.B., Ch.B.

From Harefield Hospital, Middlesex

Introduction

This paper was intended originally as a short record of a case of mammary tuberculosis, but, finding that the considerable number of reports on the disease that have appeared (from all parts of the world) since the classical description of Sir Astley Cooper in 1829 have tended to be confusing, uninformative and, occasionally, positively misleading, we have thought it worth while discussing the matter in greater detail.

That the disease seems rarely to have been described by workers in the field of tuberculosis but often by surgeons who, naturally, have tended to approach it as a local problem, has, we believe, been responsible for its isolation and incomplete study from the standpoint of pathogenesis in particular.

Clinical Characteristics

Incidence

Mammary tuberculosis is uncommon though not rare. Morgen (1931), in a careful review, claimed to find 439 cases recorded between 1829

and 1931, and within four years McGehee and Schmeisser (1935) believed that, with their own cases, the total was 535; between 1920 and 1942 Klossner found 50 cases (none of which were included by the previously mentioned authors) in Finland. However, it is almost certain that the number of cases occurring is significantly greater than the number reported, and so many single cases and small series have now appeared in the world literature that it is pointless to continue enumerating them.

The incidence is most commonly expressed as a percentage of all breast diseases and there is little difference in various estimations: 1.04 per cent. (of all breast diseases operated upon at the Presbyterian Hospital, Chicago (Gatewood, 1916)), 1.5 per cent. (24 cases of tuberculosis from 1,587 patients with breast pathology at St. Bartholomew's Hospital, London, between 1890 and 1903 (Scott, 1904)), 1.78 per cent. (8 in 447 cases of breast disease at Memphis General Hospital from 1922 to 1934 (McGehee and Schmeisser, 1935)). It will be seen that tuberculosis probably repre-

sents about 1.5 per cent. of all diseases of the breast—or did before the antibiotic era.

At the Mayo Clinic between 1909 and 1934 there was one case of tuberculous mastitis for every 200 of mammary carcinoma (Harrington, 1936). Bloodgood (1921) claimed that tuberculosis accounts for 6 per cent. of benign lesions of the breast. Schultze-Jena (1951) has stated that, among breast diseases in Germany from 1947 to 1950, mammary tuberculosis has become more common, but this may merely be a reflection of the general increase in tuberculosis which has followed the war in that country.

Sex

The condition is much more common in women than men though why this should be is far from clear; relationship with lactation has been alleged but not substantiated. Rossi (1950) gives the female : male ratio as 25 : 1, and in his review Morgen found 20 males—that is, 22 : 1. This may be accounted for in part by the fact that in the male the disease must often be described as 'tuberculosis of the chest wall.'

Age

The disease is first seen in the majority of patients between 20 and 50 years of age (Morgen), though the extremes of life are occasionally affected. Demme (1889) reported an often-quoted case, proved by animal inoculation, in a male infant of 6 months, while Impallomani (1949) recorded patients of 12 and 75 years, and Schultze-Jena (1951) two in the ninth decade.

Bacteriology

In this respect Raw (1924) is widely cited: he claimed to isolate (by rabbit inoculation followed by culture on glycerine agar) the bovine tubercle bacillus from the lesions of three of his seven patients, and suggested that this organism was invariably the one responsible for tuberculous mastitis. This general conclusion is clearly unwarranted, but we have been unable to find typing of the organism carried out by other writers on the disease. However, on general grounds the human bacillus is more likely to be the causative organism (at least in Europe), the bovine bacillus having, in a recent survey, been found responsible for little more than 20 per cent. of all extrapulmonary lesions in Great Britain (Wilson *et al.*, 1952).

Pathology

Classifications of the types of lesion proceeds, in many papers, to unnecessarily fine variations, but we believe it is sufficient to define the two

main variants in the pathological scale as in tuberculosis in general.

1. *Nodulo-caseous type*. This seems to be the commoner. Cellular aggregation and caseation are predominant, and there is little fibrosis. The lesions are usually single and large, but may be small and multiple as in miliary tuberculosis. Chronic sinuses are more likely to occur in this type.

2. *Fibrous type* ('sclerosing type' of some authors). Fibrosis, obviously, is dominant and may be extremely dense with little or no caseation present. Sinuses, therefore, do not tend to occur. The skin in the vicinity of the lesion may be dimpled or the nipple inverted. The resemblance to scirrhous carcinoma is often complete even when the breast is cut ('tuberculous pseudo-neoplasm' of Chauvin, 1923).

The characteristics of both types, one or other predominating, may naturally occur in any one lesion.

The usually described routes by which the breast may become infected are:—

1. *Lymphatic*, by retrograde spread of disease to the regional lymph nodes and along lymphatic channels normally draining the breast. Tuberculous disease in the regional nodes may be recent or old disease that has broken down by endogenous recrudescence.

2. *Haemic*, from a lesion either overt or unidentified elsewhere in the body.

3. *Direct*, from disease in structures underlying the mammary gland such as rib, costochondral junction, sternum or pleural cavity; rarely reinfection with the tubercle bacillus ('superinfection') through the skin or nipple.

4. *Lactiferous ducts*, spread of disease from the nipple region.

Symptoms and Signs

Commonly the patient complains of a painless lump, though in 6 per cent. of Morgen's cases pain (which must largely have been due to a rapid increase in size of the lesion) was a prominent symptom. When such increase in size occurs the area is tender and often red and inflamed. The average duration of breast swelling before the patient seeks advice has been said to be from two to four months (Scott, 1904) up to 18 months (Morgen) with the longest between five and six years (Scott). Sinus formation with considerable deformity was present in about one-half of cases before the era of effective anti-tuberculous drugs, and is certainly liable to occur if the tuberculous mass is incised in mistake for a pyogenic abscess. Enlargement of the regional lymph nodes may be present and the sum of information in the literature

indicates that this is more likely to be found than not.

Diagnosis

The disease is usually confused clinically with mammary carcinoma or pyogenic abscess; differentiation during pregnancy from carcinoma of pregnancy and during lactation from non-specific lactation mastitis may be difficult. Carcinoma and tuberculosis have occasionally been found in the same breast (McGehee and Schmeisser, 1935; Grausman and Goldman, 1945; Musante, 1947; Schultze-Jena, 1950; Mineo, 1952), but this is distinctly rare.

Tuberculous mastitis has also to be considered in the differential diagnosis of benign tumours, traumatic fat necrosis, chronic mastitis, 'plasma cell' mastitis, actinomycosis and gumma (now very rare).

Diagnosis rests on clinical history, physical examination, and the examination and culture of pus, sinus scrapings and abnormal tissue. The taking of biopsy material, though occasionally helpful, does not meet with universal approval because of the possibility of disseminating carcinoma cells should the lesion be neoplastic.

Prognosis and Treatment

Prognosis in relation to life is usually regarded as good though the fate of these patients in relation to tuberculosis in other systems does not appear to be known; untreated, increasing local destruction can be expected, but radical treatment in the days before the use of anti-tuberculous drugs was rarely followed by recurrence. With drug treatment the position is not yet clear, but if employed reasonably early the lesion may be expected to subside; certainly radical surgery should now rarely be necessary.

Brief Case Report

A widow, aged 77, had noticed a lump growing rapidly in the right breast for about three weeks; it was not painful but was irritated by her clothing. She had had a winter cough for some years, but could remember no previous illnesses.

On examination. She was frail and emaciated and had a moderately severe cough with some mucopurulent sputum, unfortunately not examined for tubercle bacilli.

Right breast. There was a slightly reddened swelling about 3 cm. in diameter in the upper and outer quadrant; it was superficially fluctuant and adherent to the skin. Beneath it was a fairly hard, irregular mass about 5 cm. in diameter, which was lightly tethered to the pectoral muscle. There was no nipple retraction. There were several firm, discrete, clearly enlarged, though

non-fluctuant lymph nodes in the right axilla, but no palpable nodes elsewhere.

Left breast. Normal.

The lesion being regarded as a carcinoma, local mastectomy was performed with removal of as much axillary tissue as the preservation of the pectoral muscles permitted. It was not thought justifiable to perform a radical operation in a woman of this age.

There was sound healing of the wound on the 10th day, though throughout there was intermittent pyrexia up to 100° F. On the 17th day she collapsed in severe left-sided heart failure (secondary to systemic hypertension), developed a left pleural effusion (cardiac in origin) and died. Chest X-ray shortly before death revealed a large left-sided pleural effusion and a few large calcified areas in the right lung field, the left field being obscured.

Pathological Findings

Right breast. A cystic mass was present in the upper and outer quadrant about 7 cm. from the nipple; it was 4 cm. in size, apparently thick walled and filled with caseous material. Closely overlying it was an area of fat necrosis. A pectoral lymph node 2 cm. in diameter and other smaller nodes in the axillary tissue were found. Microscopically, the main mass was a caseous abscess with a thin fibrous wall but with little other surrounding fibrous tissue; it had arisen in a pectoral lymph node as indicated by remnants of lymph node structure about it. Towards one pole of the lesion there was a firmly calcified area 0.5 cm. in diameter. The 2 cm. pectoral and right axillary nodes contained confluent, caseating miliary and larger tubercles, but no calcification. No tubercle bacilli were discovered in any of the lesions. Fibro-adenomatous change was present in much of the remaining breast tissue, but there was no evidence of carcinoma. No direct connection between the lesion and costal cartilages, rib or pleural cavity was found.

Left breast. No gross abnormality.

Thorax. No evident disease in ribs or rib cartilages.

Lungs. These were extensively and firmly adherent to the parietal pleura and a few discrete, hard $\frac{1}{2}$ -2 cm. foci, and areas of fibrosis were scattered throughout the parenchyma of both lungs, in particular the right; there was generalized emphysema. Microscopically (and radiologically pre- and post-mortem), the $\frac{1}{2}$ -2 cm. foci were firmly calcified and some, in fact, ossified; pulmonary fibrosis and emphysema were confirmed, but no active tuberculous disease observed. The tracheo-bronchial and bifurcation lymph nodes were enlarged, firm, and adherent; the last group

contained numerous caseating tubercles, but no calcification. The internal mammary nodes were unfortunately not examined.

Alimentary tract. The mesenteric lymph nodes were considerably enlarged and many were intensely hard. On microscopy, some showed calcification and ossification, but no active tuberculous lesion. There was no naked-eye evidence of disease in the small or large intestines.

Other organs. No gross or microscopic evidence of tuberculosis.

Discussion of Case

In most respects the disease in our patient is in accord with the clinical characteristics already described, although she falls into an unusually late age group. The rate of growth of the lesion which, as stated, lay in a pectoral lymph node and not in breast tissue, is perhaps remarkable in so elderly a woman. It is unfortunate that it proved impossible to isolate and type the causative organism. The evidence indicates that the pulmonary disease was of long standing.

It may be suggested, with some reticence, that the original disease took the following course: primary infection (presumably with the human type bacillus) occurred in the lungs and then spread (swallowed sputum?) to the intestine with subsequent mesenteric lymph node involvement while the body tissues were still in the pre-allergic phase; that is, a so-called 'double primary' which is probably not uncommon when the original infection has been massive or repetitive in a short period of time.

It is very probable that the lymph nodes in the pectoral region were originally involved by the retrograde spread of reactivated old primary disease (lymph node endogenous recrudescence (Pagel, 1953)) from tracheo-bronchial and related nodes, in which activation was also observed, to and through the anterior mediastinal or (and) the internal mammary nodes; though it is impossible to know when this process occurred. Caseation associated with calcification in the lesion suggests that fairly recent recrudescence of disease had occurred in the pectoral lymph nodes followed by extension into the neighbouring axillary lymph nodes where active tubercles—but no calcification—were seen. While caseation in the breast lesion indicates recent disease, which may have accounted for its rapid increase in size, calcification suggests healing which had probably occurred more than six months before the patient attended hospital, but possibly not materially longer than 12 to 18 months. Calcification in one place and progression in another may have been occurring at the same time. As calcification was absent from the axillary nodes it is more likely that disease

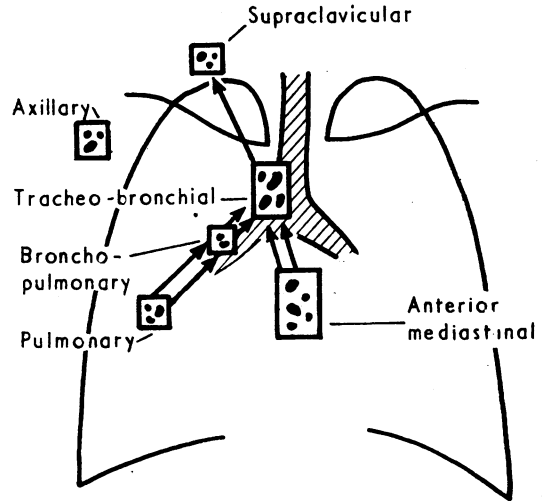


FIG. A

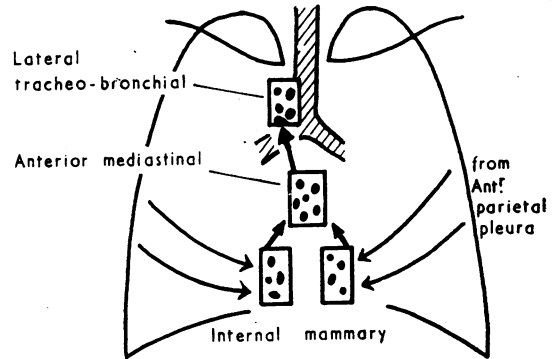


FIG. B

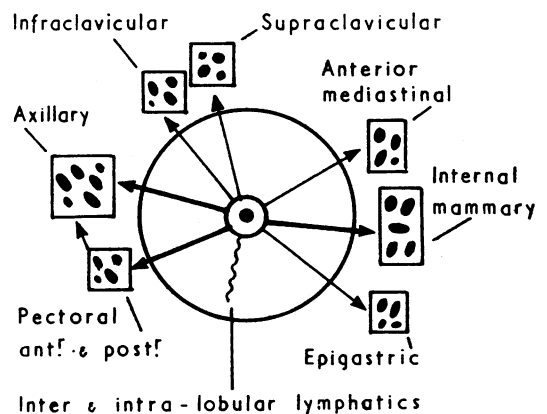


FIG. C

Diagrammatic representation of relevant intrathoracic and regional mammary lymph nodes. Arrows indicate normal direction of lymph flow. C. Heavy arrows; main routes of lymph drainage.

proceeded to them from the pectoral nodes rather than in the reverse direction.

While it is realized that the foregoing is somewhat controversial there remains no doubt that tuberculous disease spread in this patient by the lymphatic route, though it is unfortunate that the internal mammary nodes were not examined, their possible significance not being recognized at the time of autopsy.

General Discussion

The accompanying diagrams indicate some of the most important lymph drainage and lymph node groups of the thorax and the breast, and the extent to which the breast has indirect lymphatic connection with nearly all the nodal groups within the thorax and with the cervical nodes. The node groups of particular interest in this discussion are the internal mammary (para-sternal) and the anterior mediastinal (sub-sternal) (see figs. B and C); a great part of the parietal pleura is drained by the former group ('Gray's Anatomy,' 1949) and they also receive important lymph afferents from the breast. The latter group also drain the breast to some extent and are closely related and in communication with the internal mammary and tracheo-bronchial nodes.

The breast and its environment may be involved by tuberculous disease which has broken the confines of regional lymph nodes (see fig. C) and proceeded against the lymph flow to a greater or lesser distance along the lymphatic vessels, the valves of which, however, tending to resist such advance until they are destroyed by disease. Any group of regional lymph nodes—but most commonly the internal mammary, anterior mediastinal, axillary, pectoral and supraclavicular—may be invaded by disease (from a pulmonary or extra-pulmonary source) which may either continue its retrograde course from them or heal; should it heal, recrudescence may occur at a later date—perhaps years later—and the disease progress to breast. There are obviously a number of natural barriers to this process.

Largely as a result of the work of Burke (1940, 1947, 1950, 1954), there is considerable evidence that tuberculous disease often spreads from the pleura to the internal mammary nodes; which supports in great part the conclusions of Souligoux (1894) and Kaufmann (1930, 1931, 1933) that the majority of spontaneous tuberculous abscesses of the chest wall arise from the breakdown of disease in these nodes, and, in those instances of post-mortem examination of patients with pleural or pleuro-pulmonary tuberculosis where these nodes are sought, they are often found enlarged and caseous (Burke, 1950). Further, on the grounds of his own animal experiments and the report of

Roper and Waring (1952) on the fate of young people who had sero-fibrinous tuberculous pleurisy treated with shorter or longer periods of rest, Burke (1954) tends to the opinion that the frequency and extent to which the internal mammary nodes (and, incidentally, the posterior mediastinal nodes) are diseased, may depend, at least in part, on the duration of rest allowed patients during the active phase of pleural disease; that is, they may be related to the frequency and (or) amplitude of respiration during this time. There is, then, good reason to believe that tuberculous disease may, on occasion, pass from these nodes in retrograde fashion into the breast lymphatics. It is not suggested that this is necessarily the most important lymphatic route, for disease can spread to the other regional lymph node groups of the breast from various sources: from cervical nodes to supra-clavicular, infra-clavicular and axillary nodes; from the spine to axillary nodes; and from tracheo-bronchial to anterior mediastinal or internal mammary nodes. It may then proceed from any of these regional nodes along lymphatics toward the breast and, in many instances, this retrograde movement probably follows lymph nodular recrudescence of old disease. However, the association of tuberculous axillary or other regional mammary nodes with tuberculous mastitis does not necessarily indicate that this process has occurred, for, obviously, disease may have spread to them in the direction of normal lymph flow; elucidation may then have to rest on histological interpretation as in our own case. It seems possible that disease which has spread to the breast from a group of tuberculous regional lymph nodes may travel through the deep lymph plexuses to a part of the breast not directly drained by that group. Historically, it is interesting that Velpeau (1853) distinguished three types of mammary tuberculosis, two of which he named 'lymphatic tumours' and 'lymphatic degeneration.'

This is not to imply that haemic spread to the breast from some distant tuberculous focus (clinically identifiable or unidentifiable) does not occur, though its occurrence is the subject of much divergence of opinion. Some Italian and other continental authors (e.g. Mineo, 1952; Rossi, 1950; and Schultze-Jena, 1951) clearly indicate that they think tuberculous mastitis invariably arises as a result of blood-borne infection; while McKeown and Wilkinson (1952) state: '... it would seem that the breast is resistant to tuberculous infection by the blood stream.' These extremities of opinion and the evidence upon which they are based are unsatisfactory, and they are both likely to be inaccurate; the former opinion is stated by its authors with negligible evidence, while the latter rests largely on a paper

by Raw (1924) and work by Nagashima (1925) which is widely drawn on in this context. Raw's paper is very brief and certainly does not throw any light on the methods by which disease spreads to the breast (though he was of the personal opinion that it was usually from diseased cervical lymph nodes); on the other hand, Nagashima examined microscopically the breasts of 34 female patients dying of tuberculosis—some of acute disseminated disease—and was unable to find evidence of tuberculosis. This seems tenuous evidence indeed from which to conclude that blood-borne spread to the breast is very rare or does not occur, and that the breast 'resists' such spread. On the whole, if tuberculous mastitis is found in association with other evidence of extrapulmonary tuberculosis, it is most likely to be part of a post-primary haematogenous manifestation. In the cow, however, contrary to what seems to happen in the human subject, tuberculosis of the udder is a haematogenous infection and hardly ever due to retrograde lymphatic spread from the supra-mammary lymph nodes (Francis, 1947).

It is of interest that in 1912 Kurashige *et al.* isolated tubercle bacilli by guinea-pig inoculation from the milk of 17 in a series of 20 lactating women with tuberculosis; 9 of the 20 patients with fairly early disease had tuberculous bacillæmia (proved by guinea-pig inoculation), and of these 9, bacilli were demonstrated in the milk of 6. It is uncertain whether or not there was any clinical evidence of mammary disease. A very few, mostly unimpressive, reports also indicated this finding before 1912, but, in spite of the fact that certain investigators—for example, Griffith and Griffith (1911) and Gaiger and Davies (1933)—have shown that tubercle bacilli may appear intermittently in the milk of tuberculous cows when no lesion can be demonstrated in the mammary gland, and that Calmette (1923) remarked: '... it seems established that, although excretion of the bacilli by the mammary glands of tuberculous females is rather rare, it may nevertheless occur in certain cases even in the absence of a local lesion,' remarkably little work appears to have been done to substantiate the findings of Kurashige, and it is extraordinary that this aspect of human tuberculosis is largely a matter of speculation. However, it is unlikely that the passage of tubercle bacilli in the milk of lactating tuberculous mothers is a common happening.

From analogy then with tuberculous pathology in general and the evidence of the literature on tuberculous mastitis (in which the majority of reported cases appear to us to be of lymphatic origin) in association with the foregoing argument we suggest that the lymphatic mode of spread (perhaps most frequently via the intrathoracic and

internal mammary nodes) is commoner than the haemic, though how much so it is impossible to say. There is little more to add about the 'direct' mode of spread apart from the fact that it may well occur on occasion by virtue of an enlarged caseous internal mammary node 'pointing' through into the breast; it seems to be less common than lymphatic spread, though it may sometimes predominate in the series of some clinicians.

Many of the reports of tuberculous disease spreading from the nipple along the lactiferous ducts are not very convincing and the concept of tubercle bacilli entering the breast in this way (apart from the rare occurrence of reinfection) appears improbable. When 'duct' lesions do occur disease will tend to lie in the peri-ductal lymphatics (*vide* Tuberculous Mastitis Obliterans, Lee and Floyd, 1934) to which it is most likely to spread by the lymphatic retrograde process or by the blood stream. Some of the cases of this 'peri-duct mastitis' group may well have been examples of plasma cell mastitis (Cheatle and Cutler, 1931; Adair, 1933) which has, in fact, been described as 'pseudo-tuberculosis' (Parsons *et al.*, 1944); occasionally the clinical resemblance to a tuberculous lesion may be complete (though there is some tendency to spontaneous regression of the inflammatory element), while the histological resemblance, though sometimes very close (e.g. giant cell systems), does not satisfy all the criteria of the tuberculous process, and eosinophilic 'plasma cells' are usually numerous. Harrington (1954) believes that, on the histological picture alone, confusion may arise and, for this reason, considers that before a firm diagnosis can be made tubercle bacilli should be found in the abnormal tissue; but this seems an unnecessarily strict criterion when the lesion can be examined histologically.

Occasionally, pathological diagnosis of mammary tuberculosis may present difficulty. Tubercle bacilli may be seen in smears or grown from sinus scrapings, but they are not easily grown from cut tissue; where they cannot be isolated histological diagnosis is of paramount importance and naturally rests upon identification of epithelioid cells, Langhan's giant cells and caseation, and sometimes tubercle bacilli in an appropriately stained section.

Plasma cell mastitis may not stand alone in suggesting tuberculous pathology and it is possible that some of the reported cases of carcinoma and tuberculosis occurring within the same breast have been carcinomas with associated 'foreign body' giant cell accumulations, though it is true that the two diseases can occur together. The expert in tuberculous histopathology may be required to clarify such problems.

Apparently isolated sarcoid lesions within the breast have been described (Geschickter, 1945) but must be very rare, and the difficulty in distinguishing them from frank tuberculosis very great.

The word 'primary' is used widely in the literature when tuberculous disease elsewhere than in the mammary region has not been clinically identified. Its use in this sense is confusing and better discontinued for it does not refer to the primary complex of initial tuberculous pathology. Klossner's suggestion (1944) that 'primary' be replaced by 'isolated' in this context and 'secondary' by 'combined' seems sensible. It may be that some of the 'isolated' lesions reported in the literature followed tuberculous pleurisy. True primary tuberculosis of the breast appears, as might be expected, to be extremely rare, and some of the cases reported as such are not convincing (e.g. Ferrando *et al.*, 1953); when it does occur it must follow trauma to the nipple or nearby skin with the subsequent entry of tubercle bacilli, and the major part of the disease process will be borne by the regional lymph nodes.

Pre-operative diagnosis obviously rests on physical examination and one or other of the techniques already indicated, but certain difficulties may be met. There is in the literature a tendency to make the distinction between acute mastitis and tuberculosis (usually the nodulo-caseous form) appear unduly simple. Yet from time to time, without the aid of ancillary techniques (e.g. culture of pus, biopsy), it may be most difficult. Obviously, the former is much more common, generally more acute, and usually associated with more severe constitutional symptoms; but, should an acute mastitis be rendered indolent by inadequate or delayed penicillin or other antimicrobial therapy, the clinical picture may become misleading (e.g. Mills, 1953); and, further, if an acute lactation abscess is drained without due attention to its loculated nature, recurrence with sinus formation is apt to occur (Patey, 1954). It is notoriously difficult to differentiate carcinoma from the fibrous type of tuberculous lesion which may be adherent to skin and muscle and associated with enlarged pectoral and axillary lymph nodes. In the majority of instances of this dilemma the lesion will be a carcinoma and it would seem ill advised to take a biopsy specimen in order to exclude the presence of a much less common lesion. Inspection of the excised tumour at operation before proceeding to radical removal of the breast can undoubtedly assist diagnosis, but may often be indecisive; and examination of frozen sections is unreliable unless performed by a pathologist skilled in the method. X-ray of the breast is probably of little value but may detect

calcification (Leborgne, 1954). However, the clinical picture of mammary carcinoma in a woman under 40 years of age should cause tuberculosis to be considered in the differential diagnosis; for, in a young woman, the unnecessary loss of a breast is an appalling tragedy.

Tuberculosis elsewhere in the body is not always easily demonstrated, though a careful search does not appear to have been made in all the reported cases. The presence of active pulmonary tuberculosis in 16 per cent. of cases of tuberculous mastitis given by Grausman and Goldman is, unfortunately, not very reliable because of its method of derivation.

The principles of treatment of the disease may be summarized as follows:—

1. If the diagnosis is certain, streptomycin and P.A.S. or I.N.A.H. must be used in dosage systems and combinations similar to those used in other forms of tuberculosis. Search for tuberculosis elsewhere is naturally made, and bed rest and other general measures employed for at least three months in the first instance. Local injection of streptomycin has been suggested and tried (Cesar, 1950; Perdomo de Fernandez, 1950), but apparently without striking success.

2. (a) If resolution occurs, and this may perhaps be expected in the majority of instances, no further treatment may be required.

- (b) If resolution does not occur, or is incomplete, surgical intervention will be necessary; on the one hand, to be certain that neoplasia is not being overlooked or, on the other, to remove the main tuberculous disease under the protection of appropriate anti-microbial therapy. In the latter case, in spite of the fact that as recently as 1950 Nagnibeda claimed that prognosis was poor if radical removal was not performed, extensive surgery should be unnecessary; though dissection of pectoral and axillary lymph nodes may be indicated.

3. Should the diagnosis be in doubt, it will be necessary to operate in order that the lesion may be inspected as already described. If tuberculosis is confirmed, it should be treated as outlined but, if it is impossible to exclude carcinoma, the breast must be sacrificed.

Conclusion

In the past mammary tuberculosis has been an uncommon, but not rare, disease; it has probably gone unrecognized on many occasions as the breast is not always examined post-mortem, particularly in sanatoria. In this era of effective anti-tuberculous drugs it may be expected to become rare indeed, but, at the present at least, it should be given due place in the differential diagnosis of breast pathology, though not such

unbalanced emphasis as to endanger the diagnosis and prompt treatment of the commoner and more dangerous carcinoma.

When the disease is discovered more careful investigation of the condition itself and of the other systems than has commonly been recorded in reports of known cases is required, and it may be of interest to elicit a past history of tuberculous pleurisy and its treatment. General treatment must not be too short (as has often been the case) and regular observation must be continued for some years.

It is suggested that retrograde lymphatic spread is the commonest way in which the breast becomes infected, although occasionally, in the experience of some clinicians, the direct route has been predominant. It is difficult to determine how frequently haemic spread occurs, but it seems considerably less common than lymphatic; it may sometimes be responsible for 'isolated' lesions although in the majority of such cases careful search in other regions will often reveal other extra-pulmonary tuberculous lesions. Possibly lymphatic spread from diseased parietal pleura may be responsible for some 'isolated' lesions. Reinfection via the nipple along lactiferous ducts may be expected to be a great rarity.

Summary

1. An outline of the clinical characteristics of tuberculous of the breast is given.

2. The disease in a woman aged 77 is described and discussed from the point of view of pathogenesis.

3. The routes by which the breast may become infected are discussed. The retrograde spread of disease from tuberculous regional lymph nodes (most probably after recrudescence) is mentioned; in particular, the possible significance, from this point of view, of the internal mammary nodes as a link between the lymphatics of the parietal pleura and those of the breast.

4. Difficulties in diagnosis, both clinical and pathological, are examined in some detail.

5. General principles of treatment are stated.

Acknowledgments

We express gratitude to Mr. D. Levi for his encouragement and permission to publish the case; to Dr. W. Pagel for his advice patiently and freely given; to Dr. E. Nassau and his department for the autopsy investigations; and to Miss P. Durand for her careful typing of the manuscript. Our thanks are also due to Mr. P. J. Bishop and Mr. D. F. Kemp, both of the Institute of Diseases of the Chest, London; the former for his assistance with the more elusive references, and the latter for his production of the diagrams.

BIBLIOGRAPHY

- ADAIR, F. E. (1933), *Arch. Surg. Chicago*, **26**, 735.
 BLOODGOOD, C. (1921), *Ibid.*, **3**, 3.
 BURKE, H. E. (1940), *J. Thor. Surg.*, **9**, 506.
 BURKE, H. E. (1947), *Trans. Amer. Climat. (Clin.) Assoc.*, **59**, 122.
 BURKE, H. E. (1950), *Amer. Rev. Tuberc.*, **62**, 48 (Part 2, Baldwin Memorial Issue).
 BURKE, H. E. (1954), *Brit. J. Tuberc.*, **48**, 3.
 CALMETTE, A. (1923), 'Tubercle Bacillus Infection and Tuberculosis in Man and Animals,' p. 455 (translated by W. B. Soper and G. H. Smith), 2nd edition, Williams and Wilkins, Baltimore.
 CESAR, S. (1950), *Clin. Contemp.*, **4**, 143.
 CHAUVIN, E. (1923), *Progr. med. Paris*, **38**, 109.
 CHEATLE, Sir G. L., and CUTLER, M. (1931), 'Tumours of the Breast,' p. 208, Arnold, London.
 COOPER, Sir Astley (1829), 'Illustrations of Diseases of the Breast,' London.
 DEMME, (1889), 'Bericht über d.Tätigkeit d.Jennerschen Kinderspitäls,' Bern.
 FERRANDO, H., COTTINI, G. F., and CASTELLANOS, L. (1953), *Sem. méd.*, B. Aires., **102**, 380.
 FRANCIS, J. (1947), 'Bovine Tuberculosis,' Staples Press, London.
 GAIGER, S. H., and DAVIES, G. O. (1933), *Vet. Rec.*, **46**, 900.
 GATEWOOD, (1916), *Interst. med. J.*, **23**, 272.
 GESCHICKTER, C. F. (1945), 'Diseases of the Breast,' 2nd edition, Lippincott, Philadelphia.
 GRAUSMAN, R. I., and GOLDMAN, M. L. (1945), *Amer. J. Surg.*, **67**, 48.
 'GRAY'S ANATOMY' (1949), 30th edition, edited by T. B. Johnston and J. Whillis, London.
 GRIFFITH, A. S., and GRIFFITH, F. (1911), Roy. Comm. Tuberc., Final Report, Appendix 111, p. 81.
 HARRINGTON, S. W. (1936), *Surg. Gynec. Obstet.*, **63**, 797.
 HARRINGTON, S. W. (1954), Personal communication.
 IMPALLOMENI, G. (1949), *Arch. Sci. Med.*, **87**, 269.
 KAUFMANN, R. (1930), 'Pathogénie des Abcès Froids Thoraciques,' Le Grand, Paris.
 KAUFMANN, R. (1931), *J. Chir. Paris*, **37**, 829.
 KAUFMANN, R. (1933), *Ann. Anat. path. med.-chir.*, **10**, 541.
 KLOSSNER, A. R. (1944), *Acta Chir. Scand.*, Suppl. 85, Helsinki.
 KURASHIGE, T., MAYEYAMA, R., and YAMEDA, G. (1912), *Z. Tuberk.*, **18**, 433.
 LEBORGNE, R. (1954), *El Tórax.*, **3**, 61.
 LEE, W. E., and FLOYD, W. R. (1934), *Ann. Surg.*, **99**, 753.
 McGEHEE, J. L., and SCHMEISSER, H. C. (1935), *Amer. J. Surg.*, **28**, 461.
 McKEOWN, K. C., and WILKINSON, K. W. (1952), *Brit. J. Surg.*, **39**, 420.
 MILLS, C. P. (1953), *Brit. med. J.*, **1**, 1427.
 MINEO, R. (1952), *Ann. Ital. Chir.*, **29**, 878.
 MORGEN, M. (1931), *Surg. Gynec. Obstet.*, **53**, 593.
 MUSANTE, C. (1947), *Arch. E. Maragliano*, **2**, 796.
 NAGASHIMA, Y. (1925), *Virchow's Arch. path. Anat.*, **254**, 184.
 NAGNIBEDA, N. I. (1950), *Vestn. Khir.*, **70**, 50 (No. 6).
 PAGEL, W. (1953), in 'Pulmonary Tuberculosis': W. Pagel, F. A. H. Simmons, and N. Macdonald, 3rd edition, Oxford University Press, London.
 PARSONS, W. H., HENTHORNE, J. C., and CLARKÉ, R. L. (1944), *Arch. Surg. Chicago*, **96**.
 PATEY, D. H. (1954), *Postgrad. med. J.*, **30**, 3.
 PERDOMO DE FERNANDEZ, C., and MURAS, O. (1950) *Rev. Tuberc. Urug.*, **18**, 17.
 RAW, N. (1924), *Brit. med. J.*, **1**, 657.
 ROPER, W. H., and WARING, J. J. (1952), *Trans. Nat. Tuberc. Assoc. N.Y.*, **150**.
 ROSSI, N. (1950), *Arch. Ital. Chir.*, **73**, 359.
 SCOTT, S. R. (1904), *St. Bart's Hosp. Rep.*, **40**, 97.
 SCHULTZE-JENA, B. S. (1951), *Zbl. allg. Path. path. Anat.*, **88**, 52.
 SOULIGOUX, (1894), 'Pathogénie des Abcès Froids du Thorax,' Thèse de Paris.
 VELPEAU, A. A. L. M. (1854), 'Traité des Maladies du Sein et de la Région Mammaire,' V. Masson, Paris.
 WILSON, G. S. N., BLACKLOCK, J. N. S., and REILLY, L. V. (1952), 'Non-Pulmonary Tuberculosis of Bovine Origin in Great Britain and Northern Ireland,' N.A.P.T., London.