

# Herpes Simplex Virus Type 1-Induced Hydrocephalus in Mice

KOZABURO HAYASHI,<sup>1\*</sup> YUZO IWASAKI,<sup>2</sup> AND KAZUO YANAGI<sup>3</sup>

*Laboratory of Viral Immunology, The Koriyama Institute of Medical Immunology, Koriyama, 963, Japan<sup>1</sup>; Department of Neuropathology, Institute of Brain Diseases, Tohoku University School of Medicine, Sendai, 980, Japan<sup>2</sup>; and Department of Virology and Rickettsiology, National Institute of Health, Tokyo, 108, Japan<sup>3</sup>*

Received 3 May 1985/Accepted 4 November 1985

Adult ICR/Sic or BALB/c mice developed hydrocephalus when attenuated herpes simplex virus type 1 (HSV-1) (strain Ska) was injected intracerebrally 2 to 4 weeks earlier and then after mice were challenged with the same virus or virulent HSV-1. Initial inoculation of the Ska strain elicited acute meningitis and ependymitis with transient mild hydrocephalus. Viral antigen was seen in the meninges and subependymal areas, and the virus was titrated during the acute phase of infection. After the second virus inoculation, more prominent inflammation was evoked in the same area, and the animals developed hydrocephalus, although viral antigen and infectious virus were hardly detected. When the mice were immunosuppressed with cyclophosphamide, they ceased to develop hydrocephalus. BALB/c nude mice did not show the same pathology, even though they were treated in the same way. When irradiated mice, which had been infected with the Ska strain intracerebrally 2 weeks earlier, received syngeneic immune spleen cells, they developed hydrocephalus. The T-cell nature of the effector cells was confirmed by the elimination of the pathology after treatment of the donor cells with anti-Thy-1.2 plus complement. No hydrocephalic mice were observed after treatment of the donor cells with anti-Lyt-1.2 plus complement, which gave further evidence of the T-cell nature of the effector cells as the Lyt-1<sup>+</sup>.2<sup>+</sup> antigen-bearing subsets. Intervals between priming and challenge virus inoculation could be more than 18 months. The presence of purified HSV-1 envelope protein was feasible for the development of the hydrocephalic animals.

Herpes simplex virus type 1 (HSV-1) is now the most common cause of nonepidemic viral encephalitis in the world (6). However, the pathogenesis of HSV-1 encephalitis in humans is poorly understood.

In 1978, a patient died because of HSV-1 encephalitis 5 months after onset of the disease. Pathological studies revealed deposition of the immune complex on the vascular wall and an unusual accumulation of lymphocytes in the perivascular area, which was accompanied by massive necrosis and loss of myelin (8). These features suggest that the immunopathological processes occur during the development of the HSV-1 encephalitis, particularly in prolonged cases of the illness (K. Hayashi, K. Yanagi, and S. Takagi, *J. Infect. Dis.*, in press).

We started to establish the animal model of the prolonged HSV-1 encephalitis using avirulent HSV-1 (strain Ska) which was attenuated by repeated zigzag passages of chorioallantoic membrane and suckling mouse brains to such an extent that even intracerebral (IC) inoculation into suckling mice failed to kill all of the mice (24).

After repeated IC inoculation of the Ska strain, most of the mice developed a marked hydrocephalus without any clinical signs. Several viruses are known to produce hydrocephalus both in patients and experimental animals (1, 9, 13, 14, 17). Primary damage of ependymal cells and periaqueductal edema with subsequent obstruction of the aqueduct have been the common pathological features of the disease. As a part of an inquiry into the influence of HSV-1 infection in the central nervous system (CNS), we report the morphological alterations and the possible mechanisms of HSV-1-induced hydrocephalus in mice.

## MATERIALS AND METHODS

**Virus.** A chorioallantoic membrane-grown strain (Ska) of HSV-1 was originally obtained from Kamesaburo Yoshino (24). Strain Ska was then propagated on African green monkey kidney (GMK) cells which were fed Eagle minimal essential medium supplemented with 10% fetal bovine serum, L-glutamine, and antibiotics (complete medium; CM). When the maximum cytopathic effect was observed, the virus was harvested from infected cells by three cycles of freezing and thawing. The lysate was then clarified by low-speed centrifugation at  $1,500 \times g$  for 10 min to remove cell debris. The CHR-3 strain of HSV-1 (5) was propagated on GMK cells by the same procedures described above. Strains Ska and CHR-3 were assayed for infective titer on GMK cells grown in 96-well microtitration plates (Linbro, Hamden, Conn.) overlaid with CM containing a final concentration of 2% heat-inactivated anti-HSV-1 rabbit antibody. The stock virus titer was  $10^{6.3}$  PFU/ml for strain Ska and  $10^{6.8}$  PFU/ml for strain CHR-3.

UV inactivation of HSV-1 strain Ska or strain CHR-3 was performed by exposing the virus to a Toshiba germicidal UV light at 98 erg/s per  $\text{mm}^2$  for 10 min. The virus titer declined by 99% after 10 min of exposure to UV light.

Purified envelope protein of HSV-1 was prepared by the method of Cappel (3).

The envelope protein demonstrated efficacy as a subunit vaccine against HSV-1 when it was administered intradermally (25). Normal GMK cell lysate was prepared from cells grown in a glass bottle after three cycles of freezing and thawing followed by the centrifugation at  $1,500 \times g$  for 10 min.

**Mice.** Six- to eight-week-old BALB/c mice, BALB/c nude

\* Corresponding author.

mice, and ICR/Slc mice were purchased from the Shizuoka Experimental Animal Farm (Hamamatsu, Shizuoka, Japan).

**Immunofluorescence.** Fluorescein isothiocyanate (FITC)-labeled anti-HSV-1 antibody was prepared from hyperimmune rabbit serum, and its specificity was confirmed by one- and two-step inhibition tests after its nonspecific reactivity was absorbed with acetone-treated mouse liver and brain powder (22). Mouse brains were frozen in precooled *n*-hexane at  $-80^{\circ}\text{C}$ . Cryostat sections (thickness,  $4\ \mu\text{m}$ ) of the brains were made, and they were fixed with acetone for 10 min at room temperature. FITC-labeled anti-HSV-1 antibody was then flooded onto the sections and reacted at  $37^{\circ}\text{C}$  for 1 h or at  $4^{\circ}\text{C}$  overnight. After the sections were washed with phosphate-buffered saline, they were mounted onto microscope slides with buffered glycerol and observed under a fluorescence microscope (7). FITC-labeled anti-mouse immunoglobulin M (IgM)( $\mu$ ), IgG( $\gamma$ ), and IgA( $\alpha$ ) antibodies were purchased from Hoechst Japan Inc. Ltd., Tokyo, Japan.

**Animal inoculation.** Under light ether anesthesia, mice were inoculated with 0.025 ml of undiluted HSV-1 strain Ska into the right hemisphere of the brain. Some animals were inoculated with an equal volume of the supernatant of normal GMK cell lysate in the same locus. A stepped needle was used (the needle shaft was enlarged in the middle, thus preventing penetration beyond the enlarged section). Two weeks after the initial inoculation, the mice were again challenged IC with 0.025 ml of either HSV-1 strain Ska or strain CHR-3. The mice were then observed daily for clinical signs of infection.

**Histopathology.** Mice were sacrificed at given times after IC inoculation of the virus by ether anesthesia or cervical dislocation. Brains were removed and fixed in phosphate-buffered 10% Formalin and embedded in paraffin. Sections were stained with hematoxylin and eosin (HE) or by the method of Klüver and Barrera for myelin (14a). The hydrocephalus was graded from  $-$  to  $++$  according to the degree of the dilation of the ventricles:  $-$ , no apparent ventricular dilation;  $\pm$ , rarefaction of callosal radiation accompanied by slight dilation of unilateral lateral ventricle;  $+$ , dilation of bilateral lateral ventricles;  $++$ , marked dilation of lateral ventricles with rarefaction of adjacent parenchymal tissue.

**Preparation of immune spleen cells.** Donor mice (BALB/c) were immunized with 0.3 ml of HSV-1 strain Ska intraperitoneally. Seven days later they were sacrificed by cervical dislocation, and spleen cells were passaged through stainless steel mesh. They were then suspended in RPMI 1640 medium supplemented with 10% fetal bovine serum and antibiotics. Cells that adhered to the glass were depleted by placing them in a large glass bottle at  $37^{\circ}\text{C}$  for 90 min.

Nonadherent cells were then collected after gentle agitation of the bottle. Erythrocytes were lysed by adding 0.83%  $\text{NH}_4\text{Cl}$  followed by three cycles of washing with RPMI 1640 medium. Normal spleen cells of BALB/c mice were also collected and suspended in the same medium as described above.

**Treatment of the immune spleen cells.** Immune spleen cells were incubated at  $37^{\circ}\text{C}$  for 1 h with appropriately diluted rabbit anti-mouse immunoglobulin antiserum (purchased from Hoechst Japan Inc. Ltd.). The cells were then washed and treated with a 1:10 dilution of low toxic rabbit complement (Cederlane Laboratories, Ltd., Ontario, Canada) at  $37^{\circ}\text{C}$  for 1 h. The cells were then washed and suspended in RPMI 1640 medium at a desired concentration. Similarly, immune spleen cells were treated with anti-Thy-1.2 antibody

(Cederlane) and rabbit complement with low toxicity to deplete Thy-1.2 antigen-bearing cells.

The immune spleen cells were depleted of Lyt-1.2- or Lyt-2.3-bearing cells by the treatment with either monoclonal anti-Lyt-1.2 or anti-Lyt-2.2 antibody (Cederlane) at  $4^{\circ}\text{C}$  for 1 h. After the cells were washed they were incubated at  $37^{\circ}\text{C}$  for 1 h with the rabbit complement with low toxicity. After these treatments, the percentage of viable cells was estimated by the trypan blue exclusion test. Approximately 45 to 60% of the cells were viable after these treatments, and the cells were washed three times with RPMI 1640 medium and adjusted to the desired concentration before they were transferred to recipient mice.

**Adoptive transfer of the immune spleen cells.** BALB/c mice or BALB/c nude mice were inoculated IC with 0.025 ml of HSV-1 strain Ska. Two weeks after IC inoculation, BALB/c mice were irradiated with 400 rad with a Shimadzu model SHT 250M-3 X-ray generator with a tube voltage of 250 kV, 0.3 Cu and 1.0 Al filters, a focus-source distance of 50 cm, and a dose rate of 0.951 Gy/min. BALB/c mice were then divided into the following four groups: group 1, mice were administered  $10^8$  immune spleen cells via the tail vein; group 2, mice were administered intravenously (i.v.)  $10^8$  immune spleen cells which had been treated with anti-mouse immunoglobulin plus complement; group 3, mice were administered i.v.  $10^8$  immune spleen cells which had been treated with anti-Thy-1.2 antibody plus complement; group 4, mice were administered i.v.  $10^8$  normal spleen cells.

BALB/c mice were divided into the following four groups: group 1, mice were administered i.v.  $10^8$  immune spleen cells; group 2, mice were administered i.v.  $10^8$  immune spleen cells treated with anti-Thy-1.2 antibody plus complement; group 3, mice were administered i.v.  $10^8$  immune spleen cells treated with monoclonal anti-Lyt-1.2 antibody plus complement; group 4, mice were administered i.v.  $10^8$  immune spleen cells treated with monoclonal anti-Lyt-2.2 antibody plus complement.

Two hours after adoptive transfer of the cells, recipient mice were inoculated IC with HSV-1 strain Ska under ether anesthesia. Two weeks after the cell transfer, mice were sacrificed and the brains were processed for histopathology.

**Virus titration in the infected brain.** Mice were sacrificed at set intervals after IC inoculation of the virus, and brains were removed aseptically. The brains were weighed and homogenized in a mortar to make a 10% emulsion. After centrifugation, the supernatant was serially log diluted, and infectivity was determined by the antibody overlay method in GMK cells plated on 96-well microtitration plates (Linbro).

**Neutralization titration of the sera and spinal fluid.** Mice were bled by cardiac puncture, and sera were separated by centrifugation at  $1,500 \times g$  for 10 min. Cerebrospinal fluid (CSF) was obtained from hydrocephalic mice by cisternal puncture.

Equal volumes of HSV-1 strain CHR-3 and the sample for the titration were mixed and incubated at  $37^{\circ}\text{C}$  for 1 h with occasional agitation, and then the remaining infectivity was assayed by the antibody overlay method on GMK cells. The endpoint was calculated by reciprocal dilution of the 50% reduction of viral plaques from the control.

**Immunosuppression by cyclophosphamide treatment.** Before virus inoculation, mice were immunosuppressed by daily intraperitoneal inoculation of cyclophosphamide (CY; 100 mg/kg of body weight) by administration of a total of 300 mg/kg of body weight. After virus inoculation, additional CY was given twice every other day.

TABLE 1. Hydrocephalus developed after prolonged HSV-1 encephalitis<sup>a</sup>

Route (interval [wk]) of infection <sup>b</sup>	No. of mice	Virus strain		No. of mice with the following grades of hydrocephalus <sup>c</sup>			
		Initial	Challenge	++	+	±	-
IC (2-4)/IC (2-4)	45	Ska	CHR-3	30	8	1	6
IC (2-4)/IC (2-4)	36	Ska	Ska	22	8	0	6
IP (2-4)/IC (2-4)	20	Ska	CHR-3	0	0	1	19
IC (4-8)	14	Ska		0	1	2	11
IC (2-4)/IC (2-4)	10	CM	CM	0	0	0	10
IC (2-4)/IC (2-4)	10	GMK cell lysate	GMK cell lysate	0	0	0	10

<sup>a</sup> ICR/Slc mice (8 weeks old) were inoculated IC with strain Ska. At 2 to 4 weeks after initial virus inoculation, the mice were challenged IC with either the same virus or strain CHR-3. At 2 to 4 weeks after challenge virus inoculation, mice were sacrificed and observed for pathological changes in the brain.

<sup>b</sup> IC, intracerebral inoculation; IP, intraperitoneal inoculation.

<sup>c</sup> See text for meaning of symbols.

**Immunoblotting analyses of the serum obtained from hydrocephalic mice.** Lysates of HEp-2 cells which were infected with MacIntyre strain of HSV-1 and herpes simplex virus type 2 (HSV-2) (strain uw268) were first subjected to electrophoresis in a slab of sodium dodecyl sulfate-polyacrylamide gels by the method of Laemmli (16).

The polypeptides were then transferred to a sheet of nitrocellulose (BA85; Schleicher & Schüll, Inc., Dassel, Federal Republic of Germany) by the method of Towbin et al. (23). The nitrocellulose sheet was incubated with appropriately diluted serum for 1 h at 37°C. It was then treated with a 1:1,000 dilution of peroxidase-conjugated anti-mouse IgG antibody (Cappel Laboratories, Cochranville, Pa.). The color was developed with diaminobenzidine.

## RESULTS

**Hydrocephalus induced after repeated intracerebral inoculation of HSV-1.** ICR/Slc male and female mice developed marked hydrocephalus after repeated IC inoculation of

attenuated HSV-1 strain Ska or IC inoculation of strain Ska followed by challenge with HSV-1 strain CHR-3 at the same inoculation site (Table 1). Figure 1 shows three hydrocephalic and three normal brains.

The bilateral cerebral hemispheres of the hydrocephalic brains have indentations because of the collapse of the dilated ventricles. The interval between the primary and secondary IC inoculations of the virus was 2 weeks in most cases, and pathological changes were observed 2 weeks after the secondary inoculation. However, when the interval between the primary and secondary virus inoculations was extended to 3, 6, 12, and 18 months, 10 of 10, 12 of 13, 9 of 10, and 10 of 10 ICR/Slc mice, respectively, still developed hydrocephalus. Therefore, once the animals were sensitized locally, the effect lasted a considerable length of time, probably even for the entire lifetimes of the mice.

Animals that were given a primary inoculation intraperitoneally did not develop hydrocephalus even after IC challenge with the virulent HSV-1 strain CHR-3 (Table 1). This phenomenon indicates that local sensitization is essential for the development of the pathological changes.

Few of the animals that were injected once IC with either HSV-1 strain Ska or CHR-3 but that were not administered the challenge inoculation developed pathological changes, although mild encephalitis was seen in a few animals (Table 1).

Control mice that were inoculated with either CM or GMK cell lysate by the same schedule did not show any pathological changes (Table 1).

**Histopathology of the hydrocephalic brains.** The dilation of the lateral ventricles was accompanied by rarefaction of paraventricular tissues, particularly of the callosal radiation (Fig. 2). The ventricular wall was irregular and often devoid of ependymal lining cells, and proliferation of subependymal astrocytes was a prominent feature of the denuded areas (Fig. 3). Mild mononuclear cell collection was occasionally encountered in perivascular spaces in the paraventricular parenchymal tissues (Fig. 4A). The third ventricle was apparently obliterated in the mice with severe hydrocephalus. Mild mononuclear cell infiltration was also commonly seen in the subarachnoid space of hydrocephalic mice (Fig. 4B).

Virus antigen was located by immunofluorescence staining during the acute phase of the initial viral inoculation.

Positive fluorescence of viral antigen was first detected 2 days postinfection (p.i.) in ependymal cells and in a part of the meninges (Fig. 5). It then spread more widely to the adjacent brain tissues. Figure 6 indicates viral antigen localization at 6 days p.i. At this time, viral antigen was most widely distributed in ependyma, neuronal cells, and glial

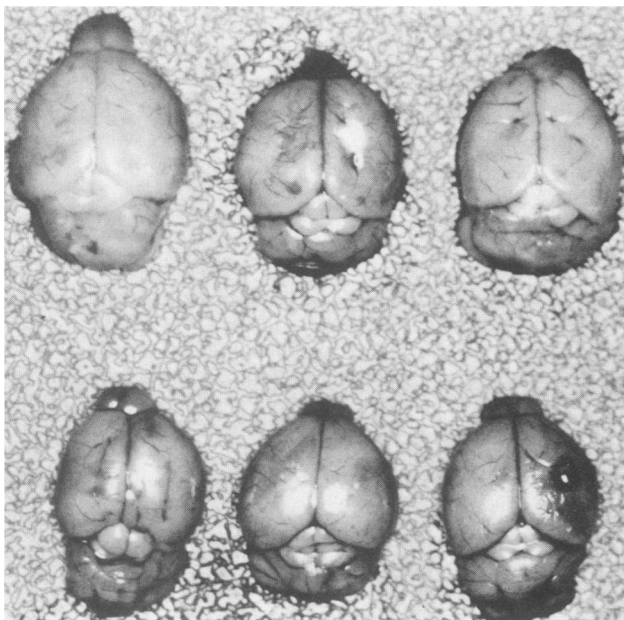


FIG. 1. Hydrocephalus induced after repeated IC inoculation of HSV-1. Upper three brains, hydrocephalic brains induced after repeated IC inoculation of strain Ska; lower three brains, normal brains.

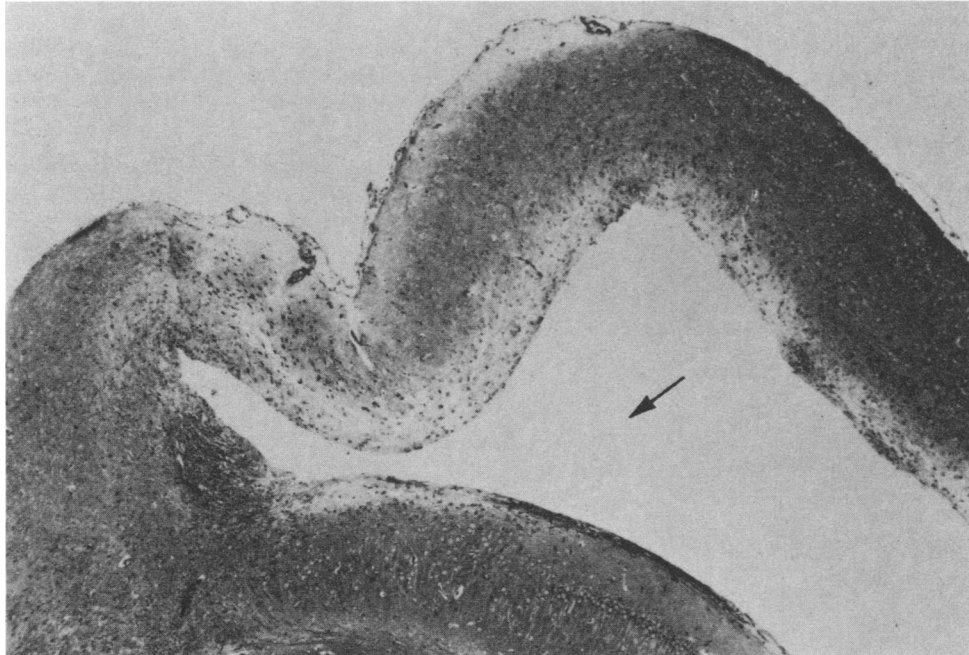


FIG. 2. Severe dilation of lateral ventricle (arrow) is accompanied by devastation of the callosal radiation. The destructive processes associated with the expansion of the ventricle extend partly into the adjacent cerebral cortex. Photograph was taken 14 days after the secondary IC inoculation of HSV-1 strain Ska and HE stain was used. Magnification,  $\times 100$ .

cells of the subependymal area along with the lateral ventricles. It was also seen in the meninges and the choroid plexus. It became almost undetectable at 10 days p.i. and in these areas lipofuscin accumulation was noted. After sec-

ondary viral inoculation, an immunofluorescence test for viral antigen revealed only occasional weak positive fluorescence in ependymal cells and the subependymal area. However, when the brains were stained with various FITC-

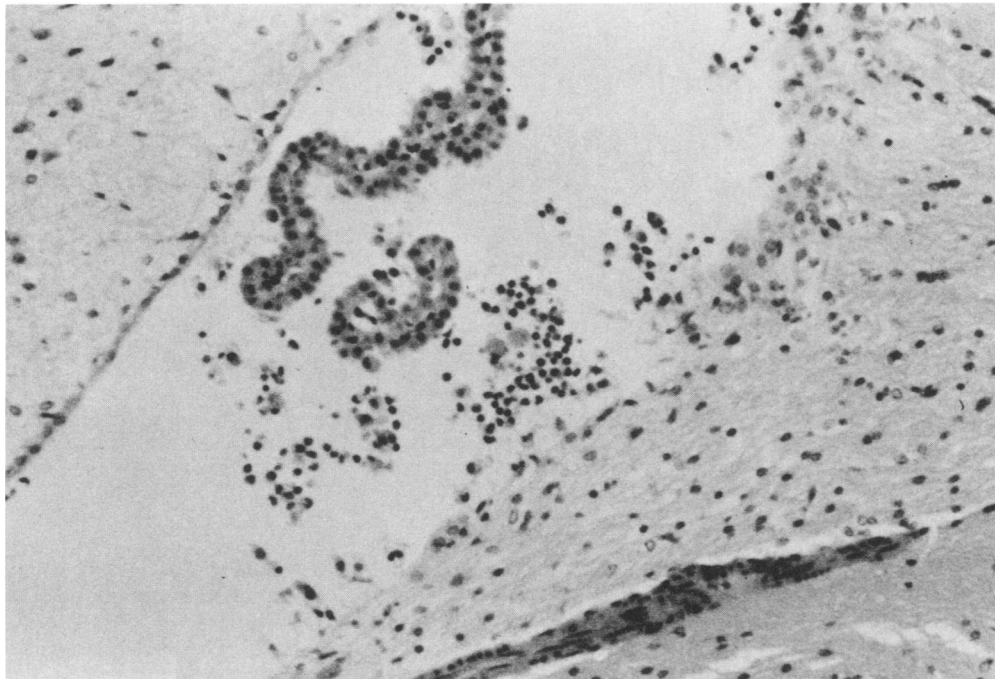


FIG. 3. Granular ependymitis in the wall of the lateral ventricle of a mouse challenged IC with HSV-1 strain CHR-3 3 days previously. Note the nodular proliferation of subependymal glia cells and mononuclear cell infiltration in the area devoid of ependymal lining cells. HE stain was used. Magnification,  $\times 120$ .

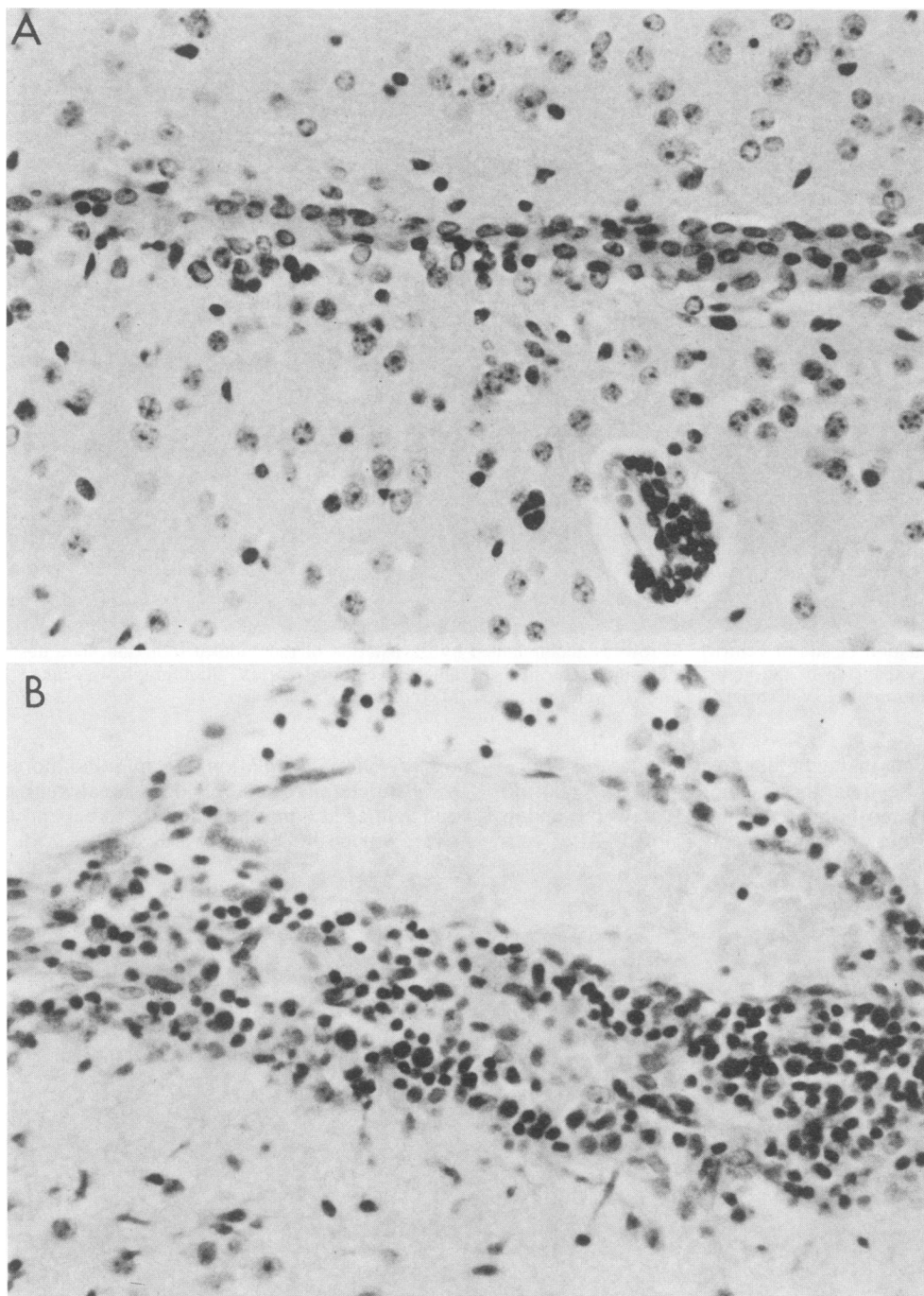


FIG. 4. (A) A small perivascular cell accumulation in the vicinity of the third ventricle. A few lymphocytes are also present within the subependymal parenchyma. Photograph was taken 10 days after secondary strain Ska inoculation and HE stain was used. Magnification,  $\times 120$ . (B) Accumulation of lymphocytes and plasma cells in the subarachnoid space. Photograph was taken 10 days after secondary strain Ska inoculation and HE stain was used. Magnification,  $\times 120$ .

labeled anti-mouse immunoglobulin classes (IgG, IgM, and IgA) after secondary virus inoculation, scattered IgM deposition was seen occasionally in the vascular walls or capillary endothelia and in the brain parenchyma. After treatment with 3 M NaSCN for 30 min at room temperature, some of the brains revealed weak viral antigen in the area identical to the place of the IgM deposition.

**Virus growth in the brain and the development of neutral-**

**izing activity in sera and CSF.** Kinetics of virus growth in the brain and the development of antibody activities in sera and CSF are shown in Fig. 7.

HSV-1 strain Ska grown in the brain was first detected on day 2; its titer became maximum on day 6 and undetectable on day 14 p.i. These results were well matched with the results of viral antigen distribution in the brain assessed by immunofluorescence. After the challenge virus inoculation,



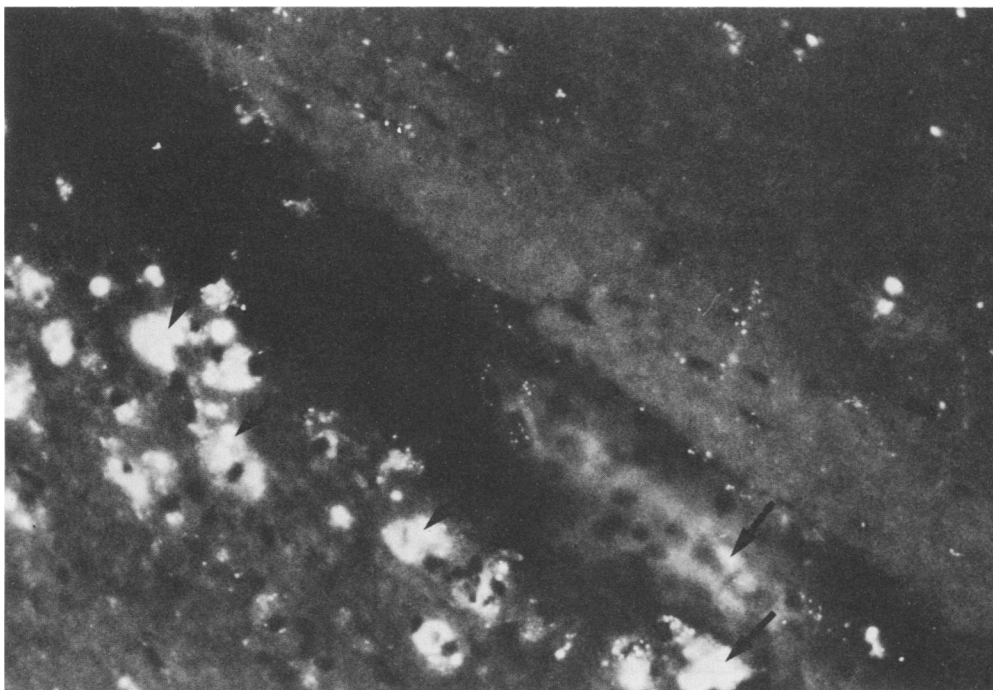


FIG. 5. Immunofluorescence of the HSV-1 antigen seen in ependymal area 6 days after IC inoculation of HSV-1 strain Ska. Arrows indicate the specific fluorescence of the HSV antigen.

neither strain Ska nor CHR-3 was titrated in the brain. Although no replication of infectious strain Ska or CHR-3 was demonstrated after secondary IC inoculation, positive fluorescence was seen in occasional ependymal and subependymal cells as described above. This fluorescence faded over the subsequent 3 to 4 days without noticeable involvement of an additional number of cells.

Serum neutralization antibody was first detected at 6 days post-primary infection and persisted with gradual increases of its activity up to 1:512 at 14 days p.i. when 50% reduction of the virus plaques from the control was taken as an endpoint. After challenge virus inoculation, the antibody

titer was boosted precipitously and reached a maximum over 1:2,000 at 8 days post-secondary virus inoculation.

CSF free from contamination of the blood was obtained from the hydrocephalic brains. It contained a high titer of antiviral activity, although the class of immunoglobulin in the CSF was not determined because of the limited volume of the sample obtained for further analyses.

**Inability to induce hydrocephalus in immunosuppressed mice and athymic BALB/c nude mice.** To determine whether the immunopathological process was involved in the development of hydrocephalus, BALB/c mice were immunosuppressed by the administration of CY. They were weighed and CY (100 mg/kg of body weight) was given intraperitoneally as described above.

Mice that were treated with CY at the secondary virus inoculation did not develop hydrocephalus (Table 2). On the other hand, when the mice received CY at the primary virus inoculation and were not immunosuppressed at the secondary virus inoculation, they developed hydrocephalus, as did the untreated mice.

When BALB/c nude mice were inoculated IC with strain Ska and subsequently challenged IC with the same virus or strain CHR-3, they did not develop hydrocephalus (Table 3). All BALB/c nude mice that received IC the initially virulent strain CHR-3 died before it was time for them to receive the secondary virus inoculation.

These data strongly suggest the involvement of T-cell-mediated immunopathology in the development of hydrocephalus.

**Hydrocephalus induced after adoptive transfer of immune spleen cells.** We next designed the adoptive transfer experiment to determine whether these processes could be transferred to the irradiated syngeneic mice by immune spleen cells. We also tried to define more precisely the T-cell subset of these processes by using monoclonal anti-T-cell subset antibodies.

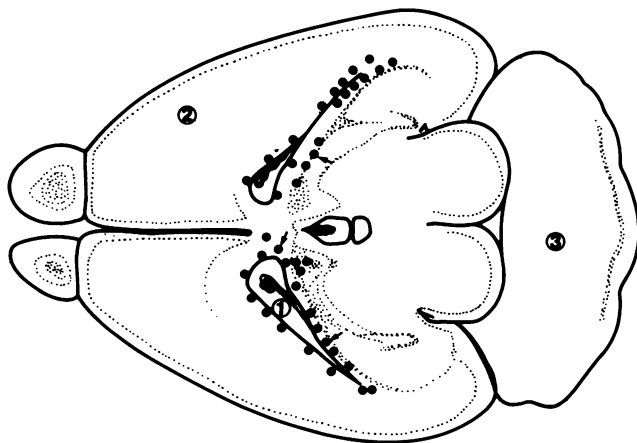


FIG. 6. Viral antigen localization 6 days after the primary IC inoculation of HSV-1 strain Ska. Closed circles indicate localization of HSV-1 antigen studied by direct immunofluorescence test 6 days after the primary IC inoculation of HSV-1 strain Ska. 1, Lateral ventricle; 2, cerebral cortex; 3, cerebellum.

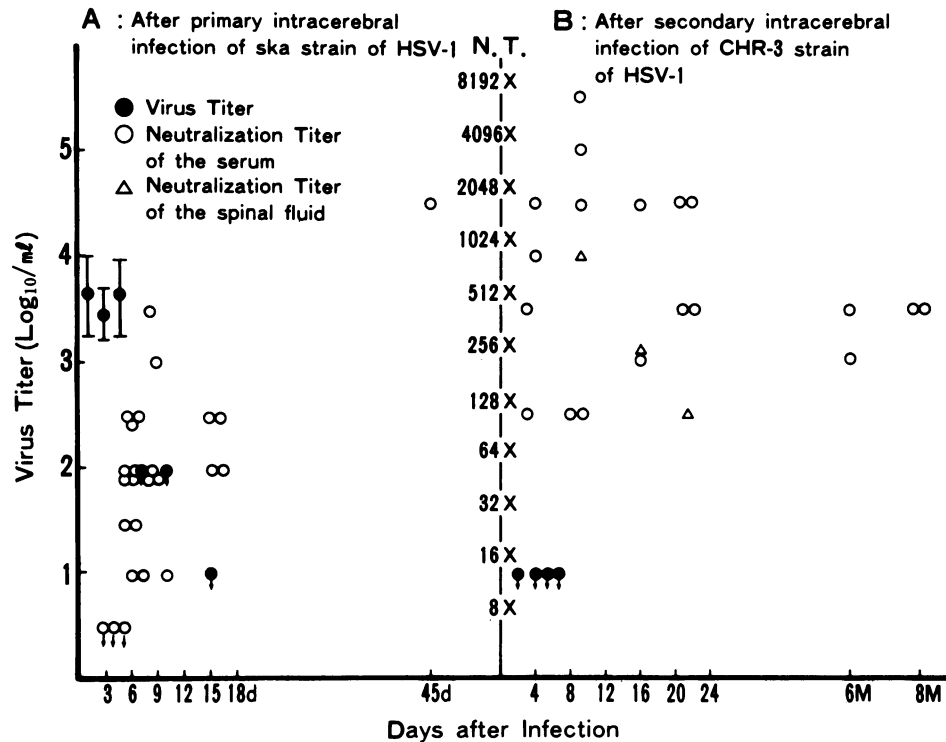


FIG. 7. Kinetics of the virus growth in the brain and the development of antibody activities in the serum and spinal fluid. Mice were sacrificed at set times after virus inoculation and brains were removed aseptically. They were homogenized to make a final 10% (wt/vol) emulsion. Virus titers were determined by plaque assay on GMK cells. Serum and spinal fluid were obtained from the mice, and neutralization titers were determined by the reciprocal highest dilution of them for the 50% reduction of viral plaques from the control. Symbols: ●, virus titer per gram of tissue weight; ○, neutralization titer in serum; △, neutralization titer in spinal fluid; †, less than the value indicated by the closed circle. d, day; M, month.

Four groups of BALB/c mice were inoculated IC with strain Ska 2 weeks earlier and irradiated with 400 rads, as described above. They then received an i.v. injection of  $1.5 \times 10^8$  whole immune spleen cells or immune spleen cells treated with either anti-immunoglobulin plus complement or anti-Thy-1.2 antibody plus complement.

One group of mice which had been administered i.v. normal spleen cells served as a control. They were challenged IC with 0.025 ml of strain Ska after the cell transfer. Recipient mice were sacrificed on day 14 after the cell transfer and secondary virus inoculation. During this period, mice did not develop any clinical manifestations of the illness. When the cranial cavities of these mice were opened, hydrocephali had developed in the group of mice that received whole immune spleen cells and those treated with anti-immunoglobulin plus complement, whereas the majority of the mice that were administered cells that were treated with anti-Thy-1.2 antibody plus complement did not show

hydrocephali, although some of the animals showed slight hydrocephalic changes in their brains (Table 4).

On the contrary, no hydrocephalic mice were observed when mice were administered normal syngeneic spleen cells. Histopathological examination of the hydrocephalic brains showed subarachnoidal and subependymal infiltrations of mononuclear cells and lymphocytes. Patchy destruction and detachment of ependymal cells was noted. As described above, these pathological features were similar to those seen in the hydrocephalic brains induced after repeated IC inoculation of strain Ska.

These features indicate strongly that the inflammatory reactions elicited after secondary virus challenge were more severe than those that were seen after primary virus infection. The inflammation occurred after the secondary virus challenge was mediated by immune T lymphocytes, thus resulting in obstructive hydrocephalus in these mice.

TABLE 2. Effect of CY treatment

Treatment <sup>a</sup>	Virus inoculated IC	No. of mice with the following grades of hydrocephalus:			
		++	+	±	-
Cy	Ska/CHR-3 (CY)	0	0	2	8
	Ska (CY)/CHR-3	4	0	0	0
None	Ska/CHR-3	6	2	0	0

<sup>a</sup> Mice were immunosuppressed by daily intraperitoneal inoculation of CY (100 mg/kg of body weight) to a total of 300 mg/kg of body weight. After virus inoculation, additional CY was given twice every other day.

TABLE 3. Effect of IC inoculation of strain Ska in nude mice<sup>a</sup>

Mouse strain	Virus inoculated IC	No. of mice with the following grades of hydrocephalus:			
		++	+	±	-
BALB/c nu/nu	Ska/Ska	0	0	3	5
	Ska/CHR-3	— <sup>b</sup>	—	—	—
BALB/c nu/+	Ska/Ska	7	2	1	0
	Ska/CHR-3	8	2	1	0

<sup>a</sup> BALB/c nude mice were inoculated IC with strain Ska and subsequently challenged IC with the same virus or strain CHR-3.

<sup>b</sup> —, All mice died after inoculation with strain CHR-3.

TABLE 4. Hydrocephalus-induced adoptive transfer of immune spleen cells<sup>a</sup>

Group	Virus inoculated IC	Donor cell	Treatment	No. of mice with the following grades of hydrocephalus:			
				++	+	±	-
1	Ska/Ska	Immune spleen cells	None	0	6	4	0
2	Ska/Ska	Immune spleen cells	Anti-immunoglobulin + complement	4	3	4	1
3	Ska/Ska	Immune spleen cells	Anti-Thy-1.2 + complement	0	4	2	6
4	Ska/Ska	Normal spleen cells	None	0	0	0	8

<sup>a</sup> Two weeks after IC inoculation of strain Ska, BALB/c mice were irradiated with 400 rads with a Shimazu model SHT 250M-3 X-ray generator (Kyoto, Japan). They were administered  $1.5 \times 10^8$  immune spleen cells which had been treated with either anti-Thy-1.2 antibody plus complement or normal spleen cells via the tail vein. Two hours after adoptive transfer of the cells, recipient mice were inoculated IC with strain Ska. Two weeks after cell transfer, the mice were sacrificed and the brains were scored for hydrocephalus.

To determine whether these changes were mediated by Lyt-1<sup>+</sup>.2<sup>+</sup>-bearing T cells or the Lyt-2<sup>+</sup>.3<sup>+</sup>-bearing T cell subset, further transfer experiments were performed with BALB/c nude mice as recipients.

As described previously, nude mice did not develop hydrocephalus even after repeated challenge of strain Ska.

When these mice were administered syngeneic immune spleen cells which were depleted of Lyt-2<sup>+</sup>.3<sup>+</sup> cells by treatment with anti-Lyt-2.2 antibody plus complement, they developed hydrocephalus, whereas recipient mice that were administered Lyt-1<sup>+</sup>.2<sup>+</sup> cell-depleted immune spleen cells did not develop hydrocephalus appreciably (Table 5).

Thus, we conclude that the inflammatory processes that lead to the final hydrocephalic pathology are dependent on the recruitment of the immune Lyt 1<sup>+</sup>.2<sup>+</sup>-bearing T-cell subsets into the crucial loci.

**Antigenic requirements for the development of hydrocephalus.** We next studied the antigenic requirement for the induction of the pathological changes.

Mice that were primed IC with strain Ska and then challenged with UV-inactivated virus or the purified envelope protein of HSV-1 elicited inflammatory reactions at the local site and developed hydrocephalus (Table 6). On the other hand, those mice that were inoculated with bovine serum albumin in place of UV-inactivated virus or the virus envelope protein did not develop hydrocephalus.

In the next step, serum obtained from the hydrocephalic mouse was analyzed by the Western blotting (immunoblotting) method (Fig. 8). It was shown that the serum obtained from a hydrocephalic mouse which had been treated by regular, repeated IC virus inoculations of the Ska strain showed two bands at an approximate molecular weight of 130,000 (130K), a broad band at 65K to 83K and sharp bands at 58K, 48K, and 40K (Fig. 8, lane 2). The serum had weak cross-reactivity to HSV-2 antigen (Fig. 8, lane 3).

The neutralizing antibody titer of this serum against

HSV-1 was 1:1,024. Thus, it was suggested that at least some of the antigenic molecules that contributed to the immunopathology of these mice were a constituent of the HSV-1 envelope proteins, capsid proteins, or both.

## DISCUSSION

This paper describes for the first time HSV-1-induced hydrocephalus in experimental animals.

The immunopathological nature of the disease process was analyzed, and we conclude that the Lyt-1<sup>+</sup>.2<sup>+</sup>-bearing T-cell subset that recognized one or more viral envelope proteins was at least partly responsible for this unique pathology.

When the virus was inoculated IC, virus particles were forced back along the needle tract due to the increase of intracranial pressure, thus flooding the entire subarachnoid space, the perivascular spaces, the ventricles, and the central canal of the spinal cord (12, 19). Accordingly, viral antigen localization after the initial virus inoculation was primarily on the meninges, choroid plexus, and ependymal lining cells, which was followed by the spread to the ventricular walls and subependymal parenchyma. This initial distribution of the virus determined the patterns of the subsequent pathological changes, because avirulent strain Ska did not spread widely to the underlying brain cell populations, although multiple cycles of infectious virus production occurred. This localization of infection was similar but wider than those of the mumps, parainfluenza, and influenza virus infections, which shows the selective vulnerability of ependymal cells for the virus multiplications (10, 13, 14).

Our findings show that Lyt-1<sup>+</sup>.2<sup>+</sup>-bearing T cells are the main effector for the pathological changes.

It is known that in CNS inflammatory processes, CSF, meningeal exudate, parenchymal infiltrate, and perivascular cuffing are different in each cell population (20). Thus, it is conceivable that on secondary virus inoculation, antigen-

TABLE 5. Hydrocephalus induced in nude mice after transfer of immune T-cell subsets<sup>a</sup>

Group	Donor cell	Treatment	No. of mice with the following grades of hydrocephalus:			
			++	+	±	-
1	Immune spleen cells	None	1	6	1	0
2	Immune spleen cells	Anti-Lyt-1.2 + complement	0	0	2	3
3	Immune spleen cells	Anti-Lyt-2.2 + complement	2	2	1	1
4	Immune spleen cells	Anti-Thy-1.2 + complement	0	0	0	3
5	None	None	0	0	1	5

<sup>a</sup> BALB/c nude mice that were infected IC with strain Ska 2 weeks earlier were administered i.v. syngeneic immune T cells that were treated with either monoclonal anti-Lyt-1.2 or anti-Lyt-2.2 antibody plus complement. They were then challenged IC with strain Ska. Two weeks after cell transfer, they were sacrificed and observed for hydrocephalus.



TABLE 6. Effect of UV-inactivated virus and virus envelope protein<sup>a</sup>

Virus inoculated IC	No. of mice with the following grades of hydrocephalus:			
	++	+	±	-
Ska/UV-inactivated CHR-3	2	1	4	3
Ska/envelope protein (70 µg/ml)	6	1	2	4
Ska/envelope protein (20 µg/ml)	4	3	4	0
Ska/bovine serum albumin	0	1	3	4

<sup>a</sup> ICR/Sic mice were inoculated IC with strain Ska. Two weeks after the initial virus inoculation, the mice were challenged with either UV-inactivated virus or purified envelope protein IC (3). Two weeks after the challenge inoculation, the mice were examined for the development of pathological effects.

specific Lyt-1<sup>+</sup>.2<sup>+</sup>-bearing cells proliferated locally or recruited from the circulation because they recognized virally sensitized target cells resulted in granular ependymitis, choroiditis, and meningeal cell exudation, accompanied by subependymal inflammation, and finally in the obstructive hydrocephalus (11, 13). However, it might also be possible that these cells recognized the modified host components and reacted with them to produce true autoimmunity. Further analyses are now under way to elucidate these problems. HSV-1 antigen was not detected in mouse brains at the

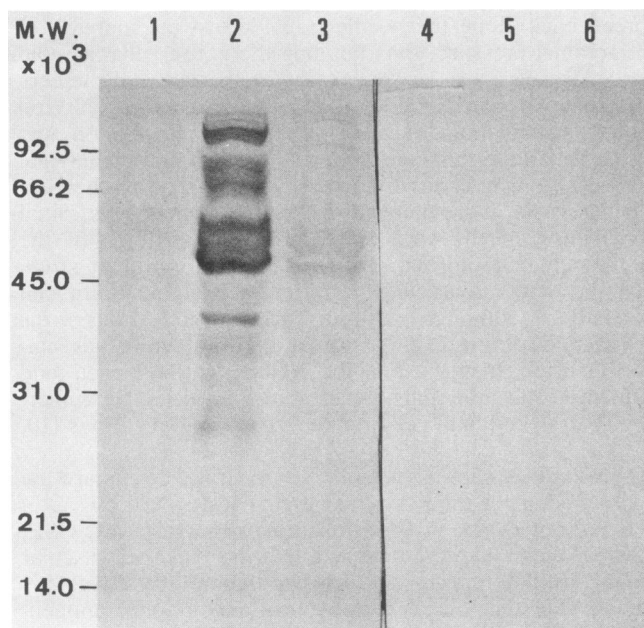


FIG. 8. Immunoblotting analysis of the serum obtained from the hydrocephalic mouse. Lysate of HSV-1 (MacIntyre strain) and HSV-2- (strain uw268) infected HEP-2 cells or uninfected HEP-2 cells were electrophoresed in a sodium dodecyl sulfate-polyacrylamide slab gel. The polypeptides were then transferred to a nitrocellulose sheet, and it was incubated with the appropriately diluted serum for 1 h at 37°C. It was then reacted with peroxidase-conjugated anti-mouse IgG antibody. The color was developed with diaminobenzidine. Antigen was included in lanes 1 and 4, lysate of uninfected HEP-2 cells; lanes 2 and 5, lysate of HSV-1 (MacIntyre strain) infected HEP-2 cells; and lanes 3 and 6, lysate of HSV-2 (strain uw268) infected HEP-2 cells. Antibody was included in lanes 1, 2, and 3, serum obtained from a hydrocephalic mouse 14 days after secondary IC inoculation with strain Ska; and lanes 4, 5, and 6, normal mouse serum. MW, Molecular weight.

secondary virus challenge. Apparently, the histopathological changes progressed without virus replication or the persistence of viral antigens. Similar progressive pathological changes occurred in mice inoculated with the white matter in the parainfluenza type 1 virus or UV-inactivated virus (10).

These results are consistent with results of this study and may also exclude the possibility of the toxic effect of the virus as being a mechanism of tissue degeneration, since inactivation of the virus usually abolishes its toxicity (2).

Occasional immune complex was seen in some of the hydrocephalic mice and in a prolonged case of herpes encephalitis in a human brain (8; Hayashi et al., in press). The immune complex might attract inflammatory cells around it; however, the pathognomonic significance of it is not clear at present, since hydrocephalus was produced in mice by adoptive transfer of immune T cells, and in these cases the immune complex was not detected even in hydrocephalic brains.

The clinical implications of our results are as follows. Hydrocephalic mice did not show any clinical abnormalities. Once the mice were sensitized locally, the effect was observed for almost their entire lives, and immunopathological changes were produced on encounter with another antigenic stimulation. HSV-1 reactivation, which is frequently seen around oral mucosa or lips, might also occur in the CNS; and not only recurrent encephalitis (15, 18) but also inapparent pathology might be elicited without any noticeable clinical signs. If this is the case, typical acute necrotizing encephalitis with a short duration is only a very small part of the entire disease entity of herpes encephalitis (4, 21).

In CNS there are a number of chronic degenerative diseases with unknown etiology such as normotensive hydrocephalus, multiple sclerosis, congenital hydrocephalus, etc. Whether some of these diseases might be etiologically related to HSV-1 infection or a similar immunopathological background must be studied in the future.

#### ACKNOWLEDGMENTS

We thank Kamesaburo Yoshino for continued encouragement and advice during this study. We are also indebted to Phillip Danielson for reviewing the manuscript.

This work was supported in part by a grant-in-aid from The Vehicle Racing Commemorative Foundation.

#### LITERATURE CITED

- Ahdab-Barmada, M., J. Moosy, O. T. Preble, and J. S. Younger. 1982. Hydrocephalus in weaning mice induced by a temperature-sensitive mutant of vesicular stomatitis virus. *J. Neuropathol. Exp. Neurol.* **41**:606-617.
- Burnet, F. M. 1962. Principles of animal virology, 2nd ed., p. 195-200. Academic Press, Inc., New York.
- Cappel, R. 1976. Comparison of the humoral and cellular immune responses after immunization with live, UV-inactivated herpes simplex virus and subunit vaccine and efficacy of these immunizations. *Arch. Virol.* **52**:29-35.
- Cleobury, J. F., G. R. B. Skinner, M. E. Thonless, and P. Wildy. 1971. Association between psychopathic disorder and serum antibody to herpes simplex virus (type 1). *Br. Med. J.* **1**:438-439.
- Hamper, B., A. L. Notkins, M. Mage, and M. A. Keehn. 1968. Heterogeneity in the properties of 7S and 19S rabbit-neutralizing antibodies to herpes simplex virus. *J. Immunol.* **100**:586-593.
- Hanshaw, J. E. 1970. Idoxuridine in herpes virus encephalitis. *N. Engl. J. Med.* **47**:282.
- Hayashi, K., and F. Shimizu. 1982. IV. Substrate preparation. V. Staining procedures, p. 32-74. *In* A. Kawamura and Y.

- Aoyama (ed.), Immunofluorescence in medical science. University of Tokyo Press, Tokyo, Japan.
8. Hayashi, K., S. Takagi, N. Sekine, and I. Kurihara. 1983. Clinical and experimental study of the immune complex (herpes simplex virus type 1-IgM) in herpes encephalitis patient's brain. *Ann. N.Y. Acad. Sci.* **420**:147-158.
  9. Holz, A., G. Borman, and C. P. Li. 1966. Hydrocephalus in mice infected with polyoma virus. *Proc. Soc. Exp. Biol. Med.* **121**:1196-1200.
  10. Iwasaki, Y., J. McMichael, and H. Koprowski. 1975. Experimental parainfluenza type 1 virus-induced encephalopathy in adult mouse. *Acta Neuropathol.* **31**:315-324.
  11. Johnson, K. P., and R. T. Johnson. 1972. Granular ependymitis: occurrence in myxovirus infected rodents and prevalence in man. *Am. J. Pathol.* **67**:511-526.
  12. Johnson, R. T. 1982. Pathogenesis of CNS infections, p. 37-60. *In* R. T. Johnson (ed.), *Viral infections of the nervous system*. Raven Press, New York.
  13. Johnson, R. T., and K. P. Johnson. 1968. Hydrocephalus following viral infection: the pathology of aqueductal stenosis developing after experimental mumps virus infection. *J. Neuropathol. Exp. Neurol.* **27**:591-606.
  14. Johnson, R. T., and K. P. Johnson. 1969. Hydrocephalus as a sequela of experimental myxovirus infections. *Exp. Mol. Pathol.* **10**:68-80.
  - 14a. Klüver, H., and E. Barrera. 1953. A method for the combined staining of cells and fibers in the nervous system. *J. Neuropathol. Exp. Neurol.* **12**:400-403.
  15. Koenig, H., S. G. Rabinowitz, E. Day, and V. Miller. 1979. Post-infectious encephalitis after successful treatment of herpes simplex encephalitis with adenosine arabinoside: ultrastructural observations. *N. Engl. J. Med.* **300**:1089-1093.
  16. Laemmli, U. K. 1970. Cleavage of structural proteins during the assembly of the head of bacteriophage T4. *Nature (London)* **227**:680-685.
  17. Margolis, G., and L. Kilham. 1969. Hydrocephalus in hamsters, ferrets, rats and mice following inoculations with reovirus type 1. II. Pathologic studies. *Lab. Invest.* **21**:189-198.
  18. Milstein, J. M., and H. E. Biggs. 1977. Recurrent encephalitis with elevated titers for herpes simplex. *Arch. Neurol.* **34**:434-436.
  19. Mims, C. A. 1960. Intracerebral injections and the growth of viruses in the mouse brain. *Br. J. Exp. Pathol.* **41**:52-59.
  20. Moench, T. R., and D. E. Griffin. 1984. Immunocytochemical identification and quantitation of the mononuclear cells in the cerebrospinal fluid, meninges and brain during acute viral meningoencephalitis. *J. Exp. Med.* **159**:77-88.
  21. Shearer, M. L., and S. M. Finch. 1964. Periodic organic psychosis associated with recurrent herpes simplex. *N. Engl. J. Med.* **271**:494-497.
  22. Shimizu, F. 1982. Labelled antibody preparation, p. 17-30. *In* A. Kawamura and Y. Aoyama (ed.), *Immunofluorescence in medical science*. University of Tokyo Press, Tokyo, Japan.
  23. Towbin, H., T. Staehelin, and J. Gordon. 1979. Electrophoretic transfer of protein from polyacrylamide gels to nitrocellulose sheets. Procedures and some applications. *Proc. Natl. Acad. Sci. USA* **76**:4350-4354.
  24. Yoshino, K., T. Andoh, M. Hashimoto, and Y. Aoyama. 1976. Absence of correlation between an attenuated strain of type 1 herpes simplex virus and tumors produced in neonatally infected mice. *Jpn. J. Exp. Med.* **46**:139-144.
  25. Yoshino, K., K. Yanagi, and K. Abe. 1982. Efficacy of intradermal administration of herpes simplex virus subunit vaccine. *Microbiol. Immunol.* **26**:753-757.