

## Monoclonal Antibodies against the Fusion Protein Are Protective in Necrotizing Mumps Meningoencephalitis

ARTHUR LÖVE,<sup>1\*</sup> ROBERT RYDBECK,<sup>1</sup> GÖRAN UTTER,<sup>1</sup> CLAES ÖRVELL,<sup>1</sup> KRISTER KRISTENSSON,<sup>2</sup> AND ERLING NORRBY<sup>1</sup>

*Department of Virology, Karolinska Institute, c/o SBL, S-105 21 Stockholm,<sup>1</sup> and Department of Pathology, Division of Neuropathology, Karolinska Institute, Huddinge Hospital, S-141 86 Huddinge,<sup>2</sup> Sweden*

Received 15 October 1985/Accepted 26 December 1985

**A monoclonal antibody against the fusion (F) protein of mumps virus was found to confer marked protection in mumps virus-induced encephalitis. Almost total prevention of extensive brain necrosis was found. This study indicates that the virus F protein is directly involved in the pathogenesis of brain necrosis.**

Monoclonal antibodies to specific antigenic sites on viral surface proteins can identify immunogenic parts of proteins essential for protection against infection. Surface proteins of paramyxoviruses are the hemagglutinin-neuraminidase (HN) and fusion (F) proteins. HN is responsible for hemagglutinating and neuraminidase activities and for adsorption of the virus to host cells (2). F is involved in viral penetration of cells by causing fusion between viral envelope and cell membrane (2). Monoclonal antibodies to certain sites on the hemagglutinin glycoprotein of paramyxoviruses are neutralizing *in vitro* and protective *in vivo* (11, 12, 19). Also, treatment with anti-H monoclonal antibodies can induce a subacute persistent state of viral infection of the brain (15). In pulmonary infection with Sendai virus, both anti-HN and anti-F monoclonal antibodies significantly reduce viral titers (12). In a recent extensive study on protection against mumps meningoencephalitis with monoclonal antibodies, no anti-F antibody clones conferred biologically important protection (19). The present study, however, demonstrates that a monoclonal antibody against the F protein can be highly protective in necrotizing mumps meningoencephalitis.

Two recently described antibody clones directed against different sites of the F protein were tested (11). Monoclonal antibody 5418 had hemolysis inhibition activity, but the other one, 2159, did not. Antibody 5418 was of immunoglobulin G subclass 2a, and 2159 was immunoglobulin G subclass 1. Neither had neutralizing effects *in vitro*. The antibodies were determined to be directed against the F protein, and their specificity was verified by radioimmunoprecipitation assay (11). F(ab')<sub>2</sub> fragments of antibody 5418 were generated by trypsin digestion (14). The protein content of the (F(ab')<sub>2</sub>) material was determined to be 0.3 mg/ml, and its purity was assessed by 10% sodium dodecyl sulfate-polyacrylamide gel electrophoresis. Two derivatives of the Kilham mumps virus strain were tested (A. Löve, R. Rydbeck, Å. Ljungdahl, K. Kristensson, and E. Norrby, *Microb. Pathogenesis*, in press). These variants are designated RK and SK and have a high and a low capacity of cell fusion in Vero cells, respectively. Both variants react strongly with the antibodies in radioimmunoprecipitation and immunofluorescence assays, and both are lethal when injected intracerebrally into newborn hamsters. For animal experiments, newborn (less than 24 h old) golden Syrian hamsters were inoculated intracranially with 0.03 ml of virus material with a titer of  $5 \times 10^6$  PFU per ml. Simultaneously,

the hamsters were treated subcutaneously with 0.04 ml of antibody ascites or F(ab')<sub>2</sub> fragment material. Control animals were either untreated or treated with monoclonal antibody ascites against the nucleocapsid protein (NP) of mumps virus. Every other day postinfection (p.i.), four or five newborn hamsters were randomly picked and sacrificed, and their brains were processed for viral titration (7, 18). Survival was recorded by daily census (6). Histological preparations from animals treated with antibody 5418 and from nontreated controls were processed as previously described (4). Distribution of viral antigen was determined by use of the immunoperoxidase method (17).

Survival of the infected newborn hamsters was prolonged by treatment with both anti-F antibodies (Fig. 1). Antibody 5418 had a much greater protective effect than 2159. All infected animals treated with antibody 5418 died of obstructive hydrocephalus about 20 days after infection (3). Reduction of viral titers in the hamster brains was found only after

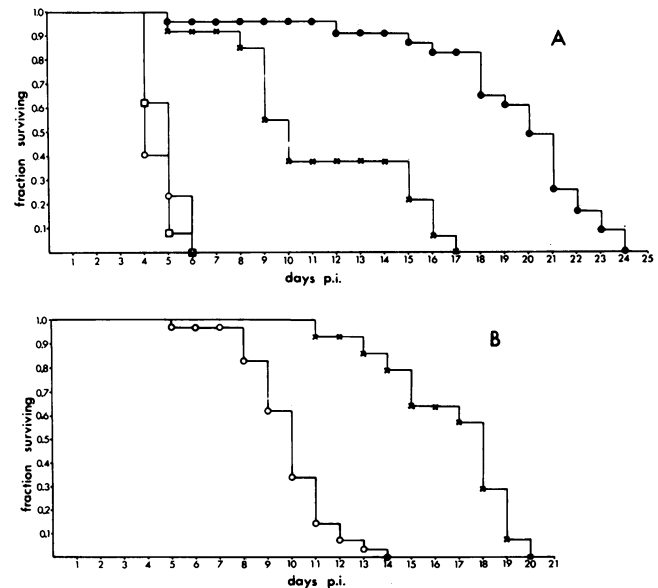


FIG. 1. (A) Survival curves for RK virus-infected animals. Symbols: Nontreated (○); treated with monoclonal antibodies 5418 (●) or 2159 (×) or with F(ab')<sub>2</sub> fragments of antibody 5418 (□). (B) Survival curves for SK virus-infected animals. Symbols: Nontreated (○); treated with monoclonal antibody 5418 (×). Each group of infected animals consisted of 20 to 30 animals except for the one treated with the F(ab')<sub>2</sub> fragments, which comprised 13 animals.

\* Corresponding author.

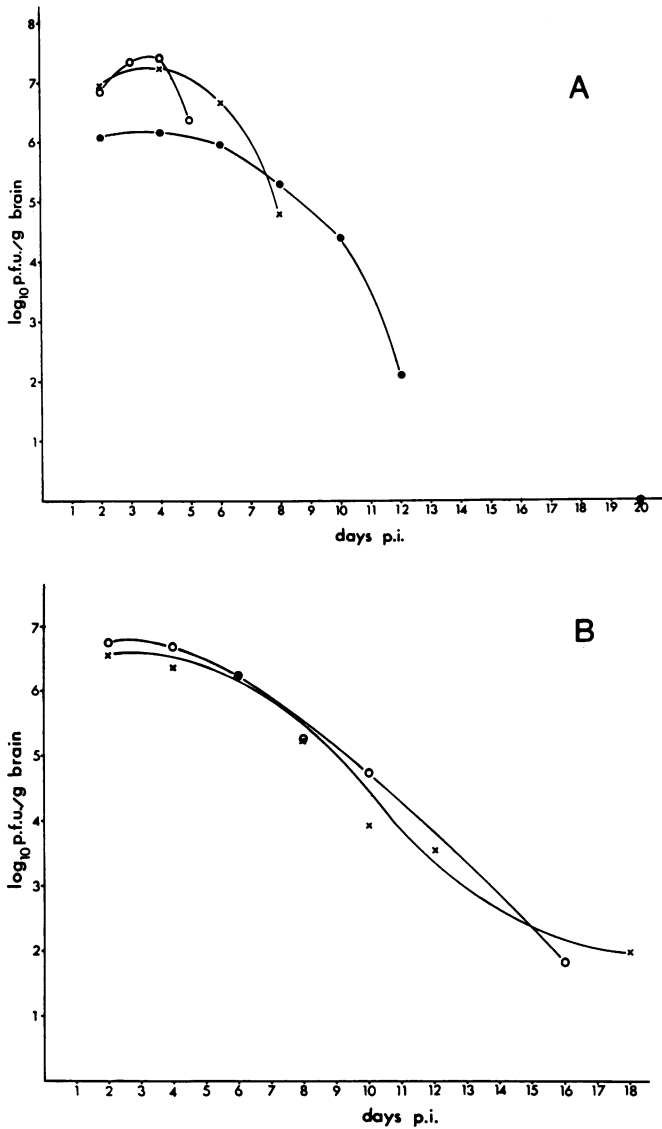


FIG. 2. (A) Titration curves from RK virus-infected brains. Symbols: Nontreated (0); treated with monoclonal antibodies 5418 (●) and 2159 (×). (B) Titration curves from SK virus-infected brains. Symbols: Nontreated (0); treated with monoclonal antibody 5418 (×). All data points are average titers from four or five brains, randomly picked from several litters except for the SK-infected, nontreated sample at 16 days p.i., which is from a single survivor.

treatment with antibody 5418, using the highly fusing RK variant for infection (Fig. 2). Treatment with F(ab')<sub>2</sub> fragments of antibody 5418 conferred no protection (Fig. 1A). Histologically, the RK strain caused extensive necrosis of almost the whole cerebral cortex within 4 days p.i. (Fig. 3A). Necrotic neurons also occurred in the hippocampus, caudate nucleus, and brainstem. After treatment with the 5418 anti-F antibody, virtually no necrosis was seen at all (Fig. 3B). At 8 days p.i., infiltration of mononuclear inflammatory cells was prominent in the leptomeninges and perivascularly in the brain. Hydrocephalus had started to develop, but neuronal necrosis was minimal. Large amounts of virus antigen were present in neurons in both treated and untreated animals (Fig. 3C). Only minimal histological changes were seen after infection with the SK variant, and viral

antigen occurred in neurons to a similar extent in both treated and nontreated animals.

Significant protection can, thus, be obtained in mumps encephalitis after passive administration of monoclonal an-

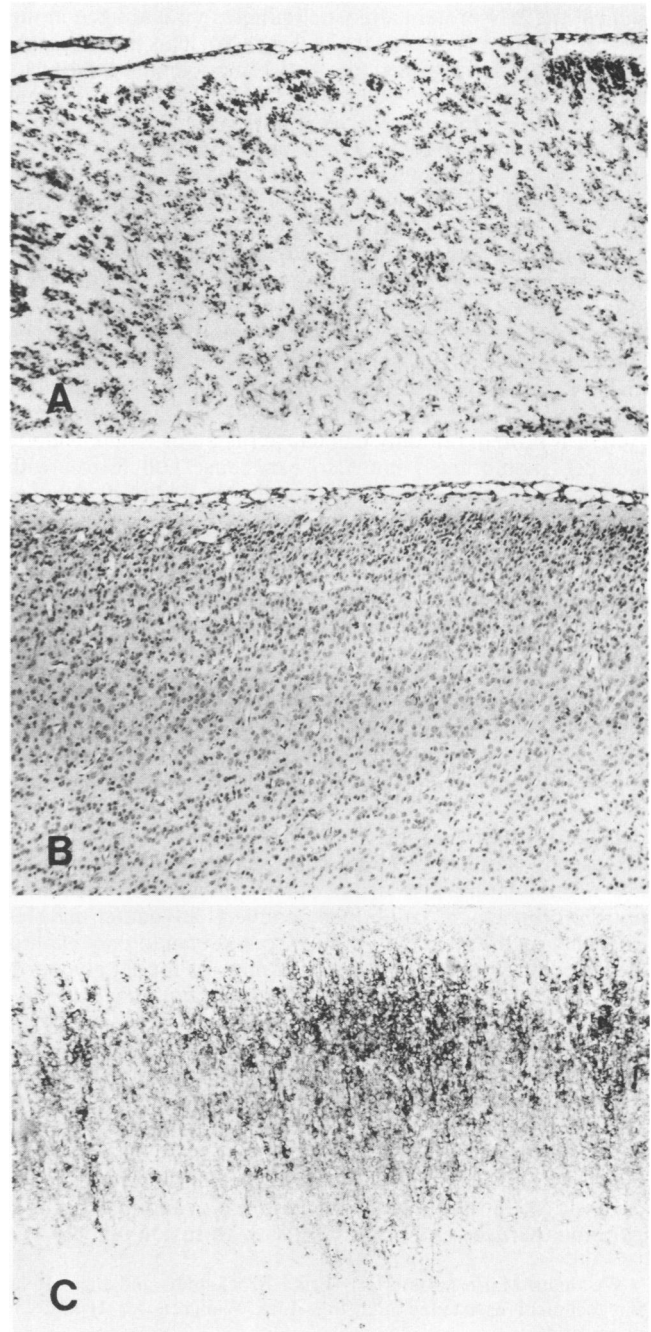


FIG. 3. (A) Totally necrotic cerebral cortex 4 days p.i. with the RK mumps virus variant. After treatment with anti-F antibody 5418, the cortex is well preserved (B) in spite of the fact that large amounts of viral antigen are present in a parallel section (C). Groups of six to eight treated or untreated hamsters infected with either the RK or SK variant were examined 4 days p.i. At 8 days p.i., similar size groups of survivors were taken. Paraffin-embedded sections were stained with hematoxylin-eosin for histology and incubated with polyclonal mumps antiserum for the immunoperoxidase method to detect viral antigen. Magnification, ×100.

tibodies directed against certain sites of the F protein of mumps virus. The different degrees of protection obtained with the two monoclonal antibodies show that the antigenic site against which the antibodies are directed is of considerable importance.

Treatment with neutralizing monoclonal antibodies against the HN protein almost eliminates viral antigen in the brain and protects against the disease (19). This is in contrast to the present situation where anti-F monoclonal antibodies protected against the disease but large amounts of viral antigen were still present in the tissue. Nonneutralizing anti-F antibodies may inactivate viral spread and growth in the brain by complement-dependent or antibody-dependent cell-mediated lysis of virions or virus-infected cells (16). The lack of effect of F(ab')<sub>2</sub> fragments would then suggest an important role of the Fc antibody fragment (5). However, the viral titers were not reduced below levels which in previous studies have been associated with brain necrosis (7), and in the present study, areas with large amounts of viral antigen showed only minimal cell damage in antibody-treated animals. F protein may directly be involved in cytotoxicity, as F antibodies to specific sites inhibited the tissue destruction. Active F protein not only can cause fusion of viral envelope and cell membranes, but also can cause cell fusion with formation of multinuclear giant cells. In addition, concentrated virions may cause damage to erythrocyte membrane with consequent hemolysis (10), which can be prevented by anti-F antibodies. F protein may therefore cause membrane damage and also lysis of neurons. This may be accomplished by active F protein on neuronal cell surfaces attacking surrounding cells, by a high concentration of virions in the tissue, and by F-containing membrane fragments released from lysed cells. These mechanisms may explain the rapid and complete tissue destruction presently observed. This hypothesis is also supported by the finding that the low-fusion-capacity strain (SK) caused only minimal neuronal necrosis.

Data on the alteration of the pathogenesis of viral brain disease by monoclonal antibodies against surface proteins are accumulating also from other studies. For instance, anti-H monoclonal antibodies convert an acute measles encephalopathy in BALB/c mice to a subacute encephalitis (15), and antibodies to distinct epitopes of the E<sub>2</sub> glycoprotein of mouse hepatitis virus convert a fatal encephalomyelitis to a demyelinating disease in mice (1). Considering the results of the present study, it is therefore apparent that the balance between the antibody specificities in polyclonal sera can be of crucial importance for both the course of disease and tissue reaction (13). This study highlights the F protein as a prominent pathogenetic determinant (8, 9). The relevance of F antigen has to be strongly considered in development of conventional or subunit vaccines against paramyxoviruses and other viruses with fusion activity.

We thank Marie Mannerlöf, Ulrika Brockstedt, and Inger Rehn for technical assistance and Inga-Lisa Wallgren for typing the manuscript.

This project was supported by grants from the Swedish Medical Research Council (grants B85-16X-00116-21B and B85-12X-04480-11B).

#### LITERATURE CITED

1. Buchmeier, M. J., H. A. Lewicki, P. J. Talbot, and R. L. Knobler. 1984. Murine hepatitis virus-4 (strain JHM)-induced neurologic disease is modulated in vivo by monoclonal antibody. *Virology* **132**:261-270.
2. Choppin, P. W., and A. Scheid. 1980. The role of viral glycoproteins in adsorption, penetration and pathogenicity of viruses. *Rev. Infect. Dis.* **2**:40-61.
3. Johnson, R. T., and K. P. Johnson. 1968. Hydrocephalus following viral infections: the pathology of aqueductal stenosis developing after experimental mumps virus infection. *J. Neuropathol. Exp. Neurol.* **27**:591-606.
4. Kristensson, K., J. Leestma, B. Lundh, and E. Norrby. 1984. Sendai virus infection in the mouse brain: virus spread and long-term effects. *Acta Neuropathol. (Berl.)* **63**:89-95.
5. Lefrançois, L. 1984. Protection against lethal viral infection by neutralizing and nonneutralizing monoclonal antibodies: distinct mechanisms of action in vivo. *J. Virol.* **51**:208-214.
6. Liddell, F. D. K. 1978. Evaluation of survival in challenge experiments. *Microbiol. Rev.* **42**:237-249.
7. Löve, A., R. Rydbeck, K. Kristensson, C. Örvell, and E. Norrby. 1985. Hemagglutinin-neuraminidase glycoprotein as a determinant of pathogenicity in mumps virus hamster encephalitis: analysis of mutants selected with monoclonal antibodies. *J. Virol.* **53**:67-74.
8. McCarthy, M., B. Jubelt, D. Fay, and R. T. Johnson. 1980. Comparative studies of five strains of mumps virus in vitro and in neonatal hamsters: evaluation of growth, cytopathogenicity, and neurovirulence. *J. Med. Virol.* **5**:1-5.
9. Merz, D. C., and J. S. Wolinsky. 1983. Conversion of nonfusing mumps virus infections to fusing infections by selective proteolysis of the HN glycoprotein. *Virology* **131**:328-340.
10. Norrby, E., and Y. Gollmar. 1975. Identification of measles virus-specific hemolysis-inhibiting antibodies separate from hemagglutination-inhibiting antibodies. *Infect. Immun.* **11**:231-239.
11. Örvell, C. 1984. The reactions of monoclonal antibodies with structural proteins of mumps virus. *J. Immunol.* **132**:2622-2629.
12. Örvell, C., and M. Grandien. 1982. The effects of monoclonal antibodies on biological activities of structural proteins of Sendai virus. *J. Immunol.* **129**:2779-2787.
13. Örvell, C., and E. Norrby. 1985. Antigenic structure of paramyxoviruses, p. 241-264. *In* M. H. V. van Regenmortel and A. R. Neurath (ed.), *Immunochemistry of viruses. The basis for serodiagnosis and vaccines.* Elsevier Science Publishers B.V., Amsterdam.
14. Parham, P. 1983. On the fragmentation of monoclonal IgG1, IgG2a, and IgG2b from BALB/C mice. *J. Immunol.* **131**:2895-2902.
15. Rammohan, K., H. F. McFarland, and D. E. McFarlin. 1981. Induction of subacute murine measles encephalitis by monoclonal antibody to virus haemagglutinin. *Nature (London)* **290**:588-589.
16. Schmaljohn, A. L., E. D. Johnson, J. M. Dalrymple, and C. A. Cole. 1982. Non-neutralizing monoclonal antibodies can prevent lethal alphavirus encephalitis. *Nature (London)* **297**:70-72.
17. Sternberger, L. A. 1979. *Immunocytochemistry.* John Wiley & Sons, Inc., New York.
18. Wolinsky, J. S., and W. G. Stroop. 1978. Virulence and persistence of three prototype strains of mumps virus in newborn hamsters. *Arch. Virol.* **57**:355-359.
19. Wolinsky, J. S., M. N. Waxham, and A. C. Server. 1985. Protective effects of glycoprotein-specific monoclonal antibodies on the course of experimental mumps virus meningoencephalitis. *J. Virol.* **53**:727-734.