

---

# CASE REPORTS

---

## FALSE-POSITIVE THROMBOSCINTIGRAM RESULTING FROM LYMPHEDEMA— A ROENTGEN PATHOLOGICAL MODEL

James D. Collins, MD, Lawrence W. Bassett, MD, Harold D. Snow, DVM, Nancy A. Ross, BA, and Thomas Patin

**Abnormal thromboscintigrams were observed in patients with lymphatic obstruction. This syndrome was reproduced by surgically ligating the lymphatic drainage of the lower extremity of a dog prior to thromboscintigraphy.**

Thromboscintigraphy is a benign screening procedure for thrombophlebitis.<sup>1-4</sup> Thromboscintigraphy (radionuclide-clot localization) depends on particle entrapment (usually technetium labeled macroaggregates of albumin) in areas of fibrin deposition or endothelial damage to diagnose clot formation. On isotope scans, this entrapment re-

sults in localized abnormal accumulations of the isotope. Any factor that interrupts the flow of the radionuclide results in abnormal accumulations of the isotope.

In 1975, the senior author used thromboscintigraphy for bipedal lymphangiogram to establish radionuclide perfusion in dogs.<sup>5</sup> In August 1976, Grollman et al<sup>6</sup> reported that while thromboscintigraphy is highly sensitive for detection of thrombophlebitis, the false-positive results are also high. These false positives have been attributed to several causes including venous stasis, endothelial abnormalities, and cellulitis.<sup>7</sup>

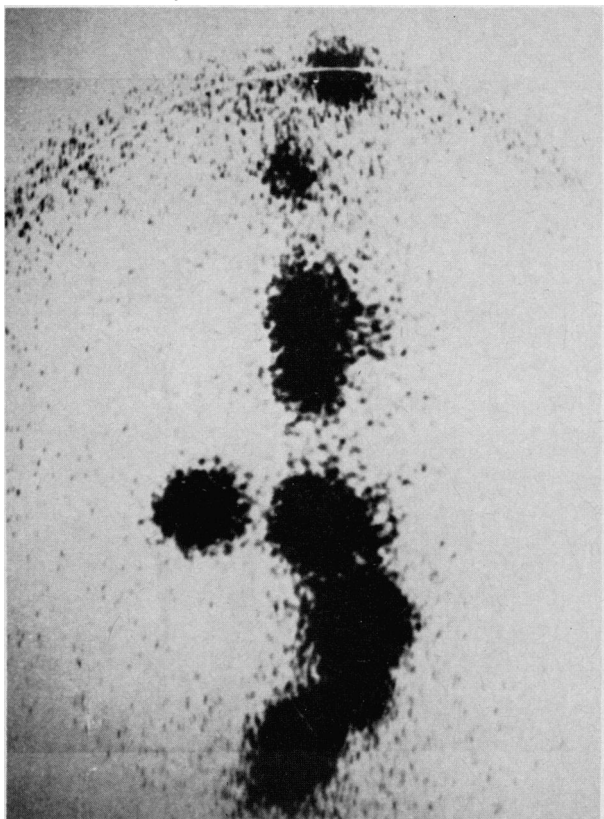
In several cases of lymphedema with lymphangiograms demonstrating obstructions of the lymphatics, false-positive thromboscintigrams were obtained. The venograms were entirely normal. These cases were clinically suspected of having thrombophlebitis involving the legs. The lymphatic abnormalities of lymph stasis, perivascular staining, and dermal back flow were demonstrated on the subsequent lymphangiograms. As the result of this observation, an experiment was designed to

Continued on page 878

---

From the UCLA School of Medicine, Department of Radiology, Los Angeles, California. Presented at the National Medical Association's 86th Annual Convention and Scientific Assembly, July 23, 1981. Requests for reprints should be addressed to Dr. James D. Collins, Department of Radiology, UCLA School of Medicine, Los Angeles, CA 90024.

Continued from page 875



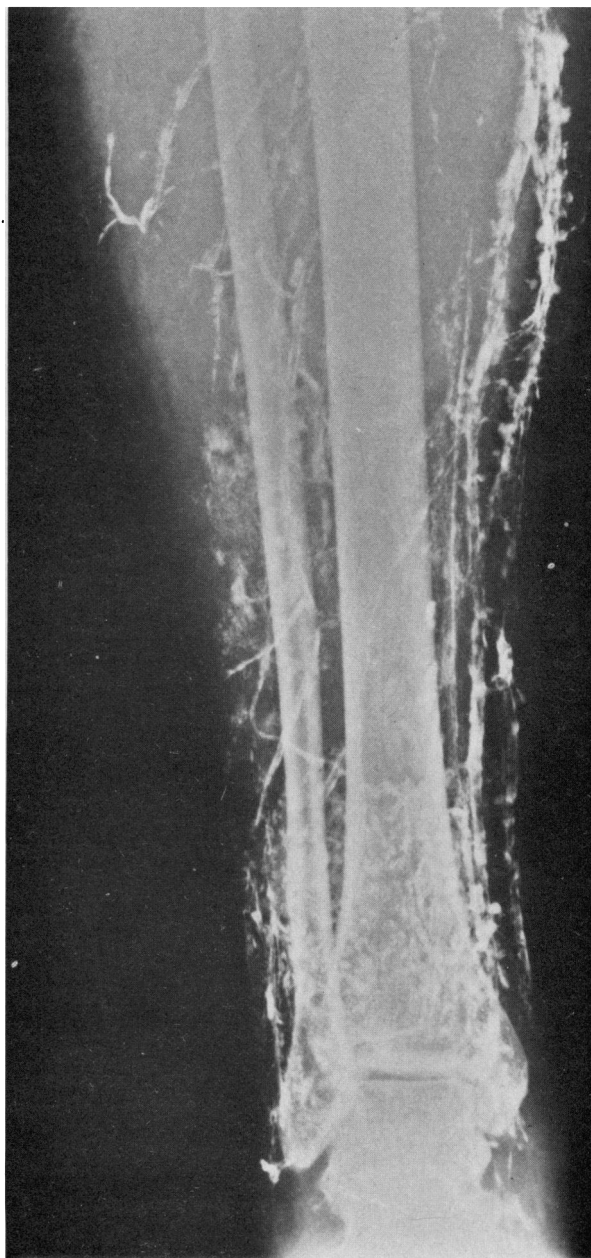
**Figure 1.** A 21-year-old woman with recurrent episodes of right lower extremity swelling. A thromboscintigram performed after injection of technetium 99m labeled macroaggregates of albumin in both feet shows abnormal accumulations of isotope throughout the right lower extremity, indicating possible thrombophlebitis. Venograms were normal

determine if a false-positive thromboscintigram could be created in an animal model.

The purpose of this paper is to present a representative clinical example of thrombophlebitis and to use an animal model to determine the possible cause of false-positive thromboscintigram.

### CASE REPORT

A 21-year-old woman had swelling and pain in the left leg. A clinical examination resulted in a diagnosis of thrombophlebitis. She was treated



**Figure 2.** A lymphangiogram reveals absence of the deep lymphatic nodal structures and perivesicular accumulations of lymphangiogram contrast agent (Ethiodol). Same patient as shown in Figure 1

with heparin for 10 days. The swelling decreased, but never totally resolved. One month after completed therapy, she returned with recurrent leg

swelling and pleuritic chest pain. Despite a negative lung scan, she again was treated with heparin and discharged. In another month, she again had leg swelling, was treated with heparin, and discharged. A month later, she was admitted for similar complaints, and as thrombophlebitis was considered likely, she was discharged. She continued to complain of swelling in her left leg. A thromboscintigram showed abnormal accumulation of isotope throughout the popliteal and calf region, indicating possible thrombophlebitis (Figure 1). The venogram, however, was normal. Finally, a lymphangiogram revealed congenital absence of deep lymph nodes, atrophy of normal lymphatic drainage, and perivascular accumulation of contrast material in the left lower extremity (Figure 2).

## METHOD AND MATERIALS

An experiment was performed on a 32-kg dog to verify that a false-positive thromboscintigram could result from a surgically induced lymphatic obstruction. To establish a normal baseline, a thromboscintigram, phlebogram, and lymphangiogram were performed. The baseline studies were again repeated after surgical preparation of the animal model. All studies were normal.

A description of the experimental procedures is given in the following sections.

### Lymphangiogram

Before the procedure, the dog was anesthetized by an intravenous injection of 18 mL of a 5 percent solution of sodium thiamylal (Surital). Approximately 30 minutes later, 0.5 mL of methylene blue and a 1 percent lidocaine hydrochloride solution (Xylocaine) was injected into the subcutaneous tissue of both hind feet. The animal was then prepared, draped, and a superficial cutdown was performed over the dorsum of both feet. The lymphatics were then isolated, cannulated with a Viomonte type needle and 5 mL of Ethiodol was injected bilaterally. Routine radiographs of the hind legs, pelvis, and abdomen were obtained on completion of the study and at the 24-hour interval.

### Thromboscintigram

A technetium-sulfur suspension was made after a modified Patton procedure. Into a clean, dry, sterile, stoppered serum vial was placed 3.5 mL of pertechnetate solution in saline from a sterile molybdenum-technetium 99m generator. To this was added 1.0 mL of a 10 mg/mL solution of sodium thiosulfate and 1.0 mL of 1N HCl. All solutions were sterile and pyrogen free. The vial was vented by inserting a 22-gauge needle and placed in boiling water bath for 3<sup>1</sup>/<sub>2</sub> minutes, then cooled in running water for 3<sup>1</sup>/<sub>2</sub> minutes. One mL of a 1:10 dilution of human serum (HSA) was added to the vial, followed by the addition of 2 mL of acetate buffer. The vial was then placed in boiling water and agitated for about 30 seconds. Macroaggregates were obtained in the size of approximately 50 microns.

The <sup>99</sup>Tc labeled macroaggregates were then injected into the veins of the hind legs of the dog. Images were recorded on an Anger camera. Upon clearing of the injected macroaggregates, the dog was maintained in the same position and the venogram was performed.

### Venogram

The animal, still in the same position, was injected with 50 mL (25 mL in each leg) of Renografin-76. The injection was made into the same catheters through which the isotope was introduced. The entire procedure was performed under fluoroscopic control with spot films taken of each leg following the injection.

To create a lymphatic obstruction, most of the afferent vessels to the right inguinal lymph nodes were surgically occluded by a standard laparotomy.

### Surgical Tying Off of Lymphatics

A standard laparotomy approach was performed with careful attention not to harm the vascular structures. The lymphatics stained with methylene blue were then surgically tied. A standard surgical closure of the wound was then accomplished. Following surgery, gross measure-

**TABLE 1. STUDIES OF SURGICALLY INDUCED LYMPHATIC OBSTRUCTIONS IN DOGS**

	Lymphangiogram	Thromboscintigram	Venogram
Baseline studies	Normal	Normal	Normal
Postoperative 3 Months	Abnormal on right	Abnormal on right	Normal
Postoperative 6 Months	Abnormal on right	Abnormal on right	Normal
Postoperative 1 Year*	Abnormal on right	Abnormal on right	Normal

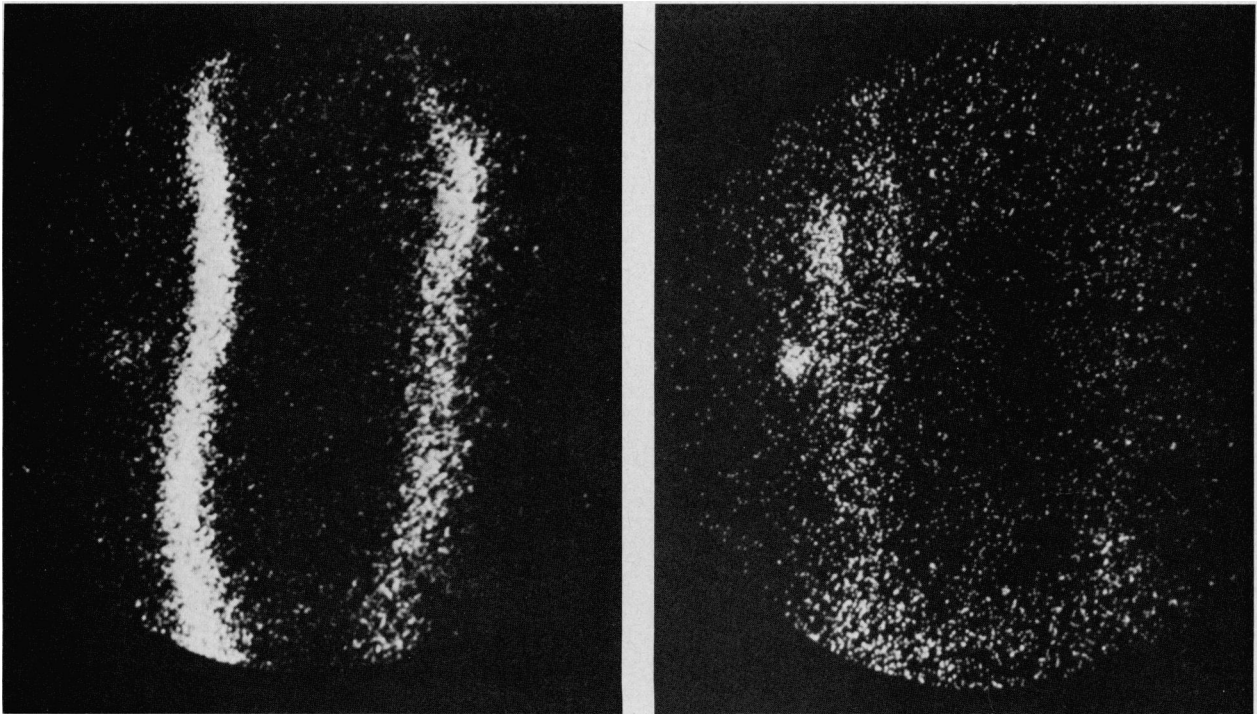
\*Animal model 1, right hind limb 3/4 in larger than left limb, while animal model 2 had right hind limb 1/2 in larger than left limb

Note: One of three canines died at 6 months

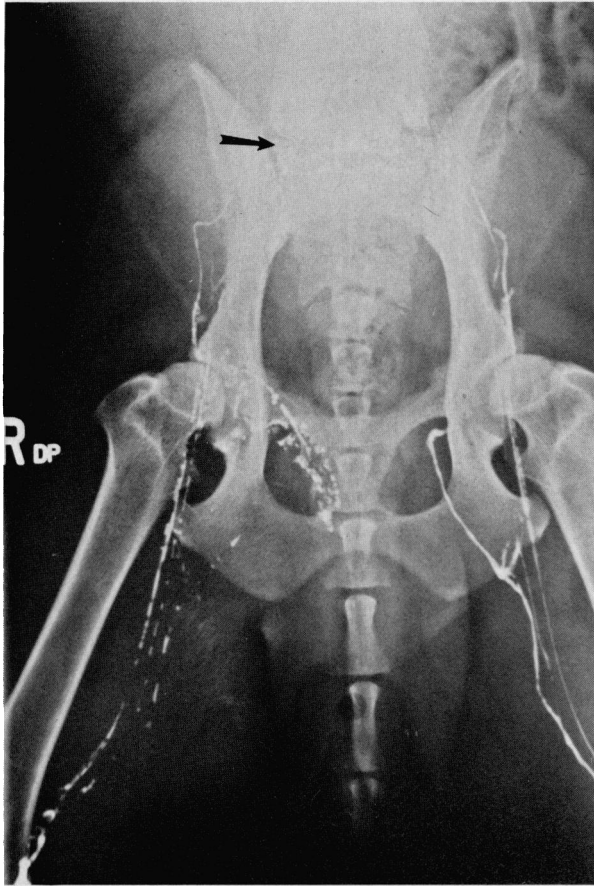
ments of the paw, ankle, and thigh were taken at two-week intervals.

**RESULTS**

Imaging of the animal model one week after the operation revealed an abnormal thromboscintigram and lymphangiogram. The venogram was entirely normal. The thromboscintigram revealed an accumulation of the isotope in the venous drainage of the right hind limb (Figure 3). The lymphangiogram demonstrated obstruction of the Ethiodol contrast by circumvention of the forward flow in the right hind limb (Figure 4). On subsequent studies incomplete drainage of the lymphatics was again demonstrated (Table 1).



**Figure 3. The lymphatic drainage of a dog's right lower extremity has been ligated. A thromboscintigram immediately after the injection of technetium-labeled aggregates in the dorsal veins of the feet of the dog showed abnormal accumulations of isotope in the right lower extremity (left)**



**Figure 4.** A lymphangiogram using contrast agent demonstrates circumvention of contrast material to the obturator lymphatics on the right lower extremity (the surgical ligation of lymphatic drainage is indicated by the arrow)

The venous drainage was normal on the follow-up venograms for over one year. The hind limb on the right (operative side) measured larger than the left side (Table 1). The entire experiment was repeated with two other canines with the same results.

## DISCUSSION

The results demonstrate that obstructive changes to the flow of lymph in the extremities may render a false impression of a positive thromboscintigram. The senior author has observed var-

ious stages of edema in patients presenting with swollen extremities. The subcutaneous tissues in these patients were in various stages of thickening and entrapment with scar tissue. The capillaries and lymph channels were often encased by the fibrous tissue within the extremity. The proliferation of tissue resulting in swelling may be the cause of a false-positive thromboscintigram. Certainly, other causes as mentioned contribute to false studies. The intention here was to test only the theory that edema may be a differential possibility.

Since the presentation of this paper, Henze et al<sup>8</sup> used one of the surviving canines to test a new agent for lymphoscintigraphy. The <sup>99</sup>Tc labeled dextran selectively absorbed by the lymphatics displayed the obstruction as reported. It is therefore recommended that in those patients presenting with swelling of an extremity who may have lymph obstruction, a lymphangiogram, thromboscintigram, or lymphoscintigram be considered.

## Acknowledgment

Research for this paper was supported partially by funds from the Committee on Research of the Academic Senate, Los Angeles Division.

## Literature Cited

1. Webber MM, Bennett LR, Cragin M, Webb R Jr. Thrombophlebitis—Demonstration by scintiscanning. *Radiology* 1969; 92:620-623.
2. Webber MM, Victory W, Cragin MD. Demonstration of thrombophlebitis and endothelial damage by scintiscanning. *Radiology* 1971; 100:93-97.
3. Duffy CG, D'Auria A, Brien TG, et al. New radioisotope test for detection of deep venous thrombosis in the legs. *Br Med J* 1973; 1:712-714.
4. Webber MM, Pollak EW, Victory W. Thrombosis detection by radionuclide particle (MAA) entrapment. Correlation with fibrinogen uptake and venography. *Radiology* 1974; 111:645-650.
5. Steckle RJ, Furmanski S, Collins JD, Poe N. Radionuclide perfusion lymphangiography. A follow-up study. *Br Radiol* 1978; 51:35-40.
6. Grollman JH Jr, Webber MM, Gomes A. Phlebography and radionuclide-clot localization in the lower extremities. *Radiol Clin North Am* 1976; 14:371-385.
7. Rosenthal L, Greyson ND. Observations on the use of <sup>99m</sup>Tc albumin macroaggregates for detection of thrombophlebitis. *Radiology* 1970; 94:413-416.
8. Henze E, Shelbert HR, Collins JD, et al. Tc-99m labeled dextran: A new radiopharmaceutical for radionuclide lymphangiography. *J Nucl Med* 1982; 3:823-829.