

New Mouse Models for Chronic *Cryptosporidium* Infection in Immunodeficient Hosts

BETH L. P. UNGAR,^{1,2*} JENNIFER A. BURRIS,³ CAROLE A. QUINN,¹ AND FRED D. FINKELMAN²

Departments of Preventive Medicine,¹ Medicine,² and Laboratory Animal Medicine,³ Uniformed Services University of the Health Sciences, Bethesda, Maryland 20814-4799

Received 5 October 1989/Accepted 9 January 1990

***Cryptosporidium* sp. causes fulminant diarrhea and chronic infection in immunocompromised, particularly human immunodeficiency virus-infected, persons. The lack of in vitro cultivation and a suitable animal model has limited development of effective treatment. We describe two new mouse models of chronic symptomatic cryptosporidiosis in adult athymic mice and in T-cell subset-depleted mice. A progressive infection, fatal within 4 months, occurred in most adult athymic mice; a few developed stable infections. Symptoms included dehydration, weight loss, intermittent diarrhea, and jaundice. Pathologic abnormalities and organisms localized in the intestine in stable infections but involved the hepatobiliary tree and pancreas in others. Lymphoid cells from histocompatible, *Cryptosporidium* sp.-immune mice cured infected nude mice. Identical infections occurred in neonatally infected BALB/c mice treated with anti-CD4 monoclonal antibodies alone or also with anti-CD8 monoclonal antibodies; the mice were cured when the monoclonal antibody treatments were stopped. These models will be useful in definition of the immune defects that permit chronic cryptosporidiosis to develop and in assessment of treatment modalities.**

Cryptosporidium infection is now a well-recognized cause of diarrhea in immunologically healthy and compromised humans and in animals of veterinary and agriculture interest throughout the world (4, 11, 33). Clinical disease can be fulminant, particularly in human immunodeficiency virus (HIV)-infected hosts, in whom infection persists throughout life. While immunologically healthy patients recover spontaneously within 30 days, their clinical illness can also be severe and their potential for transmission can be persistent for as long as 60 days after symptoms cease (9, 18, 34). Treatment remains limited to hydration and hyperalimentation although more than 90 interventional agents have been tried (4, 11, 33).

By 1986, in the United States, an estimated 3.6% of HIV-infected individuals reported to the Centers for Disease Control, Atlanta, Ga., had cryptosporidiosis (24). In patients with acquired immunodeficiency syndrome and diarrhea, 15% of those evaluated at the National Institutes of Health, Bethesda, Md., and 16% of those evaluated at the Johns Hopkins Hospital, Baltimore, Md., had cryptosporidiosis, which was the most common pathogen in the latter series (21, 32). In two hospitals in Great Britain and Brazil, respectively, 11 and 12% of patients with acquired immunodeficiency syndrome were infected with *Cryptosporidium* sp. and 19% of those in Great Britain were thought to have died as a direct result (3, 8). In other populations, *Cryptosporidium* infection has been described in at least 50 countries throughout the world and is thought to be one of the top enteropathogens in many regions of the less-developed world. Symptomatic illness occurs most often in children and is prolonged by concomitant immunosuppressing conditions, such as malnutrition (4, 11).

The lack of a simple in vitro cultivation system and the lack of a suitable small animal model have limited more rapid development and testing of treatment modalities as well as better understanding of the immunologic response to this parasite (5, 6). We describe here two mouse models of

chronic symptomatic cryptosporidiosis, one in adult congenitally athymic nude mice and the other in anti-CD8 (anti-Lyt2) and/or anti-CD4 (anti-L3T4) antibody-treated suckling BALB/c mice. These models offer the opportunity to investigate therapeutic and immunologic modulation of this infection, as well as to study the specific immune defects which permit prolonged *Cryptosporidium* infection in some hosts.

MATERIALS AND METHODS

***Cryptosporidium* oocyst preparation.** *Cryptosporidium parvum* oocysts were purified from feces of orally infected newborn calves (from two geographically distinct areas) by flotation in distilled water saturated with sodium chloride, followed by three washes in distilled water and, finally, by sedimentation in phosphate-buffered saline (pH 7.4) (38). Approximately 0.2 mg of gentamicin (GIBCO Laboratories, Grand Island, N.Y.) was added to each 5 ml of suspended, washed oocysts to decrease bacterial contamination. The oocysts were counted with a hemacytometer immediately before administration.

Animals. BALB/c pregnant mice, adult BALB/c *nu/nu* inbred mice, and adult athymic nude outbred mice were all obtained from the Small Animal Division of the National Cancer Institute, National Institutes of Health.

***Cryptosporidium* inoculation.** Approximately 10⁷ *C. parvum* oocysts were fed on two successive days to each of 21 adult athymic mice in three temporally unrelated experiments. This dosing regimen was chosen to eliminate the variability noted in the ability of some *C. parvum* isolates to cause infection and illness. The oocysts were administered by gastric gavage, using a 22-gauge straight feeding needle (Thomas Scientific, Swedesboro, N.J.). All mice received a subcutaneous loading dose of 12 mg of sulfadimethoxin (Hoffmann-La Roche Inc., Nutley, N.J.), followed by 6 mg daily for 4 weeks as prophylaxis against gram-negative bacterial infection. All mice were housed in individual filter-topped plastic cages with wood chip bedding and free access to food (Prolab Animal Diet for mice, rats, and hamsters; Agway, Inc., Syracuse, N.Y.) and water.

* Corresponding author.

In two other temporally unrelated experiments, neonatal BALB/c mice were fed approximately 10^7 oocysts on days 3 and 5 of life through an 18-gauge needle covered with silicone rubber tubing (2.1-mm peristaltic pump tubing; Pharmacia Biotechnology, Piscataway, N.J.) inserted into the oral cavity. All litters were housed with their dams as described above until natural weaning occurred; no prophylactic antibiotics were administered. By 7 to 10 days of life, all neonates produced formed stools, and both fecal examination and clinical observations were performed as described below.

Fecal examination and clinical assessment. Fecal pellets from each mouse were examined for *Cryptosporidium* oocysts before feedings and at least four times per week thereafter. Each animal was assessed clinically on days of stool collection for lethargy, weight loss, skin turgor, skin coloration, and abdominal distention. Stool consistency was also noted. Five adult-size fecal pellets were collected from each adult mouse, homogenized in 1 ml of distilled water, mixed with 8 ml of Sheather sucrose solution, and centrifuged at $850 \times g$ at 4°C for 10 min to concentrate oocysts. Approximately half a suckling mouse-size fecal pellet was obtained from each neonatal mouse and homogenized with an equal amount of Sheather sucrose solution. The number of oocysts in a single drop of the resulting mixture was determined by direct light microscopic examination of 25 (neonatal mice) or 100 (adult mice) microscopic fields ($45\times$ objective). These procedures for enumerating oocysts by fecal examination are useful for comparisons among different experimental animal groups. Oocysts were recognized by their typical pink refringence (1); selected specimens were confirmed by modified acid-fast staining.

Monoclonal antibody preparation. The hybridomas GK1.5 (40) and 2.43 (29), which produce rat immunoglobulin G2b (IgG2b) monoclonal antibodies to murine T-cell CD4 and CD8 determinants, respectively, were grown in ascitic fluid in pristane-primed nude mice. The rat IgG2b fractions were purified from these ascites fluids by sequential $(\text{NH}_4)_2\text{SO}_4$ precipitation, DE-52 ion-exchange chromatography, and Sephadex G-200 gel filtration, as previously described (12). The same procedure was used to purify the IgG fraction of nonimmune rat serum (Pel-Freez, Rogers, Ark.). The purified antibodies were concentrated by ultrafiltration through a Dia-Flo PM-10 membrane (Amicon Corp., Danvers, Mass.) and were dialyzed against 0.15 M NaCl and kept at -70°C until use.

Microbiologic and pathologic examination. Animals were euthanized by lethal overexposure either to methoxyflurane or carbon dioxide. At euthanasia, 1 to 2 ml of whole blood was collected by sterile intracardiac puncture. Serum was separated by centrifugation and analyzed for antibodies to the following murine pathogens: minute virus of mice, pneumonia virus of mice, reovirus type 3, mouse hepatitis virus, K virus, Theiler's virus, Sendai virus, lymphocytic choriomeningitis virus, mouse adenovirus, ectromelia virus, polyomavirus, and *Mycoplasma pulmonis* (Anmed/Biosafe, Rockville, Md.).

At necropsy, the contents of the stomach, duodenum, ileum, jejunum, cecum, colon, and gallbladder were aspirated with needle and syringe. The contents were mixed with an equal amount of Sheather sucrose solution, and a single drop was examined for *Cryptosporidium* oocysts by direct microscopy (magnification, $\times 45$). A complete gross examination of all organs and tissues was conducted, and any visible abnormalities were noted. Pieces of liver for culture were collected by using sterile technique, emulsified in

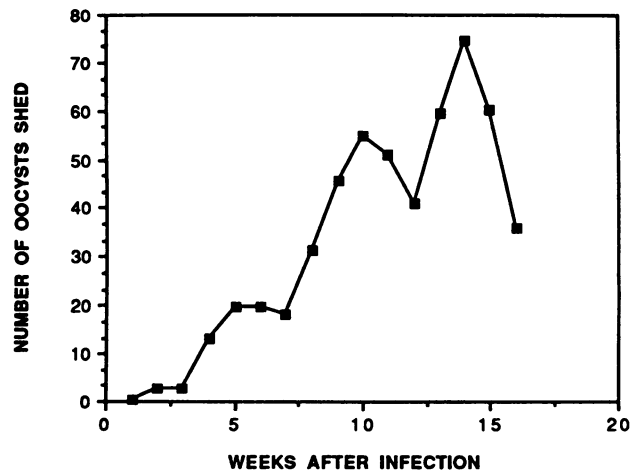


FIG. 1. Pattern of *Cryptosporidium* oocyst excretion in chronically infected adult athymic (*nu/nu*) mice. The number of oocysts shed per week represents the pooled weekly mean number of oocysts detected per microscopic field for eight mice.

Trypticase soy broth, and plated on blood agar, MacConkey agar, and thioglycolate medium. All major organs and tissues were collected and placed in 10% buffered Formalin for fixation. The tissues were then embedded in paraffin for routine histopathologic processing. Sections were stained with hematoxylin and eosin and examined with a bright-field microscope.

RESULTS

Chronic, severe *Cryptosporidium* infection can be established in adult nude mice. Initial experiments were performed to determine whether adult nude mice could be infected with *Cryptosporidium parvum* and, if so, to determine the duration and consequences of such an infection. A total of 14 mice, age 6 to 10 weeks, were infected as described above. No significant clinical abnormalities were observed in any mouse for the first 3 weeks after infection. Subsequently, dehydration, weight loss, and poor skin turgor with dry, flaky skin occurred, accompanied by intermittent loose, bulky and often frankly diarrhetic stools, with large amounts of fecal fat visible microscopically. All infected animals exhibited these clinical signs alternating with periods of normality. Three distinct patterns emerged. The first was characterized in four mice by an abrupt exacerbation of clinical illness over a 2 to 3-day period, followed by death. Two mice, including one with frank jaundice, had a gradual decline over a 4-week period, also followed by death. A final group of three mice continued in a steady state of *Cryptosporidium* infection until sacrificed at week 16 after inoculation. The five other mice died from causes unrelated to cryptosporidiosis, from massive aspiration during feeding or esophageal penetration and abscess formation subsequent to feeding.

No animal shed more than 10 oocysts per microscopic field during the first 3 weeks after infection (Fig. 1). Subsequently, the numbers of oocysts shed increased to as many as 80 per microscopic field. This did not correlate with clinical manifestations, except on the day or two before death, when the numbers decreased significantly. All mice shed oocysts on every day of fecal examination although the number detectable varied considerably from day to day, as is characteristic of *Cryptosporidium* oocyst shedding; the

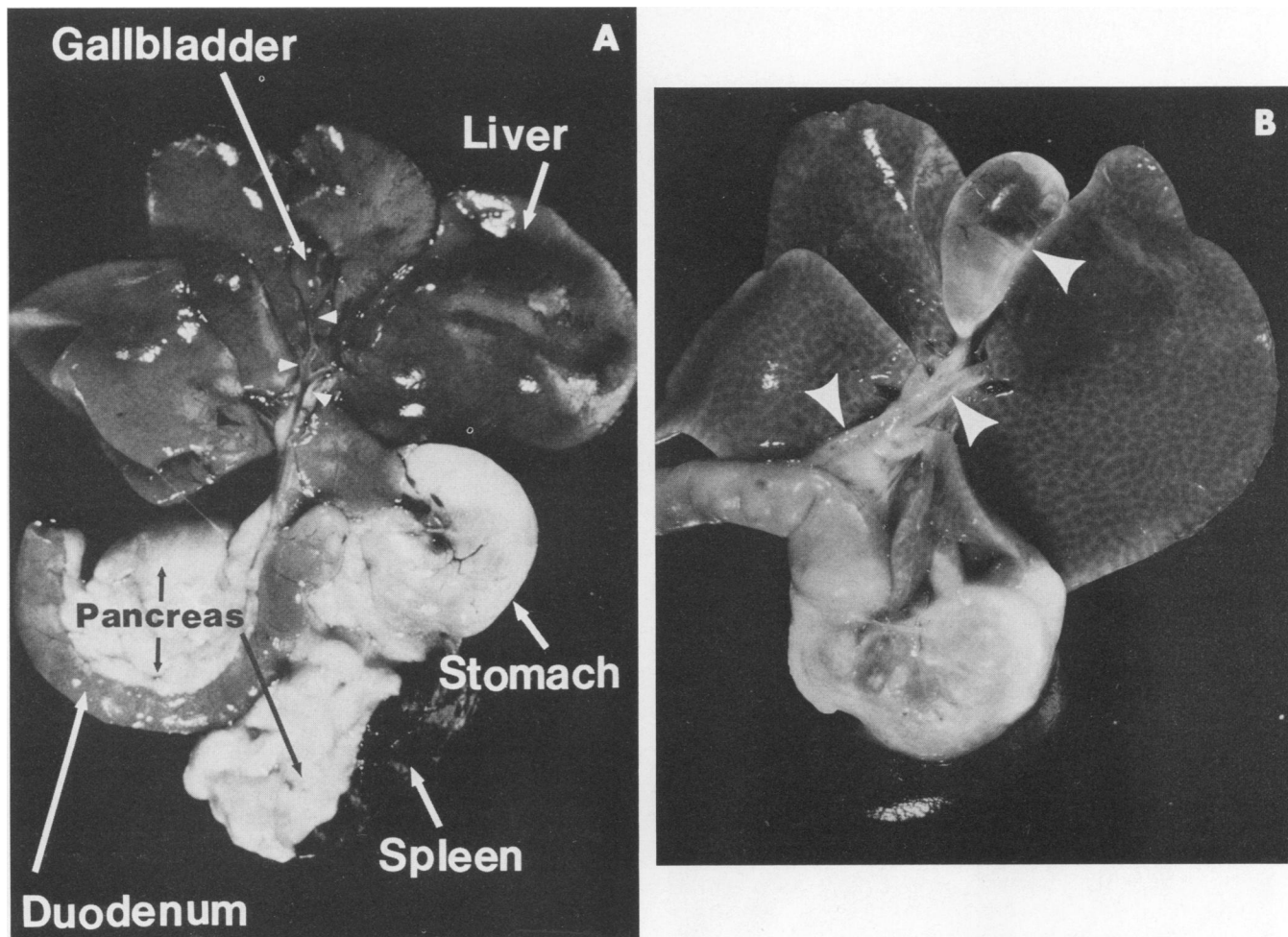


FIG. 2. (A) Cranial-abdominal contents at necropsy of normal adult BALB/c uninfected mouse. Note the appearance of normal liver, biliary tree, and pancreas. Arrowheads point to the bile ducts. The gallbladder and bile ducts are narrow with thin, clear walls. There is abundant pancreatic tissue. (B) Cranial-abdominal contents at necropsy of a chronically infected, clinically deteriorating adult athymic (*nu/nu*) mouse with cryptosporidiosis. Anatomic orientation of organs is identical to that in panel A. The liver is swollen (hepatomegaly) and has a diffuse reticular pattern (cholangiohepatitis). The gallbladder is tremendously distended, as are the cystic duct, extrahepatic ducts, and common bile duct (arrowheads). The ducts are opaque and have thickened inflamed walls. There is severe pancreatic atrophy.

weekly standard deviation was usually equal to the mean number of oocysts shed weekly.

Complete necropsy was possible on nine mice from different clinical groups. On gross pathologic inspection, those mice that had appeared most ill were frequently icteric, were emaciated with abdominal distention, and demonstrated hepatomegaly and dilated biliary systems. The livers of some of these mice showed a diffuse reticular pattern representing the inflamed intrahepatic biliary system and portal areas (Fig. 2B); the common bile ducts, cystic ducts, gallbladders, and extrahepatic ducts were distended and often had opaque and thickened inflamed walls (Fig. 2B). Blood from bleeding gastric ulcers filled the small intestine in some instances. Clinically stable mice that were sacrificed at 16 weeks demonstrated none of these findings (Fig. 2A).

On histologic examination, most infected animals, irrespective of clinical picture, showed mild to moderate gastric ulceration, inflammation at the pyloric ring, typhlitis, colitis, and splenic and mesenteric lymphoid hyperplasia. The mice with more severe clinical deterioration had the greatest inflammation of the gallbladder and biliary tree, the liver,

and the pancreas (Fig. 2B, 3A and B, and 4A and B). In general, intestinal inflammation associated with *Cryptosporidium* sp. was characterized by degeneration, sloughing, and regeneration of both surface and glandular epithelial cells and dilated crypts and glands. Inflammation of the liver (Fig. 3A and B) centered on bile ducts, portal and periportal areas, with associated hepatocyte degeneration and necrosis; fibrosis and striking biliary hyperplasia were present in portal areas, and inflammation often bridged portal areas. Cholelithiasis, cholecystitis, and cholangitis were indicated by hyperplasia, dilatation, chronic-active inflammation, and occasional erosions. The pancreas displayed necrosis with atrophy, infiltration by inflammatory cells, and hyperplastic ducts (Fig. 4A and B). Animals with stable infection had histologic changes limited mostly to the small and large intestines.

No significant gross or histologic abnormalities were found in the following other organs examined in each mouse: cerebrum, cerebellum, esophagus, trachea, lung, heart, duodenum, jejunum, kidneys, adrenal glands, urinary bladder, salivary glands, clitoral glands, prepuccial glands, testes,

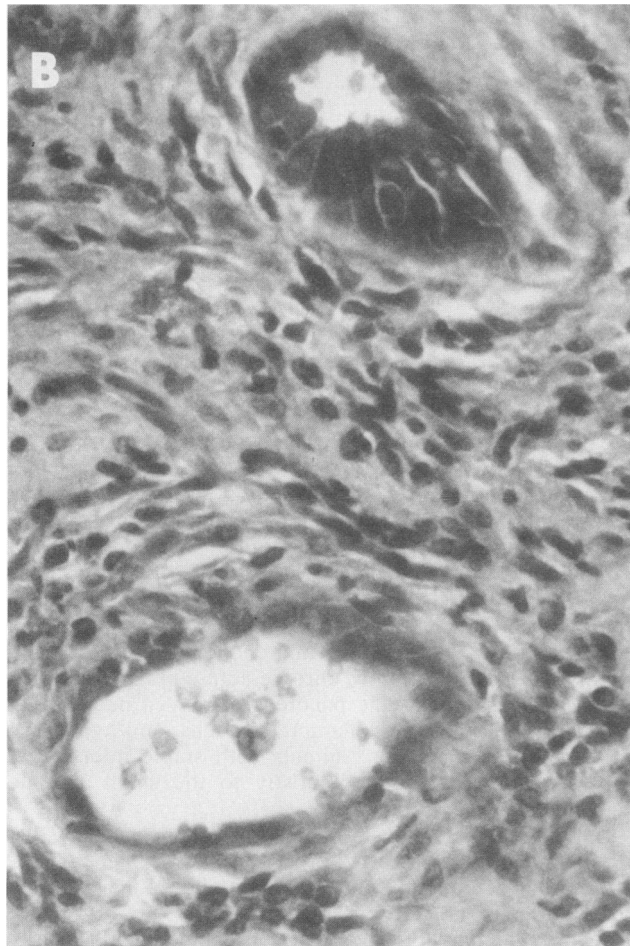
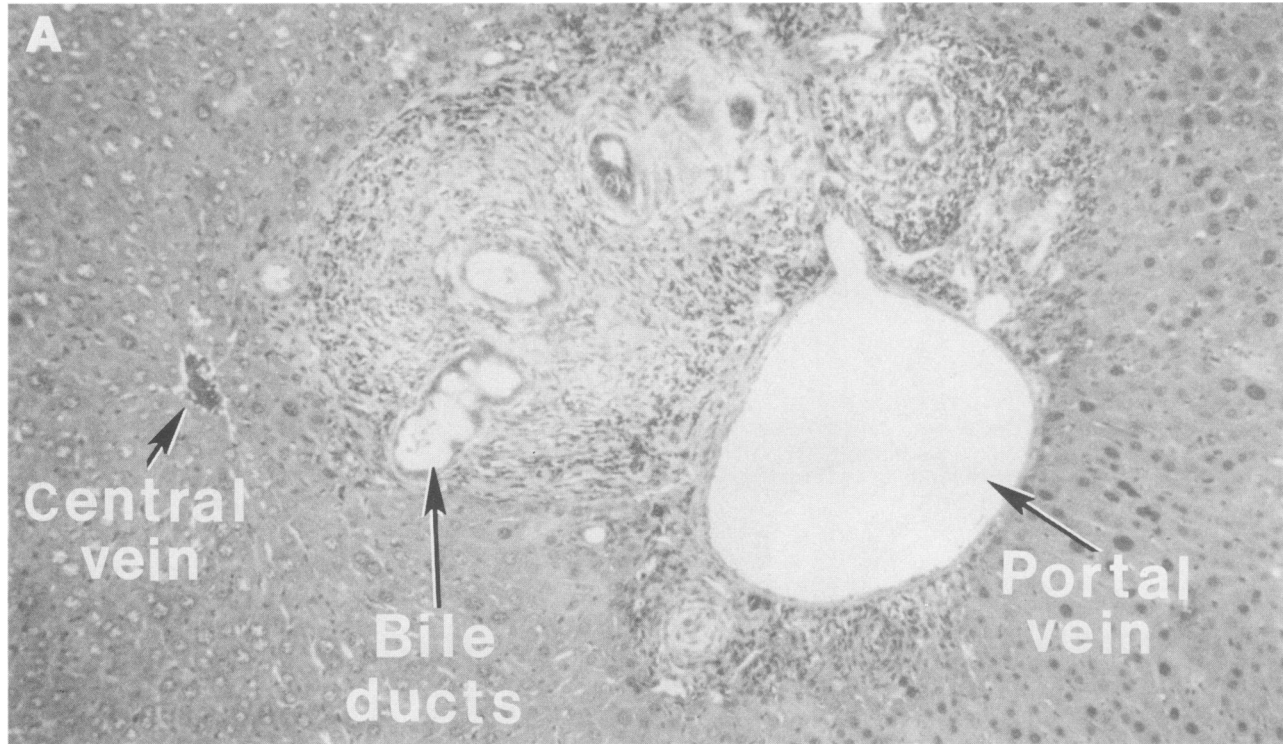


FIG. 3. (A) Liver of a mouse chronically infected with *Cryptosporidium* sp. The portal area shown and adjacent liver parenchyma are fibrotic and infiltrated by large numbers of inflammatory cells. The bile ducts are dilated and hyperplastic. Hematoxylin and eosin stain; magnification, $\times 100$. (B) Higher magnification of portal area shown in panel A. These hyperplastic ducts contain *Cryptosporidium* organisms along the luminal surface of epithelial cells. Hematoxylin and eosin stain; magnification, $\times 400$.

ovaries, uterus, prostate, seminal vesicles, or coagulating gland. Serologic assays obtained for four mice were negative for all viruses and mycoplasma. Cultures of liver tissue were negative for bacterial growth in the three mice tested.

Cryptosporidium oocysts were detectable by aspiration of the gallbladder (five of eight animals), the ileum or jejunum (three of five animals), and the cecum (six of eight animals). No organisms were detected in aspirated stomach or duodenal fluid of any mouse. Anatomic locations at which *Cryptosporidium* organisms were found histologically are shown in Table 1. Organisms were generally identified in the pyloric rings, ilea ceca, and colons of all clinical groups. They were less common in the biliary and pancreatic systems of mice with stable nonprogressive infection compared with those with abrupt clinical deterioration. Characteristically, organisms lined the luminal borders of surface, glandular, and ductal epithelial cells of affected organs and were associated with inflammation (Fig. 3 to 5).

Lymphoid cells from histocompatible, *Cryptosporidium* sp.-immune mice will cure *Cryptosporidium* sp.-infected nude mice. Having shown that a chronic *Cryptosporidium* infection could be established in nude mice, we studied whether lymphoid cells from histocompatible *Cryptosporidium* sp.-immune mice could terminate this infection. Four weeks after seven BALB/c *nu/nu* mice, 6 to 10 weeks of age, were infected with *Cryptosporidium* sp., four mice each received a single intravenous injection of 0.5 ml of 0.15 M NaCl containing 10^8 cells that had been prepared from the spleens

TABLE 1. Histologic location of *Cryptosporidium* organisms in chronically infected athymic (*nu/nu*) mice^a

Organ(s)	Presence of <i>Cryptosporidium</i> organisms ^b in individual mice with:								
	Abrupt clinical deterioration			Gradual clinical deterioration			Stable infection		
Stomach ^c	-	-	NE	-	-	-	-	-	-
Pyloric ring	+	+	NE	+	NE	NE	+	+	+
Duodenum	+	-	-	-	NE	-	-	+	-
Jejunum	-	-	NE	-	-	-	-	+	+
Ileum	+	+	-	+	-	-	+	+	+
Cecum	+	+	+	+	+	+	+	+	+
Colon	+	+	+	+	+	-	+	+	+
Gallbladder	+	+	+	+	NE	NE	-	NE	-
Common bile duct	+	-	+	+	NE	+	NE	-	-
Extrahepatic bile ducts	+	NE	+	+	NE	-	-	NE	-
Intrahepatic and interlobular bile ducts	+	+	+	+	+	-	-	+	-
Pancreatic ducts	-	-	+	+	NE	+	-	-	-

^a Hematoxylin-and-eosin-stained slides were examined by light microscopy.
^b -, *Cryptosporidium* absent; +, *Cryptosporidium* present; NE, not examined.
^c Both glandular and nonglandular areas were examined.

and mesenteric lymph nodes of five BALB/c mice that spontaneously recovered after neonatal *Cryptosporidium* infection.

All immunologically reconstituted mice cleared detectable *Cryptosporidium* organisms within 1 week of injection of immune lymphoid cells (Table 2). The experiment was terminated once the injected mice had not shed oocysts for at least 28 days. Necropsies performed on two of these mice at 8 weeks after the initial infection detected no gross lesions; histopathology detected no *Cryptosporidium* organisms. At week 25, the two remaining reconstituted mice continued to have no detectable oocyst shedding. In contrast, one mouse of the nonreconstituted group died after a period of gradual clinical deterioration at 16 weeks (*Cryptosporidium* organisms were found in aspirates taken throughout the small and large intestines) and two other nonreconstituted mice continued to shed organisms and show clinical disease progression.

TABLE 2. Clearance of *Cryptosporidium* organisms from immunologically reconstituted chronically infected adult athymic (*nu/nu*) mice

Week after oral infection	Weekly mean no. of oocysts shed per microscopic field ^a for mouse ^b :						
	1	2	3	4	5	6	7
0	0	0	0	0	0	0	0
1	ND	ND	ND	ND	ND	ND	ND
2	6.0	5.7	1.3	0.3	6.7	0.7	4.3
3	26.6	28.6	2.7	9.7	6.6	6.3	19.0
4	44.7	33.3	4.7	7.3	0.3	1.3	19.0
5	92.3	29.6	3.3	0	0	0	0
6	144.0	35.7	16.7	0	0	0	0
7	171.6	13.0	0.6	0	0	0	0
8	400.0	27.0	3.0	0	0	0 ^c	0 ^c
9	111.0	32.0	6.0	0	0		
10	ND	ND	ND	ND	ND		
11	452.0	113.0	18.0	0	0		

^a Number represents the mean number of oocysts per microscopic field of at least three fecal examinations performed on different days during any 1-week period. ND, Not done.

^b A slow intravenous injection of 10⁸ mesenteric and lymph node cells harvested from BALB/c mice that had recovered from a neonatal *Cryptosporidium* infection was given to mice 4 to 7 between weeks 3 and 4, while mice 1 to 3 remained untreated.

^c Sacrificed.

Chronic *Cryptosporidium* infection can be produced in neonatally infected mice that are treated with anti-CD4 or anti-CD4 plus anti-CD8 antibodies. To determine whether suppression of T-cell function prolongs *Cryptosporidium* infection, BALB/c mice that had been infected with *Cryptosporidium* sp. as neonates received either no additional treatment (*n* = 11) or weekly intraperitoneal injections of 0.5 mg each of monoclonal anti-CD4 plus anti-CD8 antibodies, beginning on day 5 of life (*n* = 4). (This dosage of monoclonal antibody eliminates CD4⁺ T cells [20]). While mice that did not receive anti-T-cell antibodies became free of evident infection 3 to 5 weeks after inoculation, mice treated with anti-T-cell antibodies continued to excrete oocysts throughout the period of antibody administration. Two of the latter mice, in which antibody administration was discontinued 6 weeks after *Cryptosporidium* inoculation, stopped shedding oocysts by week 8. One of these two was necropsied 10 weeks later and showed no evidence of remaining infection. Of the two mice continuously treated with anti-T-cell antibody, one developed a clinical picture similar to that noted in the severely ill infected nude mice and died 7 weeks after inoculation. The other continued to receive weekly anti-T-cell antibodies for 20 weeks after *Cryptosporidium* inoculation, at which time it was sacrificed; at necropsy, findings included diffusely located *Cryptosporidium* organisms throughout the intestinal tract with inflammation in the pyloric area, colitis, and splenic and mesenteric node hyperplasia.

An additional experiment was performed in which neonatally infected mice received anti-CD4 monoclonal antibody alone, both anti-CD4 and anti-CD8 monoclonal antibodies, anti-CD8 monoclonal antibody alone, normal rat IgG, or no antibody (Table 3). Mice that received no antibody, normal rat IgG, or anti-CD8 monoclonal antibody alone ceased shedding detectable oocysts by 3 or 4 weeks after inoculation; in contrast, mice treated with anti-CD4 monoclonal antibody or with a combination of anti-CD4 plus anti-CD8 monoclonal antibodies continued to shed oocysts for the duration of antibody treatment and for 2 to 4 additional weeks after antibody treatment was stopped. One mouse that received both anti-CD4 and anti-CD8 antibodies was sacrificed at week 5 of antibody administration and at necropsy had minimal to mild ileitis, typhlitis, and colitis, with *Cryptosporidium* organisms seen histologically in these

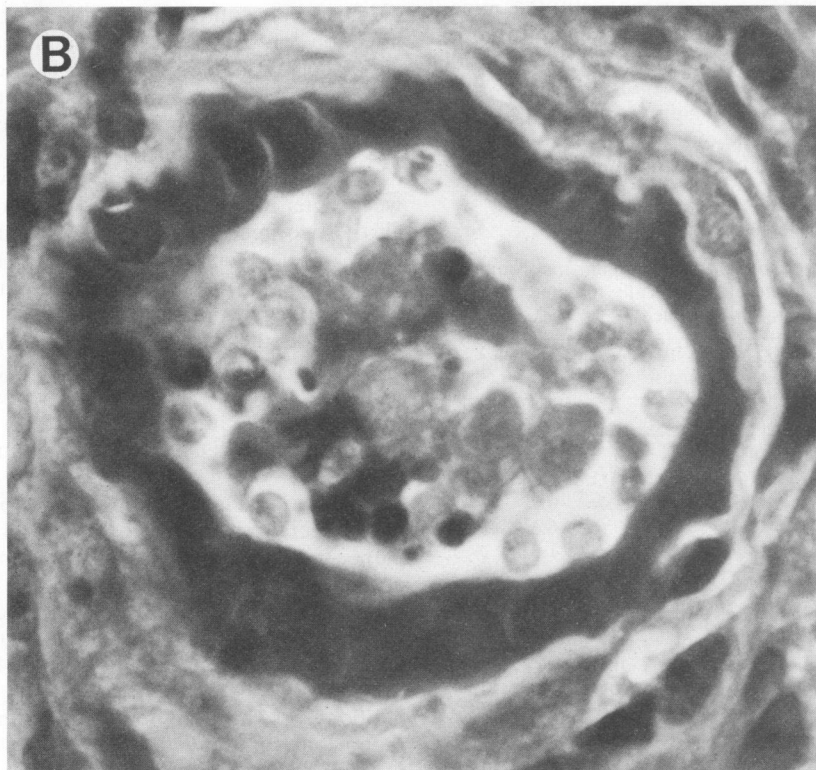
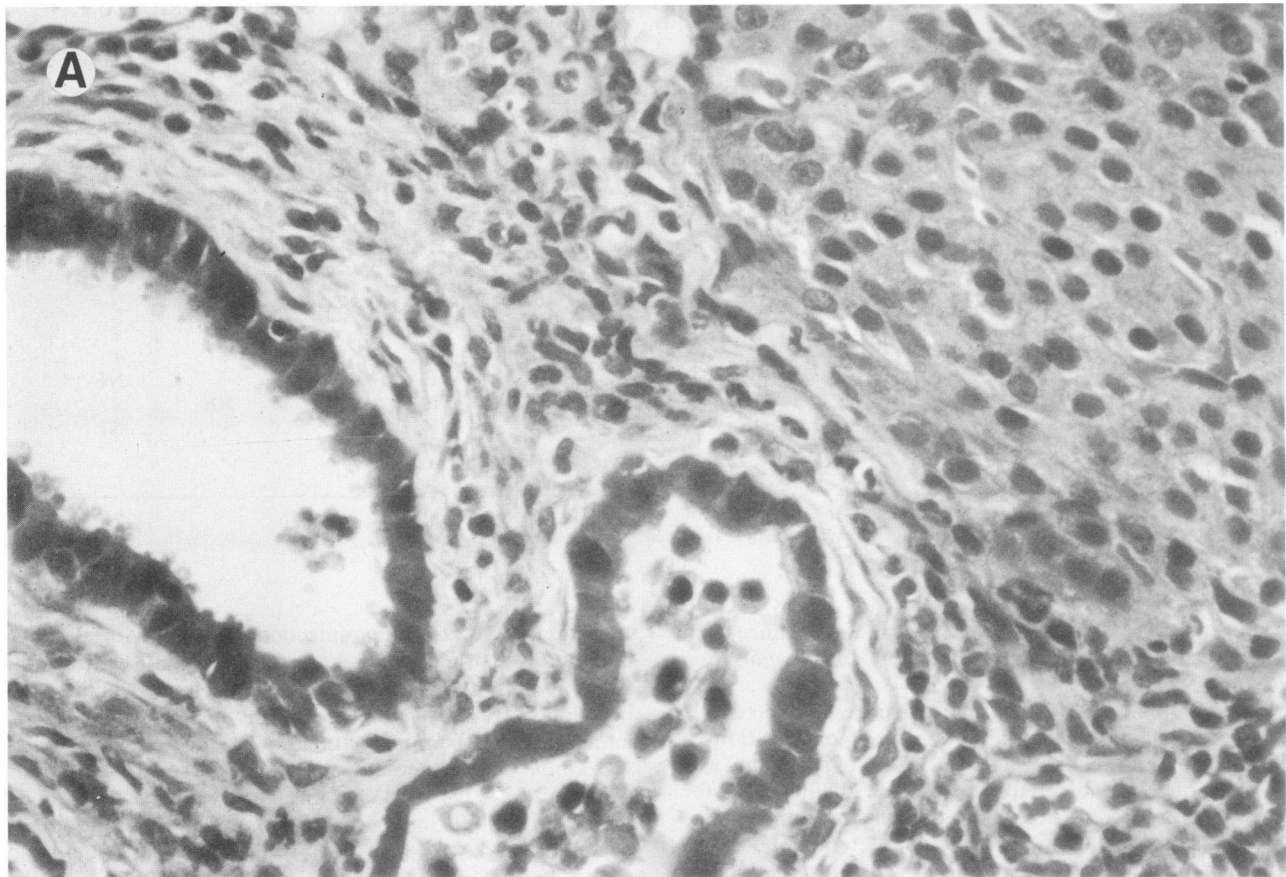


FIG. 4. (A) Pancreas of a mouse chronically infected with *Cryptosporidium* sp. There is a normal islet in the upper right corner. Dilated, hyperplastic interlobular pancreatic ducts contain abundant *Cryptosporidium* organisms and intraluminal neutrophils and macrophages. Large numbers of inflammatory cells have infiltrated the parenchyma. Hematoxylin and eosin stain; magnification, $\times 400$. (B) Higher magnification of ductal area. Inflamed, dilated intralobular pancreatic ducts contain *Cryptosporidium* organisms, intraluminal macrophages, and sloughed epithelial cells. Note the banana-shaped merozoites at twelve o'clock. Hematoxylin and eosin stain and oil immersion microscopy were used.

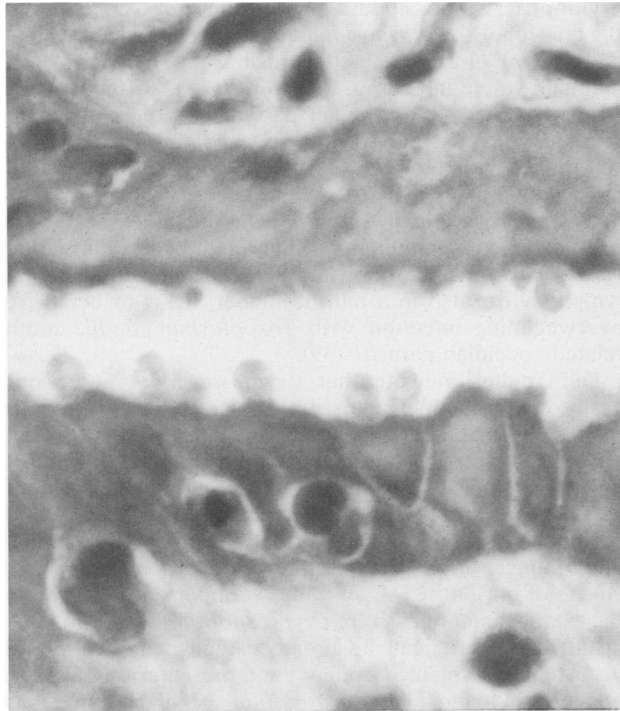


FIG. 5. Gallbladder of a mouse chronically infected with *Cryptosporidium* sp. Numerous *Cryptosporidium* organisms are adherent to the luminal surfaces of epithelial cells. Hematoxylin and eosin stain and oil immersion microscopy were used.

areas. Two anti-CD4 antibody-treated animals that were sacrificed 5 weeks after antibody treatment had been stopped had no detectable organisms in their intestinal contents.

DISCUSSION

Cryptosporidium infection was first noted in 1907 by E. E. Tyzzer as an asymptomatic infection in the gastric glands of

laboratory mice (*C. muris*); a second isolate (*C. parvum*) was subsequently identified in the small intestinal epithelia of laboratory mice (36, 37). Many decades later, as the acquired immunodeficiency syndrome epidemic heightened awareness of *Cryptosporidium* sp. as a human pathogen, a suitable small animal model was sought. Initial studies showed that while laboratory mice could be asymptotically infected as 1- to 4-day-old neonates, mice 21 days old or older at best had a transient infection, even if immunosuppressed with cyclophosphamide (31). Additional work involving neonatal mice demonstrated that patent infection develops in approximately 4 days, that oocysts are shed for an average of 9 days, and that oocysts are spontaneously cleared by 3 weeks of age (7, 10, 16).

Attempts to infect adult mice include the establishment of intrauterine infection by direct inoculation (22) and the establishment of intestinal (particularly in the ileum, upper colon, and cecum) infection in germfree adult mice (14), although infection in these adults was never as great as in suckling mice inoculated and sacrificed at the same time as the adult mice.

In nude mice, experimentally infected neonatal animals were reported to develop a chronic infection in which diarrhea, dehydration, weight loss, and increased oocyst shedding were observed approximately 30 days after infection (16). *Cryptosporidium* organisms were found in the ilea, ceca, and colons of these mice. In contrast, the same authors reported that 42-day-old adult athymic nude mice shed only an occasional oocyst during the 11 days they were monitored with fecal examination postinfection with *Cryptosporidium* sp. (16). In another study, only 1 of 28 nude mice more than 21 days old became intestinally infected as determined by histologic examination (31). In both of these studies, although mice (of necessity, since systematic in vitro cultivation of *Cryptosporidium* sp. is not possible) received oocysts purified from fecal specimens as did the animals discussed here, the inoculum size and method of administration of oocysts were different.

Rat models which rely on the administration of hydrocorti-

TABLE 3. Clearance of *Cryptosporidium* organisms from infected neonatal BALB/c mice with and without deleted CD8⁺ and/or CD4⁺ T-cell lymphocytes

Week after oral infection	Weekly mean no. of oocysts shed per microscopic field ^a by mice treated with:						
	Anti-CD4 ^b		Anti-CD4 + anti-CD8 ^b		Anti-CD8 ^b (n = 6)	Rat IgG (n = 3)	No antibody (n = 5)
	n = 5	n = 4	n = 6	n = 4			
0	0	0	0	0	0	0	0
1	ND	ND	ND	ND	ND	ND	ND
2	52.5	191.5	1,365.2	926.3	734.0	1,262.9	430.8
3	12.8	19.3	68.2	63.6	2.6	1.0	1.5
4	18.2	17.2	63.9 ^c	73.1	0.1	0	0.1
5	15.8	17.9	53.8	43.2	0	0	0
6	11.3 ^c	18.4	53.9	36.5	0	0	0
7	4.9	15.2	25.7	15.5			
8	1.7	11.1 ^c	1.0	16.6			
9	0.1	3.3	0	15.9 ^c			
10	0	1.8	0	11.6			
11	0	0		4.0			
12	0	0		5.3			
13		0		0			
14				0			

^a Number represents the mean number of oocysts per microscopic field of at least three fecal examinations performed on each animal on different days during any 1-week period. ND, Not done.

^b GK1.5 was used to ablate CD4⁺ T cells and 2.43 was used to ablate CD8⁺ T cells.

^c Monoclonal antibody injections were terminated at this time.

sone acetate, cyclophosphamide, or dexamethasone have also been described (2, 25, 26).

The mouse models described here have advantages over these earlier models and also further elucidate immune requirements for the control of *Cryptosporidium* infection. Chronic symptomatic cryptosporidiosis of the gastrointestinal and hepatobiliary tracts can be produced in adult (rather than neonatal) athymic mice and in infant mice as they mature by depletion of CD4⁺ T-cell function. Monitoring of clinical signs and serial study of formed feces for oocyst excretion are possible for longer periods of time, which allows the course of the disease to be better delineated and avoids reliance on a single necropsy examination, which characterized some other studies. Anti-CD4 antibody also modifies the immune system in a way that more closely resembles the selective CD4⁺ T-cell deficiency in HIV infection than does steroid or cytotoxic drug treatment or even the pan-T-cell defect of nude mice. This depletion prevents the spontaneous clearing of *Cryptosporidium* organisms that characteristically occurs as otherwise-untreated, neonatally infected mice mature and points to specific T-cell defects which allowed chronic cryptosporidiosis to develop. This should permit testing of possible therapeutic interventions in a system that more closely resembles (although is not identical to) the human HIV-infected patient with chronic cryptosporidiosis.

In HIV-infected patients, symptoms fluctuate, with asymptomatic periods alternating with modest or more intractable diarrhea (4, 11, 18, 33, 34). Histologically documented extraintestinal cryptosporidiosis and associated symptoms in these patients have been increasingly reported, particularly involving the biliary tract. Acalculous cholecystitis, cholangitis, portal hepatitis, hepatic pericholangitis, and pancreatitis have all been described, occasionally, in immunocompetent individuals as well (13, 15, 19, 23, 30). Of note, concentrated searches for *Cryptosporidium* life cycle stages outside the intestinal tract are still rudimentary in humans.

Both the infected congenitally athymic mice and the neonatally infected, persistently anti-CD4 antibody-treated BALB/c mice also developed waxing and waning periods of diarrhea, with increasing weight loss and dehydration, that began about 4 weeks after oral inoculation. Rapid deterioration or a more slowly progressive illness preceded death in many immunodeficient mice, while others developed a steady clinical state that persisted until termination of the experiment. This result has not been described in any other small animal model to date, most of which produce asymptomatic or intestinally limited infections or require the use of broadly immunosuppressive agents, such as cyclophosphamide or hydrocortisone acetate (2, 10, 16, 25, 26, 31). Oocyst shedding also varies in most infected humans on a daily and weekly basis, as it does in the mouse models described here (18, 34).

Necropsy examination of chronically infected animals confirms diffuse infection with *Cryptosporidium* organisms comparable to that of some HIV-infected humans. Most mice showed organisms in the intestine, and unlike humans, at the pyloric ring, while those with the most severe clinical illness had involvement of the pancreas and hepatobiliary tree. Although the simultaneous presence of another undetected pathogen or a necessary cofactor cannot absolutely be ruled out either in these mice or in humans, all viral serologic studies and liver cultures that were performed on mice in our study were negative, and there was no histopathologic evidence of other infectious agents.

Our observations about the importance of CD4⁺ T cells in the control of *Cryptosporidium* infection are consistent with findings for closely related parasites: nude BALB/c mice maintain stable infections with *Giardia muris* unless reconstituted with lymphoid cells, particularly those from mice previously exposed to *Giardia* sp., while normal mice have self-limited infection (27, 35). Monoclonal antibody studies have shown that CD4⁺ T cells are necessary for elimination of *G. muris*, although CD8⁺ T cells are not (17). CD4⁺ T cells also mediate immunity to the related coccidian *Eimeria vermiformis* in mice (28), and selective depletion of these lymphocytes, also in a murine model, leads to death from overwhelming infection with *Toxoplasma gondii*, another related coccidian parasite (39).

Our studies indicate that *Cryptosporidium* infection is easily established in adult nude mice, as was previously reported for neonatal nude mice (16). Surprisingly, this is not the case for anti-CD4 antibody-treated adult mice, which are much more resistant to infection as adults than as neonates (B. L. P. Ungar, unpublished data). This suggests the possibility that some T-cell population which is absent in the nude mouse, and which is either CD4⁻ or resistant to the effects of our anti-CD4 antibody, is important in preventing the establishment of severe *Cryptosporidium* infection but is insufficient to eradicate an already established infection. The occurrence of splenic lymphoid and mesenteric lymph node hyperplasia in most *Cryptosporidium* sp.-infected nude mice and in mice treated with anti-CD4 plus anti-CD8 antibodies suggests that non-T cells in these mice respond immunologically to *Cryptosporidium* but that this is not effective in curing the infection. A lack of T cells is crucial to the establishment of persistent *Cryptosporidium* infection, and reconstitution with a T-cell population that includes CD4⁺ T cells is necessary for successful recovery from cryptosporidiosis. The animal models of chronic *Cryptosporidium* infection described here will be useful for the further definition of defects in the immune response to *Cryptosporidium* sp. that might be amenable to immunotherapy, as well as for assessment of potential prophylactic and treatment modalities.

ACKNOWLEDGMENTS

We thank Donna Boyle for her expert clerical assistance.

This work was supported by USAMRDC grant DAMD17-86MM6514 and the Uniformed Services University of the Health Sciences protocol nos. G18792 and R08308.

LITERATURE CITED

1. Baxby, D. and N. Blundell. 1988. Recognition and laboratory characteristics of an atypical oocyst of *Cryptosporidium*. *J. Infect. Dis.* **158**:1038-1045.
2. Brasseur, P., D. Lemeteil, and J. J. Ballet. 1988. Rat model for human cryptosporidiosis. *J. Clin. Microbiol.* **26**:1037-1039.
3. Connolly, G. M., M. S. Dryden, D. C. Shanson, and B. G. Gassard. 1988. Cryptosporidiosis diarrhoea in AIDS and its treatment. *Gut* **29**:595-597.
4. Crawford, F. G. and S. H. Vermund. 1988. Human cryptosporidiosis. *Crit. Rev. Microbiol.* **16**:113-159.
5. Current, W. L., and T. B. Haynes. 1984. Complete development of *Cryptosporidium* in cell cultures. *Science* **224**:603-605.
6. Current, W. L., and P. L. Long. 1983. Development of human and calf *Cryptosporidium* in chicken embryos. *J. Infect. Dis.* **148**:1108-1113.
7. Current, W. L., and N. C. Reese. 1986. A comparison of endogenous development of three isolates of *Cryptosporidium* in suckling mice. *J. Protozool.* **33**:98-108.
8. Dias, R. M. D., A. C. S. Mangini, D. M. G. V. Torres, M. O. A. Correa, N. Lupetti, F. M. A. Correa, and P. P. Chieffi. 1988. Cryptosporidiosis among patients with Acquired Immunodeficiency.

- ciency Syndrome (AIDS) in the country of Sao Paulo, Brazil. *Rev. Inst. Med. Trop. Sao Paulo* **30**:310-312.
9. Edelman, M. J., and E. C. Oldfield. 1988. Severe cryptosporidiosis in an immunocompetent host. *Arch. Intern. Med.* **148**:1873-1874.
 10. Ernst, J. A., B. L. Blagburn, and D. S. Lindsay. 1986. Infection dynamics of *Cryptosporidium parvum* in neonatal mice. *J. Parasitol.* **72**:796-798.
 11. Fayer, R., and B. L. P. Ungar. 1986. *Cryptosporidium* and cryptosporidiosis. *Microbiol. Rev.* **50**:458-483.
 12. Finkelman, F. D., S. W. Kessler, J. F. Mushinski, and M. Potter. 1981. IgD-secreting murine plasmacytomas: identification and partial characterization of two IgD myeloma proteins. *J. Immunol.* **126**:680-687.
 13. Gross, T. L., J. Wheat, M. Bartlett, and W. O. O'Connor. 1986. AIDS and multiple system involvement with *Cryptosporidium*. *Am. J. Gastroenterol.* **81**:456-458.
 14. Harp, J. A., M. W. Wannemuehler, D. B. Woodmansee, and H. W. Moon. 1988. Susceptibility of germfree or antibiotic-treated adult mice to *Cryptosporidium parvum*. *Infect. Immun.* **56**:2006-2010.
 15. Hawkins, S. P., R. P. Thomas, and C. Teasdale. 1987. Acute pancreatitis: a new finding in *Cryptosporidium* enteritis. *Br. Med. J.* **294**:483-487.
 16. Heine, J., H. W. Moon, and D. B. Woodmansee. 1984. Persistent *Cryptosporidium* infection in congenitally athymic (nude) mice. *Infect. Immun.* **43**:856-859.
 17. Heyworth, M. F., J. R. Carlson, and T. H. Ermak. 1987. Clearance of *Giardia muris* infection requires helper/inducer T lymphocytes. *J. Exp. Med.* **165**:1743-1748.
 18. Jokipii, L., and A. M. M. Jokipii. 1986. Timing of symptoms and oocyst excretion in human cryptosporidiosis. *N. Engl. J. Med.* **26**:1643-1647.
 19. Kahn, D. G., J. M. Garfinkle, D. C. Klonoff, L. J. Pembroke, and D. J. Morrow. 1987. Cryptosporidial and cytomegaloviral hepatitis and cholecystitis. *Arch. Pathol. Lab. Med.* **111**:879-881.
 20. Katona, I. M., J. F. Urban, and F. D. Finkelman. 1988. The role of L3T4+ and Lyt 2+ T-cells in the IgE response and immunity to *Nippostrongylus brasiliensis*. *J. Immunol.* **140**:3206-3211.
 21. Laughon, B. E., D. A. Druckman, A. Vernon, T. C. Quinn, B. F. Polk, J. F. Modlin, R. H. Yolken, and J. G. Bartlett. 1988. Prevalence of enteric pathogens in homosexual men with and without acquired immunodeficiency syndrome. *Gastroenterology.* **94**:984-993.
 22. Liebler, E. M., J. F. Pohlenz, and D. B. Woodmansee. 1986. Experimental intrauterine infection of adult BALB/c mice with *Cryptosporidium* sp. *Infect. Immun.* **54**:255-259.
 23. Margulis, S. J., C. L. Honig, R. Soave, A. F. Govoni, J. A. Mouradian, and I. M. Jacobson. 1986. Biliary tract obstruction in the Acquired Immunodeficiency Syndrome. *Ann. Intern. Med.* **105**:207-210.
 24. Navin, T. R., and A. M. Harden. 1987. Cryptosporidiosis in patients with AIDS. *J. Infect. Dis.* **155**:150.
 25. Rehag, J. E., M. L. Hancock, and D. B. Woodmansee. 1987. Characterization of cyclophosphamide-rat model of cryptosporidiosis. *Infect. Immun.* **55**:2669-2674.
 26. Rehag, J. E., M. L. Hancock, and D. B. Woodmansee. 1988. Characterization of a dexamethasone-treated rat model of cryptosporidial infection. *J. Infect. Dis.* **158**:1406-1407.
 27. Roberts-Thomson, I. C., and G. F. Mitchel. 1978. Giardiasis in mice: prolonged infections in certain mouse strains and hypothyroid mice. *Gastroenterology* **75**:42-46.
 28. Rose, M. E., H. S. Joysey, P. Hesketh, R. K. Grecis, and D. Wakelin. 1988. Mediation of immunity to *Eimeria vermiciformis* in mice by L3T4+ T cells. *Infect. Immun.* **56**:1760-1765.
 29. Sarmiento, M. A., L. Glasebrook, and F. W. Fitch. 1980. IgG or IgM monoclonal antibodies reactive with different determinants on the molecular complex bearing Lyt2 antigen block T cell-mediated cytolysis in the absence of complement. *J. Immunol.* **125**:2665-2672.
 30. Schneiderman, D. J., J. P. Cello, and F. C. Laing. 1987. Papillary stenosis and sclerosing cholangitis in the Acquired Immunodeficiency Syndrome. *Ann. Intern. Med.* **106**:546-549.
 31. Sherwood, D., K. W. Angus, D. R. Snodgrass, and S. Tzipori. 1982. Experimental cryptosporidiosis in laboratory mice. *Infect. Immun.* **38**:471-475.
 32. Smith, P. D., H. C. Lane, V. J. Gill, J. F. Manischewitz, G. V. Quinlan, A. S. Fauci, and H. Masur. 1988. Intestinal infections in patients with the acquired immunodeficiency syndrome (AIDS). *Ann. Intern. Med.* **108**:328-333.
 33. Soave, R., and D. Armstrong. 1986. *Cryptosporidium* and cryptosporidiosis. *Rev. Infect. Dis.* **8**:1012-1023.
 34. Stehr-Green, J. K., L. McCaig, H. M. Remsen, C. S. Rains, M. Fox, and D. D. Juranek. 1987. Shedding of oocysts in immunocompetent individuals infected with *Cryptosporidium*. *Am. J. Trop. Med. Hyg.* **36**:338-342.
 35. Stevens, D. P., D. M. Frank, and A. A. F. Mahmoud. 1978. Thymus dependency of host resistance to *Giardia muris* infection. *J. Immunol.* **120**:680-682.
 36. Tyzzer, E. E. 1907. A sporozoan found in the peptic glands of the common mouse. *Proc. Soc. Exp. Biol. Med.* **5**:12-13.
 37. Tyzzer, E. E. 1912. *Cryptosporidium parvum* (sp. nov.), a coccidium found in the small intestine of the common mouse. *Arch. Protistenkd.* **26**:394-412.
 38. Ungar, B. L. P., R. Soave, R. Fayer, and T. E. Nash. 1986. Enzyme immunoassay detection of immunoglobulin M and G antibodies to *Cryptosporidium* in immunocompetent and immunocompromised persons. *J. Infect. Dis.* **153**:570-578.
 39. Vollmer, T. L., M. K. Waldor, L. Steinman, and F. K. Conley. 1987. Depletion of T-4+ lymphocytes with monoclonal antibody reactivates toxoplasmosis in the central nervous system: a model of superinfection in AIDS. *J. Immunol.* **38**:3737-3741.
 40. Wilde, D. B., P. Marrack, J. Poppler, D. P. Dialynas, and F. W. Fitch. 1983. Evidence implicating L3T4 in class II MHC antigen reactivity: monoclonal antibody GK 1.5 (anti-L3T4) blocks class II MHC antigen-specific proliferation, release of lymphokines, and binding by cloned murine helper T lymphocyte lines. *J. Immunol.* **131**:2178-2183.