

AN OBSERVATION CONCERNING THE MECHANISM OF RENAL CYST FORMATION.* By Lawrence R. Freedman, *Department of Internal Medicine, Yale University School of Medicine.*

The present report describes the experimental production of renal cysts following localized thermal injury of the papilla (or low medulla) of the normal rabbit kidney.

MATERIALS AND METHODS

A technique of producing intrarenal obstruction in the rabbit has been described in detail elsewhere.³ In brief, it consists of the insertion of a wire through the surface of the kidney into the papilla or low medulla. Cautery current is then applied, producing a localized thermal injury about 2 mm. in diameter around the tip of the wire. The result is obstruction of a wedge of nephrons. The tubular changes after one week consist of tubular dilatation and atrophy.³ Glomeruli are not altered. After two to four months, atrophic tubules predominate, but many dilated tubules lined with flattened epithelium can still be found. In some areas there is dilatation of Bowman's capsule to approximately twice its normal diameter.

A modification of this procedure was employed in a group of rabbits in order to produce renal insufficiency. Three burns were placed in the papilla of the left kidney of eight animals. After two to four months the kidneys were removed for histological and bacteriological study and blood samples obtained for the determination of urea nitrogen (BUN).

RESULTS

Seven of the eight injured kidneys showed a variety of scars similar to those found following a single medullary burn and characterized predominantly by severe focal renal atrophy (Fig. 1). The eighth kidney was enlarged rather than contracted and on section had the appearance of the cut surface of a grapefruit (Fig. 2). Microscopically this kidney was seen to consist of a network of greatly distended tubules with recognizable cortex limited to a rim beneath the capsule (Fig. 3). There was a large scar occupying the area where one would have expected to find papilla. Areas of bone formation were seen within this papillary scar. Culture of half of this kidney was sterile. The other kidney of this animal had been removed one week prior to examination and was normal. The BUN determined at the time of sacrifice was 84 mg.%, indicating that this kidney retained some function, since complete loss of functioning renal tissue in a rabbit is associated with death in about three days. Other kidneys showed gross and microscopic evidence of severe atrophy, but had areas within them which were obviously intermediate stages (Fig. 4) of the extreme example of cyst formation illustrated in Figure 3. Culture of one half of each kidney removed was sterile in all instances.

* Supported by a grant from the U. S. Public Health Service (E-1850).

Received for publication 4 June 1960.

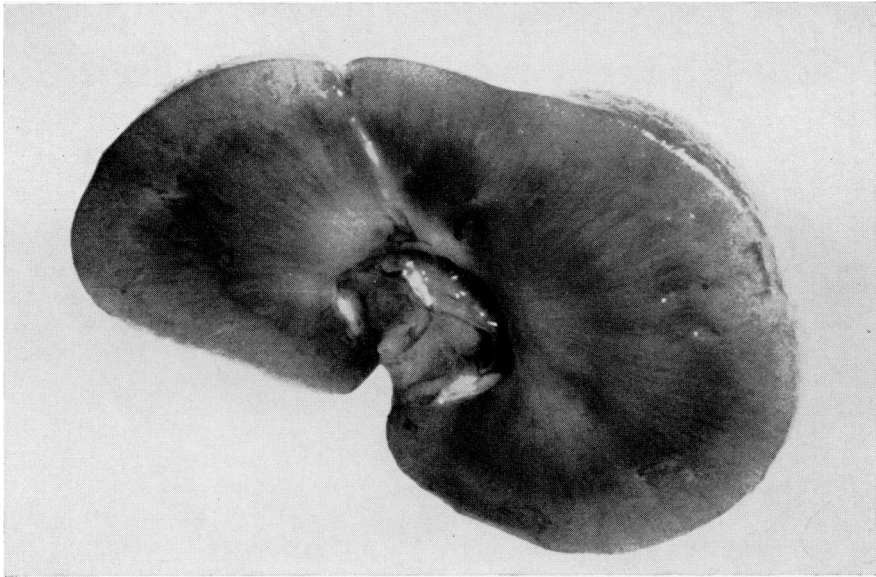


FIG. 1. Cut surface of rabbit kidney two months after the placement of three cautery burns in the medulla showing atrophic scars.

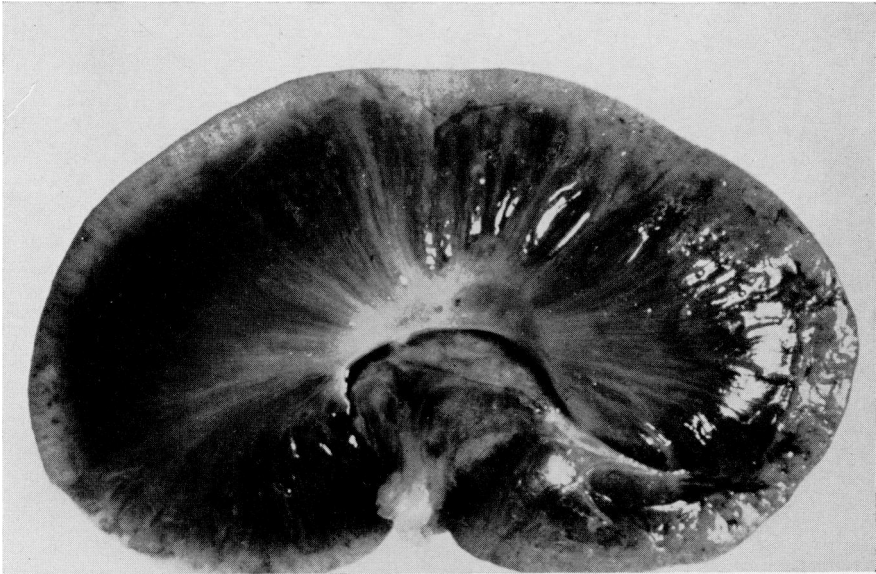

FIG. 2. Cut surface of rabbit kidney two months after the placement of three cautery burns in the medulla showing diffuse cystic change of the tubules.

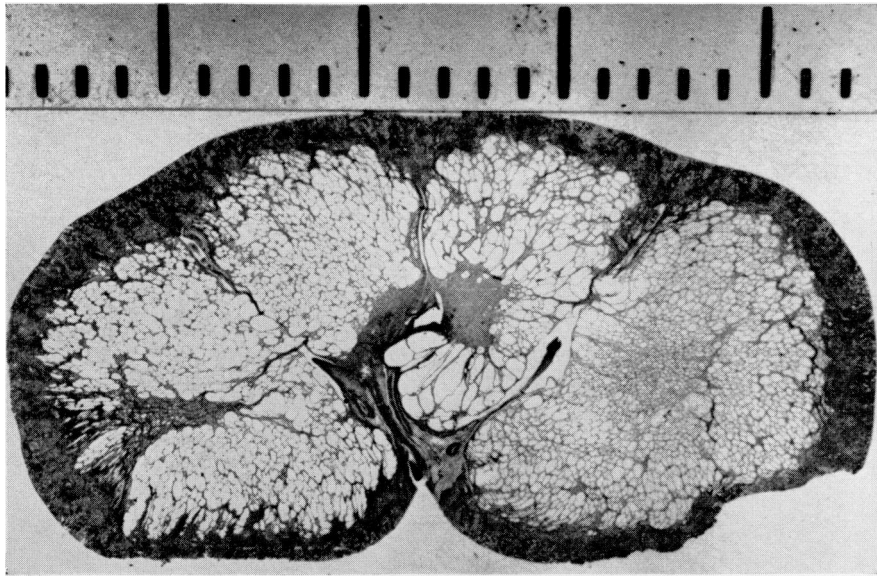


FIG. 3. Microscopic view of section of kidney shown in Figure 3. Each division equals 2 mm.

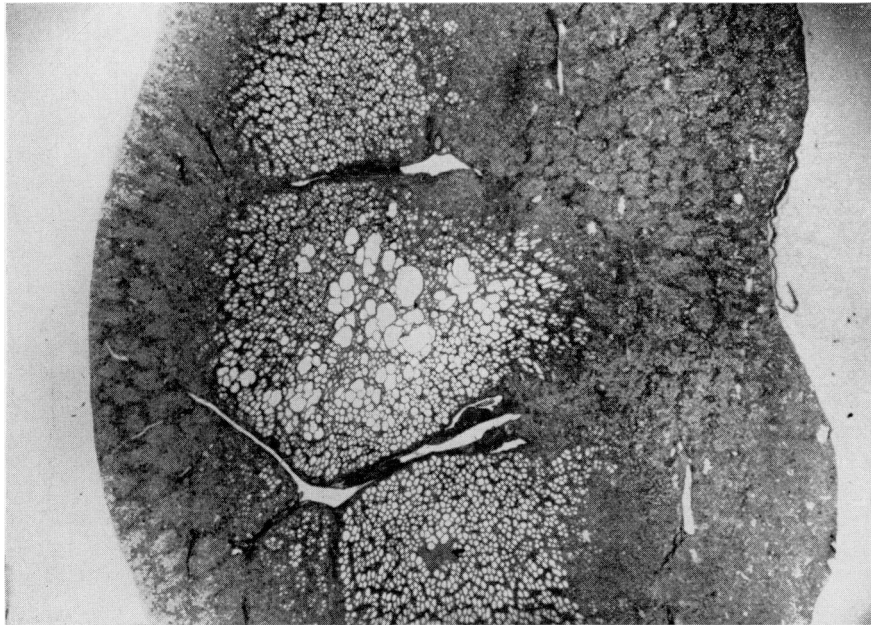


FIG. 4. Low power microscopic view of kidney two months after the placement of three cautery burns in the medulla showing atrophy as the predominant change with some localized cyst formation. (4.5x)

DISCUSSION

Injury to the renal papilla of the rabbit kidney results in two types of change involving the renal tubules: atrophy and cyst formation. Atrophy is the most common lesion, although, examples of localized cyst formation were seen scattered in a random fashion within the obstructed areas. Cyst formation involving the entire kidney was seen once and this kidney resembled very closely the type of polycystic kidney seen in infants.¹ Both the atrophic and cystic kidneys were capable of limited function.

These observations are thought to be of interest for two reasons. The first relates to the theories of production of renal cysts. Whatever the mechanism may be in man, in the rabbit it would appear that damage to the terminal portion of a normal nephron may result in extreme cystic dilatation. This cystic nephron is probably capable of limited function. Indeed, function has also been demonstrated in cystic nephrons in man.²

The second point of interest is that a single injury may result in either atrophy or dilatation of nephrons, changes which superficially appear to be quite dissimilar. The fact that they might result from the same type of damage however, raises the interesting possibility that in man the factors leading to the development of polycystic kidney and renal atrophy (hypoplasia) may be related. Some support for this argument is obtained from the observation that cyst formation is quite common in hypoplastic human kidneys³ just as it was in the atrophic rabbit kidneys described above. It remains for future study to determine the conditions which decide the type of response to be exhibited by specific nephrons following an obstructive lesion.

SUMMARY

Thermal injury of the papilla of normal rabbit kidneys as a rule results in severe atrophy of nephrons with occasional examples of isolated cyst formation. A single instance of complete cystic transformation of the kidney was produced. This kidney was demonstrated to have limited function.

Whatever the cause of renal cyst formation in man, such cysts may be produced in the rabbit by injury to the terminal portion of normal nephrons. It is of interest that injury to the renal papilla may result either in severe atrophy or extensive dilatation of the nephrons tributary to the obstruction. The suggestion is offered that this may have a bearing on the knowledge of the pathogenesis of cyst formation sometimes encountered in human hypoplastic kidneys.

REFERENCES

1. Allen, A. C.: *The kidney. Medical and surgical diseases*. New York, Grune and Stratton, 1951, pp. 92, 93.
2. Bricker, N. S. and Patton, J. F.: Cystic disease of the kidneys. A study of dynamics and chemical composition of cyst fluid. *Amer. J. Med.*, 1955, 18, 207-219.
3. Rocha, H., Guze, L. B., Freedman, L. R., and Beeson, P. B.: Experimental pyelonephritis. III. The influence of localized injury in different parts of the kidney on susceptibility to bacillary infection. *Yale J. Biol. Med.*, 1958, 30, 341-354.