

Two Cases of *Mycobacterium microti*-Derived Tuberculosis in HIV-Negative Immunocompetent Patients

Stefan Niemann,* Elvira Richter,* Helga Dalügge-Tamm,†
Hejko Schlesinger,‡ Dietrich Graupner,‡ Bodo Königstein,§
Gudrun Gurath,¶ Ulf Greinert,* and Sabine Rüsç-Gerdes*

*National Reference Center for Mycobacteria, Borstel, Germany;

†Niedersächsisches Landesgesundheitsamt, Hannover, Germany; ‡Praxis,

Rötenberg, Germany; §Gesundheitsamt Rottweil, Rottweil, Germany,

¶Gemeinschaftspraxis Labor Clotten, Freiburg, Germany

We describe two cases of *Mycobacterium microti* infection causing pulmonary tuberculosis (TB) in HIV-seronegative immunocompetent patients in Germany. The isolates were identified as *M. microti* of the llama and vole types, according to spoligotype patterns. Our data demonstrate that *M. microti* can cause severe pulmonary TB in immunocompetent patients.

Mycobacterium microti, which causes tuberculosis (TB) mainly in small rodents such as voles, has been considered nonpathogenic for humans (1-3). Considering the DNA sequences of the 16S rRNA gene and the 16S-to-23S internal transcribed spacer region, *M. microti* proved to be a member of the *Mycobacterium tuberculosis* complex. Primary isolation and differentiation by classical biochemical tests are complicated by the very slow growth of this species (1,2). The new molecular spoligotyping method has recently permitted the simultaneous detection and typing of *M. microti* (1). This technique has been applied in two retrospective studies of *M. microti* infections in the Netherlands and England, enabling identification of cases in llamas, cats, and ferrets, as well as in five humans, only one of whom was described as immunocompetent (1,4). A case in an HIV-positive patient has been described in detail by Foudraine and co-workers (5). We report two cases of *M. microti* infection causing pulmonary TB in Germany, representing the second and third reported cases in HIV-seronegative immunocompetent patients.

Case 1

In January 1999, an HIV-seronegative 53-year-old man was hospitalized with a solid lesion in the upper lobe of the right lung, first identified in 1989. Computer tomography (CT) of the chest showed two dense infiltrates, 3x2 cm and 6x5 cm, without cavitation. The patient reported nonproductive cough and weight loss of 3 kg in 2 years. He was a cigarette smoker (approximately 1 pack/day for 30 years). Chronic abuse of alcohol began in 1992, after the initial diagnosis. An elevated erythrocyte sedimentation rate was the only abnormal laboratory finding. A tuberculin skin test (5 units of PPD) had a 7-mm induration. Sputum and bronchoalveolar lavage fluid were smear negative for acid-fast bacilli (AFB). Tuberculous granuloma were found in bronchial and peribronchial lung tissue obtained by bronchoscopy; however, no AFB or signs of malignancy were detected. Anti-TB therapy was started with isoniazid, rifampin, and pyrazinamide. The patient's clinical condition improved, and by November 1999 the pulmonary infiltrate had almost completely resolved. In interviews, the patient said that he had no extended exposure to household or farm animals. He lives in his own apartment in a town (population 14,000) in central Germany. No tuberculin skin test-positive contact persons have been identified.

Address for correspondence: Stefan Niemann, Forschungszentrum Borstel, National Reference Center for Mycobacteria, Parkallee 18, D-23845 Borstel, Germany; Fax: (49)-4537-188311; e-mail: sniemann@fz-borstel.de.

One mycobacterial culture was grown from bronchoalveolar lavage fluid in liquid media (12B vial, BACTEC460TB, Becton Dickinson Microbiology Systems, Cockeysville, MD) after 5 weeks of incubation. Limited growth was observed on Stonebrink medium (small colonies visible after >6 weeks of incubation), and no growth was detected on Loewenstein-Jensen medium. The isolate was identified as *M. tuberculosis* complex by gene probes (ACCUProbe, GenProbe, San Diego, CA) and as llama-type *M. microti* by the characteristic spoligotype pattern (Figure 1) (1). After reculturing, the strain showed normal growth in BACTEC 460TB (Becton Dickinson), allowing drug-susceptibility testing that indicated susceptibility to isoniazid, rifampin, pyrazinamide, ethambutol, and streptomycin. Because of the limited growth on solid media, classical biochemical tests could not be performed. The bacteria showed normal cell morphologic features in several Ziehl-Neelsen-stained microscopic preparations from cultures.

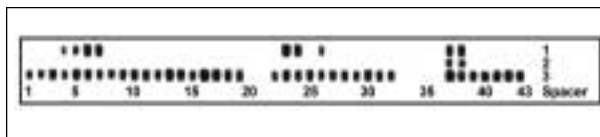


Figure 1. Spoligotype patterns of the isolates obtained from patient 1 (lane 1) and patient 2 (lane 2) and control strain H37Rv (lane 3)

Case 2

A severely ill 58-year-old man sought medical attention in April 1999. The patient was in poor general condition, with weight loss (> 8 kg in the last year), night sweats, occasional fever, fatigue, and productive cough. He had a history of smoking (10 cigarettes/day for at least 20 years) and diabetes mellitus (diagnosed in 1980). A chest X-ray in December 1983 showed no abnormalities of the heart and lung. The current illness had onset in early 1998, after which the patient was examined intensively by a number of physicians. Several X-rays of the chest indicated pulmonary disease with progression to bilateral lesions, predominantly in the right lung (Figure 2a); however, diagnosis was inconclusive. In September 1998, the general condition of the patient had so deteriorated that he was unable to work. Cytopathologic examination of a hemorrhagic pleural effusion in October 1998 showed lymphocytic-granulocytic pleuritis. X-ray examination

(Figure 2b) and CT scan (data not shown) in April 1999 showed bilateral fibrosis of the lung parenchyma with a partial honeycomb pattern. Comparison with the X-ray in early 1998 documented a clear progression of the changes in the right lung.

Laboratory values were normal except for a slightly elevated leukocyte count. A tuberculin skin test (Mendel-Mantoux) and tests for HIV-1 and HIV-2 were negative. Fiberoptic bronchoscopy showed chronic atrophic bronchitis without signs of malignancy. For the first time, a bronchial secretion specimen was smear positive for AFB, and severe pulmonary TB was diagnosed. After treatment was begun with isoniazid, ethambutol, rifampin, streptomycin, and pyrazinamide, the patient's clinical condition improved, he recovered his normal weight, and the clinical symptoms resolved. Despite restrictive alterations in ventilatory function that correlated with radiologic and histomorphologic findings, the patient's condition improved and he has returned to work. An X-ray in January 2000 showed a consistent picture of the fibrosing lung disease.

One liquid culture (MGIT, Becton Dickinson) from a gastric aspiration obtained in April 1999 was positive for Mycobacteria in mid-June after 9 weeks of incubation. *M. tuberculosis* complex-specific gene probes (ACCUProbe) were positive. By the spoligotyping method, the isolate was unequivocally identified as vole-type *M. microti* (Figure 1). In contrast to the llama-type isolate, even after reculturing, the vole isolate showed very slow growth in liquid media and no growth on solid media, making drug-susceptibility testing and biochemical characterization impossible. In the Ziehl-Neelsen-stained microscopic preparation of both the bronchial secretion and several cultures, the bacterial cells showed normal morphologic features. In subsequent interviews, the patient said that he had not been exposed to household or farm animals. He lives in a village in a rural area in southern Germany. No tuberculin skin test-positive contact persons have been identified.

Conclusions

We describe the first two cases of pulmonary TB due to *M. microti* of the llama and vole types, respectively, in German patients. *M. microti* caused severe pulmonary TB with extensive histopathologic changes in

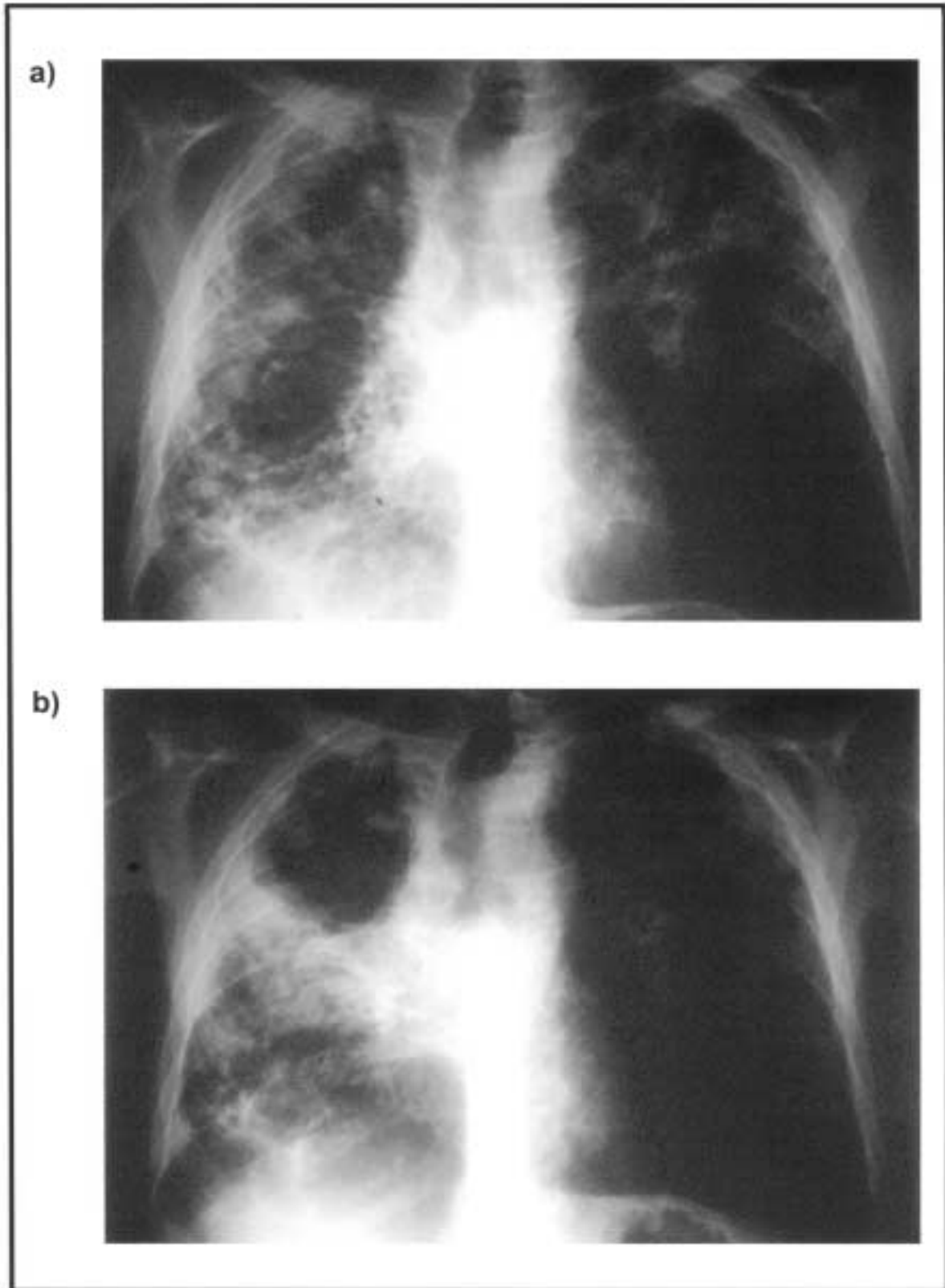


Figure 2. X-rays obtained in February 1998 (a) and April 1999 (b), of the chest of a 58-year-old patient.

the lung of an HIV-seronegative immunocompetent patient. As in the case reported by van Soolingen et al. (1), our data confirm the potential of *M. microti* to cause clinical illness in immunocompetent patients.

In contrast to the case reported by Foudraïne and co-workers (5), both patients responded well to treatment with isoniazid, rifampin, and pyrazinamide or isoniazid, ethambutol, rifampin, streptomycin, and pyrazinamide, which indicates that regular anti-TB therapy may be appropriate for patients with *M. microti* infection.

As reported previously (1), primary isolation and biochemical characterization of *M. microti* are complicated by the slow growth of the bacteria. The resultant diagnostic delay, especially if atypical pulmonary lesions are present, may lead to false diagnosis and inadequate treatment. Thus, infection with *M. microti* should be considered in the differential diagnosis of patients with typical signs of TB but no bacteriologic proof. In these cases, spoligotyping is a fast, reliable technique for identification and differentiation of *M. microti* and other members of the *M. tuberculosis* complex (1,6,7).

The vole-type strain showed only limited growth during primary isolation and reculturing, impeding further characterization. In contrast, our results indicate that the llama-type *M. microti* may show normal growth in BACTEC 460TB. Moreover, we demonstrated that drug-susceptibility testing of clinical isolates of this subtype may be performed in liquid media.

Transmission from rodents to humans has been discussed as a possible pathway for the acquisition of *M. microti* infection (1). Although patients were interviewed, no source of infection could be identified.

Because of the difficulty with primary isolation and differentiation, the prevalence and clinical importance of *M. microti* may have been underestimated. Further studies based on molecular methods are needed to characterize the epidemiology of this emerging human pathogen.

Acknowledgments

We thank B. Koch, I. Radzio, B. Schlüter, and A. Zyzik for excellent technical assistance and E. Vollmer for help with preparation and revision of the manuscript.

Parts of this work were supported by the Robert Koch Institut, Berlin, Germany.

Dr. Niemann is working in a postdoctoral position at the German National Reference Center for Mycobacteria, Research Center Borstel, Borstel, Germany, where he is responsible for molecular characterization and typing of mycobacteria. His research interests include the characterization of the *Mycobacterium tuberculosis* complex by molecular techniques and the epidemiology of tuberculosis by DNA fingerprinting.

References

1. Van Soolingen D, van der Zanden AG, de Haas PE, Noordhoek GT, Kiers A, Foudraïne NA, et al. Diagnosis of *Mycobacterium microti* infections among humans by using novel genetic markers. *J Clin Microbiol* 1998;36:1840-5.
2. Wayne LG, Kubica GP. The Mycobacteria. In: Sneath PHA, Holt JG, editors. *Bergey's manual of systematic bacteriology*. Vol. 2. Baltimore, Md: The Williams Co; 1986:1435-57.
3. Wells AQ, Oxon DM. Tuberculosis in wild voles. *Lancet* 1937;i:1221.
4. Kremer K, van Soolingen D, van Embden J, Hughes S, Inwald J, Hewinson G. *Mycobacterium microti*: more widespread than previously thought. *J Clin Microbiol* 1998;36:2793-4.
5. Foudraïne NA, van Soolingen D, Noordhoek GT, Reiss P. Pulmonary tuberculosis due to *Mycobacterium microti* in a human immunodeficiency virus-infected patient. *Clin Infect Dis* 1998;27:1543-4.
6. van Soolingen D, Hoogenboezem T, de Haas PE, Hermans PW, Koedam MA, Teppema KS, et al. A novel pathogenic taxon of the *Mycobacterium tuberculosis* complex, Canetti: characterization of an exceptional isolate from Africa. *Int J Syst Bacteriol* 1997;47:1236-45.
7. Niemann S, Richter E, Rüscher-Gerdes S. Differentiation among members of the *Mycobacterium tuberculosis* complex by molecular and biochemical features: evidence for two pyrazinamide susceptible subtypes of *M. bovis*. *J Clin Microbiol* 2000;1:152-7.