

Plasmodium vivax Ookinetes in Human Peripheral Blood

BETTY A. HUMMERT*

Microbial Diseases Laboratory, Division of Communicable Disease Control, California Department of Health Services, Berkeley, California 94704-1011

Received 8 April 1994/Returned for modification 31 May 1994/Accepted 12 July 1994

Microscopic examination of a peripheral blood smear revealed ookinetes of *Plasmodium vivax*. This unusual finding was probably due to an excessive delay between blood collection and smear preparation. Ookinete formation normally occurs in the mosquito gut. When seen in blood smears, it can cause confusion and misidentification of the parasite.

In the natural life cycle of the malarial parasites that infect humans, production of ookinetes occurs in the mosquito gut (1). When a mosquito ingests mature gametocytes in its blood meal, the gametocytes transform into gametes within 15 min (8). The macrogametocytes (female) transform into only one macrogamete each, while exflagellation of a microgametocyte (male) produces several highly motile, very slender microgametes. A microgamete then penetrates a macrogamete, and the resulting zygote transforms into a fusiform, motile ookinete within 24 h (10).

The usual *Plasmodium* forms seen in human peripheral blood smears include the rings, trophozoites, and schizonts of the asexual, intraerythrocytic cycle and the macrogametocytes and microgametocytes of the sexual cycle. While exflagellation normally occurs in mosquitoes, it has been known for a long time that it can occur in vitro. In 1897, MacCallum (7) reported seeing gametocytes become flagellated forms while examining infected human blood under a microscope. Further, because exflagellating microgametocytes produce a visible disturbance of the erythrocytes immediately surrounding them (8), placing a drop of diluted, anticoagulated blood on a microscope slide and observing it for exflagellating microgametocytes is now the method used to judge the maturity of gametocytes. Thus, although we know that exflagellation occurs in vitro, the presence of microgametes on stained peripheral blood smears has rarely been reported (4, 11). Presented here is a case of *Plasmodium vivax* malaria in which exflagellated microgametocytes and ookinetes were found on a peripheral blood smear.

In April 1991, an 8-year-old girl from India was seen in a doctor's office. Since her symptoms were suggestive of malaria, blood was drawn into a collection tube containing EDTA. The blood remained in the tube from late afternoon until late that night, when a smear was prepared at a local laboratory. The smear was stained with Giemsa stain, and the parasites were identified at the laboratory as *P. falciparum* on the basis of the presence of what appeared to be crescent-shaped gametocytes. The smear was then forwarded to the Microbial Diseases Laboratory for species confirmation. Examination of the smear revealed typical intraerythrocytic asexual stages of *P. vivax* in enlarged erythrocytes with Schuffner's stippling, as well as exflagellating microgametocytes and microgametes (Fig. 1A). There were also forms that appeared to be either macrogametocytes or zygotes (2).

The fusiform cells were recognized as not being *P. falcipa-*

rum gametocytes, but since these forms had not been seen previously, they could not be immediately identified. They did resemble a drawing of the ookinete stage in the mosquito phase of the life cycle (12). The fusiform cells ranged in length from 13 to 16 μm and in width from 3.5 to 5 μm . The shape varied from slender to stout and from straight or slightly curved to hooked. Most had an area at one end that stained darker than the cytoplasm and appeared granular, with the nucleus centrally located and what appeared to be a small vacuole. The identification of these ookinetes was kindly confirmed by John E. Williams (London School of Hygiene and Tropical Medicine), who pointed out that the smear revealed the entire sequence of ookinete development (Fig. 1B to F). There were several of the younger forms, called "retorts" because of their resemblance to the distillation flask of the same name, as well as progressively more mature forms (2). Figure 1 shows some of the developmental stages, as well as a typical mature ookinete with apical pigment, a central nucleus, and a posterior vacuole.

Because this blood had not been exposed to air and was kept for less than 9 h before the smear was made, the question arose as to whether it was possible for the mosquito stages to develop within the elapsed time and under the conditions in which this specimen had been handled. Researchers have reported that exflagellation in peripheral blood requires exposure to ambient air, which causes a decrease in pCO_2 with a consequent rise in pH from the normal 7.4 to at least 7.7 (3). In addition, protocols used for the culture of ookinetes specify an 18- to 24-h incubation period (10). However, it has now been shown that *P. falciparum* gametocytes, at least, exflagellate at room temperature at pH 7.4 as long as the human serum concentration exceeds 1.5% (9) and that ookinetes form within 8 h in culture (2).

To my knowledge, this is the first report of ookinetes in a smear of human peripheral blood. Rather than being a clinical oddity, this case may be an indication that blood specimens are not being handled properly. Our laboratory, which identifies an average of six to eight malaria cases per month, has noticed an increase in the frequency with which we see microgametes on thin blood smears. In the first 6 months of 1994, we have seen five cases with microgametes on the peripheral blood smear. On inquiry, we usually find that the blood has been drawn into tubes containing EDTA and that the smears have not been made until some time, often 1 to 2 h, later. An excessive delay between blood collection and smear preparation can lead to deterioration of the usual blood stage forms and production of unusual mosquito stage forms, both of which may lead to erroneous species identification. Two of the cases in which microgametes were identified in 1994 were referred to our

* Mailing address: California Department of Health Services, Microbial Diseases Laboratory, 2151 Berkeley Way, Berkeley, CA 94704-1011. Phone: (510) 540-2242. Fax: (510) 540-2374.

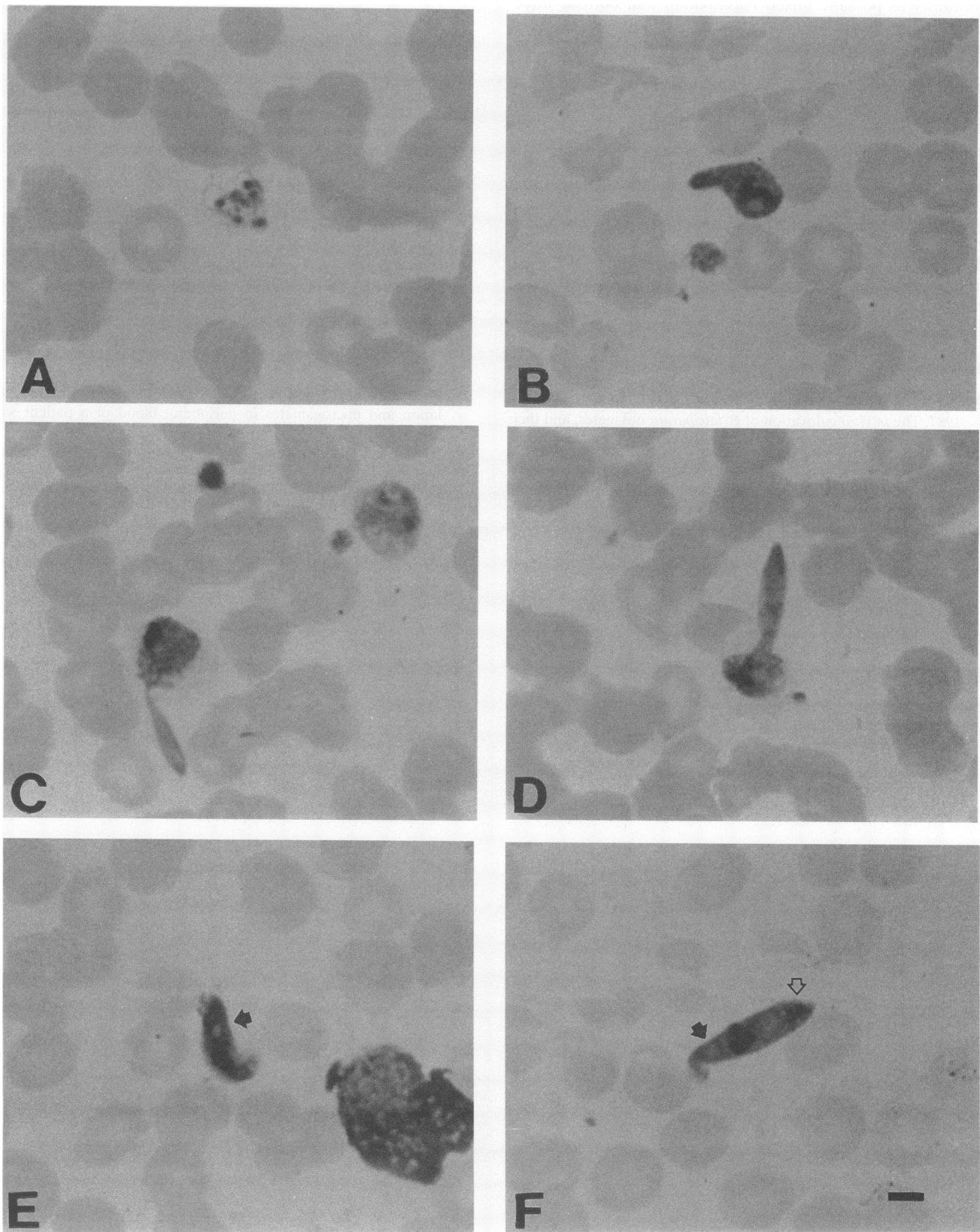


FIG. 1. Giemsa stain of a patient's peripheral blood showing the development of *P. vivax* ookinetes (magnification, $\times 1,000$). Panels: A, exflagellating microgametocyte; B, very early retort form; C and D, progressively older retort forms; E, ookinete with vacuole (solid arrow) anterior to the nucleus; F, mature ookinete with vacuole (solid arrow) posterior to the nucleus. The apical pigment is visible (open arrow). Bar, 4 μm .

laboratory as possible mixed *Plasmodium* and *Borrelia* infections. It appears that microgametes can be mistaken for spirochetes by microscopists unfamiliar with their morphology.

The importance of correct collection of blood specimens for malaria diagnosis cannot be overemphasized. In standard procedures (5, 6), the preferred method is to make both thin and thick smears directly from blood collected by finger stick. If this is not practical, good smears can be made from blood drawn into EDTA as long as they are made soon after the blood is collected, preferably within 30 min but certainly within 1 h.

As can be seen from this case, ookinetes can form under conditions that may be encountered in clinical laboratories. Microscopists need to be aware of the possibility of finding these unusual forms of malaria parasites in peripheral blood smears.

REFERENCES

1. Beaver, P. C., R. C. Jung, and E. W. Cupp (ed.). 1984. Clinical parasitology, 9th ed., p. 175–176. Lea & Febiger, Philadelphia.
2. Carter, E. H., A. Suhrbier, P. J. A. Beckers, and R. E. Sinden. 1987. The *in vitro* cultivation of *P. falciparum* ookinetes, and their enrichment on Nycodenz density gradients. *Parasitology* **95**:25–30.
3. Carter, R., and M. M. Nijhout. 1977. Control of gamete formation (exflagellation) in malaria parasites. *Science* **195**:407–409.
4. Gerber, J. E., T. E. Ukena, L. Cote, J. M. Wyllie, and W. C. Winn, Jr. 1981. Exflagellation of malarial parasites in human peripheral blood. *J. Clin. Microbiol.* **13**:236–237.
5. Isenberg, H. D. (ed.). 1992. Clinical microbiology procedures handbook, vol. 2, p. 7.8.2.1. American Society for Microbiology, Washington, D.C.
6. Long, E. G. 1988. Malaria, p. 911–928. In A. Balows, W. J. Hausler, Jr., M. Ohashi, and A. Turano (ed.), *Laboratory diagnosis of infectious diseases, principles and practice*, vol. I. Springer-Verlag, New York.
7. MacCallum, W. G. 1897. On the flagellated form of the malarial parasite. *Lancet* **ii**:1240–1241.
8. Nijhout, M. M., and R. Carter. 1978. Gamete development in malaria parasites: bicarbonate-dependent stimulation by pH *in vitro*. *Parasitology* **76**:39–53.
9. Ogwan'g, R. A., J. K. Mwangi, J. Githure, J. B. O. Were, C. R. Roberts, and S. K. Martin. 1993. Factors affecting exflagellation of *in vitro*-cultivated *Plasmodium falciparum* gametocytes. *Am. J. Trop. Med. Hyg.* **49**:25–29.
10. Warburg, A., and I. Schneider. 1993. *In vitro* culture of the mosquito stages of *Plasmodium falciparum*. *Exp. Parasitol.* **76**:121–126.
11. Weinstein, M. P., and D. V. Alcidi. 1982. Occurrence of exflagellation and microgametes in peripheral blood of a patient with malaria. *J. Infect. Dis.* **146**:448.
12. Wilcox, A. 1960. Manual for the microscopical diagnosis of malaria in man. U.S. Public Health Service publication no. 796. U.S. Government Printing Office, Washington, D.C. (Out of print.)