

Pathogenesis of Change in the Upper Respiratory Tracts of Turkeys Experimentally Infected with an *Alcaligenes faecalis* Isolate

JOHN G. GRAY,^{1†*} JOHN F. ROBERTS,¹ RICHARD C. DILLMAN,² AND DONALD G. SIMMONS²

Department of Zoology, School of Agriculture and Life Sciences,¹ and Department of Microbiology, Pathology and Parasitology, School of Veterinary Medicine,² North Carolina State University, Raleigh, North Carolina 27650

Received 18 May 1983/Accepted 11 July 1983

The course of changes within the upper respiratory tracts of turkey poultts experimentally infected with *Alcaligenes faecalis* was studied. The initial change observed (5 days post-inoculation) was colonization of the upper respiratory tract by the bacterium. Changes in the nasal turbinates and trachea were first apparent as a focal loss of cilia but subsequently developed into a general loss of cilia (11 days post-inoculation). Eventually, the entire ciliated epithelial layer in the cranial region of the trachea was lost (13 days post-inoculation). With the loss of cilia and ciliated cells, a highly viscous mucus was able to accumulate in the anterior one-half to two-thirds of the trachea. In addition, changes in the gross structure of the trachea (flaccid trachea) were observed in all poultts inoculated with *A. faecalis*. There was an apparent gradation in the severity of these changes from severe in the cranial region of the trachea to mild in the region just anterior to the bronchial bifurcation. The observations resulting from *A. faecalis* infection indicated two major tracheal changes responsible for the chronic and sometimes severe nature of this disease. These changes included a loss of ciliary activity and a flaccid trachea which together resulted in the accumulation and stasis of mucus and tracheal collapse.

The *Alcaligenes faecalis* strain responsible for rhinotracheitis in turkeys was first described by Filon et al. (4) in Canada and by Hinz et al. (6) in West Germany as a *Bordetella bronchiseptica*-like bacterium. This description resulted from the similarity between the morphologies and biochemical properties of these two bacteria and the natures of the diseases associated with them. Morphologically, *A. faecalis* and *B. bronchiseptica* are small, gram-negative rods and are peritrichous flagellated. Biochemically, the two bacteria are nearly identical, their differentiation being accomplished primarily by the urease test. *B. bronchiseptica* has been distinguished by its urease production and *A. faecalis* by its negative reaction in the urease test (12).

The pathological changes associated with *B. bronchiseptica* in canine bordetellosis (kennel cough) and those caused by *A. faecalis* in rhinotracheitis of turkeys have some characteristics in common. Coughing (called snicking in turkeys) has been associated with the acute stage of the diseases and lasts only 1 to 2 weeks. In the two diseases, both bacteria become fixed to the

cilia of the respiratory epithelium and multiply without restriction. In addition, neither bacteria appear to cause damage to other tissue, and the pathological changes caused are neither deep-seated nor general (1, 2, 8, 13; unpublished observations). However, differences include neutrophilic infiltration of the epithelial respiratory mucosa and involvement of the bronchioles leading to bronchopneumonia, which has been associated with *B. bronchiseptica* infection in dogs (1). Turkeys infected with *A. faecalis* do not demonstrate an inflammatory response or lower respiratory tract involvement (3, 10). Additionally, *A. faecalis* infection causes damage to the superficial epithelium primarily in the anterior region of the trachea, whereas *B. bronchiseptica* damages the ciliated cells throughout the respiratory tract (2, 10; unpublished observations).

A. faecalis strains in general, unlike *B. bronchiseptica*, are not considered to be primary pathogens. In humans, *A. faecalis* strains have been isolated from the ear, blood, sputum, urine, mouth, wounds, peritoneal fluid, feces, cerebrospinal fluid, and abscesses (7); however, they are considered secondary pathogens. Controlled laboratory studies demonstrate that the

† Present address: Box 3020, Duke Medical Center, Duke University, Durham, NC 27710.

A. faecalis strain used in this study is a primary pathogen. Turkeys infected with this *A. faecalis* strain develop the following clinical signs: mucus at the external nares, a foamy discharge around the eye, snicking (coughing), mouth breathing, and, in severe cases, dyspnea. Gross pathological changes include nares and tracheae filled with foamy mucus, flaccid tracheae, and, in the field, an occasional tracheal plug (3; M. E. Bergeland, W. V. Knudtson, and I. Stotz, *Annu. Proc. N. Central Poult. Dis. Conf.* 28th, p. 28, 1977). Microscopic changes from field outbreaks and laboratory studies include distension of mucus glands in the nasal turbinate and trachea and loss of cilia and necrosis of the more superficial epithelial cells, with depletion of mucus glands in the trachea (3, 4, 6). The present study was undertaken to determine the pathogenesis of the changes induced by *A. faecalis* and their specific association with the disease process.

MATERIALS AND METHODS

Turkeys. One-day old poults were obtained from a commercial source (Goldsboro Milling Co., Goldsboro, N. C.) for use in this study. Six positive-pressure Horsfall isolation units were used. Two of these units were used to house uninoculated controls (each unit containing 20 poults), and four were used for *A. faecalis*-inoculated poults (each unit containing 25 poults). The poults were fed with commercial feed (Goldsboro Milling Co.) and tap water ad libitum.

A. faecalis. The *A. faecalis* strain used in this study was isolated from a natural outbreak of rhinotracheitis and was shown to cause severe clinical rhinotracheitis when inoculated into turkey poults maintained under laboratory conditions (9-11). Stock cultures of the bacterium were maintained on brain heart infusion agar slants. The broth culture of *A. faecalis* used to inoculate turkeys was prepared by loop inoculation from a stock slant into a tube containing 5 ml of brain heart infusion broth. The culture was grown with vigorous aeration at room temperature for 18 h. Numbers of CFU per milliliter were determined after plating serial dilutions on brain heart infusion agar plates and incubation at 37°C for 28 h.

Turkey inoculation. One-day-old turkey poults were inoculated intranasally by pipetting 0.05 ml of a bacterial suspension containing 10^6 CFU in brain heart infusion broth onto the nasal opening on one side. The inoculum was drawn into the area of the turbinates by normal inspiration.

Clinical course of disease. The clinical course of the disease was assessed by examining five randomly selected turkey poults from the *A. faecalis*-infected group and two from the control group at each time period studied for predetermined respiratory signs associated with rhinotracheitis. These predetermined respiratory signs included mucus at the external nares, mouth breathing, foamy discharge around the eye, and dyspnea.

Gross Examination. Turkey poults were killed at each time period selected, and their turbinates and tracheae were removed. The turbinates were examined for the presence of excess mucus. The portion of

trachea removed included the cranial region just beneath the epiglottis and distal to the area of bronchial bifurcation. The tracheae were stripped of surrounding tissue and examined for gross structural changes. Portions of tracheae that remained after histological and bacteriological sampling were bisected longitudinally. These longitudinal sections were examined for the presence, quality, and distribution of mucus.

Histology. Tissues were collected from two uninoculated controls and five *A. faecalis*-inoculated poults at each of the selected times. These tissues included the nasal turbinates and trachea. Ten-millimeter sections were removed from the anterior, medial, and posterior regions of each trachea. A 5-mm section was cut from the middle of each 10-mm section and fixed in 10% phosphate-buffered neutral Formalin. Nasal turbinates were further processed by decalcification for 48 h in a commercial decalcifying solution (Decalcifying Fluid; Herleco Division, American Hospital Supply Co., Gibbstown, N. J.). Tissues were embedded in paraffin, sectioned at 5 μ m, stained with hematoxylin and eosin, and examined by light microscopy.

Determining bacterial load. The two (2.5-mm) tracheal portions remaining after removal of the histological sections were weighed and suspended in 2 ml of phosphate-buffered saline. To aid the dispersion of bacteria from these tissues, the luminal surfaces of the suspended tracheal sections were scraped with a scalpel and the entire suspension was vortexed at maximum speed for 10 s. The numbers of CFU per milliliter were determined by plating serial dilutions of the vortexed suspension in duplicate on brain heart infusion agar and incubating them at 37°C for 28 h. The numbers of CFU per milligram of tissue were determined and reported as the \log_{10} .

RESULTS

Clinical disease. During the 36-day experiment, uninoculated controls were free of clinical signs, and there were no deaths. In *A. faecalis*-inoculated poults, clinical signs, characterized by mucus in the external nares and mouth breathing, were first observed at 5 days post-inoculation (p.i.) and were observed in all poults examined by 7 days p.i. The clinical disease gradually became more severe, as evidenced by the increased number of poults which developed mouth breathing, foamy discharge around the eye, and dyspnea (Table 1). Of five infected poults that died, at least one was known to have died from complications arising during labored respiration (suffocation due to a collapsed trachea). The other four poults were found to have collapsed tracheae consistent with suffocation as a cause of death. The clinical signs were evident in all infected poults until 23 days p.i., when these signs began to subside. There were no observable clinical signs at 36 days p.i.

Gross pathological changes. Nasal turbinates and tracheae from uninoculated controls had no observable changes throughout the experiment. In *A. faecalis*-inoculated turkeys, the initial observable change was associated with the nasal

TABLE 1. Progression of clinical signs associated with *A. faecalis* infection

Days p.i.	No. of poult with following clinical signs ^a :			
	Mucus in nares	Mouth breathing	Dyspnea	Foamy conjunctivitis
5	2	1	0	0
6	3	0	0	0
7	5	0	0	0
9	5	3	0	1
11 ^b	5	4	0	2
13 ^c	5	3	1	1
15	5	4	1	1
19	5	5	2 ^d	2
23	4	2	1	2
27	4	4	2	1
32	2	3	0	0
36	0	0	0	0

^a Five poult were randomly selected at each time period studied and examined for the indicated respiratory signs associated with rhinotracheitis.

^b First day p.i. that tenacious mucus was seen in the trachea.

^c First day p.i. that flaccid tracheae were seen.

^d One poult died of suffocation.

turbinates. This change consisted of clear mucus in the area of the turbinate scroll and sinuses as early as 3 days p.i. Within 5 days p.i., the mucus had become thick and opaque and was present through 27 days p.i. (Table 2). Mucus in the cranial region of the trachea was evident as early as 6 days p.i., but 9 days elapsed before the number of tracheae with excess mucus was significant. The excess mucus persisted until 32 days p.i.; however, from 13 to 27 days p.i., the mucus present was highly viscous and sticky (tenacious mucus) (Table 2). The tenacious mucus was limited to the anterior one-half to two-thirds of the trachea and was rarely seen below this point. Tenacious mucus was probably the result of drying due to stasis of normally secreted mucus.

The most remarkable change in the trachea was first observed in the cranial region 13 days p.i. (Fig. 1). The dorsal surface appeared to be folding into the lumen (collapsed), partially occluding the trachea. The collapsed region observed on day 13 was preceded at 9 and 11 days p.i. by what appeared to be a softening of the tissue (flaccid) in the cranial region of the trachea. When these tracheae were placed in a petri dish, the supporting cartilage was unable to maintain an opening at the cranial end. The posterior end of the trachea maintained its rigid structure and remained open in all tracheae examined. At least one turkey poult died of suffocation caused by a combination of thick mucus and a collapsed trachea. The severity of this change decreased by 27 days p.i., but the

cranial half of the trachea retained a knotty, uneven appearance.

Histopathology. No histopathological changes were observed in the nasal turbinates or tracheae of uninoculated control poult (Fig. 2A). In the *A. faecalis*-inoculated poult, mucus was observed microscopically at day 3 p.i. in the scroll of the nasal turbinates but was not excessive. In nasal turbinate and tracheal sections examined before 9 days p.i., a focal loss of cilia was observed. By 9 to 11 days p.i., the focal loss had become more of a general loss of cilia, with large areas devoid of cilia evident. Changes occurring at 15 to 19 days p.i. included a general loss of cilia, degeneration and eventual loss of much of the superficial epithelial and goblet cells, and hyperplasia and squamous metaplasia evident in some areas (Fig. 2B-D). The most severe changes were observed in the cranial region of the trachea. There were moderate numbers of heterophiles (pseudoeosinophilic granulocytes) in focal areas throughout the tissue. By 23 days p.i., the nasal turbinates had apparently recovered from much of the lost superficial epithelial tissue, and cilia were again present (Table 3).

Pathological changes associated with the columnar epithelial cells resulted in loss of most of these cells from the anterior region of the tra-

TABLE 2. Progression of gross changes associated with *A. faecalis* infection

Days p.i.	No. of poult with following gross changes ^a :			
	Flaccid trachea	Excess tracheal mucus (cranial)	Tenacious tracheal mucus ^b	Excess turbinate mucus
5	0	0	0	5
6	0	2	0	5
7	0	1	0	5
9	1 ^c	3	0	5
11	5 ^c	5	2	5
13	5 ^d	5	5	5
15	5 ^d	5	5	5
19	5 ^d	5	5	5
23	5 ^d	5	4	5
27	4 ^e	5	5	5
32	2 ^e	3	2	5 ^f
36	2 ^e	2	0	4 ^f

^a A total of five poult were examined.

^b Tenacious mucus found primarily in the anterior one-half to two-thirds of the trachea.

^c Anterior 5 to 10 mm of trachea appeared flaccid.

^d Anterior 5 to 10 mm of trachea appeared to be on the verge of collapse.

^e Tracheae were more rigid but still had areas of distortions and had an overall knotty, uneven appearance primarily in the cranial half of the tracheae.

^f Mucus had changed from thick and opaque to light and clear.

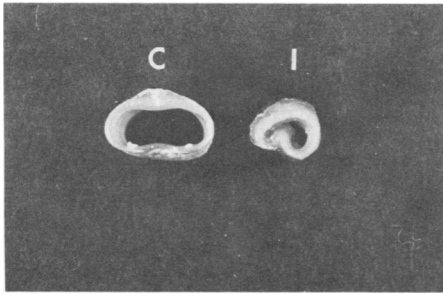


FIG. 1. Comparison of tracheae from an uninoculated control (C) and an *A. faecalis*-inoculated turkey (I) 13 days p.i. The 5-mm sections were from the cranial region. Involution is from the dorsal surface.

chea by 19 days p.i. (Fig. 2D). The medial tracheal sections usually had focal areas of ciliated cell loss and a general loss of cilia; however, large areas of ciliated cellular loss were rare. The distal tracheal sections had evidence of bacterial colonization and some loss of cilia, but little damage was observed in these sections.

The hyperplasia was initially observed at about the same period of time as the most severe loss of ciliated epithelial tissue and continued until evidence of tissue regeneration at 27 days p.i.

Bacterial colonization of the cilia was observed early (5 days p.i.) in the course of the infection, before damage to the superficial epithelial cells was evident (Fig. 2B). Mucus lining the tracheal lumen was observed to contain many bacteria. However, the bacteria were evenly dispersed and judged, therefore, to have been trapped by the mucus and not to be the result of colonization. By light microscopy, bacteria were not observed to be colonizing the basal epithelial layer of cells. However, a large number of bacteria are apparently associated with this tissue (Fig. 3).

Bacteriology. *A. faecalis* was not isolated from the nasal turbinates or tracheae of any of the uninoculated control poult but could be isolated, along with many contaminating bacteria, from nasal turbinates of inoculated poult as early as 1 day p.i. and as late as 36 days p.i. After 19 days p.i., *A. faecalis* was isolated only

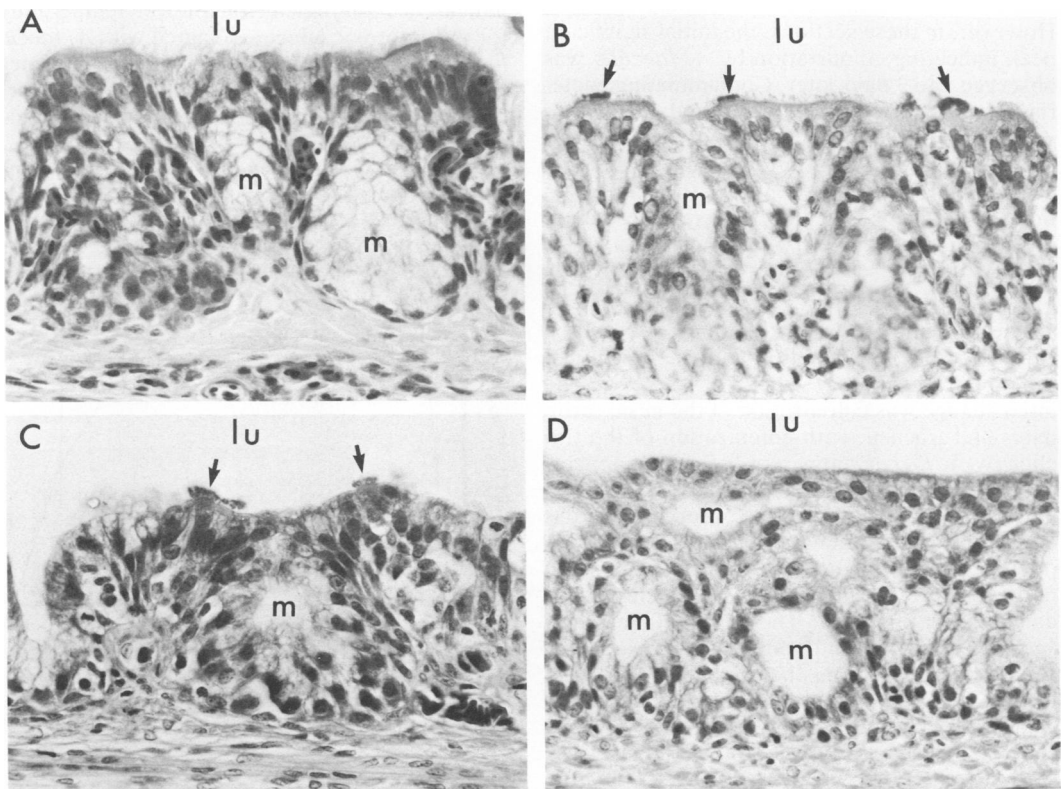


FIG. 2. Sections from the cranial region of trachea representing stages of *A. faecalis* infection. Tracheal tissues from a control 19-day-old turkey (A) and from *A. faecalis*-infected turkeys at days 9 (B), 13 (C), and 19 (D) p.i. are shown. Arrows indicate areas where cilia are colonized by *A. faecalis*. lu, Tracheal lumen; m, mucus glands. In (D), the morphological appearance of the cells at the luminal surface indicates squamous metaplasia. In addition, the mucus glands in this section appear to be depleted. Magnification, $\times 600$.

TABLE 3. Time frame of microscopic tracheal changes in *A. faecalis*-inoculated poult

Microscopic change	Days p.i. change seen in following tracheal section:		
	Cranial	Median	Posterior
Bacterial colonization	6-15	6-19	6-23
General loss of cilia	11-23 ^a	15-23 ^b	19 ^c
Loss of ciliated epithelial cells	11-19	15-19	19 ^c
Hyperplasia	19-27	19-23	23 ^c

^a Loss of cilia complete at 19 and 23 days p.i. Cilia were again evident in areas at 27 days p.i.

^b Complete loss of cilia at 23 days p.i. Cilia were again evident in areas at 27 days p.i.

^c Not observed in all poult examined.

occasionally from nasal turbinates. The results of the bacterial load determination of *A. faecalis* associated with the cranial tracheal sections are summarized in Fig. 3. The median and posterior tracheal section bacterial load results were similar to those determined for the cranial sections. However, in these sections, the initial significant peak indicating colonization by *A. faecalis* was observed 2 to 3 days later. Contaminating bacteria (usually *Escherichia coli* and *Klebsiella pneumoniae*) were isolated from the anterior region of many tracheae after 13 days p.i. and on occasion throughout the length of the trachea. In most sections for which titers were determined, however, only *A. faecalis* was isolated.

DISCUSSION

These results describe the changes resulting from experimental infection with *A. faecalis* of the upper respiratory tracts of turkeys. The initial change was colonization of the nasal turbinates and trachea, with colonization of the trachea by *A. faecalis* apparent before the appearance of clinical signs and as many as 6 days before tissue damage could be observed by gross or microscopic examination.

The nasal turbinates and cranial regions of tracheae were the first tissues in which cellular damage was observed. The early cellular damage observed consisted primarily of foci in which cilia were absent from the epithelial cells. The focal loss of cilia progressed to a general loss of cilia and eventually to a total loss of ciliated epithelial cells. Accumulation of mucus was seen in areas associated with damaged epithelial cells. In contrast, the posterior region of the trachea had little or no apparent loss of cilia, and the accumulation of mucus was not observed.

The most severe tissue damage was observed in the cranial region of the trachea. In this

region, the ciliated epithelial cells were completely lost, and gross pathological changes were readily apparent. The involution of the trachea from the dorsal tracheal surface all but completely occluded the tracheal lumen. The dyspnea observed in some of the infected turkeys was believed to be caused by a combination of tenacious mucus and involution of the trachea which temporarily obstructed the tracheal lumen, making normal respiration difficult. The obstructed tracheal lumen was determined to have caused the death of at least one turkey (and possibly four others) owing to suffocation and was a source of clinical stress for all turkeys inoculated with *A. faecalis*. It is interesting that the most severe damage was confined to the cranial region of the trachea. This observation is in contrast to the tracheal damage described in canine bordetellosis caused by *Bordetella bronchiseptica*, which damages these tissues throughout the length of the trachea and bronchial tree (2). A possible explanation of this observation is that the temperature of the trachea in the cranial region is lower than that in the more distal regions. This hypothesis would indicate a requirement for a lower temperature for the cytotoxic effect associated with *A. faecalis*. In the normal animal, inspired air is warmed by the nasal turbinates to the body temperature of the animal before the air enters the trachea.

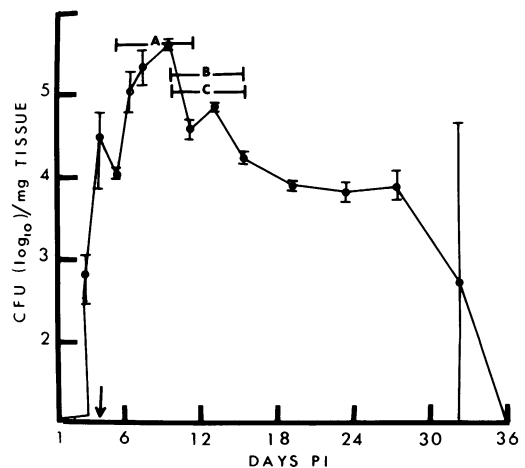


FIG. 3. Growth of *A. faecalis* in the cranial region of the tracheae of turkeys. Each point represents the mean titration of *A. faecalis* from cranial sections of five individual turkeys. Vertical lines represent the standard deviation of the titer values. Peaks of *A. faecalis* colonization found in cranial tracheal sections (5 to 11 days p.i.) (A) and in median (B) and posterior (C) tracheal sections (9 to 15 days p.i.) are shown. Arrow indicates day p.i. of the initial isolation of *A. faecalis* from the median and posterior tracheal sections (3 days p.i.).

However, in *A. faecalis*-infected animals, the production of mucus in the nasal region is so great as to block the nares, forcing the animal to breathe through its mouth. Mouth breathing then leads to a temperature gradient, with the cooler air in the cranial region of the trachea.

It was noticed that the large number of bacteria observed colonizing the trachea did not elicit a substantial cellular inflammatory response. The failure of *A. faecalis* to elicit inflammation was probably due to its lack of invasiveness and the superficial nature of its effects. In other studies (5; unpublished observations), we have found a cytotoxic property associated with this *A. faecalis* isolate that is specific for the ciliated tracheal epithelial cells both in vitro and in vivo, leaving the cells of other tissues largely intact. Therefore, it appeared that the effects of *A. faecalis* on the upper respiratory tract were for the most part superficial and localized.

In conclusion, two primary pathogenic effects were determined to be responsible for the bulk of the morbidity and mortality associated with *A. faecalis* infection. These effects were primarily in the cranial region of the trachea and consisted of the loss of the ciliated epithelial cells and a collapsing trachea. The loss of the ciliated epithelial cells lining the luminal surface of the trachea resulted in the inability of the trachea to clear itself of mucus laden with foreign matter. In the field, the accumulation of foreign matter and mucus would result in an excellent environment for the growth of secondary pathogens, leading to the possibility of a clinically more severe and chronic condition. A correlation may exist between loss of the ciliated epithelial cells and tracheal collapse; however, a direct cause has not been established. The pathological change that led to blocking of the respiratory passage resulted in clinical stress and, in some instances, to complete blockage, resulting in the death of the animal. It was clear from this study that *A. faecalis* alone can cause severe respiratory disease and death. This conclusion is supported by a study of an *A. faecalis* isolate that was capable of colonizing the upper respiratory tract but was unable to damage the superficial

epithelial cells or cause tracheal collapse (manuscript submitted for publication). The resulting respiratory disease was, therefore, a clinically mild disease of short duration when compared with infection by this more virulent *A. faecalis* isolate.

LITERATURE CITED

1. Bemis, D. A., L. E. Carmichael, and M. J. G. Appel. 1977. Naturally occurring respiratory disease in a kennel caused by *Bordetella bronchiseptica*. *Cornell Vet.* 67:282-293.
2. Bemis, D. A., H. A. Greisen, and M. J. G. Appel. 1977. Pathogenesis of canine bordetellosis. *J. Infect. Dis.* 135:753-762.
3. Dillman, R. C., and D. G. Simmons. 1977. Histopathology of a rhinotracheitis of turkey poults associated with adenovirus. *Avian Dis.* 31:481-491.
4. Filion, R., S. Cloutier, E. R. Urancken, and G. Bernier. 1967. Infection respiratoire du dindonneau causee par un microbe apparente au *Bordetella bronchiseptica*. *Can. J. Comp. Med.* 31:129-134.
5. Gray, J. G., J. F. Roberts, R. C. Dillman, and D. G. Simmons. 1981. Cytotoxic activity of pathogenic *Alcaligenes faecalis* in turkey tracheal organ cultures. *Am. J. Vet. Res.* 42:2184-2186.
6. Hinz, K. H., G. Glunder, and H. Lunders. 1978. Acute respiratory disease in turkey poults by *Bordetella bronchiseptica*-like bacteria. *Vet. Rec.* 103:262-263.
7. Rarick, H. R., P. S. Riley, and R. Martin. 1978. Carbon substrate utilization studies of some cultures of *Alcaligenes denitrificans*, *Alcaligenes faecalis*, and *Alcaligenes ordorans* isolated from clinical specimens. *J. Clin. Microbiol.* 8:313-319.
8. Rhea, L. J. 1915. The comparative pathology of the tracheal and bronchial lesions produced in man by *Bordetella pertussis* (whooping-cough) and those produced in dogs by *B. bronchisepticus* (canine distemper). *J. Med. Res.* 27:471-474.
9. Saif, Y. M., P. D. Moorhead, R. N. Dearth, and D. J. Jackwood. 1980. Observations on *Alcaligenes faecalis* infection in turkeys. *Avian Dis.* 24:655-684.
10. Saif, Y. M., P. D. Moorhead, and R. E. Whitmoyer. 1981. Scanning electron microscopy of tracheas from turkey poults infected with *Alcaligenes faecalis*. *Avian Dis.* 25:730-735.
11. Simmons, D. G., J. G. Gray, L. P. Rose, R. C. Dillman, and Sara E. Miller. 1979. Isolation of an etiologic agent of acute respiratory disease (rhinotracheitis) of turkey poults. *Avian Dis.* 23:194-203.
12. Simmons, D. G., L. P. Rose, and J. G. Gray. 1980. Some physical, biochemic, and pathologic properties of *Alcaligenes faecalis*, the bacterium causing rhinotracheitis (coryza) in turkey poults. *Avian Dis.* 24:82-90.
13. Thompson, H., I. A. P. McCandlish, and N. G. Wright. 1976. Experimental respiratory disease in dogs due to *Bordetella bronchiseptica*. *Res. Vet. Sci.* 20:16-23.