

Bordetella bronchiseptica Bronchitis

CHRISTOPHER J. PAPASIAN,^{1,2*} NANCY J. DOWNS,^{3,4} ROBERT L. TALLEY,^{3,4} DEBRA J. ROMBERGER,^{3,4} AND GLENN R. HODGES^{3,4}

Laboratory Service¹ and Medical Service,³ Veterans Administration Medical Center, Kansas City, Missouri 64128, and Departments of Pathology and Oncology² and Internal Medicine,⁴ University of Kansas Medical School, Kansas City, Kansas 66103

Received 29 August 1986/Accepted 28 November 1986

The clinical course of a patient with bronchitis caused by *Bordetella bronchiseptica* is described. The organism was recovered on one occasion from a protected catheter brush specimen obtained at bronchoscopy and on two occasions from expectorated sputum specimens. The infection was eradicated with antimicrobial therapy.

Bordetella bronchiseptica is a common veterinary pathogen but has rarely been implicated in human infections. We report a case of bronchitis caused by *B. bronchiseptica* and review the role of this organism as a human pathogen.

Case report. A 60-year-old man with a 6-year history of chronic lymphocytic leukemia, splenectomy secondary to an autoimmune hemolytic crisis 3 years before admission, and biopsy-documented interstitial lung disease was admitted to the Kansas City Veterans Administration Medical Center with a 5-day history of fever, chills, and shortness of breath. He recently received a 5-month course of fludarabine chemotherapy (40 to 50 mg daily for 5 days each month) for refractory chronic lymphocytic leukemia; his last course of fludarabine was approximately 10 weeks before admission. Two weeks before admission he began complaining of increasing shortness of breath, fever, and chills. He was treated with prednisone for exacerbation of his interstitial pneumonitis. Despite temporary resolution of his fever and chills, he became increasingly anorectic. Five days before admission, his fever recurred and was accompanied by chills, sweats, and shortness of breath. He was hospitalized for evaluation of these symptoms.

Physical examination revealed an elderly cachectic man in mild respiratory distress with a temperature of 103°F (39.4°C); pulse 76/min; respirations, 30/min; and blood pressure, 106/50 mm Hg ($14 \times 10^3/6.7 \times 10^3$ Pa). Bibasilar rales, decreased breath sounds, and expiratory wheezing were noted upon auscultation of the chest. Additional physical findings included an abdominal mass (8 by 10 cm) near the umbilicus, a palpable right axillary lymph node (1 by 1 cm), and a grade II/VI systolic ejection murmur heard best at the apex.

Leukocyte counts during the first 5 hospital days ranged from 3.8×10^3 to $10.2 \times 10^3/\text{mm}^3$. Differential leukocyte counts during the same period varied between 38 and 51% polymorphonuclear leukocytes, 19 and 36% bands, 10 and 25% lymphocytes, 1 and 5% monocytes, 0 and 1% basophils, 7 and 17% atypical lymphocytes, and 1 and 3% metamyelocytes. Blood gases on the day of admission were characterized by the following: pH, 7.3; PaCO₂, 40 mm Hg (5.3×10^3 Pa); and PaO₂, 70 mm Hg (9.3×10^3 Pa). Roentgenograms of the chest revealed chronic interstitial disease consistent with hypersensitivity pneumonitis but no acute infiltrates.

Bronchoscopy performed on the day after admission revealed purulent secretions in the right and left airways with the greatest accumulation in the right lower and middle lobe bronchi. Bronchial wash specimens were submitted for fungal and mycobacterial cultures and for *Pneumocystis* staining. Protected catheter brushings were collected during bronchoscopy, immersed in saline, sent to the microbiology laboratory, and vortexed before culture. The fluid was inoculated onto blood, chocolate, MacConkey, and phenylethyl alcohol agars for aerobic bacterial growth (35°C, 5 to 10% CO₂, 90 to 95% air) and onto anaerobic phenylethyl alcohol and Centers for Disease Control blood agars (Remel, Lenexa, Kans.) for anaerobic bacterial growth (Bio-Bag A; Marion Scientific, Div. Marion Laboratories, Inc., Kansas City, Mo.). The brush itself was immersed in thioglycolate broth. Heavy growth of a catalase- and oxidase-positive, gram-negative coccobacillus was observed on the aerobic blood, MacConkey, and chocolate agars and on subcultures from the thioglycolate broth. The organism was identified as *B. bronchiseptica* by using the API 20E system (Analytab Products, Plainview, N.Y.); this identification was confirmed by the Missouri Department of Health. The organism was susceptible to amikacin, carbenicillin, cephalothin, ceftazidime, gentamicin, ticarcillin, tobramycin, and trimethoprim-sulfamethoxazole and resistant to ampicillin, cefoxitin, ceftriaxone, and cefuroxime by disk diffusion. Protected catheter brush cultures also produced sparse growth of an alpha-hemolytic *Streptococcus* sp. Additional biochemical characteristics of the *Bordetella* isolate included positive motility and nitrate reduction, a rapid positivity (within 4 h) for urea, and growth on salmonella-shigella agar. Fungal and mycobacterial cultures and *Pneumocystis* staining from the bronchial wash were negative. Gram stain of a sputum specimen submitted 2 days after bronchoscopy showed numerous leukocytes, few squamous epithelial cells, and pleomorphic gram-negative coccobacilli in clumps, as well as some apparently intracellular organisms (Fig. 1). Cultures of this specimen produced heavy growth of *B. bronchiseptica*.

Intravenous antimicrobial therapy with amikacin (550 mg every 12 h) and cefazolin (1 g every 8 h) was initiated after bronchoscopy. The patient became afebrile within 48 h and remained so while hospitalized. Six days after the patient defervesced, antibiotics were discontinued, and he was discharged. At the time of discharge his breathing was much less labored but still abnormal, presumably because of chronic interstitial pneumonitis. Sputum cultures from the

* Corresponding author.

TABLE 1. Characteristics distinguishing *B. bronchiseptica* from phenotypically similar bacteria^a

Trait	<i>B. bronchiseptica</i>	<i>B. parapertussis</i>	<i>A. faecalis</i> ^b	<i>A. denitrificans</i> subsp. <i>denitrificans</i> ^c	CDC group IVe	CDC group IVc-2
Motility	+	-	+	+	+	+
Christiansens urea	+	+	-	v ^d	+	+
Growth on salmonella-shigella agar	+	-	v	v	-	-
Nitrate reduction	+	-	v	+	+	v
Gas from nitrate	-	-	-	+	v	-
Phenylalanine deaminase					+	-

^a See references 5, 10, and 17.

^b Includes organisms formerly classified as *A. faecalis* and *A. odorans*.

^c Formerly classified as *A. denitrificans* and excludes *A. denitrificans* subsp. *xylosoxydans*, formerly *Achromobacter xylosoxydans*.

^d v, Variable.

day of discharge produced predominant growth of *B. bronchiseptica*. Five days after discharge, the patient presented to the outpatient clinic complaining of anorexia, fever, sweats, chills, and fatigue of approximately 36-h duration; bacterial cultures were not collected. These symptoms resolved with 2 weeks of oral trimethoprim-sulfamethoxazole therapy (80 mg of trimethoprim and 400 mg of sulfamethoxazole twice daily).

B. bronchiseptica is a pleomorphic, motile, catalase- and oxidase-positive, nonfermentative, gram-negative coccobacillus which until the 1950s was difficult to distinguish from phenotypically similar organisms, particularly *Alcaligenes faecalis* (8, 16). The characteristics distinguishing *B. bronchiseptica* from morphologically and biochemically similar bacteria are shown in Table 1; recent taxonomic changes involving the genus *Alcaligenes* are included (10). Carbon utilization studies may also be useful for distinguishing the organisms shown in Table 1 from one another (13, 14). *B. bronchiseptica* is a common veterinary commensal and pathogen inhabiting the respiratory tract; it causes respiratory infections in a wide variety of laboratory and wild animals (8). *B. bronchiseptica* has been infrequently found as a commensal in the human respiratory tract and has rarely been implicated in human disease. In a 2-year hospital survey of nonfermenting gram-negative bacteria, Pederson et al. (12) recovered 12 *B. bronchiseptica* isolates; all 12 were from sputum, and none were associated with disease. Gardner et al. (6) recovered 18 *B. bronchiseptica* isolates (16 from sputum, 1 from urine, and 1 from blood) from human sources. The sputum isolates were all thought to be hospital acquired and were not related to recent animal contact. Patients harboring *B. bronchiseptica* in their respiratory tract frequently had serious underlying disease, required tracheostomies or endotracheal intubation, and had undergone prolonged therapeutic courses with antimicrobial agents. One of the sputum isolates appeared to be etiologically related to a fatal tracheobronchitis; the remaining 15 respiratory isolates and the single urinary isolate were considered nonpathogenic saprophytes. The lone blood isolate was recovered (with *Streptococcus pneumoniae*) as part of a polymicrobial bacteremia in an asplenic, immunosuppressed patient who died of pneumonia after treatment for *Staphylococcus aureus* endocarditis. Three additional cases of *B. bronchiseptica* bacteremia have been reported. These include a fatal bacteremia in a patient with cholestatic liver disease, splenic infarction, and ultimately, splenic rupture (9); a fatal bronchopneumonia and septicemia in a malnourished alcoholic (7); and a case of endocarditis caused by

simultaneous infection of the heart valve by *B. bronchiseptica* and coagulase-negative *Staphylococcus* sp. (4). Other reported nonrespiratory diseases attributed to *B. bronchiseptica* include posttraumatic meningitis in a boy

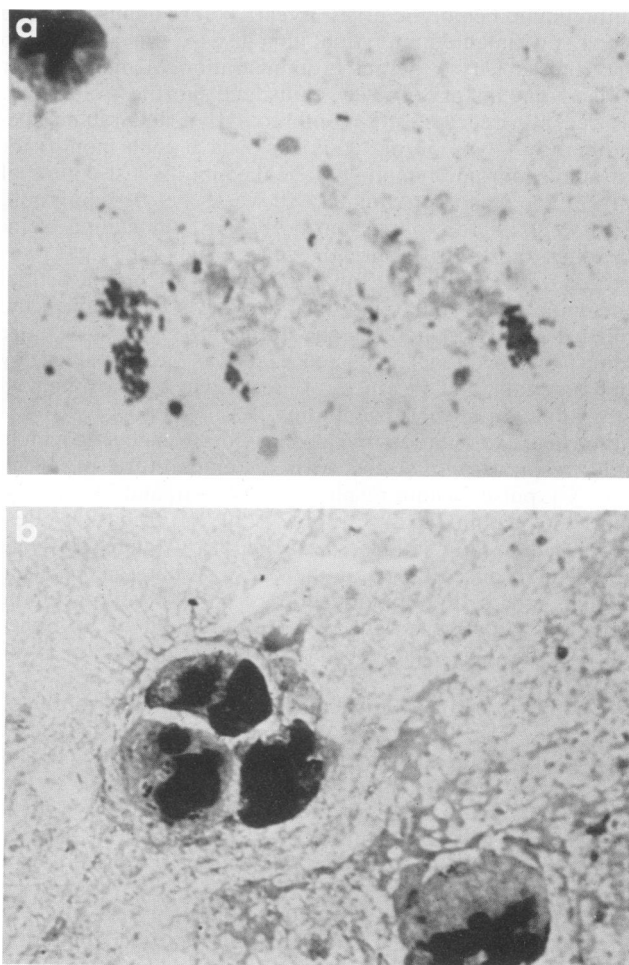


FIG. 1. Gram-stained smear of expectorated sputum (intentionally underdecolorized for illustration) showing pleomorphic gram-negative coccobacilli in clumps (a) and intracellularly (b). Note apparent capsule surrounding intracellular organisms. Magnification, $\times 874$.

who had been kicked in the head by a horse and peritonitis in a patient receiving continuous ambulatory peritoneal dialysis (2, 3).

Reports of respiratory infection attributed to *B. bronchiseptica* include a nonfatal polymicrobial pneumonia (along with *S. aureus*) in a patient with stage IV Hodgkin's disease; a subacute illness, in a 14-year-old boy, which resembled tuberculosis both clinically and roentgenologically; and an outbreak of a whooping cough-like disease in three children from the same family (6, 11, 15). An additional case of *B. bronchiseptica* infection resembling whooping cough was reported in 1926; however, the criteria used to identify the isolate are now deemed insufficient to distinguish it from phenotypically similar organisms (1). *B. bronchiseptica* has also been implicated as the etiologic agent of mild upper respiratory tract illness in animal caretakers (8).

We report here a case of successfully treated *B. bronchiseptica* bronchitis in an asplenic, immunosuppressed patient with chronic lymphocytic leukemia who denied close exposure to animals. Although *B. bronchiseptica* is most likely to be a commensal in humans, it can cause opportunistic respiratory and systemic disease. Conditions apparently predisposing to *B. bronchiseptica* infection include hematologic malignancy, cholestatic liver disease, splenectomy or splenic rupture, alcoholic malnutrition, trauma, and peritoneal catheterization. A history of exposure to animals may be significant but is not essential. Clinicians and laboratorians should not dismiss *B. bronchiseptica* as a respiratory commensal without carefully considering the clinical status of the patient. In determining the significance of sputum isolates, retrospective evaluation of the Gram stain is recommended, because the pleomorphic morphology of *B. bronchiseptica* can be misleading.

We are indebted to James Farrow for technical assistance, Brenda Adams for clerical assistance, Peter Nelson for clinical acumen, and the Missouri Department of Health for confirmation of the identification of *B. bronchiseptica*.

LITERATURE CITED

1. Brown, J. H. 1926. *Bacillus bronchisepticus* infection in a child with symptoms of pertussis. Bull. Johns Hopkins Hosp. 38:147-153.
2. Byrd, L. H., L. Anama, M. Gutkin, and H. Chmel. 1981. *Bordetella bronchiseptica* peritonitis associated with continuous ambulatory peritoneal dialysis. J. Clin. Microbiol. 14:232-233.
3. Chang, K. C., R. M. Zakheim, C. T. Cho, and J. C. Montgomery. 1975. Post-traumatic purulent meningitis due to *Bordetella bronchiseptica*. J. Pediatr. 86:639-640.
4. Dale, A. J. D., and J. E. Geraci. 1961. Mixed cardiac valvular infections: report of case and review of literature. Proc. Staff Meet. Mayo Clin. 36:288-294.
5. Elliott, T. B., G. L. Gilardi, R. Hugh, R. E. Weaver, and J. A. Webster. 1981. Identification of glucose nonfermenting gram-negative rods. American Society for Microbiology, Washington, D.C.
6. Gardner, P., W. B. Griffin, M. N. Swartz, and L. J. Kunz. 1970. Nonfermentative gram-negative bacilli of nosocomial interest. Am. J. Med. 48:735-749.
7. Ghosh, H. K., and J. Tranter. 1979. *Bordetella bronchiseptica* (bronchiseptica) infection in man: review and a case report. J. Clin. Pathol. 32:546-548.
8. Goodnow, R. A. 1980. Biology of *Bordetella bronchiseptica*. Microbiol. Rev. 44:722-738.
9. Katzenstein, D. A., L. Ciofalo, and M. C. Jordan. 1984. *Bordetella bronchiseptica* bacteremia. West. J. Med. 140:96-98.
10. Kersters, K., and J. De Ley. 1984. Genus *Alcaligenes* Castellani and Chalmers 1919, 936^{AL}, p. 361-373. In N. R. Krieg and J. G. Holt (ed.), Bergey's manual of systematic bacteriology, vol. 1. The Williams & Wilkins Co., Baltimore.
11. Kristensen, K. H., and H. Lautrop. 1962. A family epidemic of whooping cough caused by *Bordetella bronchiseptica*. Ugeskr. Laeg. 124:303-308.
12. Pederson, M. M., E. Marso, and M. J. Pickett. 1970. Nonfermentative bacilli associated with man: III. Pathogenicity and antibiotic susceptibility. Am. J. Clin. Pathol. 54:178-192.
13. Pickett, M. J., and J. R. Greenwood. 1986. Identification of oxidase-positive, glucose-negative, motile species of nonfermentative bacilli. J. Clin. Microbiol. 23:920-923.
14. Rarick, H. R., P. S. Riley, and R. Martin. 1978. Carbon substrate utilization studies of some cultures of *Alcaligenes denitrificans*, *Alcaligenes faecalis*, and *Alcaligenes odorans* isolated from clinical specimens. J. Clin. Microbiol. 8:313-319.
15. Stroll, D. B., S. A. Murphey, and S. K. Ballas. 1981. *Bordetella bronchiseptica* infection in stage IV Hodgkin's disease. Postgrad. Med. J. 57:723-724.
16. Ulrich, J. A., and G. M. Needham. 1953. Differentiation of *Alcaligenes faecalis* from *Brucella bronchiseptica* by biochemical and nutritional methods. J. Bacteriol. 65:210-215.
17. Weaver, R. E., D. G. Hollis, W. A. Clark, and P. Riley. 1982. The identification of unusual pathogenic gram-negative bacteria. Centers for Disease Control. Atlanta.