

Aerotolerant *Clostridium tertium* Brain Abscess following a Lawn Dart Injury

JUDY F. LEW,^{1†} BERNHARD L. WIEDERMANN,^{1*} JUDY SNEED,² JOSEPH CAMPOS,²
AND DAVID McCULLOUGH³

Departments of Infectious Diseases,¹ Laboratory Medicine,² and Neurosurgery,³ Children's National Medical Center,
111 Michigan Avenue, N.W., Washington, D.C. 20010

Received 1 May 1990/Accepted 25 June 1990

A young girl developed an intracranial abscess and necrotizing cellulitis following penetrating injury from a lawn dart. Initial identification of a gram-positive rod growing aerobically from clinical specimens was as a *Bacillus* organism, but the observation that the isolate grew poorly in subcultures for susceptibility testing but quite well under standard anaerobic culture techniques led to the identification of the organism as an aerotolerant *Clostridium tertium*. Early management of penetrating head trauma should include cranial imaging studies to detect fractures and intracranial pathology. Clinical microbiologists and clinicians should be aware of the phenomenon of aerotolerance in anaerobic bacteria to avoid errors in choice of antibiotic therapy.

Aerotolerance is a term applied to strains of anaerobic bacteria that are able to tolerate oxygen to the extent that growth is possible under ambient atmospheric conditions. Although the pathogenetic significance of this characteristic is unknown, it poses a potential source of confusing and misleading information for the clinician when these organisms are associated with disease. We report a case of brain abscess from which an aerotolerant *Clostridium tertium* was isolated and review previous clinical experiences with these organisms.

An 8-year-old girl was struck in the forehead by a lawn dart, which appeared to pierce the skin. The dart was removed by family members, and she was taken to a local emergency room. A small laceration was cleaned and sutured. No radiographic studies were performed, and no antibiotics were administered. The child returned home, but over the next 2 days she experienced progressive bilateral periorbital swelling, decreased appetite, and fatigue. The edges of the wound then separated, and extrusion of purulent material was noted. The sutures were removed at the local emergency room, and she was transferred to Children's National Medical Center.

At the time of admission, the child was afebrile, alert, and cooperative. Neurologic examination revealed no abnormalities. A cranial computed tomographic scan demonstrated a right frontal lobe abscess cavity with evidence of gas formation (Fig. 1). She received vancomycin, cefotaxime, and chloramphenicol and was taken immediately to the operating room. A necrotic-appearing, malodorous abscess cavity in the right frontal lobe was drained. Skin, bone, and dura mater were debrided.

Postoperatively, the patient did well, except for some evidence of poor healing of the skin incision. Histologic examination of the abscess cavity demonstrated interstitial hemorrhage in surrounding brain tissue, with the abscess wall and leptomeninges containing prominent blood vessels with septic thrombi, fibrinoid exudate, and polymorphonuclear infiltrates. She was taken for a second operative

procedure, in which necrotic cutaneous tissue surrounding the wound was excised. Following this procedure, antibiotic therapy was changed to aqueous penicillin G alone, and she had an uneventful recovery. Two years after the injury, she remained asymptomatic on anticonvulsant therapy. Neurological examination was normal. There was a right frontal skull defect (2.5 by 3.5 cm), with pulsation.

Swab specimens from the frontal lobe abscess cavity were obtained for aerobic and anaerobic bacterial cultures and transported to the Clinical Microbiology Laboratory in Port-A-Cul tubes (BBL Microbiology Systems, Cockeysville, Md.). Brain tissue samples were sent in a sterile cup. Specimens were processed in room air and placed on Centers for Disease Control anaerobic blood agar with and without kanamycin and vancomycin and on Columbia colistin-nalidixic acid blood agar (BBL) and in prerduced anaerobically sterilized chopped meat glucose broth (Remel, Lenexa, Kans.). Incubation was in a GasPak system (BBL). Aerobic cultures were placed on standard solid media. Gram stains of the material showed many erythrocytes, few leukocytes (mostly polymorphonuclear leukocytes), and a moderate number of gram-variable rods. Initially, there was 1 to 2⁺ growth in the aerobic specimens of small gray colonies on both blood and chocolate agar plates. The organism was identified as a gram-positive rod, thought to be a *Bacillus* species. However, growth was poor in subcultures for susceptibility testing. Meanwhile, anaerobic cultures were showing growth of *Clostridium perfringens*, *Clostridium sordellii*, and *Clostridium tertium*, and the possibility of an aerotolerant *Clostridium* species masquerading as a *Bacillus* species was entertained. This was confirmed by demonstration that the aerobic isolate grew better anaerobically and was catalase negative and by identification as *C. tertium* by the RapID-ANA system (Innovative Diagnostic Systems, Inc., Atlanta, Ga.).

Clostridia are gram-positive, sporeforming, anaerobic bacteria that are ubiquitous in the environment. These organisms are found in a variety of clinical syndromes, including traumatic injuries (3). *C. tertium*, *Clostridium histolyticum*, and *Clostridium carnis* are the three species of clostridia that have been reported to be aerotolerant previously (1). Their ability to grow aerobically causes them to be confused with *Bacillus* species, and inconsistent Gram stain characteristics

* Corresponding author.

† Present address: Viral Gastroenteritis Unit, Centers for Disease Control, Atlanta, GA 30333.

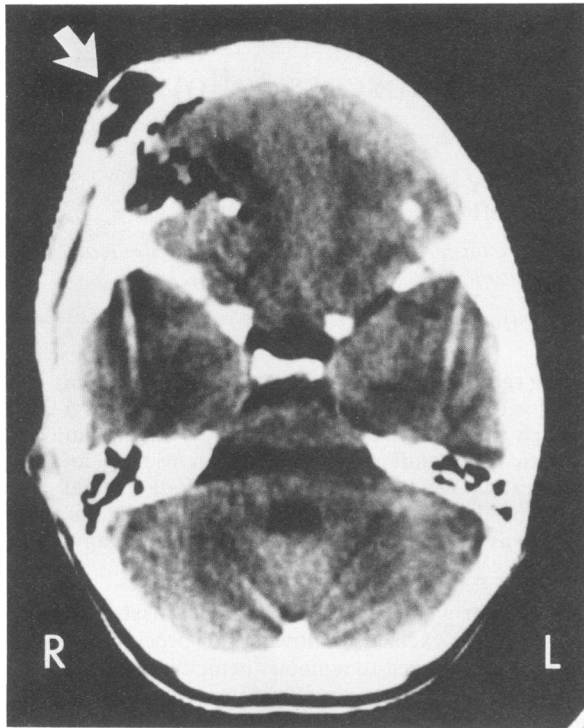


FIG. 1. Cranial CT scan shows presence of air in frontal lobe and in soft tissues at dart entry site (arrow points to path of dart).

can result in preliminary identification as gram-negative enteric organisms. In contrast to *Bacillus* species, however, aerotolerant clostridia rarely form spores when grown aerobically and are catalase negative. Also, aerotolerant clostridia tend to form larger colonies when grown anaerobically, compared with their aerobic growth (1, 3). These characteristics can aid the microbiologist in the correct identification of an aerotolerant clostridial isolate.

Aerotolerant anaerobes can be defined as bacteria that do not utilize molecular oxygen and display inhibition of growth to some extent in the presence of oxygen (2). Oxygen tolerance of anaerobic bacteria was well described by Loesche in a study of the effects of oxygen exposure of anaerobic bacteria (6). Tally et al. studied oxygen tolerance in a variety of fresh clinical isolates of anaerobic bacteria in 1975 (9). Their work with 57 anaerobic bacteria isolated from clinical specimens covered a wide range of anaerobic bacteria. Their collection included five *Clostridium* isolates, but identification to species was not reported for all of the strains. They found that all 5 of the clostridia survived 72 h of exposure to room air. A *C. sordellii* grew in 7.5% oxygen, and a *Clostridium putrificum* grew in 10% oxygen, allowing both to be classified as aerotolerant with the Loesche criteria. The other three isolates, which were not identified to species, had growth in 1.6 or 2.5% oxygen concentrations, classifying them as moderately sensitive to oxygen.

Clostridia are commonly found in contaminated wounds. During World War I, *C. perfringens* and *C. tertium* were the two most common causes of gas gangrene, and *C. tertium* ranked third among clostridial infections in World War II (7). Species of *Clostridium* have been implicated in three of five case histories of patients with lawn dart-associated cranial infections (4, 10, 12). This is not surprising, in view of the ubiquitous nature of these organisms, particularly in soil. The widespread tissue injury accompanying clostridial

wound infections may require extensive debridement, as illustrated by the case reported here. For our patient, suturing of the contaminated puncture wound without further evaluation at the time of injury may have contributed to the delay in recognition of deep infection. A skull radiograph obtained immediately after the injury most likely would have demonstrated a fracture at the site of entry and led to prompt surgical intervention.

More recently, *C. tertium* has been increasingly identified as an important cause of sepsis in immunocompromised patients. Speirs et al. reviewed 18 patients with hematologic malignancies and neutropenia who developed *C. tertium* sepsis (8). They noted that on 11 blood cultures, the organism grew in vented bottles and demonstrated growth under both aerobic and anaerobic conditions. Thaler et al. reported 10 patients with hematologic malignancies and *C. tertium* infections but did not comment on the frequency of aerotolerance observed (11). Two relatively recent case reports have commented on the confusion generated with aerotolerant *C. tertium* isolates in a 60-year-old woman with bacteremia following bowel surgery and a 48-year-old alcoholic man with aspiration pneumonia and bacteremia (5; J. Weiser, Clin. Microbiol. Newsl. 9:93-94, 1987). In both cases, the organism was mistaken for an aerobic gram-negative rod.

The role of aerotolerance in disease production is unclear, and the mechanisms by which oxygen inhibits the growth of or kills anaerobic bacteria is unknown. Although prior studies have focused on the role of bacterial catalase, peroxidase, and superoxide dismutase in this process, there has been no unifying theory that correlates the degree of oxygen sensitivity with bacterial enzyme production and pathogenicity (2). For now, the phenomenon of aerotolerance in anaerobic bacteria is primarily of importance to the clinical microbiologist so that proper identification and susceptibility testing of isolates can be done.

Recognition of the presence of aerotolerant *C. tertium* in clinical specimens is important in the determination of appropriate management. Although the isolate of our patient was susceptible to penicillin, Thaler et al. reported that only 6 of their 15 isolates had penicillin MICs of $<1 \mu\text{g/ml}$ and only 8 of 15 had clindamycin MICs of $<5 \mu\text{g/ml}$ (11). In their series, tetracycline, chloramphenicol, vancomycin, and metronidazole had MICs in the susceptible range for at least 90% of the isolates, although only five were tested for metronidazole susceptibility.

Lawn dart head injuries should be seen less frequently now that the sale of these "toys" was banned in April 1989 by the Consumer Product Safety Commission (Consumer Product Safety Commission Consumer Hotline, 1-800-638-2272). However, it should be expected that *C. tertium* infections will continue to be seen in association with contaminated wounds and in the immunocompromised host. Recognition of the aerotolerant nature of this bacterium is necessary to avoid delays or errors in appropriate antimicrobial therapy.

LITERATURE CITED

- Allen, S. D. 1985. *Clostridium*, p. 434-444. In E. H. Lennette, A. Balows, W. J. Hausler, Jr., and H. J. Shadomy (ed.), Manual of clinical microbiology, 4th ed. American Society for Microbiology, Washington, D.C.
- Allen, S. D., J. A. Siders, and L. M. Marler. 1985. Isolation and examination of anaerobic bacteria, p. 413-433. In E. H. Lennette, A. Balows, W. J. Hausler, Jr., and H. J. Shadomy (ed.), Manual of clinical microbiology, 4th ed. American Society for Microbiology, Washington, D.C.

3. **Bartlett, J. G.** 1989. Gas gangrene (other *Clostridium*-associated diseases), p. 1850-1860. In G. L. Mandell, R. G. Douglas, Jr., and J. E. Bennett (ed.), Principles and practice of infectious diseases, 3rd ed. Churchill Livingstone, Inc., New York.
4. **Hanigan, W. C., W. C. Olivero, J. J. Duffy, and R. Peterson.** 1986. Lawn dart injury in children: report of two cases. *Pediatr. Emerg. Care* **2**:247-249.
5. **Johnson, J. R., and F. C. Tenover.** 1988. *Clostridium tertium* bacteremia in a patient with aspiration pneumonia: an elusive diagnosis. *J. Infect. Dis.* **157**:854-855.
6. **Loesche, W. J.** 1969. Oxygen sensitivity of various anaerobic bacteria. *Appl. Microbiol.* **18**:723-727.
7. **MacLennan, J. D.** 1943. Anaerobic infections of war wounds in the Middle East. *Lancet* **ii**:94.
8. **Speirs, G., R. E. Warren, and A. Rampling.** 1988. *Clostridium tertium* septicemia in patients with neutropenia. *J. Infect. Dis.* **158**:1336-1340.
9. **Tally, F. P., P. R. Stewart, V. L. Sutter, and J. E. Rosenblatt.** 1975. Oxygen tolerance of fresh clinical anaerobic bacteria. *J. Clin. Microbiol.* **1**:161-164.
10. **Tay, J. S., and J. S. Garland.** 1987. Serious head injuries from lawn darts. *Pediatrics* **79**:261-263.
11. **Thaler, M., V. Gill, and P. A. Pizzo.** Emergence of *Clostridium tertium* as a pathogen in neutropenic patients. *Am. J. Med.* **81**:596-600.
12. **Tiffany, K. K., and M. W. Kline.** 1988. Mixed flora brain abscess with *Pseudomonas paucimobilis* after a penetrating lawn dart injury. *Pediatr. Infect. Dis. J.* **7**:667-669.