

## Rapid Detection of *Pneumocystis carinii* Using a Direct Fluorescent Monoclonal Antibody Stain

VALERIE L. NG,<sup>1,2\*</sup> NZEERA A. VIRANI,<sup>3</sup> RICHARD E. CHAISSON,<sup>3</sup> DAVID M. YAJKO,<sup>1</sup> HARRY T. SPHAR,<sup>3</sup>  
KATHY CABRIAN,<sup>4</sup> NICOLA ROLLINS,<sup>4</sup> PATRICIA CHARACHE,<sup>5</sup> MONICA KRIEGER,<sup>4</sup>  
W. KEITH HADLEY,<sup>1</sup> AND PHILIP C. HOPEWELL<sup>2,6</sup>

*Department of Laboratory Medicine, University of California, San Francisco, and Division of Clinical Microbiology, Clinical Laboratories,<sup>1</sup> and Medical Service,<sup>6</sup> San Francisco General Hospital, San Francisco, California 94110; Department of Medicine, University of California, San Francisco, California 94143<sup>2</sup>; AIDS Service<sup>3</sup> and Clinical Microbiology Laboratory,<sup>5</sup> The Johns Hopkins University School of Medicine, Baltimore, Maryland 21205; and Genetic Systems, Inc., Seattle, Washington 98121<sup>4</sup>*

Received 5 April 1990/Accepted 11 June 1990

A collaborative study was undertaken at two institutions to assess the performance of a direct fluorescent-antibody stain for the detection of *Pneumocystis carinii* in respiratory specimens from patients with known or suspected human immunodeficiency virus type 1 infections. A total of 163 specimens (125 induced sputa, 37 bronchoalveolar lavage fluids, and 1 tracheal aspirate) from 124 patients were examined by using modified Giemsa (Diff-Quik; Baxter American Scientific Products, Chicago, Ill.) and direct fluorescent-antibody stains. A total of 73 specimens contained *P. carinii*, which was detected in 66 (92%) of the specimens by using the modified Giemsa and in 71 (97%) of the specimens by using the fluorescent-antibody stain. One bronchoalveolar lavage fluid specimen in which *P. carinii* was detected only with the fluorescent-antibody stain was determined to be a false-positive based on subsequent clinical evaluation of the patient. Although the overall time for processing and examining specimens stained with either stain was not significantly different for those specimens containing *P. carinii*, considerably less time was required for microscopic examination of those fluorescent-antibody-stained specimens lacking *P. carinii*.

Although *Pneumocystis carinii* pneumonia is the most common lung disease that occurs in patients with acquired immune deficiency syndrome, a broad array of both infectious and noninfectious disorders is included in the differential diagnosis (4, 15, 16, 20). For this reason and because of the large and increasing numbers of patients with human immunodeficiency virus type 1-associated lung diseases, rapid and accurate diagnostic tests for the identification of *P. carinii* and other pathogens are essential. Specimens in which *P. carinii* can potentially be found include (i) lung tissue obtained by transbronchial or open lung biopsy, (ii) bronchoalveolar lavage fluid, and (iii) sputum induced by inhalation of hypertonic saline (1, 3-5, 10, 14, 16, 18-20). Of these specimens, induced sputum has the advantage of being obtained quickly by noninvasive and less expensive means. However, the ability to detect *P. carinii* in induced sputum varies widely, depending at least in part on the experience and skill of the individuals who obtain, process, and examine the specimens. From 1985 to the present at San Francisco General Hospital (SFGH), we have consistently demonstrated a sensitivity of *P. carinii* detection of 74 to 78% for induced sputum specimens obtained from individuals who were ultimately diagnosed with *P. carinii* pneumonia, regardless of whether or not prophylactic aerosolized pentamidine was administered (16, 17; V. L. Ng, E. McGinty, S. Geaghan, J. Fahey, L. Schnapp, D. M. Yajko, G. Leoung, P. C. Hopewell, and W. K. Hadley. Abstr. Annu. Meet. Am. Soc. Microbiol. 1990, C-374, p. 406).

In previous studies, the use of an indirect immunofluorescent-antibody stain, when compared with Gomori methenamine silver, modified toluidine blue O, or modified Giemsa

stains, demonstrated an increased sensitivity for detecting *P. carinii* in induced sputum specimens (2, 7, 9, 11, 13, 14). Subsequent experience with a commercially available indirect fluorescent-antibody stain has suggested that it has increased sensitivity compared with those of conventional stains, but apparent false-positive results were observed (17).

Recently, a direct fluorescent-antibody (DFA) stain for *P. carinii* has been developed (Genetic Systems, Inc., Seattle, Wash.). The DFA stain has the advantage of requiring less time and fewer reagents than the indirect fluorescent-antibody, Gomori methenamine silver, and modified toluidine blue O stains. In order to determine the usefulness of the DFA stain, we undertook a collaborative study in which the DFA stain was compared with a modified Giemsa stain (Diff Quik; DQ; Baxter American Scientific Products, Chicago, Ill.) for detecting *P. carinii* in respiratory specimens obtained from patients with or suspected of having the acquired immune deficiency syndrome.

### MATERIALS AND METHODS

**Patient selection and diagnostic evaluation.** Patients with known or presumed human immunodeficiency virus type 1 infection, respiratory symptoms, and objective evidence of lung disease (abnormal chest radiograph, reduced diffusing capacity for carbon monoxide, or increased lung uptake of gallium-67 citrate) were selected for sputum induction according to a standard diagnostic algorithm (1, 16). Induced sputum slides stained with DQ were examined immediately for purposes of clinical management. Patients who did not have *P. carinii* found on the DQ stain of induced sputum underwent bronchoalveolar lavage if they consented to the procedure and if no other etiology for their lung disease was found. For five patients at The Johns Hopkins University

\* Corresponding author.

(JHU), a second induced sputum specimen instead of a bronchoalveolar lavage specimen was obtained after a non-diagnostic induced sputum specimen was obtained.

**Cytopathology examination.** At JHU, respiratory specimens, which were obtained at the same time as the specimens for this study, were submitted to the cytopathology laboratory for independent evaluation. Direct smears were made of mucoid or viscous specimens; watery specimens were first centrifuged and the smears were made from the sediment. Smears were stained with the Gram-Weigert stain and examined microscopically.

**Histology examination.** At JHU, tissue biopsy specimens were obtained from occasional patients as part of their evaluation. Specimens were fixed in 10% buffered neutral Formalin, embedded in paraffin, stained with hematoxylin and eosin or with the Grocott modification (12) of the Gomori methenamine silver stain, and examined microscopically.

**Specimen acquisition, processing, and staining.** Sputum induction, mucolysis, centrifugation concentration, and preparation of smears on microscopic slides was performed as described previously (16). The processing and DQ staining of bronchoalveolar lavage fluid specimens has also been described previously (4, 14). The one tracheal aspirate specimen examined at SFGH was processed by mucolysis and centrifugation concentration.

All specimens were processed separately. Five smears were made from each specimen. Three smears were made by applying 100  $\mu$ l of the specimen onto glass slides; two of these were immediately stained with DQ and examined, and one was stored at  $-20^{\circ}\text{C}$  as a backup slide. Two smears were made by applying 50  $\mu$ l of the specimen onto a single 10- to 14-mm-diameter well of two coated slides (Genetic Systems). Both slides were air dried, fixed for 10 min in acetone, and either stained immediately with DFA or stored at  $-20^{\circ}\text{C}$ .

DQ staining was performed as described previously (16, 17). Briefly, after heat fixation, each smear was dipped five times in each of the three solutions (approximately 1 s per dip), rinsed in tap water, and air dried. At JHU, the DQ staining process was modified by first dipping the smears in 0.067 M phosphate buffer (pH 6.8) before staining to allow the specimen to equilibrate at the appropriate pH to optimize incorporation of the acidophilic and basophilic stains.

DFA staining was performed according to the instructions of the manufacturer. Briefly, each slide was incubated for 30 min in a humidified chamber at  $37^{\circ}\text{C}$  in 50 to 100  $\mu$ l of a buffered protein solution containing Evans blue counterstain, sodium azide, and fluorescein isothiocyanate-labeled murine monoclonal antibodies directed against *P. carinii*. Excess reagent was drained; and the slide gently washed by soaking it in deionized or tap water for 1 min, air dried, and mounted with a cover slip in mounting medium containing buffered glycerol, formaldehyde, and antiquencher.

DFA-stained slides were either read immediately or stored in the dark at  $\leq 4^{\circ}\text{C}$  for  $\leq 24$  h. Stored slides were allowed to reach room temperature before they were read, to enhance fluorescence and to avoid obscuring of the field by condensation. Each stained well was examined at  $\times 250$  magnification (ocular magnification,  $\times 12.5$ ; objective magnification,  $\times 20$ ) by using a Zeiss epifluorescence microscope with a mercury vapor lamp (HBO50) for illumination, and any apple green fluorescence was reevaluated at  $\times 500$  magnification (ocular magnification,  $\times 12.5$ ; objective magnification,  $\times 40$ ) for morphology consistent with that of *P. carinii* cysts (Fig. 1A and B).

Slides were examined in a coded and blinded fashion; i.e., the readers (N.A.V., V.L.N., D.M.Y., W.K.H.) were unaware of the patient's clinical status or of the results of the DQ staining procedure. During the course of this study, the DFA stain results were not used in patient management.

**Interpretation of smears.** A DQ-stained smear was interpreted as positive if cysts, trophozoites, or both were present (16, 17). A DFA-stained smear was interpreted as positive if at least three or more fluorescent cysts per slide with characteristic morphology (Fig. 1A and B) were observed. Although trophozoites and intracystic bodies were also observed to fluoresce, only the detection of three or more round or ovoid characteristic fluorescent cysts defined a positive specimen. A DFA-stained smear was interpreted as negative if no apple green fluorescent material was observed (Fig. 1C) or if no cysts could be detected in the fluorescent material.

**Follow-up of specimens positive by DFA only.** The medical records of patients in whose specimens *P. carinii* was detected by DFA only were reviewed. The DFA result was considered to be a true-positive result if the subsequent clinical course was consistent with *P. carinii* pneumonia or a subsequent bronchoalveolar lavage, performed within 7 days of the time that the original induced sputum specimen was obtained, contained *P. carinii*, which was detected by DQ staining. The result was considered to be a false-positive result if (i) a pulmonary disease other than *P. carinii* pneumonia was diagnosed, (ii) the patient improved spontaneously, or (iii) the patient responded to therapy which did not include anti-*P. carinii* agents. The results were considered indeterminate if (i) *P. carinii* could not be eliminated as the cause of disease or (ii) there was no clinical evaluation within 30 days of specimen acquisition.

**Follow-up evaluation of specimens lacking *P. carinii* (negative specimens).** The medical records of patients who had a single induced sputum or bronchoalveolar lavage fluid specimen in which *P. carinii* was not found were reviewed to determine whether a process consistent with *P. carinii* pneumonia occurred in the 30 days after the specimen was obtained. The test results were considered to be truly negative if (i) *P. carinii* was not found by any stain in a bronchoalveolar lavage fluid specimen obtained within 7 days of the time that the original induced sputum specimen was obtained, (ii) the respiratory process responded to treatment that did not include anti-*P. carinii* therapy, or (iii) the respiratory process resolved spontaneously and the patient had no new respiratory symptoms. The test results were considered to be falsely negative if (i) the patient had a subsequent bronchoscopy sample which contained *P. carinii* or (ii) the patient had a progressive or persistent respiratory illness which responded to anti-*P. carinii* treatment. The test results were considered to be indeterminate if (i) *P. carinii* could not be eliminated as the cause of the respiratory disease or (ii) there was no clinical evaluation within 30 days of specimen acquisition.

**Statistical analysis.** For the purpose of this study, the identification of *P. carinii* in any specimen stained with DQ was considered to be a true-positive result. Thus, by definition, there were no false-positive results with the DQ stain. In contrast, specimens in which *P. carinii* was detected only by DFA were subjected to a more rigorous set of interpretive criteria, in which results from subsequent bronchoscopic specimens, review of medical records, or both were also considered as described above. McNemar test analysis (6) was done, and sensitivity, specificity, and positive and negative predictive values were calculated (8).

## RESULTS

**Overall results.** A total of 163 respiratory specimens (125 induced sputa, 37 bronchoalveolar lavage fluids, and 1 tracheal aspirate) from 124 patients were examined by both DQ and DFA staining for the presence of *P. carinii*. A total of 73 specimens (45%) contained *P. carinii*, which was detected in 66 (90%) of the specimens by DQ staining and in 71 (97%) of the specimens by DFA staining. The rate of detection of *P. carinii* was similar at both institutions (Table 1). Although a lower sensitivity of detection of *P. carinii* with the DQ stain in comparison with that with the DFA stain was experienced at JHU, this difference was not statistically significant.

**Induced sputa.** Of the 125 induced sputum specimens examined, 60 (48%) were interpreted as positive for *P. carinii* (Tables 1 and 2). Of the 60 induced sputum specimens which contained *P. carinii*, the organism was identified by DQ staining in 54 (90%) of the specimens, by DFA staining in 58 (97%) of the specimens, and by both stains in 52 (88%) of the specimens.

In six induced sputum specimens, *P. carinii* was detected only by the DFA stain. *P. carinii* was identified in two of these specimens on subsequent blinded reading of the DQ-stained backup slides. At JHU, one other specimen was from a patient in whom *P. carinii* was detected by Gomori methenamine silver staining of an induced sputum specimen submitted to cytopathology, and one specimen was from a patient in whom *P. carinii* was detected in a liver biopsy specimen. Two specimens were from patients who had a clinical course consistent with *P. carinii* pneumonia.

There were two induced sputum specimens which contained *P. carinii* that was detected only by the DQ stain. *P. carinii* was detected in one of these specimens on blinded reading of the backup slide that was stained with DFA. In the remaining specimen, only one fluorescent cyst was observed on blinded reading of the backup slide; this was interpreted as a negative result.

Of the 65 induced sputum specimens in which *P. carinii* was not identified by either stain, 42 (65%) of the specimens were considered to be true-negative results based on the results for subsequent bronchoalveolar lavage specimens or evaluation of the patient's clinical course. Of the 65 induced sputum specimens, 17 (26%) were determined to be false-negative results: 15 were from patients in whom *P. carinii* was detected in subsequent bronchoalveolar lavage fluid specimens or induced sputum specimens, 1 was from a patient in whom *P. carinii* was detected in a Gomori methenamine silver-stained induced sputum examined by cytopathology, and 1 was from a patient who had a clinical course consistent with that of *P. carinii* pneumonia. The validity of the negative results for six (9%) induced sputum specimens could not be determined because bronchoalveolar lavage was not done and *P. carinii* pneumonia could not be excluded in the subsequent clinical course of the patient.

Thus, *P. carinii* was detected by the DQ stain, the DFA stain, or both in the induced sputum specimens of 60 of 77 (78%) patients from whom initial induced sputum specimens were obtained and who were ultimately diagnosed with *P. carinii* pneumonia.

**Bronchoalveolar lavage.** Of the 38 specimens obtained by aspiration of the airway (37 bronchoalveolar lavage fluid fluids, 1 tracheal aspirate), *P. carinii* was identified in 12 (32%) of them by both stains and 25 (66%) lacked *P. carinii* when they were examined with both stains, for a concordance rate of 98%. One bronchoalveolar lavage fluid speci-

men contained *P. carinii* that was detected only by the DFA stain; the clinical course of this patient was not consistent with that of *P. carinii* pneumonia.

The results of both stains for all specimens containing *P. carinii* are summarized in Table 1, and the overall performances of the stains are given in Table 2.

**Time for processing and examining specimens.** The laboratory time that was spent processing and examining specimens by each of the staining procedures is given in Table 3. The major differences were in the time needed to stain ( $\leq 2$  min for DQ, 15 to 20 min for DFA) and in the time needed for microscopic examination of the slides (1 to 30 min for DQ, 1 to 5 min for DFA). While the overall turnaround time did not vary much for those specimens that contained numerous *P. carinii* organisms, it was considerably shorter for those specimens that lacked *P. carinii* when they were stained and examined with the DFA stain. This shortened turnaround time was directly attributable to the ease of evaluating the DFA-stained smears. The clear distinction between the bright apple green fluorescence of *P. carinii* cysts and the counterstained red background material allowed rapid examination and interpretation of all specimens stained with the fluorescent antibody, regardless of whether *P. carinii* was present.

## DISCUSSION

The results of this comparative study show a high degree of agreement between the DFA and the reference standard DQ stains. An important shortcoming of this and other studies that have examined the performance characteristics of various tests for *P. carinii* is that, short of open lung biopsy, there is no "gold standard" that can be applied to confirm or exclude the diagnosis of *P. carinii* pneumonia. Thus, neither sensitivity nor specificity can be calculated with certainty. Nevertheless, our experience has been that, using the clinical course as the "gold standard," DQ staining of fluid obtained by bronchoalveolar lavage approaches a sensitivity of 100% (4, 5). Thus, for all practical purposes, a DQ-stained bronchoalveolar lavage specimen can be used as a "gold standard" for sensitivity against which other stains and specimens can be compared. By using this approach, the results from this study indicate that both the DQ and DFA stains have overall comparable rates of sensitivity and specificity for detecting *P. carinii* in all respiratory specimens.

The performance of the DQ and the DFA stains differed at the different institutions. While both stains performed comparably at SFGH, a higher sensitivity of *P. carinii* detection, which was not statistically significant, was observed with the DFA stain at JHU. Because the system of sputum induction and analysis for the detection of *P. carinii* in patients at risk for or with acquired immune deficiency syndrome was not implemented at JHU until the initiation of this study (September 1988), this difference in sensitivity might be attributable to the relative inexperience at JHU of interpreting DQ-stained slides, in comparison with the experience at SFGH, where sputum induction and analysis of specimens for the detection of *P. carinii* stained with DQ have been established since 1985.

There was one false-positive result obtained with the DFA stain in this study. Although a characteristic *P. carinii* clump with fluorescent cysts was clearly identified by all observers in a patient's bronchoalveolar lavage specimen stained with the DFA stain, there was no documented episode of *P. carinii* pneumonia for this patient during the subsequent 15

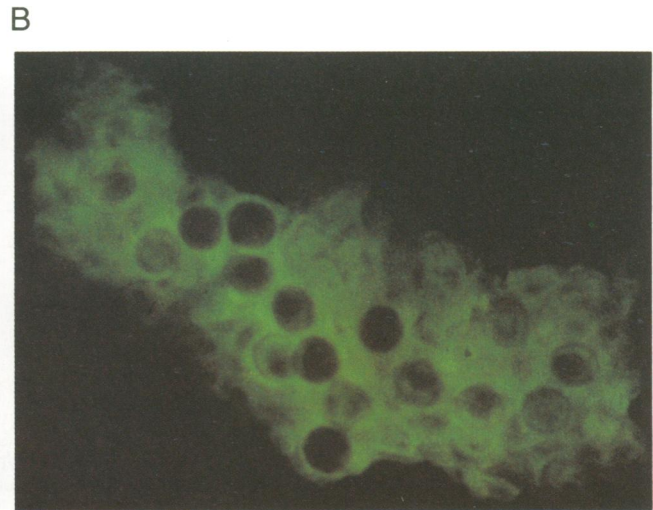
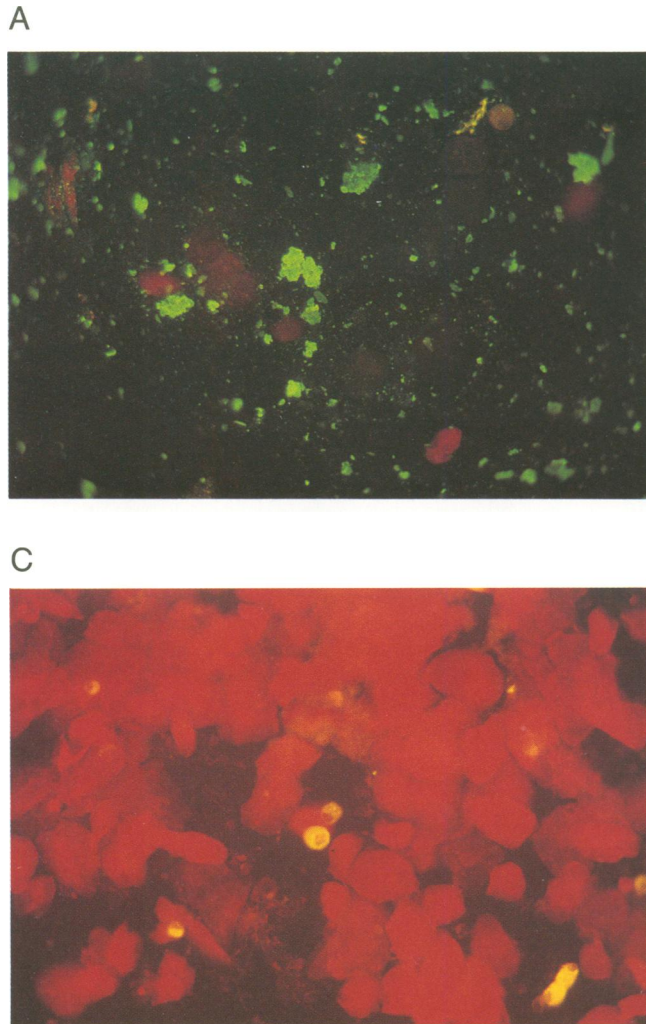


FIG. 1. Appearance of *P. carinii* cysts stained with DFA at  $\times 625$  magnification (A) and  $\times 2,500$  magnification (B). Note the bright specific apple green fluorescence of clumps of cysts on a red counterstained background of cells in panel A and a similarly stained single clump of cysts in panel B. (C) Appearance of an induced sputum specimen lacking *P. carinii* (magnification,  $\times 625$ ); note the orange-gold or gold appearance of the alveolar macrophages and the red appearance of the squamous epithelial cells.

months of clinical evaluation. In a previous study in which the subsequent clinical course or bronchoalveolar lavage was used as the criterion for test evaluation ("gold standard"), false-positive results were also observed by using an indirect fluorescent-antibody stain for detecting *P. carinii* (17). One of these false-positive results occurred when DQ and indirect fluorescent-antibody stain demonstrated clearly identifiable clumps of *P. carinii* cysts and trophozoites, yet

this patient did not receive anti-*P. carinii* treatment at that time and only developed clinically apparent *P. carinii* pneumonia 15 weeks later. This demonstrates that there may be dissociation between the presence of correctly identified *P. carinii* in respiratory secretions and clinically apparent *P. carinii* pneumonia. Nevertheless, we chose to use the clinical outcome as the "gold standard" in a situation in which the sensitivities of newer methods exceeded those of older standard methods; the ultimate goal of this study was to assess the usefulness of this new test for diagnosing clinically significant *P. carinii* pneumonia.

A distinct advantage of the DFA stain over the DQ stain was the ease and rapidity with which specimens could be examined. Microscopic examination of smears stained with the DFA stain rarely exceeded 2 min, in contrast to the approximately 20 to 30 min spent examining a DQ-stained specimen lacking *P. carinii*. It was the impression of the test readers that most specimens, regardless of whether or not *P. carinii* was present, could be interpreted more quickly with the DFA stain. The good sensitivity and specificity of the

TABLE 1. Comparison of the DQ and DFA stains for the detection of *P. carinii* in respiratory specimens at JHU, SFGH, and both (combined)<sup>a</sup>

Specimen	No. (%) of specimens with the indicated results at:											
	JHU				SFGH				Combined			
	Total	DQ+	DFA+	DQ+ and DFA+	Total	DQ+	DFA+	DQ+ and DFA+	Total	DQ+	DFA+	DQ+ and DFA+
IS	25	21	24	20	35	33	34	32	60	54	58	52
BAL	6	6	6	6	7	6	7	6	13	12	13	12
Total	31 (100)	27 (87 <sup>b</sup> )	30 (97 <sup>b</sup> )	26 (84)	42 (100)	39 (93 <sup>c</sup> )	41 (98 <sup>c</sup> )	38 (90)	73 (100)	66 (90 <sup>d</sup> )	71 (97 <sup>d</sup> )	64 (88)

<sup>a</sup> Abbreviations: Total, total number of specimens containing *P. carinii*; DQ+, specimens containing *P. carinii* detected by modified Giemsa staining (DQ); DFA+, specimens containing *P. carinii* detected by fluorescent-antibody staining; DQ+ and DFA+, specimens containing *P. carinii* detected by both DQ and DFA staining; IS, induced sputum specimen; BAL, bronchoalveolar lavage fluid specimen. Statistical analysis was performed by using the McNemar test (4).

<sup>b</sup>  $0.05 < P < 0.10$ .

<sup>c</sup>  $0.10 < P < 0.25$ .

<sup>d</sup>  $0.01 < P < 0.05$ .

TABLE 2. Overall performance of the DQ and DFA stains for detecting *P. carinii* in respiratory specimens

Test result <sup>a</sup>	No. of specimens											
	Induced sputum				Bronchoalveolar lavage fluid				Combined <sup>b</sup>			
	JHU		SFGH		JHU		SFGH		Induced sputum		Bronchoalveolar lavage fluid	
	DQ	DFA	DQ	DFA	DQ	DFA	DQ	DFA	DQ	DFA	DQ	DFA
TP	21	24	33	34	6	6	6	6	54	58	12	12
TN	24	24	18	18	6	6	19	18	42	42	25	24
FN	15	12	8	7	0	0	0	0	23	19	0	0
FP	0	0	0	0	0	0	0	1	0	0	0	1
I	0	0	6	6	0	0	0	0	6	6	0	0
Sensitivity (%)	58	67	80	83	100	100	100	100	70	72	100	100
Specificity (%)	100	100	100	100	100	100	100	95	100	100	100	96
PV+ (%)	100	100	100	100	100	100	100	86	100	100	100	92
PV- (%)	62	67	69	72	100	100	100	100	65	69	100	100

<sup>a</sup> Abbreviations: TP, true positive; TN, true negative; FN, false negative; FP, false positive; I, indeterminate (see text for definition of these terms); PV+, positive predictive value; PV-, negative predictive value (indeterminate results were not included in the calculations of sensitivity, specificity, or positive or negative predictive value).

<sup>b</sup> Combined, Data from both JHU and SFGH.

DFA stain suggests that it would be especially useful in laboratories with a relatively low volume of specimens and, thus, with personnel with relatively little experience in examining smears for *P. carinii*. Conversely, the greater rapidity of reading would make the DFA stain useful in high-volume laboratories. The cost of performing either staining procedure was roughly comparable; the pennies spent for DQ staining were offset by the technologist time and labor involved in examining the smears for 1 to 30 min, whereas the reduced labor costs involved in examining a DFA-stained smear (1 to 5 min) were offset by the higher cost of the stain (typically, \$5 to \$10 per specimen).

The only advantage of the DFA stain over commercially available indirect fluorescent stains for detecting *P. carinii* was that less time was required for staining. All other commonly considered laboratory factors, i.e., cost (approximately \$5 to \$10 per specimen), ease of interpretation, and ease of staining procedure, were comparable. Although we did not directly compare the performance of the indirect stain with the DFA stain in this study, a previous study demonstrating the higher sensitivity of the indirect fluorescent-antibody stain when compared with that of the DQ stain suggests that the indirect fluorescent-antibody stain would be more sensitive than the DFA stain (17). However, the increased sensitivity of the indirect fluorescent-antibody stain was accompanied by a higher number of false-positive results, in which the detection of *P. carinii* did not always correlate with clinical disease attributable to *P. carinii* (17).

The presence of alveolar macrophages can be detected by using either the DQ or the DFA stain; thus, use of either stain allows for the rapid assessment of specimen adequacy. However, only the DQ stain allows visualization of other

pathogens, i.e., *Cryptococcus neoformans*, *Histoplasma capsulatum*, *Toxoplasma gondii*, and cytomegalovirus, which may be present in the specimen. For this reason, use of the DQ stain might be useful for visualizing other respiratory pathogens in specimens in which *P. carinii* was not detected by the DFA stain.

#### ACKNOWLEDGMENTS

We gratefully acknowledge the helpful suggestions and technical expertise of Thomas C. Quinn, Stuart Beal, Diane McGrew, Susan Metz, Patricia Nassos, Cynthia Sanders, Iris Gartner, and Carole D. Goodman; pulmonary function technologists Joe Viana, Althanette Johnson, Miriam Bryant, and Cheryl Mancini; and Dennis Dunlop and Mack McCord for assistance with manuscript preparation.

Partial financial support for this study was provided by Genetic Systems.

#### LITERATURE CITED

1. Bigby, T. D., D. Margolskee, J. L. Curtis, P. F. Michael, D. Sheppard, W. K. Hadley, and P. C. Hopewell. 1986. The usefulness of induced sputum in the diagnosis of *Pneumocystis carinii* pneumonia in patients with the acquired immunodeficiency syndrome. *Am. Rev. Respir. Dis.* **133**:515-518.
2. Blumenfeld, W., and J. A. Kovacs. 1988. Use of monoclonal antibody to detect *Pneumocystis carinii* in induced sputum and bronchoalveolar lavage by immunoperoxidase staining. *Arch. Pathol. Lab. Med.* **112**:1233-1236.
3. Blumenfeld, W., E. Wagar, and W. K. Hadley. 1984. Use of the transbronchial biopsy for diagnosis of opportunistic pulmonary infections in acquired immunodeficiency syndrome (AIDS). *Am. J. Clin. Pathol.* **81**:1-5.
4. Broaddus, C., M. D. Dake, M. S. Stulberg, W. Blumenfeld, W. K. Hadley, J. A. Golden, and P. C. Hopewell. 1985. Bronchoalveolar lavage and transbronchial biopsy for the diagnosis of pulmonary infections in the acquired immunodeficiency syndrome. *Ann. Intern. Med.* **102**:747-752.
5. Coleman, D. L., P. M. Dodek, J. M. Luce, J. A. Golden, W. M. Gold, and J. F. Murray. 1983. Diagnostic utility of fiberoptic bronchoscopy in patients with *Pneumocystis carinii* pneumonia and the acquired immune deficiency syndrome. *Am. Rev. Respir. Dis.* **128**:795-799.
6. Downie, N. M., and R. W. Heath. 1974. Basic statistical methods, p. 185-186. Harper & Row, New York.
7. Elvin, K. M., A. Bjorkman, E. Linder, N. Heurlin, and A. Hjerpe. 1988. *Pneumocystis carinii* pneumonia: detection of parasites in sputum and bronchoalveolar lavage fluid by monoclonal antibodies. *Br. Med. J.* **297**:381-384.

TABLE 3. Laboratory turnaround time for examining respiratory specimens for *P. carinii* with the DQ versus the DFA stain

Procedure	Time (min) to perform:	
	DQ	DFA
Specimen processing	≤30	≤30
Staining	≤2	15-20
Microscopic examination	1-30	1-5
Total	33-62	46-55

8. Galen, M. F., and S. R. Gambino. 1975. Beyond normality: the predictive value and efficiency of medical diagnoses. John Wiley & Sons, Inc., New York.
9. Gill, V. J., G. Evans, F. Stock, J. E. Parrillo, H. Masur, and J. A. Kovacs. 1987. Detection of *Pneumocystis carinii* by fluorescent-antibody stain using a combination of three monoclonal antibodies. *J. Clin. Microbiol.* **25**:1837-1840.
10. Golden, J. A., H. Hollander, M. S. Stulberg, and G. Gamsu. 1986. Bronchoalveolar lavage as the exclusive diagnostic modality for *Pneumocystis carinii* pneumonia. *Chest* **90**:18-22.
11. Gosey, L. L., R. M. Howard, and F. G. Witebsky. 1985. Advantages of a modified toluidine blue O stain and bronchoalveolar lavage for the diagnosis of *Pneumocystis carinii* pneumonia. *J. Clin. Microbiol.* **22**:803-807.
12. Grocott, R. G. 1955. A stain for fungi in tissue sections and smears using Gomori's methenamine-silver nitrate technic. *Am. J. Clin. Pathol.* **25**:975-979.
13. Kovacs, J. A., V. Gill, J. C. Swan, F. Ognibene, J. Shelhamer, J. E. Parrillo, and H. Masur. 1986. Prospective evaluation of a monoclonal antibody in diagnosis of *Pneumocystis carinii* pneumonia. *Lancet* **ii**:1-3.
14. Kovacs, J. A., V. L. Ng, H. Masur, G. Leoung, W. K. Hadley, G. Evans, H. C. Lane, F. P. Ognibene, J. Shelhamer, J. E. Parrillo, and V. J. Gill. 1988. Diagnosis of *Pneumocystis carinii* pneumonia: improved detection in sputum using monoclonal antibodies. *N. Engl. J. Med.* **318**:589-593.
15. Murray, J. F., C. P. Felton, S. M. Garay, M. S. Gottlieb, P. C. Hopewell, D. E. Stover, and A. S. Teirstein. 1984. Pulmonary complications of the acquired immunodeficiency syndrome. *N. Engl. J. Med.* **310**:1682-1688.
16. Ng, V. L., I. Gartner, L. A. Weymouth, C. D. Goodman, P. C. Hopewell, and W. K. Hadley. 1989. The use of mucolysed induced sputum for the identification of pulmonary pathogens associated with human immunodeficiency virus infection. *Arch. Pathol. Lab. Med.* **113**:488-493.
17. Ng, V. L., D. M. Yajko, L. W. McPhaul, I. Gartner, B. Byford, C. D. Goodman, P. S. Nassos, C. A. Sanders, E. L. Howes, G. Leoung, P. C. Hopewell, and W. K. Hadley. 1990. Evaluation of an indirect fluorescent-antibody stain for detection of *Pneumocystis carinii* in respiratory specimens. *J. Clin. Microbiol.* **28**:975-979.
18. Ognibene, F. P., J. Shelhamer, V. Gill, A. M. Macher, D. Loew, M. M. Parker, E. Gelman, A. S. Fauci, J. E. Parrillo, and H. Masur. 1984. The diagnosis of *Pneumocystis carinii* pneumonia in patients with the acquired immunodeficiency syndrome using subsegmental bronchoalveolar lavage. *Am. Rev. Respir. Dis.* **129**:929-932.
19. Pitchenik, A. E., P. Ganjei, A. Torres, D. A. Evans, E. Rubin, and H. Baier. 1986. Sputum examination for the diagnosis of *Pneumocystis carinii* pneumonia in the acquired immunodeficiency syndrome. *Am. Rev. Respir. Dis.* **133**:226-229.
20. Stover, D. E., D. A. White, P. Romano, and R. Gellene. 1984. Diagnosis of pulmonary disease in the acquired immunodeficiency syndrome. *Am. Rev. Respir. Dis.* **130**:659-662.