

Zygomycosis Caused by *Apophysomyces elegans*

MARION A. WIEDEN,¹ KAREN K. STEINBRONN,¹ ARVIND A. PADHYE,^{2*} LIBERO AJELLO,² AND
F. W. CHANDLER³

Laboratory Service, Veterans Administration Medical Center, Tucson, Arizona 85723,¹ and Division of Mycotic Diseases²
and Division of Host Factors,³ Center for Infectious Diseases, Centers for Disease Control, Atlanta, Georgia 30333

Received 30 January 1985/Accepted 9 July 1985

A case of zygomycosis caused by *Apophysomyces elegans* in a diabetic, obese female is described. The fungus gained entry into the body through injury to the skin, penetrating the keratin, epidermis, and dermis. Hyphal angioinvasion was observed. Fungal elements invaded the subcutaneous fat, skeletal muscle fibers, nerves, and large blood vessels, resulting in the spread of the infection. The rapidity with which *A. elegans* invaded the blood vessels left no choice except amputation of the leg to stop the spread of the infection. This zygomycetous fungus closely resembles *Absidia corymbifera*. It is distinguished by its prominent campanulate apophyses. In its gross colony characteristics and failure to sporulate on routinely used media it resembles *Saksenaea vasiformis*.

In a compromised host, zygomycosis, caused by members of the order *Mucorales* and *Entomophthorales*, often becomes a serious and life-threatening infection. The genera of the family *Mucoraceae* with species known to cause zygomycosis are *Absidia*, *Mucor*, *Rhizomucor*, and *Rhizopus*. According to our present knowledge, *Rhizopus oryzae* is the most frequently encountered agent of zygomycosis in humans, followed by *R. rhizopodiformis*, *Absidia corymbifera*, and *Rhizomucor pusillus* (6). Species from families other than the *Mucoraceae* that have been incriminated as etiologic agents of zygomycosis are *Cunninghamella bertholletiae* (family *Cunninghamellaceae*), *Mortierella wolfii* (family *Mortierellaceae*), *Saksenaea vasiformis* (family *Saksenaeeaceae*), and *Syncephalastrum racemosum* (family *Syncephalastraceae*) (6).

In 1979, Misra et al. (4) isolated a zygomycetous fungus from two soil samples collected in a mango orchard in northern India and described it as a new taxon, *Apophysomyces elegans*, to characterize its distinct and impressive apophyses. In 1982, *A. elegans* was isolated from the bronchial washings of a patient in the United States (2). Two cases of traumatic zygomycosis caused by *A. elegans* and involving the extremities were reported in 1982 (R. E. Winn, P. D. Ramsey, and E. D. Adams, Clin. Res. 30:382A, 1982) and again in 1984 (R. E. Winn, M. G. Rinaldi, P. Ramsey, and E. D. Adams, Abstr. Annu. Meet. Am. Soc. Microbiol. 1984, F29, p. 297). We present a recent case of zygomycosis that resulted from the traumatic implantation of *A. elegans* in a diabetic patient.

CASE REPORT

A 49-year-old, diabetic obese woman was admitted to the Tucson Veterans Administration Medical Center from the Sells Arizona Indian Hospital because of a left tibial wound infection. She had fallen and scraped her leg 11 days before admission but sought no medical attention until after the wound worsened. Swelling, redness, and blackened areas developed over a 72-h period with the onset of fever. She was admitted to the Sells Arizona Indian Hospital 6 days after the injury occurred and was initially treated with nafcillin, with no response. Upon transfer to the Tucson Veterans

Administration Medical Center, she was treated with clindamycin, gentamicin, and nafcillin. On the next day the wound was debrided extensively, and the fragments of skin and subcutaneous tissue that showed black-green areas of discoloration and blistering were submitted for a histologic examination and culturing. Routine bacteriologic cultures of debrided tissue yielded *Escherichia coli*, *Klebsiella pneumoniae*, and beta-hemolytic *Streptococcus pyogenes* group G. Routine cultures of debrided tissue on Sabouraud dextrose agar containing chloramphenicol and on Sabouraud dextrose agar containing chloramphenicol and cycloheximide yielded floccose, white to dirty-white, fast-growing fungal colonies of a zygomycete. The mold did not sporulate when subcultured on several routinely used mycological media.

Debridement was considered inadequate to save the leg

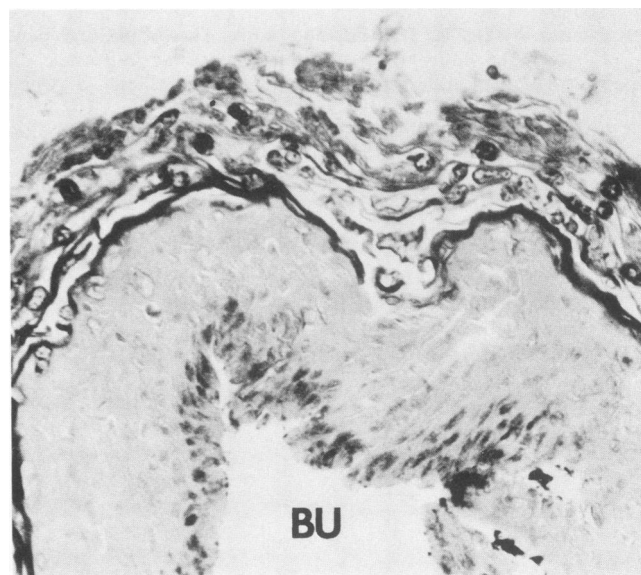


FIG. 1. Proliferating hyphae of *A. elegans* in hyperkeratotic layer of elevated epidermis. A subepidermal bulla (BU) is partially shown. HE stain; $\times 150$.

* Corresponding author.

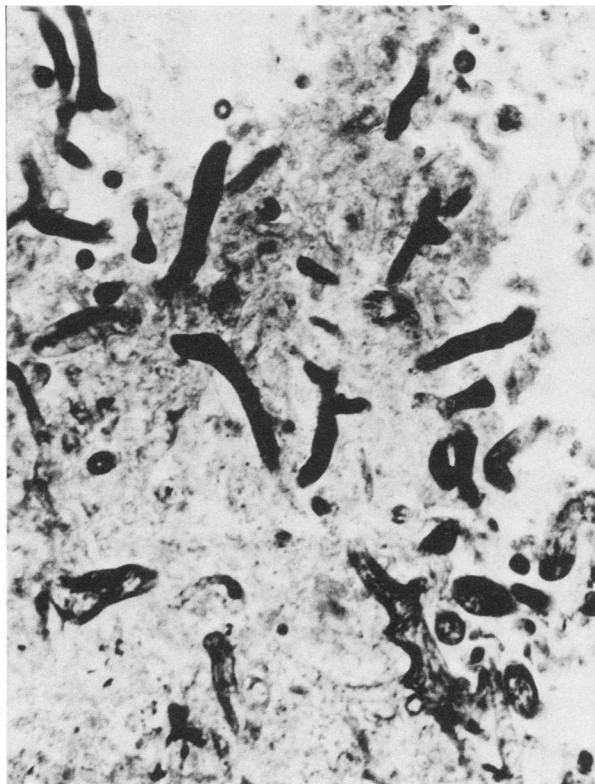


FIG. 2. Broad, randomly branched, and infrequently septate hyphae of *A. elegans* in necrotic area of dermis. The inflammatory reaction is minimal in this field. HE stain; $\times 300$.

because of the patient's vascular disease and poorly controlled diabetes mellitus. Three days later the patient underwent a guillotine amputation of the left leg above the knee. Microscopic examination once again revealed massive amounts of broad, coenocytic hyphae that stained with hematoxylin. Vascular invasion was also noted. The patient received 790 mg of amphotericin B after her amputation.

The fungal isolate (no. 5424), along with tissue blocks of debrided and amputated tissues, were sent to the Division of Mycotic Diseases, Center for Infectious Diseases, Centers for Disease Control, Atlanta, Ga., for specific identification of the zygomycete.

RESULTS

Histopathologic findings. Some of the debrided tissue fragments showed segmental hyperkeratosis and acanthosis of the intact epidermis, and others showed focal detachment of the epidermis and accumulations of neutrophils, proteinaceous fluid, and cellular debris at the dermal-epidermal junction that resulted in the formation of vesicles and bullae (Fig. 1). In these tissues and in others with focal or complete ulceration of the epidermis, there was a mixed suppurative and necrotizing inflammatory reaction in the dermis, subcutaneous tissue, and underlying skeletal muscle. Foci of suppurative necroses and hemorrhages were usually associated with necrotizing vasculitis involving arteries and veins.

Many areas of necrosis and inflammation contained broad, randomly branched, thin-walled hyphae with irregular contours and infrequent septations—morphologic features characteristic of a zygomycete in tissues (Fig. 2). There was a marked variation in the width (5 to 22 μm) and shape of the

hyphae, especially those on or near the surface of the wound. Some hyphae were collapsed, folded, twisted, and ribbon like. With the hematoxylin and eosin (HE) stain, most hyphae were strongly hematoxylinophilic and clearly delineated. In contrast, they were weakly stained by the Grocott-Gomori methenamine-silver procedure and often appeared empty. Sporangia, sporangiospores, and chlamydo spores were not detected, and the hyphae of *A. elegans* in the tissue were morphologically similar to those of the pathogenic zygomycetes of the order *Mucorales*.

In some areas of hyperkeratosis, proliferating hyphae in the keratin layer were seen penetrating the intact epidermis and invading the dermis and dermal blood vessels (Fig. 3A and B). Inflammation was absent or minimal in these zones

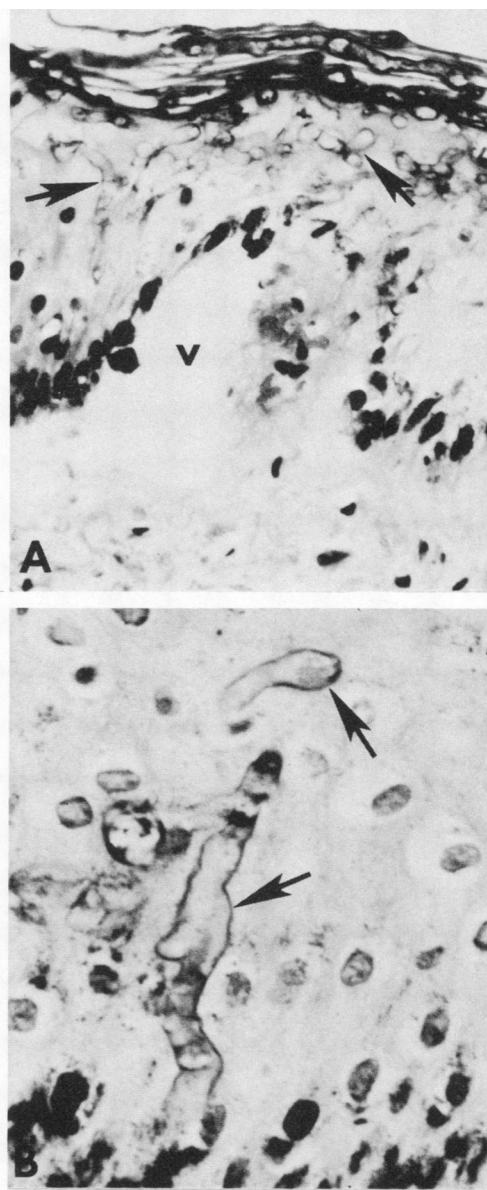


FIG. 3. (A) Penetration of intact epidermis by mucoraceous hyphae (arrows). A vesicle is seen at the dermal-epidermal junction. HE stain; $\times 150$. (B) Detail of hyphae (arrows) directly penetrating intact epidermis. HE stain; $\times 600$.

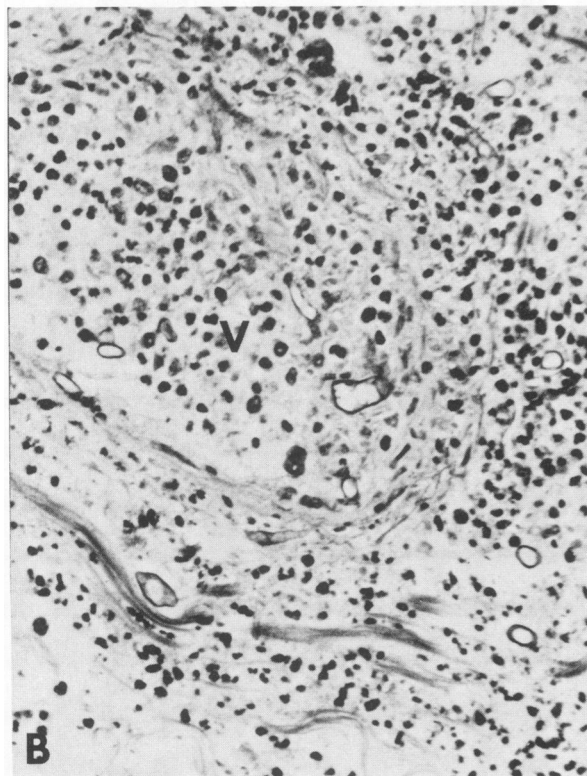
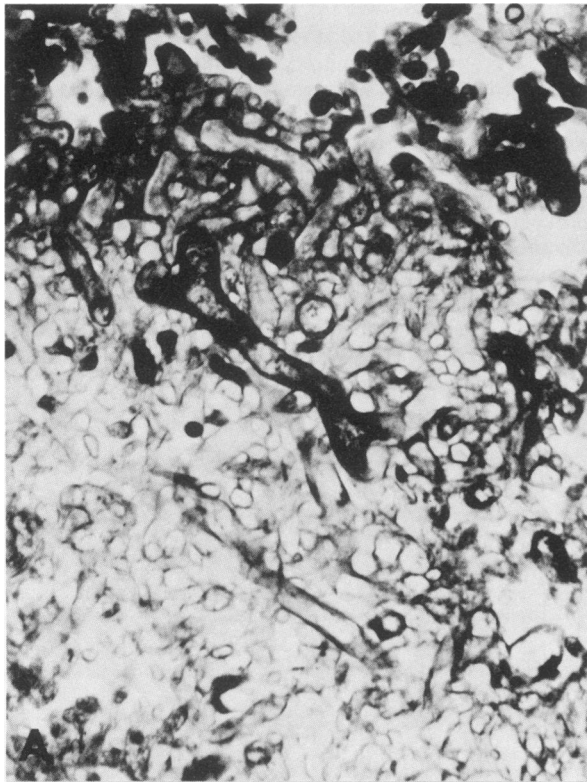


FIG. 4. (A) Massive numbers of compact, randomly oriented, and macerated hyphae at the base of an epidermal ulcer. HE stain; $\times 300$. (B) Suppurative inflammation and invasion of a dermal blood vessel (V) by hyphae of *A. elegans*. HE stain; $\times 300$.

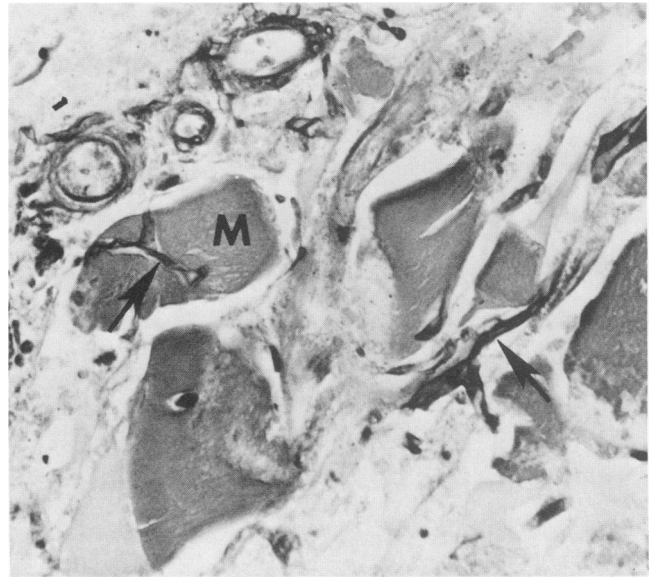


FIG. 5. Hyphae of *A. elegans* (arrows) invading skeletal muscle fibers (M). Grocott-Gomori methenamine-silver stain with HE counterstain; $\times 150$.

of epidermal invasion, despite the presence of numerous hyphae. In ulcerated tissue fragments, massive numbers of compact, randomly oriented, and sometimes macerated hyphae and hyphal fragments covered the denuded surface and aggressively invaded the underlying tissue and the walls and lumina of blood vessels (Fig. 4A and B). Hyphal angioinvasion and thrombosis often resulted in hemorrhagic infarcts. Fungal elements invaded the subcutaneous fat and skeletal muscle fibers (Fig. 5). Elongated hyphae were especially numerous along nerves, larger blood vessels, and musculofascial planes, sites that appeared to augment the rapid spread of the infection. There was no histologic

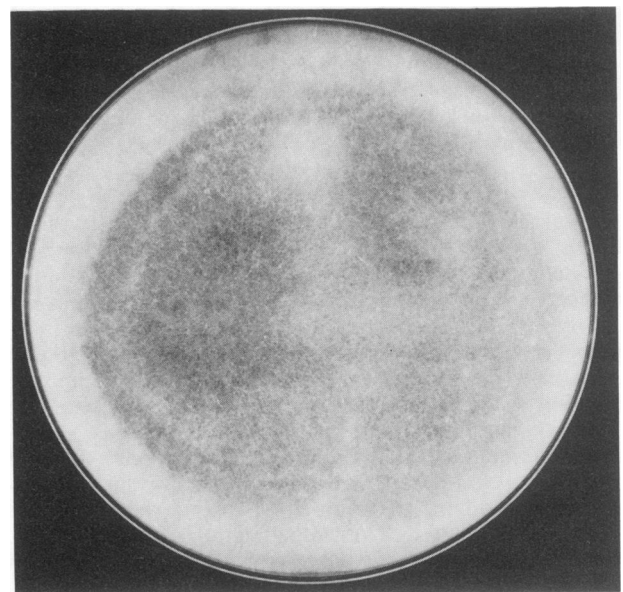


FIG. 6. Colony of *A. elegans* on Sabouraud dextrose agar after 7 days at 25°C.

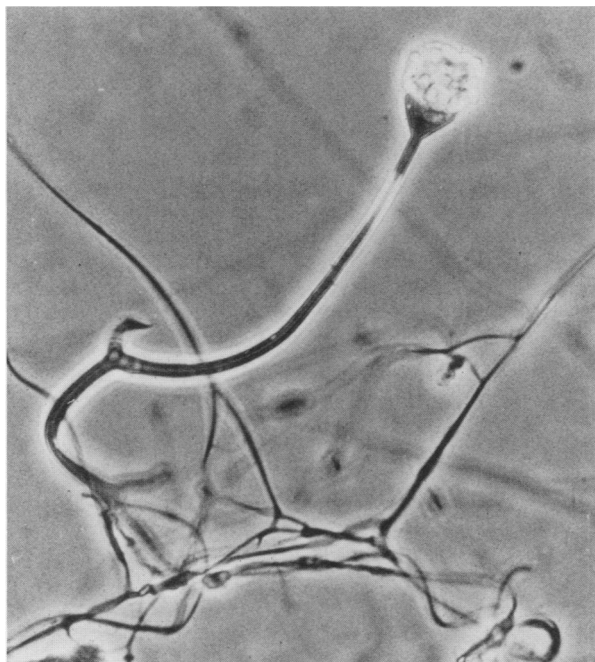


FIG. 7. Photomicrograph showing rhizoids, foot cell, sporangiophore, apophysis, and sporangium of *A. elegans*. LPCB; $\times 560$.

evidence of a coexisting mycosis. The host response to this fungus was similar to that described for infections by other mucoraceous zygomycetes.

Mycological findings. The colonies of *A. elegans* on Sabouraud dextrose agar were fast growing, covering the entire surface of the petri plates (15 by 100 mm) in 7 days at 25°C. They were floccose and had erect aerial mycelial growth approaching the upper lid of the petri plates (Fig. 6). The colonies when young were white and became creamy white to yellow upon aging. The fungus grew well at 37, 40, and 42°C. The colonies were similar to those observed at 25°C.

Slide cultures with cornmeal and potato glucose agars failed to promote sporulation. The isolate was then grown by the procedure of Ellis and Ajello (2). Briefly, the fungus was grown on cornmeal-glucose-sucrose-yeast extract agar (cornmeal agar, 17 g [Difco Laboratories]; glucose, 2 g; sucrose, 3 g; yeast extract, 1 g [Difco]; distilled water, 1 liter) for 7 days at 30°C, and a 3-mm³ agar block permeated with hyphae and the accompanying aerial hyphae was cut and placed on the surface of sterilized and solidified 1% water agar in a petri plate. The inoculated water agar plate was incubated at 30°C for 5 to 7 days, whereupon abundant sporulation occurred.

Sporangiophores generally developed singly, arising at the ends of stolon-like hyphae but not always opposite to groups of underlying rhizoids. They were unbranched and slightly tapered towards the apex (Fig. 7). The sporangiophores below the prominent apophyses were grayish brown, dark, thick-walled, up to 300 μm long, and 3 to 5 μm wide near the apophyses. The apophyses were dark, campanulate, or champagne glass shaped (Fig. 8). The sporangia were borne terminally at the tips of the sporangiophores. They were pyriform, multisporied, distinctly apophyseal, columellar, white at first, yellowish brown later, and 20 to 50 μm in diameter. The sporangial wall was thin, transparent, smooth, and deliquescent. The sporangiospores were mostly oblong,

subglobose, and subhyaline. They were light brown, smooth walled, and measured 5 to 8 μm by 4 to 5 μm (Fig. 8). Zygospores were not observed.

When compared with two authentic isolates of *A. elegans*, the isolate in this report was found to be identical. It has been deposited in the Division of Mycotic Diseases culture collection with the accession number B-3956. A living culture of B-3956 has been deposited in the American Type Culture Collection, Rockville, Md. (ATCC 58336).

DISCUSSION

Eight species belonging to the genera *Absidia*, *Mucor*, *Rhizomucor*, and *Rhizopus* of the family *Mucoraceae* are known to be etiologic agents of zygomycosis in humans. *A. elegans*, a new member of the family, has also been shown to cause zygomycosis. In the present case, the patient suffered from probable uncontrolled diabetes mellitus, a condition generally associated with rhinocerebral zygomycosis. Like other agents, *A. elegans* exhibited a strong predilection to invade the vascular system.

In general morphology, *A. elegans* closely resembles *Absidia* species in producing pyriform, apophyseal, multisporied sporangia on sporangiophores which arise on stolons but typically not opposite rhizoids. It differs from *Absidia* species in that it has more pronounced apophyses, which are funnel or bell shaped, and a hyphal segment reminiscent of the foot cells of *Aspergillus* species (Fig. 7). The characteristic darkening and thickening of the sporangiophore wall below the apophysis that narrows the lumen of the sporangiophore differentiates the genus *Apophysomyces* from related genera (4).

A. elegans resembles *S. vasiformis* in gross colony morphology and its failure to sporulate on routinely used media. Unless nutritionally deficient media are used, neither fungus sporulates readily (2).

In each of the three known cases of infection by *A. elegans*, the portal of entry into the body was probably

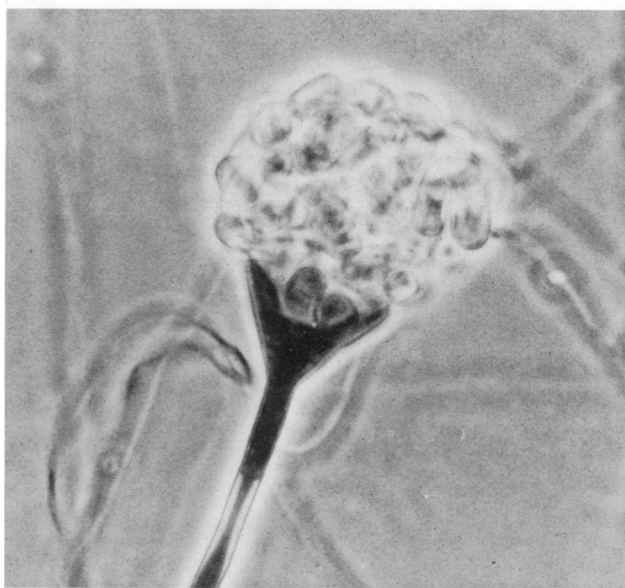

FIG. 8. Champagne-glass-shaped apophysis supported by a dark, thick-walled sporangiophore below the apophysis and oblong and subglobose sporangiospores of *A. elegans*. LPCB; $\times 1,400$.

through traumatized skin. Such is also the case with some of the infections caused by *S. vasiformis* (1, 3, 5). After gaining entry into the body, both of these zygomycetes invade blood vessels and disseminate to other organs. In the present case, the rapidity with which *A. elegans* invaded the blood vessels of the leg left no choice except amputation to control the spread of infection.

LITERATURE CITED

1. Ajello, L., D. F. Dean, and R. S. Irwin. 1976. The zygomycete *Saksenaea vasiformis* as a pathogen of humans with a critical review of the etiology of zygomycosis. *Mycologia* **68**:52-62.
2. Ellis, J. J., and L. Ajello. 1982. An unusual source for *Apophysomyces elegans* and a method for stimulating sporulation of *Saksenaea vasiformis*. *Mycologia* **74**:144-145.
3. Hay, R. J., C. K. Campbell, W. M. Marshall, B. I. Ress, and J. Pincott. 1983. Disseminated zygomycosis (mucormycosis) caused by *Saksenaea vasiformis*. *J. Infect.* **7**:162-165.
4. Misra, P. C., K. J. Srivastava, and K. Lata. 1979. *Apophysomyces*, a new genus of the Mucorales. *Mycotaxon* **8**:377-382.
5. Oberle, A. D., and R. L. Penn. 1983. Nosocomial invasive *Saksenaea vasiformis* infection. *Am. J. Clin. Pathol.* **80**:885-888.
6. Scholer, H. J., E. Muller, and M. A. A. Schipper. 1983. Mucorales, p. 9-59. In D. H. Howard (ed.), *Fungi pathogenic for humans and animals*, vol. A. Marcel Dekker, Inc., New York.