

## Opportunistic Infection of the Spleen Caused by *Aureobasidium pullulans*

IRA F. SALKIN,<sup>1\*</sup> JORGE A. MARTINEZ,<sup>2†</sup> AND MAGGI E. KEMNA<sup>1</sup>

Wadsworth Center for Laboratories and Research, New York State Department of Health, Albany, New York 12201,<sup>1</sup> and  
Chenango Memorial Hospital, Norwich, New York 13815<sup>2</sup>

Received 16 December 1985/Accepted 27 January 1986

**The mold *Aureobasidium pullulans* was isolated on several nutrient media from a splenic abscess in a patient with disseminated lymphoma. Examination of stained smears and paraffin sections revealed fungal structures characteristic of this organism. This is the first reported association of *A. pullulans* with an opportunistic visceral infection.**

Although saprobic fungi are routinely isolated from clinical specimens, tissue invasion must be established before such fungi may be considered the etiologic agents of opportunistic diseases. The incidence of such proven opportunistic fungal infections, especially in immunocompromised patients, has increased significantly in recent years (7).

To identify these potential pathogens, clinical laboratorians are finding it necessary to learn the key characteristics of an increasing number of saprobic molds and yeasts. In addition, laboratorians must be aware of the clinical incidents involving these fungi to judge the importance of the saprobes isolated from clinical specimens.

*Aureobasidium pullulans* is a saprobic mold which has been recovered from widely diverse habitats (2). Although it has occasionally been associated with superficial infections in humans (1, 3, 5, 8-10), McGinnis (6) considered many of these reports to be "questionable," i.e., unsubstantiated by the authors' clinical, mycologic, or histopathologic evidence. However, *A. pullulans* has not previously been implicated in an opportunistic visceral infection.

We present the first authenticated case of an infection of a viscus caused by *A. pullulans*. The mold was observed upon direct microscopic examination of a tissue homogenate and in microscopic studies of stained biopsy sections. In addition, it was recovered on two of three isolation media inoculated with the tissue homogenate.

(A portion of the results was presented previously [I. F. Salkin, J. A. Martinez, and M. E. Kemna, Abstr. Annu. Meet. Am. Soc. Microbiol. 1986, F43, p. 404].)

### MATERIALS AND METHODS

**Clinical history.** A 67-year-old man was admitted to Chenango Memorial Hospital complaining of loss of appetite and generalized weakness. He had a history of multiple hospital admissions as well as prolonged periods of loss of appetite, malnutrition, and dehydration. The only unusual finding upon physical examination at the time of this admission was an enlarged, nontender liver palpable 6 to 7 cm below the right costal margin.

During his hospitalization the patient developed spiking fevers (104°F), tremors in the extremities, shortness of

breath, and decreased bowel sounds. His hepatomegaly persisted. No bacterial or fungal infectious agents were isolated from sputum or urine specimens. On the 14th day of hospitalization his blood pressure dropped off markedly, and the patient died.

Examination at autopsy revealed an old, healed myocardial infarct of the left anterior wall, interstitial fibrosis of the lungs, and severe, chronic inflammation of the lungs, liver, and pancreas. A diffuse, malignant lymphoma of the large cleaved-cell type (histiocytic lymphoma) had invaded all body organs. An abscess approximately 4 cm in diameter and composed of necrotic, purulent tissue was found on a cut section of the spleen.

**Laboratory studies.** A portion of tissue from the abscess was submitted to the Mycology Laboratory of the Wadsworth Center for microscopic and mycologic studies.

Part of the specimen was fixed in 10% Formalin, embedded in paraffin, sectioned, and stained with hematoxylin and eosin or Grocott methenamine-silver stain.

Another part of the abscess specimen was homogenized in 2 ml of brain heart infusion broth (BBL Microbiology Systems, Cockeysville, Md.) for 1 min with a Tri-R (Jamaica, N.Y.) tissue homogenizer. Portions of the homogenate were streaked as for bacterial isolation onto 100-mm petri plates containing 20 ml of one of the following three isolation media: (i) cystine heart agar supplemented with hemoglobin (Difco Laboratories, Detroit, Mich.), penicillin, and streptomycin; (ii) Mycosel (BBL); and (iii) Sabouraud glucose agar fortified with penicillin and streptomycin (Difco). All cultures were incubated at 27°C and observed daily for growth.

### RESULTS

**Microscopic studies.** The abscess was composed of an amorphous pink material with cellular debris and was surrounded by tumor cells, lymphoid elements, and hemorrhages. Microscopic examination of sections stained with hematoxylin and eosin revealed tumor involvement in the blood vessels and sinusoids, with marked congestion and focal intraparenchymatous hemorrhages. Sections stained with Grocott methenamine-silver stain showed short to relatively long hyphal segments, many with budlike cells arising at the nodes, as well as budding, yeastlike cells (Fig. 1). These structures are characteristic of *A. pullulans*.

**Mycologic studies.** Lactophenol-cotton blue-stained films

\* Corresponding author.

† Present address: 8923 National, Morton Grove, IL 60053.

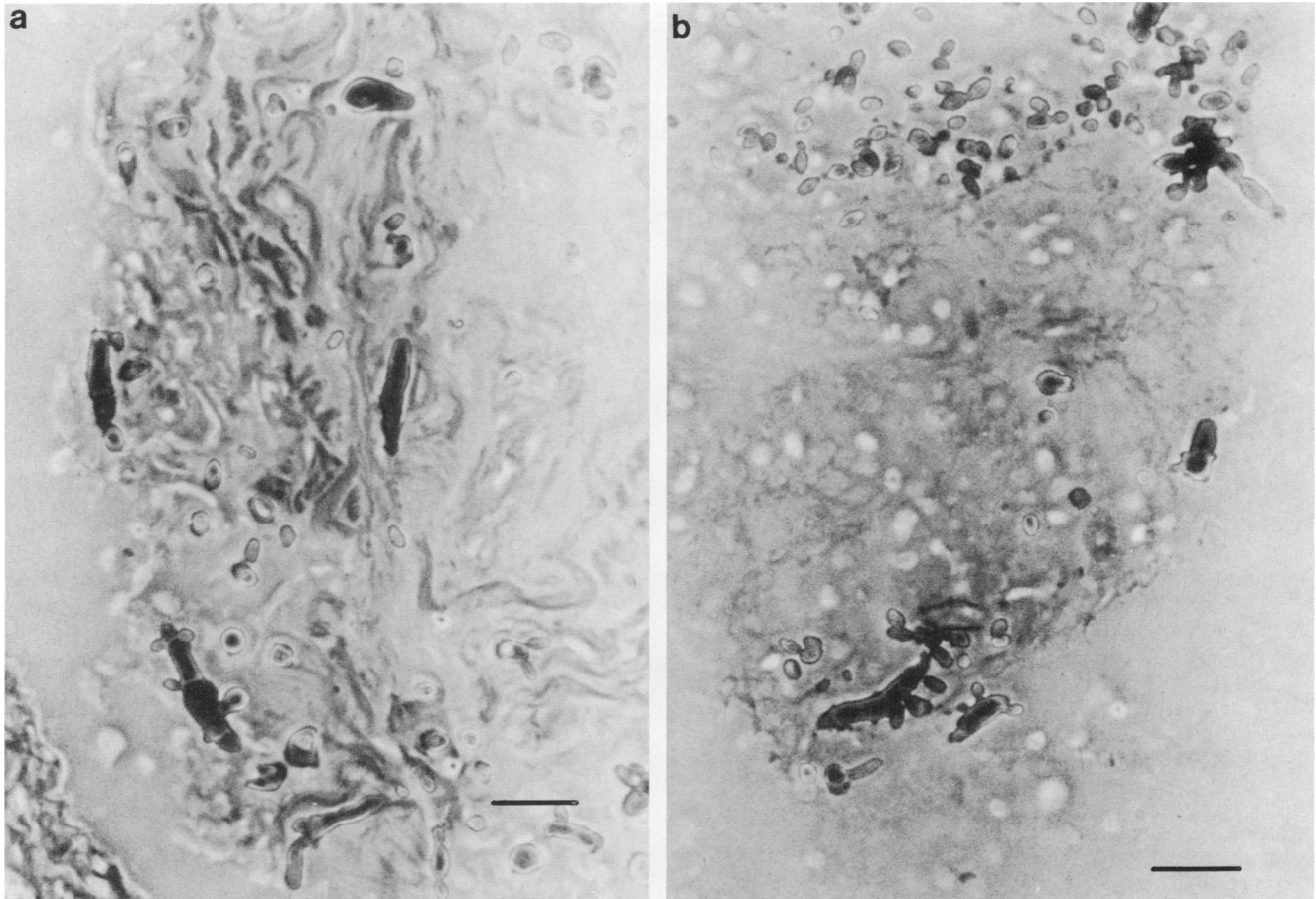


FIG. 1. Hyphal fragments, some with budlike cells (a and b) and budding, yeastlike cells (b) characteristic of *A. pullulans* in tissue from splenic abscess. Grocott methenamine-silver stain. Bar, 20  $\mu$ m.

of the tissue homogenate revealed short hyphal segments with a few budding cells, morphologically similar to the structures found in sectioned material.

There was no fungal growth on Mycosel, but the cystine heart agar-hemoglobin-penicillin-streptomycin and fortified Sabouraud glucose agar cultures yielded a number of shiny, mucoid, yeastlike colonies which were initially white but later turned black. No other fungus was isolated on either medium. A portion of growth from one colony was used to seed a cornmeal agar slide culture. Microscopic observation of the latter culture revealed branching hyphae, with one-celled conidia forming either singly at intervals along the length of the filaments or in clusters at the nodes (Fig. 2).

One- or two-celled, darkly pigmented, thick-walled conidia formed randomly within the hyphae after 7 to 10 days of incubation at 30°C. Overall the organism appeared similar to that in the stained sections and confirmed our identification of *A. pullulans*.

#### DISCUSSION

Isolation of *A. pullulans* and the observation of hyphal fragments with blastoconidia in both the tissue homogenate and stained tissue sections clearly suggest that this fungus was the etiologic agent of an opportunistic infection associated with the abscess. Although the portal of entry and mode of dissemination remain unclear, the patient's depressed immunologic state caused by his malignant lymphoprolifer-

ative disorder probably allowed the secondary invasion by *A. pullulans*.

*A. pullulans* has been described under more than 50 synonyms, due in large part to its morphologic variability (2). Colonies may be mucoid, pasty, or dry in texture; shiny to dull in appearance; and with a smooth flat to highly folded surface. They are usually white when young and generally become black with age, but they may remain white or become black in irregularly shaped sections.

The colonies are composed of hyaline to light brown, irregularly branched hyphae. Hyaline, one-celled, ovoid conidia form on short denticles, either in clusters or solitarily along the length of the hyphae. These primary conidia frequently form secondary blastoconidia, and it is the abundance of these budding conidia which gives the colony a yeasty appearance. Dark, thick-walled, one- or two-celled arthroconidia (more frequently called chlamydoconidia) form at irregular intervals within the hyphae as the colony matures.

Most laboratorians report the identification of *A. pullulans* without careful investigation on the basis of its yeasty appearance, color change from white to black, and formation of thick-walled arthroconidia. However, several other fungi also form dark, thick-walled arthroconidia (*Scytalidium* species) or have a black, yeasty appearance (*Wangiella* species). In addition, *A. pullulans* is not the only species of *Aureobasidium* (4). Consequently, its identification should

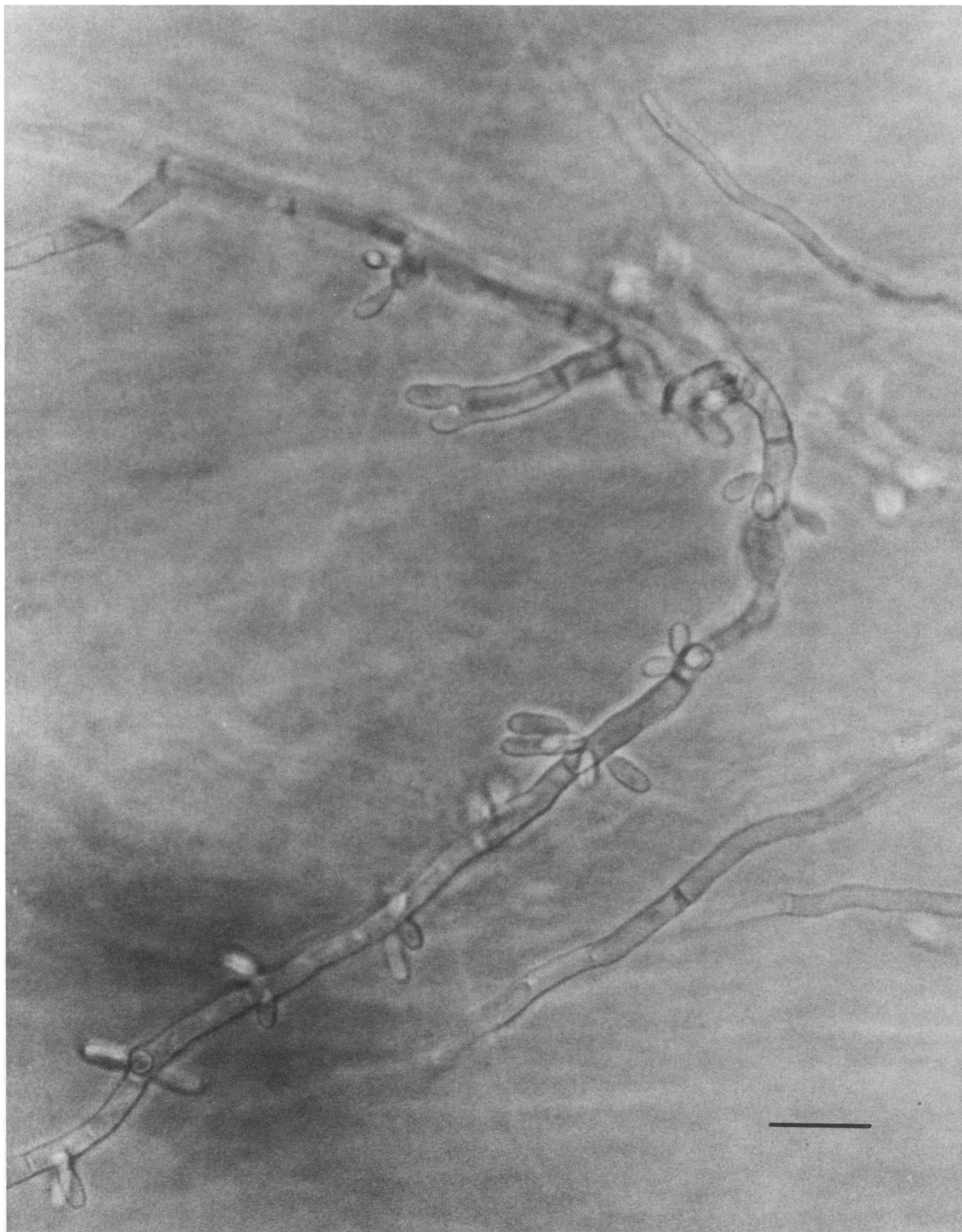

FIG. 2. Cornmeal agar slide culture of mold isolated from abscess tissue homogenate, showing blastoconidia typical of *A. pullulans*. Bar, 20  $\mu$ m.

be considered proven only after detailed studies of its morphologic features in slide cultures.

#### ACKNOWLEDGMENTS

We thank M. R. McGinnis for his review of the tissue sections and J. R. Brereton for the patient's clinical history.

#### LITERATURE CITED

1. Akagi, M., T. Fugino, S. Hayashi, Y. Yamamoto, and T. Akabe. 1958. A case of pulmonary infection caused by black yeast-like fungus. *Med. J. Osaka Univ.* 8:585-599.
2. Cooke, W. B. 1959. An ecological life history of *Aureobasidium pullulans* (De Bary) Arnaud. *Mycopathol. Mycol. Appl.* 12:1-45.
3. Haley, L. D. 1950. Etiology of otomycosis. *Arch. Otolaryngol.* 52:202-207.
4. Hermanides-Nijhof, E. J. 1977. *Aureobasidium* and allied genera. *Stud. Mycol.* 15:141-177.
5. Leavell, U. M., Jr., E. B. Tucker, and R. Muelling. 1966. Blue dot infection of the scalp of two brothers. *J. Kentucky Med. Assoc.* 64:1107-1110.
6. McGinnis, M. R. 1980. *Laboratory handbook of medical mycology.* Academic Press, Inc., New York.
7. Rippon, J. W., P. M. Arnow, R. A. Larson, and K. L. Zang. 1985. Golden tongue syndrome caused by *Ramichloridium schulzeri*. *Arch. Dermatol.* 121:892-894.
8. Vermeil, C., A. Gordeff, M.-J. Leroux, O. Morin, and M. Bouc. 1971. Blastomycose cheloidienne a *Aureobasidium pullulans* (De Bary) Arnaud en Bretagne. *Mycopathol. Mycol. Appl.* 43:35-39.
9. Vieira, J. R. 1959. Onicomycose por *Aureobasidium pullulans* (De Bary) Arnaud. *Proc. Sixth Int. Cong. Trop. Med. Malaria* 4:768-777.
10. Zapater, R. C. 1980. Keratomycoses caused by dematiaceous fungi, p. 82-87. *In Proceedings of the Fifth International Conference on the Mycoses* (scientific publication no. 396). Pan American Health Organization, Washington, D.C.