

Elucidation of *Strongyloides stercoralis* by Bacterial-Colony Displacement

KIM J. PANOSIAN, PETER MARONE, AND STEPHEN C. EDBERG*

Clinical Microbiology Laboratory, Department of Laboratory Medicine, Yale University School of Medicine, New Haven, Connecticut 06510

Received 26 December 1985/Accepted 8 April 1986

Two cases of unsuspected *Strongyloides stercoralis* infection were elucidated by the displacement of bacterial colonies on primary plating media. Observation of primary plates inoculated for the diagnosis of bacterial pneumonia or gastroenteritis revealed that normal flora colonies had been moved and were aligned in a pathway, or track. This unusual colony alignment prompted us to request a stool for the examination of parasites, and *S. stercoralis* was found. It was concluded that the parasite is capable of motility on agar surfaces, resulting in the displacement of bacterial colonies that make up the normal flora.

Infection with *Strongyloides stercoralis* results in manifestations of disease ranging from an asymptomatic carrier state to acute intestinal infection with diarrhea to severe multisystem infection, which has a high mortality rate. The severest form, termed hyperinfection or disseminated strongyloidiasis, is seen most commonly when an intestinal carrier of the parasite becomes acutely immunocompromised with steroids or other chemoimmunosuppressive agents (3, 6, 8). Since this form of infection carries with it a mortality rate as high as 85%, it is necessary to detect and eradicate any *S. stercoralis* organisms inhabiting the intestine before immunosuppressive therapy is instituted (3, 8).

From the primary agar plates of routine stool and sputum cultures for bacteria from two patients, an unusual displacement of bacterial colonies from the streak marks was noted. The colonies followed a pathway, or track, as if the inoculum had been dragged across the surface of the agar. Because the bacterial-colony displacement pattern resembled the track of a living organism, the stools were examined for parasites. *S. stercoralis* was found in both patients in whose specimens the phenomenon was observed. To our knowledge, this finding has previously been demonstrated only with sputum cultures (2).

CASE REPORTS

Case report 1. A 58-year-old Peruvian man was admitted to Yale-New Haven Hospital in December 1984 for evaluation of cutaneous nodules on his extremities; 8 months earlier, he had immigrated to Connecticut. He had been healthy, with no previous hospitalization. On physical examination, he was afebrile and had multiple 1- to 2-mm-wide papular nodules on the upper extremities and abdomen and petechiae on both lower extremities. The remainder of his physical examination was unremarkable. The admission laboratory values included normal hematocrit and platelet count and a leukocyte count of 18,500 cells per mm³ with 73% neutrophils (2% immature forms), 10% lymphocytes, 1% monocytes, 7% eosinophils, and 5% atypical lymphocytes. Two stools did not reveal ova or parasites. Biopsy of the skin nodules and petechiae showed vasculitis, compati-

ble with periarteritis nodosum. He was discharged on a dosage of 60 mg of prednisone daily.

The patient had minimal improvement of his skin lesions on prednisone, and later in December 1984, cytoxan, at 50 mg three times a day, was added. The skin lesions significantly improved, and subsequently the steroid dosage was lowered to 60 mg every other day.

In February 1985, the patient was readmitted with fever and diffuse lymphadenopathy of 2 to 3 days duration. His temperature was 104°F (40°C) orally, and the cervical and supraclavicular lymph nodes were enlarged bilaterally.

The admission laboratory values included a leukocyte count of 16,000 cells per mm³ with 78% neutrophils (7% immature forms), 4% lymphocytes, 5% monocytes, 4% eosinophils, and 1% atypical lymphocytes. No stools for ova and parasites were requested. Biopsy of an inguinal lymph node showed a T-cell non-Hodgkin's lymphoma. The patient was discharged and treated with cytoxan, vincristine, adriamycin, and prednisone.

In March 1985, 10 days after the institution of his lymphoma chemotherapy, the patient was readmitted to the hospital with acute hemoptysis, respiratory distress, anemia, leukopenia, and diffuse infiltrates on chest X ray. His temperature was 101°F (38.3°C) orally. The lymphadenopathy was markedly decreased. The admission laboratory values included hemoglobin, 4.7 g/dl; hematocrit, 14.2%; leukocyte count of 1,100 cells per mm³ with 37% neutrophils (15% immature forms), 36% lymphocytes, and 10% monocytes; and erythrocyte sedimentation rate, 7.5 mm/h. A sputum culture grew normal flora and *Staphylococcus aureus*. Bacterial colonies were displaced from their normal positions on the streak marks on the surface of the agar plates. The colonies appeared to have been pulled across the surface of the agar by a moving object (Fig. 1). Of the possible causes of the bacterial-colony displacement, two considerations were further explored, i.e., the presence of an insect or of a nematode traveling across the surface of the agar and leaving a track of bacterial colonies in its path. The laboratory requested additional specimens, and subsequent sputum and stool examination revealed *S. stercoralis* larvae in large numbers.

The patient was treated with 1,500 mg of thiabendazole orally twice a day for 25 days before his stool and sputum

* Corresponding author.

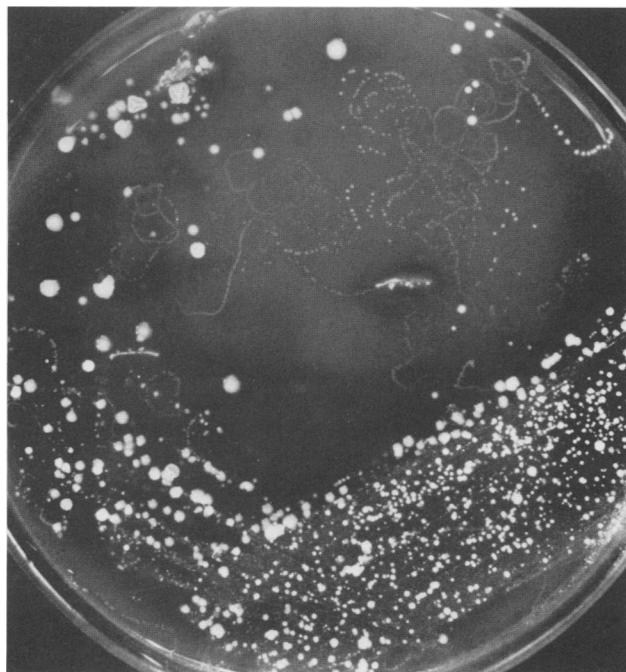


FIG. 1. Bacterial-colony displacement of sputum normal flora on sheep blood agar (case report 1).

became free of larvae. A week after thiabendazole was stopped, the patient developed increasing respiratory distress and recurrence of *S. stercoralis* larvae in sputum. He eventually succumbed to overwhelming strongyloidiasis 5 months after he began taking prednisone.

Case report 2. A 67-year-old male from Puerto Rico was admitted to Yale-New Haven Hospital in May 1985 for surgical resection of oropharyngeal carcinoma.

On physical examination, the patient was afebrile with normal vital signs. A white, fungating mass involved the hypopharynx and larynx. The remainder of the examination was unremarkable. His admission laboratory values included hemoglobin, 10.8 g/dl; hematocrit, 31.3%; and leukocyte count of 7,100 cells per mm³ with 57% neutrophils (4% immature forms), 26% lymphocytes, 10% monocytes, and 3% eosinophils. On hospital day 3, laryngopharyngectomy with jejunal interposition and radical neck dissection was performed.

The postoperative course was complicated by necrosis and a necessary excision of the jejunal flap, *Streptococcus faecalis* septicemia, renal failure, and diarrhea. A stool culture showed normal flora. The bacterial colonies comprising the normal flora were displaced from their streak marks in a manner identical with those observed in the bacterial sputum culture of patient 1. The laboratory requested an additional stool for ova and parasites, which revealed *S. stercoralis* larvae. The leukocyte count at this time was 13,700 cells per mm³ with 2% eosinophils. Thiabendazole (25 mg/kg) was given twice a day orally for 2 days. Three subsequent stools for ova and parasites were negative.

MATERIALS AND METHODS

Sputum and stools for microbes and parasites were processed by commonly accepted methods (4, 7).

RESULTS AND DISCUSSION

Microbiological findings. The sputum culture for patient 1 grew only microbes consistent with normal respiratory flora and *Staphylococcus aureus*. However, on primary plates, bacterial colonies were significantly displaced from the streak mark left from plating the specimen on the surface of the agar. At various points away from the streak marks, it appeared that microbial inoculum had been dragged across the surface of the agar, with colonies deposited at intervals along the pathways (Fig. 1).

The primary plates from the stool culture of patient 2 grew microbes consistent with normal fecal flora. Bacterial colonies were displaced from the streak marks on primary plated agar in the same manner as seen with patient 1.

Strongyloides colonization should be suspected in virtually any individual from a region in which *Strongyloides* sp. is endemic, regardless of length of time since immigration. Because of the risk of hyperinfection, one should be particularly aggressive the diagnosis of individuals from such an area who subsequently are to undergo immunosuppressive therapy. The diagnosis is usually made by the identification of rhabditiform larvae in stool. Examination of stool by the Baermann funnel technique may increase sensitivity when small numbers of larvae are present (1). In a series of 100 cases with an average of nine stool examinations per person, only 27% had identifiable larvae. A positivity of 91% resulted when duodenal aspirates were examined. The duodenal capsule technique (Enterotest) is a simple and convenient method of sampling duodenal contents (1). Therefore, the higher yield is thought to occur when both stool and duodenal aspirate are examined (5).

Our first case is an example of fatal *Strongyloides* hyperinfection. The patient's small intestine was presumably infected with the organism when steroid therapy for periarteritis nodosum was begun, although two routine stool exams for ova and parasites failed to reveal the organism. The first hint of *Strongyloides* infection occurred when the bacterial-colony displacement was seen. An extended treatment period with thiabendazole was required to clear the organism from sputum and stool. The larva-free interval was short-lived, however, and the organism reappeared 7 days after cessation of therapy.

Our second case was a *Strongyloides* infection presumably limited to the intestine. Bacterial-colony displacement seen on stool culture alerted us to the possibility of *Strongyloides* infection. The organism was successfully treated.

Infection with *S. stercoralis* should be suspected in any individual from an area in which the organism is endemic, regardless of the eosinophil count. Recognition of the bacterial-colony displacement on agar should alert the microbiologist to the possibility of *S. stercoralis* infection.

LITERATURE CITED

1. Garcia, L. S., and L. R. Ash. 1975. Diagnostic parasitology: clinical laboratory manual, p. 23, 29. The C. V. Mosby Co., St. Louis.
2. Harris, A., D. M. Musher, V. Fainstein, E. J. Young, and J. Clarridge. 1980. Disseminated strongyloidiasis: diagnosis made by sputum examination. *J. Am. Med. Assoc.* 244:65-66.
3. Igra-Siegman, Y., R. Kapila, P. Sen, Z. C. Kaminski, and D. B. Louria. 1981. Syndrome of hyperinfection with *Strongyloides stercoralis*. *Rev. Infect. Dis.* 3:397-407.
4. Isenberg, H. D., J. A. Washington II, A. Balows, and A. C. Sonnenwirth. 1985. Collection, handling, and processing of spec-

- imens, p. 73–98. *In* E. H. Lennette, A. Balows, W. J. Hausler, Jr., and H. J. Shadomy (ed.), *Manual of clinical microbiology*, 4th ed. American Society for Microbiology, Washington, D.C.
5. Pieterse, A. S., and P. C. Blumberg. 1983. Test and teach number forty-four. *Pathology* 15:366–367, 506–507.
 6. Purtilo, D. T., W. M. Meyers, and D. H. Connor. 1974. Fatal strongyloidiasis in immunosuppressed patients. *Am. J. Med.* 56:488–493.
 7. Smith, J. W., and M. S. Bartlett. 1985. Diagnostic parasitology: introduction and methods, p. 595–611. *In* E. H. Lennette, A. Balows, W. J. Hausler, Jr., and H. J. Shadomy (ed.), *Manual of clinical microbiology*, 4th ed. American Society for Microbiology, Washington, D.C.
 8. Wachter, R. M., A. M. Burke, and R. R. MacGregor. 1984. *Strongyloides stercoralis* hyperinfection masquerading as cerebral vasculitis. *Arch. Neurol.* 41:1213–1216.