

Spondylitis and Osteomyelitis Caused by *Kingella kingae* in Children

C. CHANAL,^{1*} F. TIGET,² P. CHAPUIS,³ D. CAMPAGNE,⁴ M. JAN,¹ AND J. SIROT¹

Services de Bactériologie Virologie,¹ Pédiatrie,² Chirurgie Infantile,³ et Radiologie,⁴ Centre Hospitalier Universitaire, Hotel Dieu, 63003 Clermont-Ferrand Cedex, France

Received 24 June 1987/Accepted 14 August 1987

Two cases of documented osteoarticular infections caused by *Kingella kingae* in children are reported. The main bacteriological characteristics and antibiotic susceptibilities of these two isolates are described. The pathology of *K. kingae*, particularly in bones and joints, is reviewed.

Kingella kingae is a fastidious short gram-negative rod which occasionally colonizes the upper respiratory tract (14) and rarely causes serious clinical infections. It was initially designated as *Moraxella* new species 1 by E. O. King (32). Later it was named *Moraxella kingii* (15), corrected to *Moraxella kingae* (3), and finally allocated to the genus *Kingella* as *K. kingae* within the family *Neisseriaceae* (16). Although the organism is considered to be of low pathogenicity (16, 22, 23), it has been shown to be a significant pathogen in human diseases, particularly in children (2, 5, 8, 22, 28), with an apparent tropism for valvular and skeletal tissue (5, 6, 8). Here, we report two additional cases of *K. kingae* infection in children: a spondylitis and an osteomyelitis.

Case 1. A 3-year-old girl was hospitalized with a 3-week history of back pain without fever or any signs of trauma. Her past medical history was negative. On admission, she was afebrile, and her walk was normal. Her physical examination revealed a marked paravertebral contracture, and her vertebral spine was painful on percussion from thoracic vertebra 8 (T8) to lumbar vertebra 2 (L2). A Kernig sign was present, the patellar reflexes were abolished, and the presence of a right Babinski sign was suspected. A bone scan revealed slight uptake in the vertebral bodies of L1 and L2. A spondylitis of the L1-L2 intervertebral disk was radiologically confirmed: tomograms showed a narrowed disk space with irregularities in the adjacent vertebral cortical margins between L1 and L2 (Fig. 1). Laboratory data showed a peripheral leukocyte count of 12,800/mm³ (neutrophils, 61%; lymphocytes, 33%; eosinophils, 1%; and monocytes, 5%). The erythrocyte sedimentation rate was 33 mm/h. Needle biopsy of the L1-L2 space yielded a cloudy fluid which, after gram staining, revealed abundant neutrophils and rare short gram-negative rods. *K. kingae* grew from the aspirate. The strain was susceptible to all of the antimicrobial agents tested except lincomycin. The child was immobilized, and she was treated with intravenous cefotaxime (100 mg/kg per day) and intravenous netilmicin (6.5 mg/kg per day). This therapy was maintained for 3 weeks, followed by orally administered cephalixin (80 mg/kg per day) for 2 months. Reexamination 3 months later revealed the child to be asymptomatic. Laboratory data were normalized. New X rays showed persistent disk space narrowing.

Case 2. A 3-year-old boy was hospitalized with a 1-day history of fever, irritability, and refusal to move his left arm.

His past medical history revealed only three episodes of tonsillitis 6 weeks before admission.

On physical examination he was febrile (38.6°C) and held his left arm flexed. The elbow was red, warm, and swollen, and range of motion was limited. Movement was painful in all directions. Palpation revealed a sharp pain in the proximal radial metaphysis. Laboratory data showed a peripheral leukocyte count of 6,600/mm³ (neutrophils, 57%; lymphocytes, 32%; monocytes, 8%; and basophils, 3%). The erythrocyte sedimentation rate was 15 mm/h. X rays of the left elbow showed only a swelling of soft tissue (Fig. 2A). *K. kingae* grew from one of two blood cultures and was also susceptible to all antimicrobial agents tested except lincomycin. The child was treated with intravenous cephalothin (100 mg/kg per day) and intramuscular netilmicin (6.5 mg/kg per day). The child rapidly became afebrile (in 72 h) and was discharged after 1 week. This treatment was maintained for 7 days, followed by orally administered cephalixin (35 mg/kg per day) for 2 months. On follow-up examination 3 weeks later, the child was clinically normal. New X rays showed an osteolytic lesion in the anterior portion of the proximal radial metaphysis (Fig. 2B). Reexamination 2 months later showed no clinical sequelae.

Both strains were isolated on chocolate agar (Diagnostics Pasteur, Marne la Coquette, France) after 2 days of incubation. Subcultures on sheep blood agar (Diagnostics Pasteur) in 10% CO₂ showed small corroding colonies surrounded by clear zones of beta hemolysis. A Gram stain revealed short gram-negative rods, often forming pairs or short chains. Both isolates were microaerophilic, catalase negative, and oxidase positive. Nitrite was reduced without nitrate reduction, indole was not produced, and urease was negative. Acid was produced from glucose and maltose in liquid peptone medium (Diagnostics Pasteur) with 10% horse serum (Diagnostics Pasteur). No acid was produced from xylose, mannitol, lactose, or sucrose. Susceptibility tests with the agar diffusion method on Mueller-Hinton agar with 5% horse blood (Diagnostics Pasteur) showed that the two strains were susceptible to all β -lactams, aminoglycosides, chloramphenicol, tetracyclines, erythromycin, co-trimoxazole, and pefloxacin. They were resistant to lincomycin as described previously in the literature (25).

K. kingae has been infrequently reported as a cause of clinical infections. We recorded 51 previously published cases including meningitis (31), phlegmon (5), presternal abscess (28), septicemia or bacteremia (2, 5, 10, 19), endocarditis (1, 2, 4, 5, 12, 13, 17-22, 26, 27), and bone and

* Corresponding author.

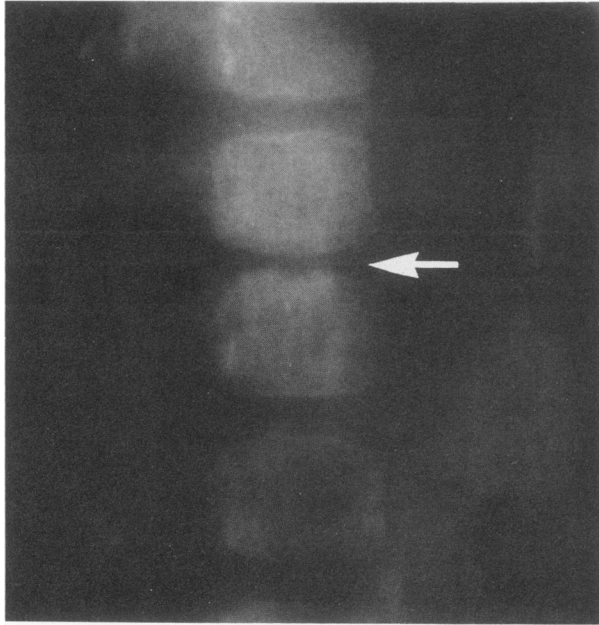


FIG. 1. Tomogram of narrowing of the lumbar spine L1-L2 disk space (indicated by the arrow).

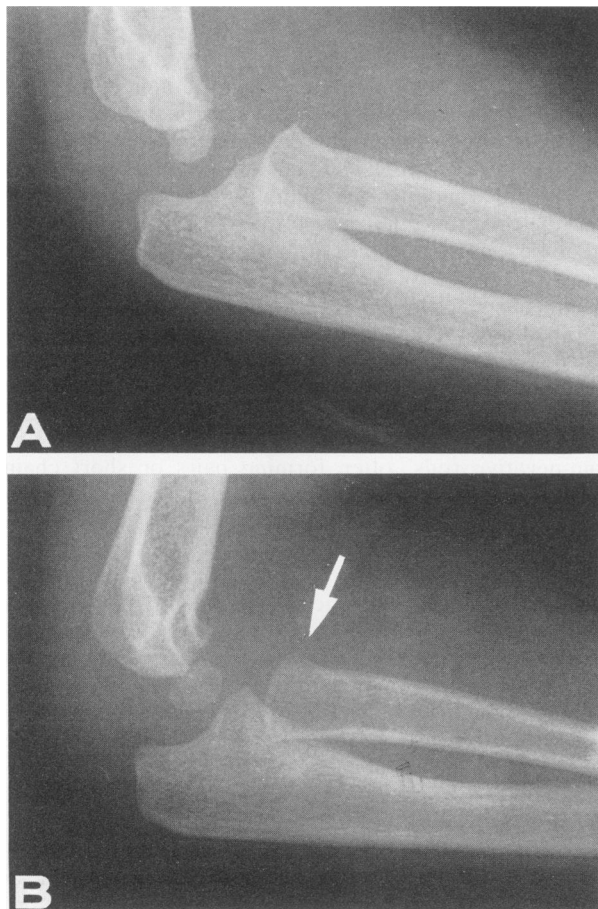


FIG. 2. X rays of the left elbow. (A) Normal bone; swelling of soft tissue. (B) Osteolytic lesion (indicated by the arrow).

joint infections (2, 5-9, 11, 23, 24, 28-30, 33). Most of the patients were previously healthy children.

The osteoarticular infections represent 51% of the cases and all except two occurred in children; septic arthritis, 14 cases; spondylitis, 7 cases; and osteomyelitis, 5 cases (Table 1). Of 75 isolates referred by the Centers for Disease Control (32), only 21 (28%) were from bones and joints. However it must be noted that 14 of the isolates were from cultures of the throat and one could wonder whether these strains were really involved in significant infections.

As in most previously reported cases, the source of the organism remains uncertain in our patients. In case 2, the existence of recurrent tonsillitis could have provided the origin of infection, resulting in bacteremia and hematogenous dissemination to bone. However, the pathogenesis and, specifically, the particular predilection of *K. kingae* for bones and joints are not understood. Whether this predilection is a real tropism for the skeleton or a function of overreporting of these infections in contrast to other ones is not known.

The clinical course of *K. kingae* osteoarticular infections has been reported as more insidious than that of infections caused by other organisms. This feature was not found in our two cases.

The growth characteristics of this fastidious organism could explain the apparent rarity of documented cases, and one can speculate that *K. kingae* might be involved in a number of culture-negative osteoarticular infections. It must also be emphasized that this organism is not suspected or

TABLE 1. Infections in bones and joints caused by *Kingella kingae* reported in the literature

Reference no.	Sex	Age	Infection (site)	Underlying disease
9	Female	22 mo	Spondylitis (L4-L5) ^a	None
33	Male	22 mo	Spondylitis (T11-T12)	None
29	Male	4 yr	Septic arthritis (knee)	Acute lymphocytic Leukemia
30	Male	49 yr	Septic arthritis (knee)	Alcohol abuse
7	Male	6 mo	Osteomyelitis (sternum)	None
7	Male	2 yr	Osteomyelitis (femur)	None
7	Male	13 yr	Septic arthritis (hip)	None
24	Female	2 yr	Septic arthritis (knee)	None
24	Male	14 mo	Septic arthritis (knee)	None
11	Female	10 mo	Septic arthritis (wrist)	None
2	Male	21 mo	Osteomyelitis (femur)	None
2	Male	10 mo	Septic arthritis (hip)	None
23	Female	18 mo	Septic arthritis (knee)	None
5	Male	18 mo	Osteomyelitis (femur)	None
5	Female	2 yr	Osteomyelitis (calcaneum)	None
5	Female	2 yr	Spondylitis (L4-L5)	None
5	Male	30 mo	Septic arthritis (knee)	None
5	Female	4 yr	Spondylitis (L2-L3)	None
5	Male	4 yr	Septic arthritis (hip)	None
5	Female	19 yr	Septic arthritis (sternoclavicular joint)	None
8	Female	5 yr	Spondylitis (L4-L5)	None
6	Female	2 yr	Septic arthritis (knee)	None
6	Female	5 yr	Septic arthritis (sternoclavicular joint)	None
6	Male	22 mo	Septic arthritis (ankle)	None
6	Male	18 mo	Spondylitis (L5-S1) ^a	None
28	Male	1 yr	Spondylitis (L5-S1)	None

^a L4-L5, Intervertebral disk between lumbar vertebrae 4 and 5; L5-S1, intervertebral disk between lumbar vertebra 5 and sacral vertebra 1.

looked for in many childhood infections, and it would be important for physicians and microbiologists to be aware of the association of *K. kingae* with skeletal infections, particularly in children. The prognosis of osteoarticular localization remains good because of the susceptibility of the organism to most antibiotics.

We thank H. H. Mollaret, Institut Pasteur Paris, for confirming identifications.

LITERATURE CITED

- Adachi, R., O. Hammerberg, and H. Richardson. 1983. Infective endocarditis caused by *Kingella kingae*. *Can. Med. Assoc. J.* **128**:1087-1088.
- Bosworth, D. E. 1983. *Kingella* (*Moraxella*) *kingae* infections in children. *Am. J. Dis. Child.* **137**:650-653.
- Bøvre, K., S. D. Henriksen, and V. Jonsson. 1974. Correction of the specific epithet *kingii* in the combinations *Moraxella kingii* Henriksen and Bøvre 1968 and *Pseudomonas kingii* Jonsson 1970 to *kingae*. *Int. J. Syst. Bacteriol.* **24**:307.
- Christensen, C. E., and G. C. Emmanouilades. 1967. Bacterial endocarditis due to "Moraxella new species 1." *N. Engl. J. Med.* **277**:803-804.
- Claesson, B., E. Falsen, and B. Kjellman. 1985. *Kingella kingae* infections: a review and a presentation of data from 10 Swedish cases. *Scand. J. Infect. Dis.* **17**:233-243.
- Clement, J. L., M. Salesse-Lavergne, M. F. Prère, M. Chaffai, J. Boulot, P. Lebarbier, J. P. Cahusac, and J. Gaubert. 1986. Osteoarthritis à *Kingella kingae*: A propos de quatre cas. *Chir. Pediatr.* **17**:359-362.
- Davis, J. M., and M. M. Pell. 1982. Osteomyelitis and septic arthritis caused by *Kingella kingae*. *J. Clin. Pathol.* **35**:219-222.
- Donnio, P. Y., J. Minet, M. N. Guerin, E. Le Gall, and M. Cormier. 1985. Spondylodiscite à *Kingella kingae* chez un enfant. *Med. Mal. Infect.* **12**:741-744.
- Falsen, E., J. E. Brorson, and E. A. Enger. 1977. *Moraxella kingii*: a rare cause of osteomyelitis. *Z. Kinderchir.* **22**:186-189.
- Forstl, H., G. Ruckdeschel, M. Lang, and W. Eder. 1984. Septicemia caused by *Kingella kingae*. *Eur. J. Clin. Microbiol.* **3**:267-269.
- Gay, R. M., T. W. Lane, and D. C. Keller. 1983. Septic arthritis caused by *Kingella kingae*. *J. Clin. Microbiol.* **17**:168-169.
- Geraci, J. E., and W. R. Wilson. 1982. Symposium on infective endocarditis. III. Endocarditis due to gram-negative bacteria: report of 56 cases. *Mayo Clin. Proc.* **57**:145-148.
- Grant, J. M., R. A. Bortolussi, D. L. Roy, and J. Wort. 1983. Prosthetic valve bacterial endocarditis caused by *Kingella kingae*. *Can. Med. Assoc. J.* **129**:406-410.
- Henriksen, S. D. 1969. Corroding bacteria from the respiratory tract. 1. *Moraxella kingae*. *Acta Pathol. Microbiol. Scand.* **75**:85-90.
- Henriksen, S. D., and K. Bøvre. 1968. *Moraxella kingii* sp. nov., a haemolytic, saccharolytic species of the genus *Moraxella*. *J. Gen. Microbiol.* **51**:377-385.
- Henriksen, S. D., and K. Bøvre. 1976. Transfer of *Moraxella kingae* Henriksen and Bøvre to the genus *Kingella* gen. nov. in the family *Neisseriaceae*. *Int. J. Syst. Bacteriol.* **26**:447-450.
- Huhn, P. 1973. *Moraxella* endocarditis in a patient with systemic lupus erythematosus. *W. Va. Med. J.* **69**:35-36.
- La Selve, H., A. Bozio, P. Vidil, S. Gallet, G. Barge, and M. David. 1985. Endocardite aiguë à *Kingella kingae* chez un nourrisson. *Arch. Fr. Pediatr.* **42**:35-36.
- Le, C. T. 1983. *Kingella* (*Moraxella*) *kingae* infections. *Am. J. Dis. Child.* **137**:1212.
- Lion, C., R. Chatelain, J. L. Neimann, F. Mory, and J. C. Burdin. 1982. Endocardite à *Kingella kingae*. *Med. Mal. Infect.* **12**:280-284.
- Miridjanian, A., and D. Berrett. 1978. Infective endocarditis caused by *Moraxella kingae*. *West. J. Med.* **129**:344-346.
- Ødum, L., K. T. Jensen, and T. D. Slotsbjerg. 1984. Endocarditis due to *Kingella kingae*. *Eur. J. Clin. Microbiol.* **3**:263-266.
- Patel, N. J., T. L. Moore, T. D. Weiss, and J. Zuckner. 1983. *Kingella kingae* infectious arthritis: case report and review of literature of *Kingella* and *Moraxella* infections. *Arthritis Rheum.* **26**:557-559.
- Powell, J. M., and J. W. Bass. 1983. Septic arthritis caused by *Kingella kingae*. *Am. J. Dis. Child.* **137**:974-976.
- Prère, M. F., M. Seguy, Y. Vezard, and M. B. Lareng. 1986. Sensibilité aux antibiotiques de *Kingella kingae*. *Pathol. Biol.* **34**:604-607.
- Rabin, R. L., P. Wong, J. A. Noonan, and D. D. Plumley. 1983. *Kingella kingae* endocarditis in a child with prosthetic aortic valve and bifurcation graft. *Am. J. Dis. Child.* **137**:403-404.
- Ravdin, J. I., R. D. Brandstetter, M. J. Wade, and R. B. Roberts. 1982. Endocarditis resulting from *Kingella kingae*, presenting initially as culture negative endocarditis. *Heart Lung* **11**:552-554.
- Raymond, J., M. Bergeret, F. Bargy, and G. Missenard. 1986. Isolation of two strains of *Kingella kingae* associated with septic arthritis. *J. Clin. Microbiol.* **24**:1100-1101.
- Redfield, D. C., G. D. Overturf, N. Ewing, and D. Powars. 1980. Bacteremia, arthritis and skin lesions due to *Kingella kingae*. *Arch. Dis. Child.* **55**:411-414.
- Vincent, J., C. Podewell, G. W. Franklin, and J. H. Korn. 1981. Septic arthritis due to *Kingella* (*Moraxella*) *kingii*: case report and review of the literature. *J. Rheumatol.* **8**:501-503.
- Walterspiel, J. N. 1983. *Kingella kingae* meningitis with bilateral infarcts of the basal ganglia. *Infection* **6**:307-309.
- Weaver, R. E., D. G. Hollis, and E. J. Bottone. 1985. Gram-negative fermentative bacteria and *Francisella tularensis*, p. 309-329. *In* E. H. Lennette, A. Balows, W. J. Hausler, Jr., and H. J. Shadomy (ed.), *Manual of Clinical Microbiology*, 4th ed. American Society for Microbiology, Washington, D.C.
- Wong, A. S., J. Dyke, D. Perry, and D. C. Anderson. 1978. Paraspinal mass associated with intervertebral disk infection secondary to *Moraxella kingii*. *J. Pediatr.* **92**:86-88.