

Recognition of Whole *Cryptosporidium* Oocysts in Feces by Negative Staining and Electron Microscopy

DERRICK BAXBY,* B. GETTY, N. BLUNDELL, AND SUSAN RATCLIFFE

Department of Medical Microbiology, Liverpool University, Liverpool L69 3BX, United Kingdom

Received 26 September 1983/Accepted 14 December 1983

Cryptosporidium oocysts in feces were recognizable in the electron microscope when prepared by the negative staining technique used by virologists. Their size, shape, and surface markings were sufficiently characteristic for cryptosporidiosis to be diagnosed by this method if more suitable methods are not available.

Increasing interest is being shown in the protozoan *Cryptosporidium* sp. as a cause of human gastroenteritis, particularly now that simple methods are available to detect oocysts in feces (3, 4). The preferred methods involve staining of fecal smears by the Ziehl-Neelson method or examination of wet preparations after sugar flotation or both.

Cryptosporidiosis has been studied by thin-section transmission electron microscopy and scanning electron microscopy (1a, 2, 5, 6), but we know of no published electron micrographs of whole *Cryptosporidium* oocysts prepared by the negative staining technique used by virologists. Many virology laboratories routinely screen feces from patients with gastroenteritis for enteropathogenic viruses and will inevitably examine material from cases of cryptosporidiosis. We publish here electron micrographs of whole cryptosporidia in feces which should serve as a guide and permit recognition of cases which might otherwise be missed.

Samples of feces in which cryptosporidia could be seen in smears stained by the Ziehl-Neelson technique were prepared for electron microscopy by glutaraldehyde fixation (0.5% for 1 min) and stained with phosphotungstic acid (0.5 to 2.0%, pH 7) or uranyl acetate (0.5 to 2%, pH 7). The structures seen were considered to be *Cryptosporidium* oocysts because they were present in samples of human (Fig. 1A) and lamb (Fig. 1B) feces shown by other methods to contain cryptosporidia; because no other bodies of similar size and shape were detected; and because thin sections of pelleted and embedded material showed structures similar to those seen in published electron micrographs (Fig. 1C) (2, 6).

Cryptosporidia were only lightly stained by the methods used, and no internal structure was discernable. The surface had characteristic folds or creases which made recognition easy. The best results were obtained with 0.5% phosphotungstic acid. Such folds may be fixation artifacts, but similar effects have been seen in thin sections (unpublished data; 6).

We believe the appearance in the electron microscope of whole cryptosporidia from feces is sufficiently characteristic for them to be recognized without difficulty. They are much smaller (5 μm) than the cysts of other protozoa. Yeasts are often present in feces but are smaller, less obviously spherical, and, in our experience, take up stain, particularly uranyl acetate, so much that they appear almost totally electron dense (Fig. 1D).

Published methods for diagnosis of cryptosporidiosis, although very successful, are labor intensive and may not be available in all laboratories. However, many laboratories

routinely examine feces for enteropathogenic viruses by electron microscopy, and the occasional recognition of cryptosporidia by this method would detect cases which would otherwise be missed. Little information is available about the numbers of cryptosporidia in human feces, but we have detected numbers in excess of $5 \times 10^7/\text{g}$ (1). Such numbers are detectable by electron microscopy without much difficulty, and with smaller numbers an occasional oocyst will be seen. We hope the micrographs published here will encourage electron microscopists to look for cryptosporidia, particularly if they work in laboratories which are not using other methods.

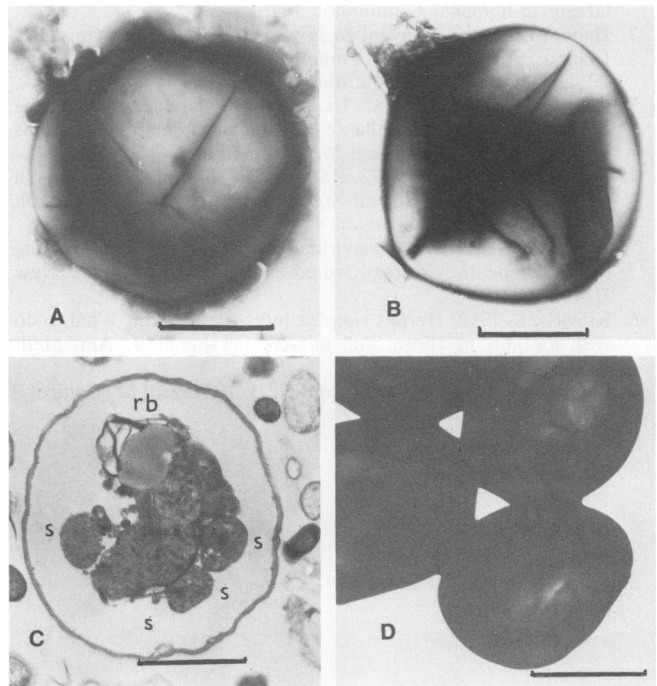


FIG. 1. *Cryptosporidium* oocysts in feces. (A) Human feces, 0.5% phosphotungstic acid. Bar, 2 μm . (B) As in (A) but from lamb feces. Bar, 2 μm . (C) Lamb feces; thin section of oocyst showing four sporozoites (S); three cut transversely, one cut longitudinally and residual body (rb). Uranyl acetate plus lead citrate. Bar, 2 μm . (D) Yeasts in human feces, 0.5% phosphotungstic acid. Bar, 2 μm . (Note: (D) was slightly underexposed in an attempt to reveal surface detail. In reality the yeast cells were much darker.)

* Corresponding author.

LITERATURE CITED

1. **Baxby, D., C. A. Hart, and C. Taylor.** 1983. Human cryptosporidiosis: a possible case of hospital cross-infection. *Br. Med. J.* **287**:1760-1761.
- 1a. **Bird, R. G., and M. D. Smith.** 1980. Cryptosporidiosis in man: parasite life cycle and fine structural pathology. *J. Pathol.* **132**:217-233.
2. **Current, W. L., N. C. Reese, J. V. Ernst, W. S. Bailey, M. B. Heyman, and W. M. Weinstein.** 1983. Human cryptosporidiosis in immunocompetent and immunodeficient persons. *N. Engl. J. Med.* **308**:1252-1257.
3. **Garcia, L. S., D. A. Bruckner, T. C. Brewer, and R. Y. Shimizu.** 1983. Techniques for the recovery and identification of *Cryptosporidium* oocysts from stool specimens. *J. Clin. Microbiol.* **18**:185-190.
4. **Ma, P., and R. Soave.** 1983. Three-step stool examination for cryptosporidiosis in 10 homosexual men with protracted watery diarrhea. *J. Infect. Dis.* **147**:824-828.
5. **Pearson, G. R., and E. F. Logan.** 1983. Scanning and transmission electron microscopic observations on the host-parasite relationship in intestinal cryptosporidiosis of neonatal calves. *Res. Vet. Sci.* **34**:149-154.
6. **Pohlentz, J., H. W. Moon, N. F. Cheville, and W. J. Bemrick.** 1978. Cryptosporidiosis as a probable factor in neonatal diarrhea of calves. *J. Am. Vet. Med. Assoc.* **172**:452-457.

ADDENDUM IN PROOF

Since this paper was submitted for publication, a rapid, simple alternative to the Ziehl-Neelson stain has been described for the detection of cryptosporidial oocysts in feces (D. Baxby and N. Blundell, *Lancet* ii:1149, 1983).