

## Local and Systemic Immune Responses in Murine *Helicobacter felis* Active Chronic Gastritis

J. G. FOX,<sup>1\*</sup> M. BLANCO,<sup>1</sup> J. C. MURPHY,<sup>1</sup> N. S. TAYLOR,<sup>1</sup> A. LEE,<sup>2</sup> Z. KABOK,<sup>3</sup> AND J. PAPPO<sup>3</sup>

Division of Comparative Medicine, Massachusetts Institute of Technology,<sup>1</sup> and Vaccine Delivery Research, OraVax Inc.,<sup>3</sup> Cambridge, Massachusetts 02139, and School of Microbiology New South Wales, Sydney, Australia<sup>2</sup>

Received 11 January 1993/Accepted 29 March 1993

*Helicobacter felis* inoculated per os into germfree mice and their conventional non-germfree counterparts caused a persistent chronic gastritis of ~1 year in duration. Mononuclear leukocytes were the predominant inflammatory cell throughout the study, although polymorphonuclear cell infiltrates were detected as well. Immunohistochemical analyses of gastric mucosa from *H. felis*-infected mice revealed the presence of mucosal B220<sup>+</sup> cells coalescing into lymphoid follicles surrounded by aggregates of Thy-1.2<sup>+</sup> T cells; CD4<sup>+</sup>, CD5<sup>+</sup>, and  $\alpha\beta$  T cells predominated in organized gastric mucosal and submucosal lymphoid tissue, and CD11b<sup>+</sup> cells occurred frequently in the mucosa. Follicular B cells comprised immunoglobulin M<sup>+</sup> (IgM<sup>+</sup>) and IgA<sup>+</sup> cells. Numerous IgA-producing B cells were present in the gastric glands, the lamina propria, and gastric epithelium. Infected animals developed anti-*H. felis* serum IgM antibody responses up to 8 weeks postinfection and significant levels of IgG anti-*H. felis* antibody in serum, which remained elevated throughout the 50-week course of the study.

An infectious etiology in gastric disease received little attention until Marshall and Warren first described *Campylobacter* (now named *Helicobacter*) *pylori* and its association with gastritis in humans (25). This organism has also recently been directly linked to the development of peptic ulcer disease and gastric cancer (4, 17, 24, 27, 29).

Because there is increasing evidence that *H. pylori* is a significant gastroduodenal pathogen, several experimental animals have been used to model the pathophysiology of the *H. pylori*-associated disease in humans. Candidate animal models susceptible to *H. pylori* experimental infection include gnotobiotic and barrier-maintained piglets, gnotobiotic dogs, and nonhuman primates (1, 19, 31). Each of these species has limited utility because of cost, availability, and special housing constraints. The domestic ferret, which is colonized naturally with *Helicobacter mustelae*, also develops a significant *Helicobacter*-associated gastritis (11).

In 1988, Lee and coworkers isolated a new spiral organism from the gastric tissue of the cat (21). On the basis of its anatomic location, morphological and biochemical characteristics, and RNA sequencing data, we have named this organism *Helicobacter felis* (30). This *Helicobacter* species has a much wider host range than *H. pylori* and naturally colonizes cats and dogs (21, 30). After experimental oral inoculation, *H. felis* efficiently colonizes mice, rats, dogs, and, to a lesser extent, ferrets (12, 13, 20, 22). However, observations of experimental infections in germfree (GF) mice and rats have been limited to 8 weeks postinoculation (12, 20). In this report, we describe the development of chronic persistent gastritis in both GF and conventional mice after oral infection with *H. felis*. We also demonstrate the compartmentalization of lymphocyte subpopulations in gastric tissue and the presence of serum immunoglobulin M (IgM) and IgG anti-*H. felis* antibody responses up to 50 weeks postinfection.

### MATERIALS AND METHODS

**Animals.** Thirty-four 4-week-old female Swiss Webster [Tac; (SW) gf] isolator-reared, axenic mice were obtained from Taconic Farms. Nineteen GF mice were maintained in a GF isolator, and the remaining 15 mice were maintained in barrier (but not sterile) conditions as viral-antibody-free mice (VAF) for the duration of the experiment (50 weeks). All materials for the GF unit were sterilized by peracetic acid, and the GF animals were fed an autoclaved pelleted diet and given sterile water ad libitum. The protocol described below was approved by the Animal Care Committee of the Massachusetts Institute of Technology.

**Bacteria.** *H. felis* (ATCC 49179) was used for oral inoculation. The organism was grown for 48 h at 37°C under microaerobic conditions on 5% lysed horse blood agar supplemented with the following antibiotics: vancomycin, 10 µg/ml (Sigma Chemical Co., St. Louis, Mo.); trimethoprim lactate, 5 µg/ml (Sigma); polymyxin B, 3 µg/ml (Sigma); and amphotericin B, 2.5 µg/ml (Fungizone; Squibb) (20). The bacteria were harvested and inoculated (approximately 10<sup>10</sup> organisms per ml) into brain heart infusion agar with 30% glycerol added. The bacterial suspension was frozen at -70°C. Prior to use, aliquots were thawed, analyzed for motility, and cultured for evidence of aerobic or anaerobic bacterial contamination.

**Experimental infection.** Of the 19 GF mice, 14 were inoculated with *H. felis* and 5 served as controls. In the remaining 15 VAF mice, 10 were inoculated with *H. felis* and 5 were controls. The outside surfaces of sealed culture vials of brain heart infusion broth containing ~10<sup>10</sup> CFU of *H. felis* per ml were sprayed with peracetic acid prior to transfer of the vials into the gnotobiotic unit. The inoculum (0.5 ml) was delivered per os into each test mouse three times at 2-day intervals by using a sterile oral catheter. At 10, 20, 30, 40, and 50 weeks postinfection, two or three experimentally infected mice and one control mouse from both the GF and VAF groups were euthanized and necropsied.

**Bacterial isolation and urease tests.** At scheduled intervals (see above), mice were removed from the isolator or barrier

\* Corresponding author.

TABLE 1. Panel of MAbs

Antigen structure	Clone	Designation	Cell specificity
Thy-1	30-H12		T
CD4	GK1.5	L3T4	T helper
CD5	53-7.3	Ly1	T, B (subpopulation)
CD8	53-6.7	Ly2	T suppressor
TCR $\alpha\beta$	H57-595		T
TCR $\gamma\delta$	GL3		T
B220	RA3-3A1/6.1		B
IgA	10-4.22		B
IgM	331.12		B
CD11b	M1/70.15	Ly43 (Mac-1)	Macrophages

and anesthetized with carbon dioxide for blood collection. The mice were then euthanized with an overdose of carbon dioxide. Two-millimeter cubes of gastric mucosa from the antrum and duodenum were collected aseptically for culture or for the urease test (18). Samples of stomach and duodenum, as well as caging material, were routinely incubated on sheep blood agar plates and incubated aerobically and anaerobically for 3 days at 37°C to assay for possible bacterial contamination of the GF mice and/or isolator.

**Histopathologic evaluation.** The tissue examined consisted of a single section of gastric mucosa taken from the greater curvature of the stomach beginning at the esophageal-gastric junction and ending at the gastroduodenal junction. Stomach tissues were fixed in neutral buffered 10% formalin and processed by standard methods, embedded in paraffin, sectioned at 5  $\mu$ m, and stained with hematoxylin and eosin (H&E) and Warthin-Starry stain. The glandular mucosa of the body, pyloric antrum, pyloric canal, and pylorus were examined for histological changes and the presence of *H. felis*.

**MAbs.** The following monoclonal antibodies (MAbs) recognizing lymphocyte cell surface molecules were used in this study (Table 1): anti-Thy-1.2 (clone 30-H12), anti-CD4 (clone GK1.5), anti-CD8 (clone 53-6.7) (Becton Dickinson, San Jose, Calif.), anti-CD5 (clone 53-7.3), anti- $\alpha\beta$  T-cell receptor (TCR [clone H57-595]), and anti- $\gamma\delta$  TCR (clone GL3) (Pharmingen, San Diego, Calif.). The MAbs anti-B220 (clone RA3-3A1/6.1), anti-IgM (clone 331.12), and anti-CD11b (clone M1/70.15) were obtained from the American Type Culture Collection (Rockville, Md.). The MAb 10-4.22, directed against mouse IgA (32), was a kind gift of T. Ermak, University of California, San Francisco).

**Immunohistochemistry.** Samples of stomach tissue (cardiac, fundic, and pyloric regions) were obtained from groups of two infected mice and one control from 20 to 50 weeks postinoculation. The tissues were mounted in O.C.T. compound (Miles Scientific, Naperville, Ill.) and frozen in liquid nitrogen-cooled Freon 22 as previously described (28). Tissue sections (7  $\mu$ m) were fixed with acetone, and biotin-avidin binding sites were blocked for 30 min (Vector Laboratories, Burlingame, Calif.). Tissue sections were incubated with 10  $\mu$ g of biotinylated MAb per ml in phosphate-buffered saline (PBS; 0.01 M phosphate, pH 7.4) and then were incubated with avidin conjugated to biotinylated horseradish peroxidase (ABC; Vector Laboratories). Controls included incubation with a MAb of unrelated specificity. Reagents were applied to tissue sections for 30 min, and the sections were washed three times with PBS. Cell-bound peroxidase was detected with 0.05% diaminobenzidine tetrahydrochloro-

TABLE 2. Colonization of stomachs of GF and VAF mice by *H. felis*<sup>a</sup>

Mice	Colonization <sup>b</sup> at postinfection wk:				
	10	20	30	40	50
GF	+2/2	+3/3	+3/3	+3/3 <sup>c</sup>	+3/3 <sup>d</sup>
VAF	+2/2	+3/3	+3/3	+3/3	+3/3

<sup>a</sup> GF mice were assayed by culture, biopsy positive for urease, and with Warthin-Starry-stained histological sections of stomach, except as noted below. VAF mice were assayed for *H. felis* by urease and histological criteria only. Control mice (one at each time point) were negative for *H. felis* by the same criteria. Duodenum samples from all animals at all time points were negative for *H. felis*.

<sup>b</sup> Number of animals positive for *H. felis*/number of animals inoculated.

<sup>c</sup> Culture was contaminated—no *H. felis* grew.

<sup>d</sup> One culture was positive, but two had no growth.

ride (Organon Teknika, Durham, N.C.) and 0.01% H<sub>2</sub>O<sub>2</sub> in PBS, and sections were counterstained with methyl green.

**ELISA for anti-*H. felis* antibody.** (i) **Antigen preparation.** *H. felis* sonicate for use in the enzyme-linked immunosorbent assay (ELISA) was as described elsewhere (11). In brief, *H. felis* was grown for 48 h in brucella broth (Difco Laboratories, Detroit, Mich.) containing 5% fetal calf serum. Cultures were incubated at 37°C in a microaerobic environment and were shaken at 120 rpm. The cultures were centrifuged at 10,000 rpm (Sorvall RC-5B; Dupont, Newtown, Conn.) for 10 min, and the pellet was washed three times in PBS. The pellet was diluted in PBS to an optical density (660 nm) of ~1.0, and the cells were disrupted by sonication (Artec K System, Inc., Farmingdale, N.Y.). After centrifugation at 10,000 rpm for 10 min, the protein content was determined and the aliquots were frozen at -70°C until used (23).

(ii) **Assay.** The ELISA was carried out as previously described, with the following modifications (12). Wells of microtiter plates (Dynatech Laboratories) were incubated with 100  $\mu$ g of *H. felis* protein per ml in carbonate buffer. After being washed, serial twofold dilutions of sera from *H. felis*-infected or control mice were incubated for 60 min at 37°C and then were given the appropriate dilution of alkaline phosphatase-conjugated goat anti-mouse IgG or IgM (Sigma). Serum samples were obtained from the 34 mice included in this study, from 20 GF mice infected with *H. felis*, and from 6 control mice monitored for 8 weeks whose histopathology was previously described (20). The antibody titer of serum samples was that dilution giving 3 standard deviations above the mean optical density of four negative control serum samples.

## RESULTS

**Colonization of gastric tissue with *H. felis*.** The gastric urease and bacterial culture results for experimental and control GF and VAF mice are shown in Table 2. Antral gastric tissues from both GF and VAF experimentally infected mice were all positive, whereas duodenal biopsies were all negative in the urease assay. In the GF mice, the antrum biopsy was positive for urease within 8 h in 13 of 15 mice and the biopsy was positive for urease in the remaining 2 mice within 12 to 18 h. For the VAF mice, 8 of 10 were positive within 6 h; the other 2 were positive within 12 to 16 h. *H. felis* was cultured from the antra of 9 of 14 infected GF mice but was not cultured from any of the 5 control mice. Contamination occurred, most likely during collection of tissues at necropsy, in the three biopsies taken at 40 weeks

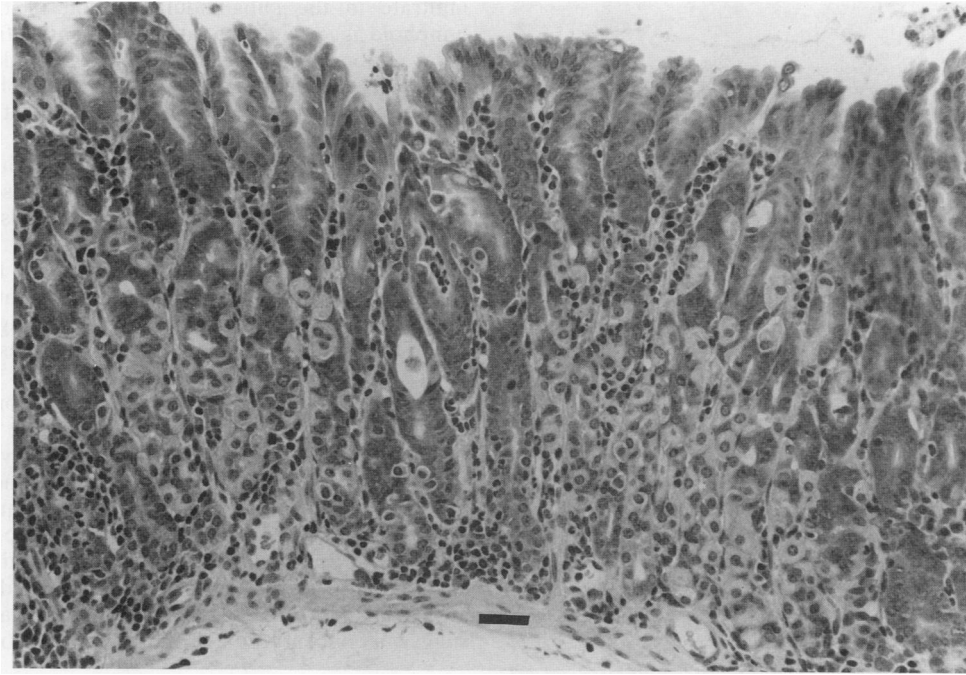


FIG. 1. Antral mucosa from a GF mouse 20 weeks postinfection with *H. felis*. Figure shows a leukocytic infiltrate in the lamina propria composed of lymphocytes and PMN leukocytes, a microabscess, and aggregates of lymphocytes and plasma cells at the level of the gastric pits. H&E stain; bar, 35  $\mu$ m.

postinfection. *H. felis* did not grow in another two biopsies sampled at 50 weeks postinfection. However, the spiral organism was present in all infected mice (both GF and VAF), as evidenced by gastric tissue stains and urease

assays. Colony counts of *H. felis* from biopsy samples were not possible because *H. felis* forms spreading colonies, thus making quantification difficult. Aerobic and anaerobic cultures of fecal samples from animals and material in the

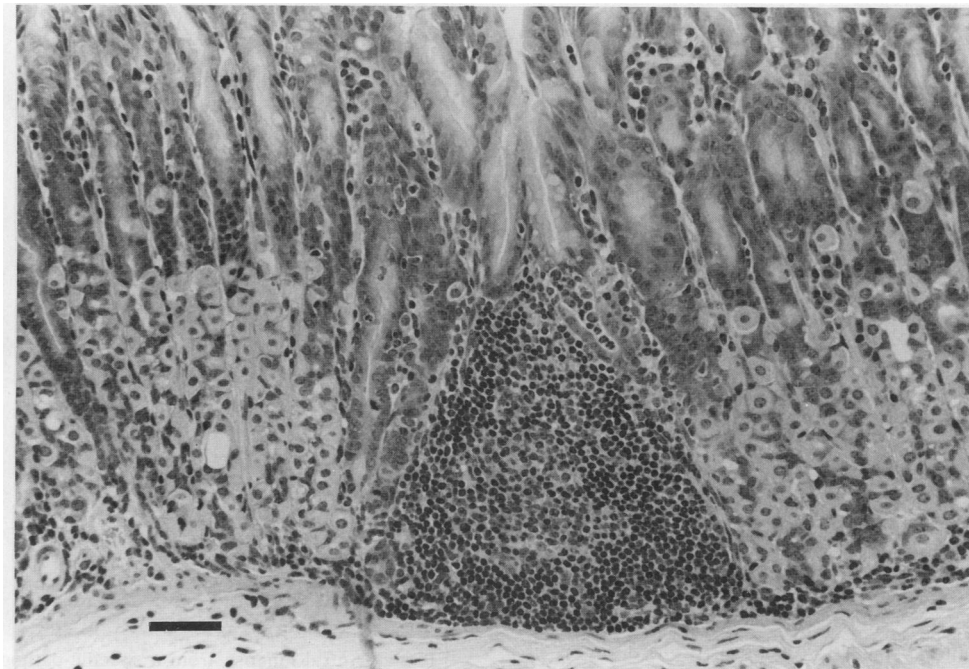


FIG. 2. Body mucosa from VAF mouse 20 weeks postinfection with *H. felis*. A lymphoid nodule is displacing glands, and a mild diffuse subglandular leukocytic infiltrate is noted. Small aggregates of lymphocytes and plasma cells in the lamina propria at the level of the gastric pits are also present. H&E stain; bar, 40  $\mu$ m.

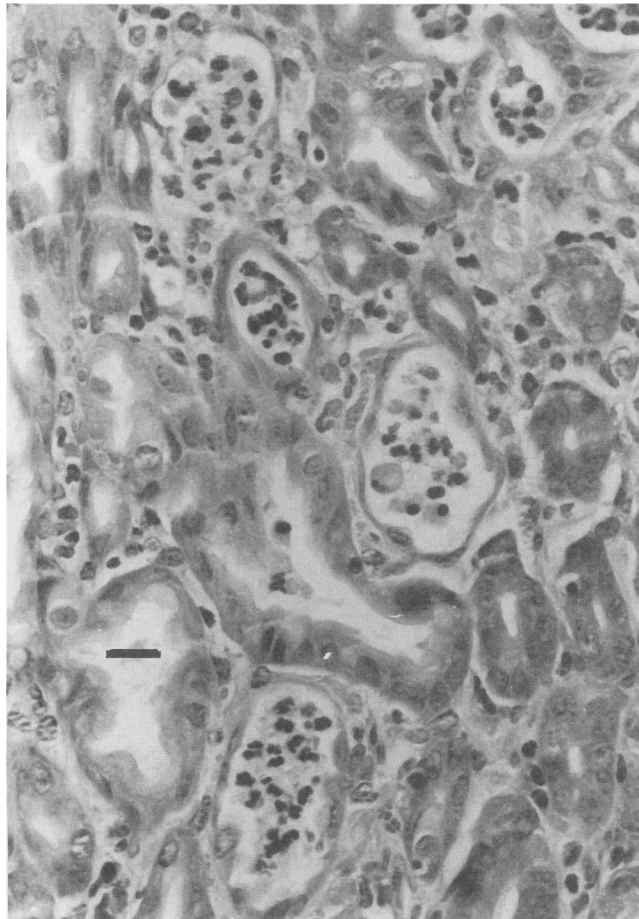


FIG. 3. Body mucosa from a GF mouse inoculated 10 weeks previously with *H. felis*. Multiple microabscesses and leukocytic infiltration of the lamina propria are depicted. H&E stain; bar, 25  $\mu$ m.

isolator were negative throughout the 50-week experiment. All control animals were negative for urease and showed an absence of *H. felis* by histological exam with Warthin-Starry stain in gastric biopsies throughout the study.

**Histopathology.** Histologic changes were restricted to the glandular portions of the stomach, which are designated the mucosa of the body and pyloric regions of the stomach. There was no significant variation between the histologic changes observed in the GF group compared with those in the VAF group. The overall evaluation of the inflammatory changes observed in the glandular mucosa of the two groups of mice was classified as mild and multifocal, with a cellular infiltrate characterized as active chronic inflammation at the 10-week interval, with transition to chronic inflammation from the 20-week interval through 50 weeks. Active chronic inflammation is defined as an inflammatory response consisting of polymorphonuclear (PMN) cells with a component of mononuclear cell infiltrates in the affected tissue. Chronic inflammation refers to a mononuclear infiltrate without significant numbers of PMN cells.

The histologic changes were consistently more severe in the body mucosa, with a gradual reduction in severity through the pyloric antrum to the pyloric sphincter. The changes included (i) a relatively diffuse mixed leukocytic

infiltrate in the subglandular region of the mucosa; (ii) lymphoid aggregates that appeared to arise from the subglandular region of the mucosa and, as they enlarged, displaced glandular elements; (iii) submucosal lymphoid aggregates; (iv) leukocytic infiltrates extending from the subglandular region through the lamina propria toward the luminal surface; (v) lymphoplasmacytic aggregates in the lamina propria at the level of the gastric pits; (vi) microabscesses; and (vii) cystic glands containing necrotic cell debris (Fig. 1 through 3). The numbers of PMN cells in these various cellular infiltrates were greatest at 10 weeks, but there were only small numbers of PMN cells at subsequent time intervals. The predominant inflammatory cell throughout the entire study was the lymphocyte. Microabscesses were observed in one or two mice from each group both within the body mucosa and within the mucosa of the pyloric region at the 10-week interval and were observed in one GF mouse at 40 weeks and in one GF mouse at 50 weeks. Cystic glands were observed in both groups, usually in only one mouse at each time interval, and the cysts were most frequent in the body mucosa. Organisms with the characteristic spiral morphology of *H. felis* were demonstrated in Warthin-Starry-stained sections of the gastric mucosa of all infected mice from both groups at all time intervals (Fig. 4). There was no evidence to suggest a concentration of organisms in association with foci

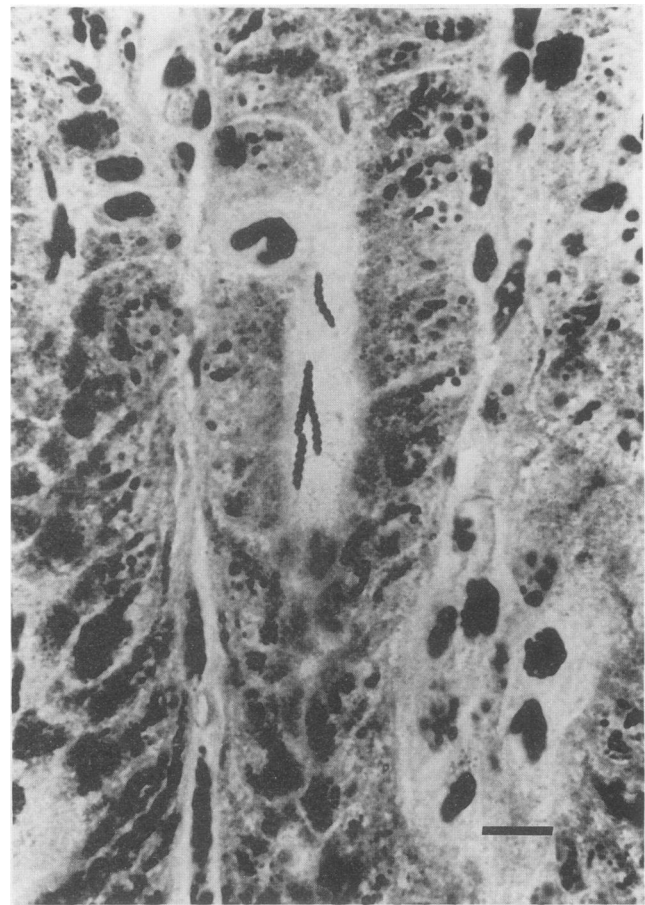


FIG. 4. Antral mucosa from a specific-pathogen-free mouse 30 weeks postinfection with *H. felis*. Spiral organisms characteristic of *H. felis* are noted within the lumen of a gland. Warthin-Starry stain; bar, 10  $\mu$ m.



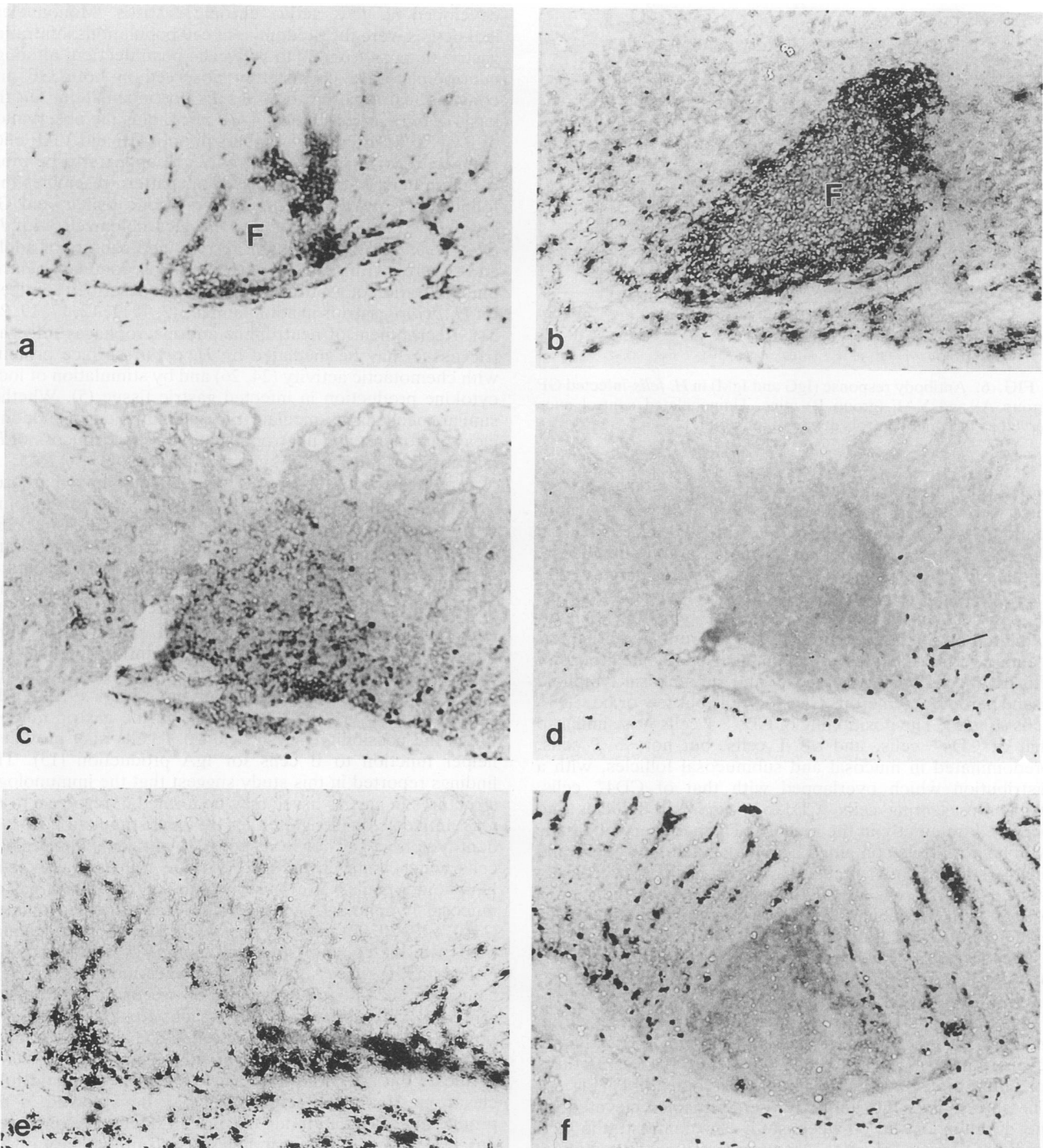


FIG. 5. Immunohistochemical mapping of cell populations in gastric tissue of *H. felis*-infected GF mice 20 weeks post-oral inoculation. Clusters of Thy-1.2<sup>+</sup> cells (a) surround mucosal lymphoid follicle (F) containing B220<sup>+</sup> cells (b). Most T cells populating follicles stain with anti-CD4 (c) but not with anti-CD8 (d). Mac-1<sup>+</sup> cells encircle follicles and occur frequently in the mucosa (e). Follicular B cells stain lightly for IgA (f), but groups of dark-staining IgA<sup>+</sup> B cells populate gastric glands, lamina propria, and epithelium. Scattered cells in the mucosa with endogenous peroxidase (arrow) are shown in panel d. Magnification,  $\times 400$ .

of inflammation. The numbers and distributions of organisms were similar in both GF and VAF mice at each time interval. The greatest concentration of organisms was found in the pyloric region, with organisms infrequently observed in the mucosa of the body, and the greatest number of organisms

was found at the 20-, 30-, and 40-week time intervals. No organisms were observed in the stomachs of GF or VAF control mice at any time interval.

**Immunohistochemical distribution of gastric mucosal lymphoid tissue.** The distribution and architectural arrangement

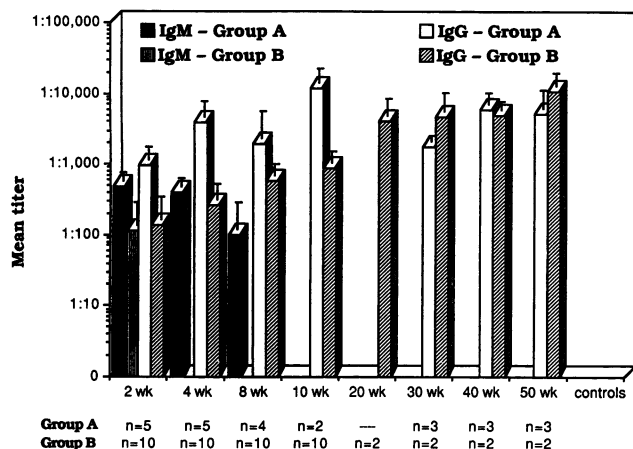


FIG. 6. Antibody response (IgG and IgM) in *H. felis*-infected GF (group A) and VAF (group B) mice. Uninoculated control mice served as baseline controls at each time point.

of cell populations infiltrating gastric tissue in GF and VAF mice were studied from 20 weeks through 50 weeks postinfection. Gastric tissue from *H. felis*-infected mice exhibited Thy-1.2<sup>+</sup> T cells scattered in the mucosa and submucosa, frequently organized as clusters surrounding large aggregates of B220<sup>+</sup> B cells assembled into lymphoid follicles (Fig. 5). In most instances, mucosal lymphoid follicles exhibited an intensely staining B220<sup>+</sup> corona and a lighter-staining germinal center containing single or small groups of Thy-1.2<sup>+</sup> cells. Gastric mucosal and submucosal lymphoid tissue harbored numerous CD4<sup>+</sup> T cells but few or no CD8<sup>+</sup> cells (Fig. 5). The positioning of CD5<sup>+</sup> T cells was similar to that of CD4<sup>+</sup> cells, and  $\alpha\beta$  T cells, but not  $\gamma\delta$  T cells, predominated in mucosal and submucosal follicles, with a distribution which overlapped with that of CD4<sup>+</sup> cells. Antigen-presenting cells (CD11b<sup>+</sup>) encircled follicles and occurred frequently in the mucosa. The periphery of gastric lymphoid follicles contained heavily labeled IgM<sup>+</sup> cells and lightly staining IgA<sup>+</sup> cells. However, groups of densely labeled IgA B cells populated gastric glands, the lamina propria, and epithelium. Gastric tissue from uninfected mice exhibited occasional mucosal Thy-1.2<sup>+</sup> and CD11b<sup>+</sup> cells.

**Kinetics of *H. felis*-specific serum IgM and IgG antibody production during infection.** In experimentally infected mice, anti-*H. felis* IgG antibody levels increased markedly at 2 to 4 weeks postinoculation. Whereas IgG antibody titers from infected GF mice peaked at 10 weeks and IgG antibody levels from VAF mice peaked at 20 weeks, the overall titers for both groups of infected mice were comparable (Fig. 6). The anti-*H. felis* IgG antibody titers remained elevated for the duration of the 50-week study. In contrast, the IgM antibody titers in GF mice were greatest 2 weeks postinfection, declined from 4 to 8 weeks postinfection, and were not measurable 10 weeks after *H. felis* infection. In the VAF mice, IgM was detected at 2 weeks postinfection only (Fig. 6). Anti-*H. felis* IgG or IgM antibody was not detectable in any of the contact control mice.

## DISCUSSION

In the present study, we demonstrated that both GF and VAF mice can be chronically infected with *H. felis*. We also examined the immunologic structures populating target gastric tissue and the serum antibody responses of mice which

developed *H. felis* active chronic gastritis. Mononuclear leukocytes were the predominant cell populations infiltrating gastric mucosa from 20 to 50 weeks postinfection, although neutrophils were consistently observed in both GF and conventional mice up to 50 weeks postinoculation. On the basis of our earlier studies in GF mice, plus the observation of PMN cells in greater numbers in both GF and VAF mice colonized for 10 weeks, the PMN cell appears to be more common in early-onset disease. This pattern resembles that found in *H. pylori* gastritis in gnotobiotic piglets and GF beagles, GF infected rats and beagles colonized with *H. felis*, *H. mustelae* gastritis in ferrets, and subsets of adults and children with gastritis. However, a predominant neutrophil infiltration of gastric tissue has been described routinely for *H. pylori* gastritis in adult humans (2, 7, 11, 12, 17, 19, 23, 31). Recruitment of neutrophils and macrophages into gastric tissue may be mediated by *H. pylori* surface proteins with chemotactic activity (24, 26) and by stimulation of local cytokine production in infected gastric tissue (5). Whether similar mechanisms mediate the accumulation of mononuclear leukocytes and neutrophils in the gastric mucosa of *H. felis*-infected mice is not known at present.

Target gastric tissue from *H. felis*-infected mice harbored compartmentalized lymphoid aggregates often resembling the cytoarchitecture of gut-associated lymphoid tissues (10). Mucosal B220<sup>+</sup> cells organized into lymphoid follicles and germinal centers, which were circumscribed by clusters of Thy-1.2<sup>+</sup> cells. Compared with small intestinal intraepithelial T cells, which are enriched in CD4<sup>-</sup> CD8<sup>+</sup>  $\gamma\delta$  T cells (16), gastric mucosal and submucosal T cells were predominantly CD4<sup>+</sup> CD5<sup>+</sup>  $\alpha\beta$  TCR<sup>+</sup>. While intraepithelial  $\gamma\delta$  T cells have recently been found in *H. pylori*-infected gastric tissue by some investigators, but not others (9, 33), the finding of CD4<sup>+</sup>  $\alpha\beta$  TCR<sup>+</sup> cells in murine gastric mucosa raises the possibility that gastric  $\alpha\beta$  T cells may provide a helper function to B cells for IgA production (15). The findings reported in this study suggest that the immunologic structures in gastric tissue may be formed in response to *H. felis* antigenic challenge, either by local stimulation of resident lymphoid cells or in response to antigen stimulation of cells which home in on gastric tissue from gut-associated lymphoid organs. The observations of organized gastric mucosal lymphoid tissue in *Helicobacter*-infected animals (11, 12, 19, 20, 22) raise the possibility that the stomach may be part of the common mucosal immune system (34).

The finding that *H. felis*-infected mice mounted a significant systemic antibody response 50 weeks in duration but remained chronically infected is consistent with observations in humans showing that systemic IgG and IgA antibody responses against *H. pylori* organisms are insufficient to eradicate the infection (2). Gastric mucosal lymphoid follicles from *H. felis*-infected mice may be involved in the production of IgA antibody because of the finding of numerous IgA<sup>+</sup> B cells in gastric mucosa and preliminary observations showing IgA antibody directed against *H. felis* in the stomach wash fluid and culture supernatants from gastric explants derived from *H. felis*-infected mice (28a). Whether B cells from gastric lymphoid tissue migrate to other mucosal sites is not known. However, the finding of *H. pylori* organisms in ectopic gastric tissue, the presence of anti-*H. pylori* IgG and IgA antibody in human duodenal biopsies, and the presence of *H. mustelae* in feces from ferrets with *H. mustelae* gastritis suggest that multiple mucosal sites in the gastrointestinal tract may be stimulated during gastric *Helicobacter* infection in a variety of hosts (2, 6, 14). Immunization with *Helicobacter* antigens, which can generate mu-

cosal and systemic anti-*Helicobacter*-specific antibody (3, 8), remains an attractive possibility for prevention of *Helicobacter*-associated gastroduodenal disease.

#### ACKNOWLEDGMENTS

This work was supported by NIH grant DK 36563, NCI grant 5-P01-CA26731, NIH grant RR07036, and NIH grant RR01046.

We acknowledge the technical assistance of Dan Polidero and Lili Yan.

#### REFERENCES

- Baskerville, A., and D. B. Newell. 1988. Naturally occurring chronic gastritis and *C. pylori* infection in the rhesus monkey: a potential model for gastritis in man. *Gut* 29:465-472.
- Blaser, M. J. 1992. Hypotheses on the pathogenesis and natural history of *Helicobacter pylori*-induced inflammation. *Gastroenterology* 102:720-727.
- Chen, M., A. Lee, and S. Hazell. 1992. Immunization against gastric *Helicobacter* infection in a mouse/*Helicobacter felis* model. *Lancet* 339:1120-1121.
- Correa, P., J. G. Fox, E. Fontham, B. Ruiz, Y. Lin, D. Zavala, N. Taylor, D. Mackinley, E. de Lima, H. Portilla, and G. Zarama. 1990. *Helicobacter pylori* and gastric carcinoma. *Cancer* 66:2569-2574.
- Crabtree, J. E., T. M. Shallcross, R. V. Heatley, and J. I. Wyatt. 1991. Mucosal tumor necrosis factor  $\alpha$  and interleukin-6 in patients with *Helicobacter pylori* associated gastritis. *Gut* 32:1473-1477.
- Crabtree, J. E., T. M. Shallcross, J. I. Wyatt, J. D. Taylor, R. V. Heatley, B. J. Rathbone, and M. S. Losowsky. 1991. Mucosal humoral immune response to *Helicobacter pylori* in patients with duodenitis. *Digest. Dis. Sci.* 36:1266-1273.
- Czinn, S. J., B. B. Dahms, G. H. Jacobs, B. Kaplan, and F. C. Rothstein. 1986. Campylobacter-like organisms in association with symptomatic gastritis in children. *J. Pediatr.* 109:80-83.
- Czinn, S. J., and J. G. Nedrud. 1991. Oral immunization against *Helicobacter pylori*. *Infect. Immun.* 59:2359-2363.
- Engstrand, L., A. Scheyniles, and C. Pahlson. 1991. An increased number of v/s ( $\tau$ 8d) T-cells and gastric epithelial expression of the groEL stress protein homologue in *Helicobacter pylori* associated chronic gastritis of the antrum. *Am. J. Gastroenterol.* 86:976-980.
- Ermak, T. H., and R. L. Owen. 1986. Differential distribution of lymphocytes and accessory cells in mouse Peyer's patches. *Anat. Rec.* 215:144-152.
- Fox, J. G., P. Correa, N. S. Taylor, A. Lee, G. Otto, J. C. Murphy, and R. Rose. 1990. *Helicobacter mustelae*-associated gastritis in ferrets: an animal model of *Helicobacter pylori* gastritis in humans. *Gastroenterology* 99:352-361.
- Fox, J. G., A. Lee, G. Otto, N. S. Taylor, and J. Murphy. 1991. *Helicobacter felis* gastritis in gnotobiotic rats: an animal model of *Helicobacter pylori* gastritis. *Infect. Immun.* 59:785-791.
- Fox, J. G., G. Otto, J. C. Murphy, N. S. Taylor, and A. Lee. 1991. Gastric colonization of the ferret with *Helicobacter* species: natural and experimental infections. *Rev. Infect. Dis.* 13:S671-S680.
- Fox, J. G., B. J. Paster, F. E. Dewhirst, N. S. Taylor, L. L. Yan, P. J. Macuch, and L. M. Chmura. 1992. *Helicobacter mustelae* isolation from feces of ferrets: evidence to support fecal-oral transmission of a gastric helicobacter. *Infect. Immun.* 60:606-611.
- Fujihashi, K., T. Taguchi, W. A. Aicher, J. R. McGhee, J. A. Bluestone, J. H. Eldridge, and H. Kiyono. 1992. Immunoregulatory functions for murine intraepithelial lymphocytes:  $\tau$ 8 T cell receptor positive (TCR+) T cells abrogate oral tolerance, while  $\alpha\beta$  TCR+ T cells provide B cell help. *J. Exp. Med.* 175:695-707.
- Goodman, T., and L. Lefrancois. 1988. Expression of the  $\tau$ 8 T cell receptor on intestinal CD8+ intraepithelial lymphocytes. *Nature (London)* 333:855-858.
- Graham, D. Y., G. M. Lew, P. D. Klein, D. J. Evans, Z. A. Saeed, and H. M. Malaty. 1992. Effect of treatment of *Helicobacter pylori* infection on the long-term recurrence of gastric or duodena' ulcer. *Ann. Intern. Med.* 116:705-708.
- Hazell, S. L., T. J. Brody, A. Gal, and A. Lee. 1987. *Campylobacter pyloris* gastritis. I. Detection of urease as a marker of bacterial colonization and gastritis. *Am. J. Gastroenterol.* 82:292-296.
- Krakowka, S., D. R. Morgan, W. G. Kraff, and R. D. Leunk. 1987. Establishment of gastric *Campylobacter pylori* infection in the neonatal gnotobiotic piglet. *Infect. Immun.* 55:2789-2796.
- Lee, A., J. G. Fox, G. Otto, and J. Murphy. 1990. A small animal model of human *Helicobacter pylori* active chronic gastritis. *Gastroenterology* 99:1315-1323.
- Lee, A., S. L. Hazell, J. O'Rourke, and S. Kouprach. 1988. Isolation of a spiral-shaped bacterium from the cat stomach. *Infect. Immun.* 56:2843-2850.
- Lee, A., S. Krakowka, J. G. Fox, G. Otto, and J. C. Murphy. 1992. *Helicobacter felis* as a cause of lymphoreticular hyperplasia in the dog stomach. *Vet. Pathol.* 29:487-494.
- Lowry, O. H., N. J. Rosebrough, A. L. Farr, and R. J. Randall. 1951. Protein measurement with the Folin phenol reagent. *J. Biol. Chem.* 193:265-275.
- Mai, U. E. H., G. I. Perez-Perez, J. B. Allen, L. M. Wahl, M. J. Blaser, and P. D. Smith. 1991. Soluble surface proteins from *Helicobacter pylori* exhibit chemotactic activity for human leukocytes and are present in gastric mucosa. *J. Exp. Med.* 175:517-522.
- Marshall, B. J., and J. R. Warren. 1984. Unidentified curved bacilli on gastric epithelium in active chronic gastritis. *Lancet* i:1311-1315.
- Neilsen, H., and L. P. Andersen. 1992. Chemotactic activity of *Helicobacter pylori* sonicate for human polymorphonuclear leucocytes and monocytes. *Gut* 33:738-742.
- Nomura, A., G. N. Stemmermann, P. Chyou, I. Kato, G. I. Perez-Perez, and M. J. Blaser. 1991. *Helicobacter pylori* infection and gastric carcinoma among Japanese Americans in Hawaii. *N. Engl. J. Med.* 325:1132-1136.
- Pappo, J. 1989. Generation and characterization of monoclonal antibodies recognizing follicle epithelial M cells in rabbit gut-associated lymphoid tissues. *Cell. Immunol.* 120:31-41.
- 28a. Pappo, J., and J. G. Fox. Unpublished observations.
- Parsonnet, J., G. D. Friedman, D. P. Vandersteen, Y. Chang, J. H. Vogelman, N. Orentreich, and R. K. Sibley. 1991. *Helicobacter pylori* infection and the risk of gastric carcinoma. *N. Engl. J. Med.* 325:1127-1131.
- Paster, B. J., A. Lee, J. G. Fox, F. E. Dewhirst, L. A. Tordoff, G. J. Fraser, J. L. O'Rourke, N. S. Taylor, and R. Ferrero. 1991. Phylogeny of *Helicobacter felis* sp. nov., *Helicobacter mustelae*, and related bacteria. *Int. J. Syst. Bacteriol.* 41:31-38.
- Radin, J. M., K. A. Eaton, S. Krakowka, D. R. Morgan, A. Lee, G. Otto, and J. Fox. 1990. *Helicobacter pylori* infection in gnotobiotic dogs. *Infect. Immun.* 58:2606-2612.
- Stohrer, R., and J. F. Kearney. 1983. Fine idiotypic analysis of B cell precursors in the T-dependent and T-independent responses to  $\alpha$ 1 $\rightarrow$ 3 dextran in BALB/c mice. *J. Exp. Med.* 158:2081-2094.
- Trejdosiewicz, L. K., A. Calabrese, C. J. Smart, D. J. Oakes, P. D. Howdle, J. E. Crabtree, M. S. Losowsky, F. Lancaster, and A. W. Boyleston. 1991. Gamma delta T cell receptor-positive cells of the human gastrointestinal mucosa: occurrence and V region gene expression in *Helicobacter pylori*-associated gastritis, coeliac disease and inflammatory bowel disease. *Clin. Exp. Immunol.* 84:440-444.
- Weisz-Carrington, P., M. E. Roux, M. McWilliams, J. M. Phillips-Quagliata, and M. E. Lamm. 1979. Organ and isotype distribution of plasma cells producing specific antibody after oral immunization: evidence for a generalized secretory immune system. *J. Immunol.* 123:1705-1708.