

IN VITRO STUDY OF HUMAN RECTAL EPITHELIAL CELLS.
I. ATYPICAL ZONE OF H³ THYMIDINE INCORPORATION
IN MUCOSA OF MULTIPLE POLYPOSIS

By ELEANOR DESCHNER, CHARLES M. LEWIS, AND MARTIN LIPKIN

(From the Department of Medicine and Radiology, Cornell University Medical College,
Second [Cornell] Medical Division, Bellevue Hospital, New York, N. Y.)

(Submitted for publication January 15, 1963; accepted August 16, 1963)

The use of labeled precursors that incorporate within the cells of the gastrointestinal tract has made it possible to study cell migration, the life span of cells, and other parameters describing the DNA, RNA, and protein metabolism of these cells. Numerous isotopic investigations related to cell function in the gastrointestinal tract have been carried out in animals (1, 2), but relatively few have been performed in human subjects (3-5). Isotopic studies with precursors such as H³ thymidine, which is incorporated solely into DNA (6), have been limited to selected preterminal patients, particularly since the carcinogenic and mutagenic nature of H³ thymidine has been established (7-9). It was therefore considered advantageous to devise a technique that would maintain normal and diseased tissues outside the body for isotopic studies of this type.

This paper reports the successful use of an *in vitro* technique that allows the study of thymidine incorporation into deoxyribonucleic acid (DNA) of epithelial cells in normal and abnormal rectal tissue. With this procedure, it has been possible not only to locate cells within the rectal crypts that incorporate thymidine, but also to show a difference in the pattern of incorporation of these cells when normal rectal crypts are compared with those found in multiple polyposis.

MATERIAL AND METHODS

Sixteen patients were biopsied for studies of normal mucosa. Ambulatory hospital patients were selected from the Second (Cornell) Medical Division. The majority were convalescing from respiratory illnesses or alcoholism.

Food was withheld from the patients for 12 hours, and they were then given a saline enema 2 hours before the biopsy procedure. The patients were placed in the left lateral decubitus position. An 8-inch proctoscope was introduced. No abnormalities were seen in the proctoscopic appearance of the rectal mucosa in the normal

subjects. Biopsies were taken from the rectal valves with a Turrell angulated biopsy forceps or Wood's suction biopsy tube. Sharp cutting edges provided specimens that survived best in tissue culture, since ragged edged specimens tended to flake.

Hemostasis was achieved with gentle pressure. No complications were encountered. One specimen from each patient was preserved in 10% formalin, and the others were placed in tissue culture medium.

Biopsy specimens were removed from the forceps and first placed in normal saline at room temperature for transport to the tissue culture room located adjacent to the proctoscopy room. Within 1 to 2 minutes the tissue specimen was removed to a second normal saline solution to be washed and rinsed. It was then placed in a test tube containing Eagle's basic salt solution with 10% human serum and approximately 1 μ c of H³ thymidine (SA, 1.9 c per mmole) per ml of media. Any changes in pH were controlled by the addition of 5% sodium bicarbonate, and the growth of any contaminant bacteria was successfully checked by the addition of streptomycin and penicillin (500 U each per ml). The tube was then gassed with 95% O₂ and 5% CO₂, placed in a Dubnoff shaker at 37° C, and allowed to incubate with gentle agitation. After a specified time interval, the tissue was removed from its nutrient medium and fixed in neutral formalin. It was then dehydrated and embedded, and 3 to 4- μ sections were cut. Slides containing the sections were deparaffinized and coated with NTB (Kodak) emulsion under standard conditions (10). The coated slides were stored in light-proof, black, plastic boxes in the refrigerator for an exposure time of approximately 2 weeks. The slides were then developed by standard photographic technique and stained with basic fuchsin.

Longitudinal sections through entire rectal crypts were examined microscopically and scored in detail for the number of labeled cells present and their relative cell position in the crypt, the number of labeled and unlabeled mitoses, and the total number of cells per crypt.

Two to 18 biopsy specimens were obtained from each patient, and a total of 131 biopsies was studied. Tissue was removed after 1, 3, 6, 7, 12, and 19 hours of incubation. Normal subjects were studied at only one time-interval.

Subjects with multiple polyposis. Two subjects with multiple polyposis were seen. Patient 1 was seen on two

occasions 6 months apart, and in all, 32 small, pink, 1-to 2-mm polyps were removed for tissue-culture purposes. This tissue was examined after 1, 3, and 20 hours of incubation. Patient 2 was studied on one occasion, and 15 1- to 2-mm polyps were removed. The tissue was examined after 1, 3, and 21 hours of incubation.

Patient 1, a 30-year-old white male, was first examined in 1949 at the age of 17 and found to have multiple polyps with no unusual pigmentation present. Sigmoidoscopy revealed polyposis throughout the entire rectum, and no normal rectal tissue was visible. Biopsy of the sigmoid colon showed adenomata with cellular atypism but no evidence of malignancy. A barium enema revealed involvement of the entire colon.

In 1951, a subtotal colectomy and an ileoproctostomy were performed. The patient's course since then has been characterized by the continued formation of polyps of all sizes that are periodically removed by snare and electrocoagulation.

Family history revealed that his mother is living and well, but that his father died of a disease believed to be cancer of the stomach. He has five brothers and one sister who are living and well. Three of the patient's brothers were seen in the clinic. Barium enemas and proctoscopy examinations of all three have been negative. The rest of the family has not consented to be examined.

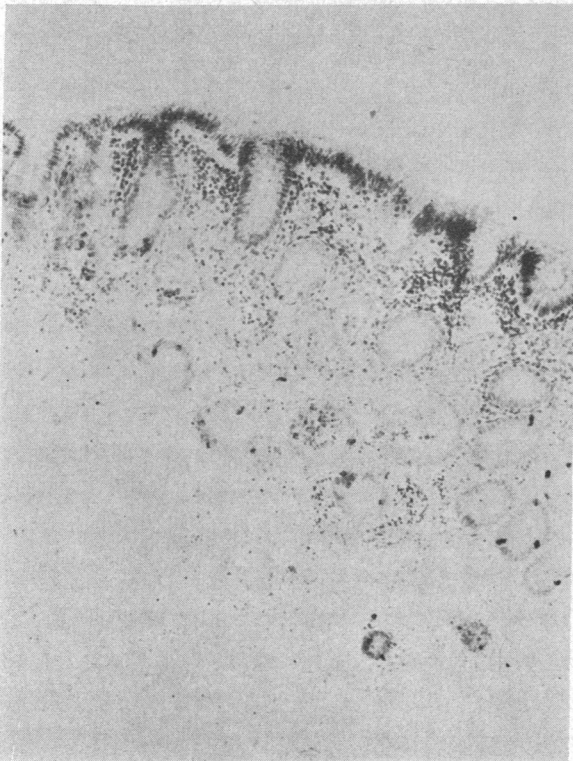


FIG. 1. PHOTOMICROGRAPH OF NORMAL, HUMAN, RECTAL MUCOSA 19 HOURS AFTER INCUBATION. $\times 90$. The specimen is intact, and the rectal crypts remain well defined with little or no lysis present.

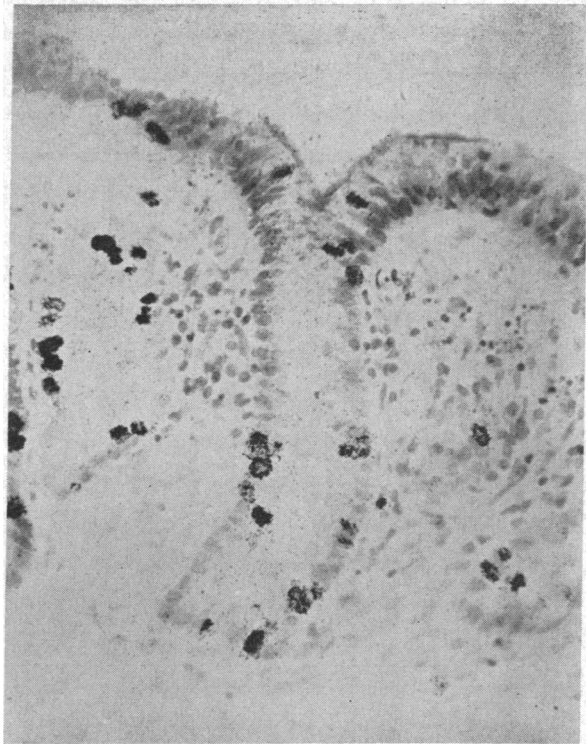


FIG. 2. A PORTION OF THE PREVIOUS SPECIMEN, AT 19 HOURS, SHOWING THAT THE EPITHELIAL CELLS ARE NOT PYKNOTIC AND INCORPORATION OF THYMIDINE INTO THE NUCLEAR DNA HAS OCCURRED ALONG THE ENTIRE LENGTH OF THE CRYPT. $\times 200$.

The patient has subsequently married and has a 2-year-old daughter who is entirely well and has not been examined.

Patient 2, a white female, age 37, was seen in 1961 when a diagnosis of cancer of the descending colon was established. Later in 1961, a resection of the carcinoma with anastomosis of the left colon and sigmoid was performed. She was seen again in 1962 when recurrence of the carcinoma was proved at a laparotomy. In addition, during the latter admission, a proctoscopic examination revealed more than 15 small (2 mm in diameter), isolated polyps in the rectum and sigmoid.

Family history disclosed that the patient's mother had died at age 46 of primary cancer of the rectum and metastases. The patient's only son has not been examined to date.

In both cases described here, cellular atypism was seen on pathological examination, and in Patient 1 polyps were distributed throughout the entire colon. These are features that are present in familial polyposis. Although the term "familial polyposis" has been used to describe cases of this type (11, 12), the hereditary pattern of the disease is not clearly borne out in either of the present cases, probably because the examination of family members is incomplete.

TABLE I
In vitro rectal mucosa

Incubation time	Patients	Crypts scored	Total cells observed	Labeled cells	No. mitoses		Cells/crypt	Labeled cells
<i>hrs</i>	<i>no.</i>	<i>no.</i>	<i>no.</i>	<i>no.</i>	<i>no.</i>	<i>%</i>	<i>mean no.</i>	<i>%</i>
Normal								
1	1	9	994	10	8	0.8	110.4	1
3	5	16.5	2,402	145	15	0.6	145.5	6
6-7	4	15	1,654	203	5	0.3	110.3	12
12	2	18	1,165	98	6	0.5	64.7	8
19	4	12	1,162	204	3	0.3	96.8	18
Multiple polyposis (exp't 1a)								
1		8	1,278	6	21	1.6	159.7	0.5
3		7.5	763	78	4	0.5	101.7	10
20		8	439	87	2	0.5	54.8	19
Multiple polyposis (exp't 1b)								
1		9	1,147	17	8	0.7	127.4	1
3		9	1,127	53	9	0.8	125.2	5
20		9	623	131	8	1.28	69.2	21
Multiple polyposis (exp't 2)								
1		12	1,132	27	1	0.1	94.3	2
3		12	1,674	48	5	0.3	139.5	3
21		12	1,315	286	5	0.4	109.5	22

RESULTS

Survival of the entire biopsy specimen with little or no lysis was found in nearly all specimens of the normal and polypoid tissue examined after short incubation times. Survival was determined by retention of normal morphology of the tissue and the continued appearance of mitotic figures.

After 19 hours, however, 50% of the specimens demonstrated some degree of histological tissue deterioration. The remaining specimens appeared intact, and the rectal crypts remained well-defined and without cellular necrosis. Figure 1 is a low-power photomicrograph of an entire biopsy specimen that demonstrates normal mucosa without

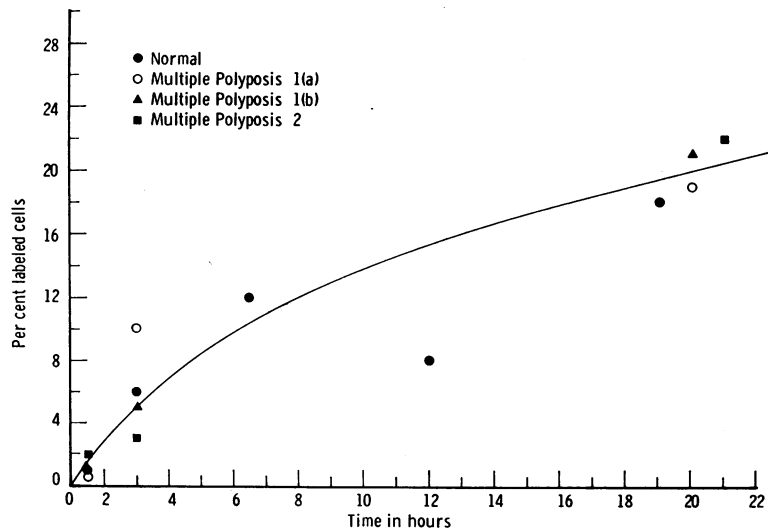


FIG. 3. RATE OF APPEARANCE OF EPITHELIAL CELLS LABELED WITH TRITIATED THYMIDINE IN THE NORMAL RECTAL TISSUE AND IN THE MULTIPLE POLYPOSIS SPECIMENS.

evidence of tissue degeneration. The appearance of one crypt from this biopsy after 19 hours of incubation can be seen under higher magnification in Figure 2.

Table I provides the data obtained from the analysis of the tissue culture material. The number of crypts scored ranged from 7.5 to 18, and the mean number of cells in each crypt ranged from 64.7 to 145.5 in the normal subjects and from 54.8 to 159.7 in the polyposis specimens. The percentage of labeled cells ranged from 1% at 1 hour to 18% at 19 hours in the normal mucosa, and from 0.5% to 2% at 1 hour and from 19% to 22% at 20 to 21 hours in the polyp tissue.

Figure 3 shows the percentage of labeled epithelial cells of the normal rectal tissue and polyposis specimens plotted against time. There is a gradual increase in the number of labeled cells observed with increasing time in tissue culture. The rate of appearance of newly labeled cells was similar in both the normal and polyp tissue, and close agreement occurred both at the short and long incubation periods.

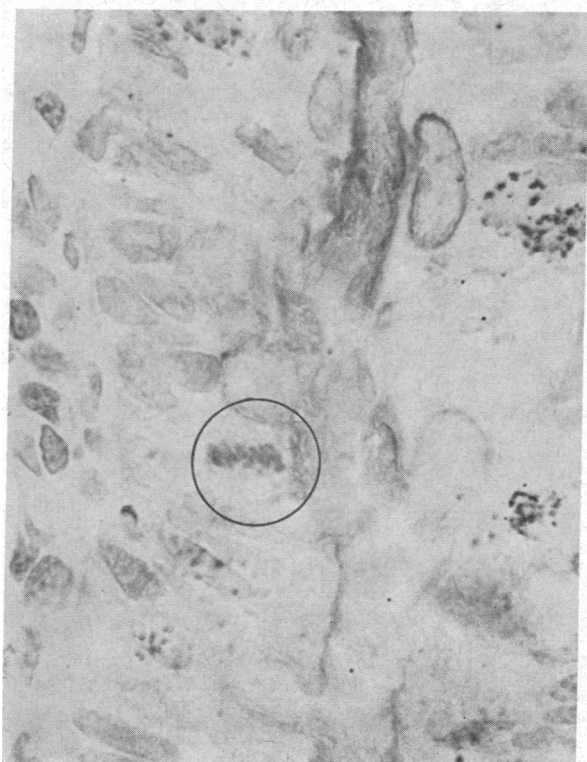

FIG. 4. LABELED MITOSIS IN THE UPPER THIRD OF A RECTAL CRYPT IN THE POLYPOSIS TISSUE, $\times 1,250$.

TABLE II
Position of percentages of total number of rectal epithelial cells labeled *in vitro**

Incubation time	Lower crypt	Middle crypt	Upper crypt
<i>hrs</i>	%	%	%
Normal			
1	70	30	0
3	56	33	11
6-7	54	33	13
12	54	29	17
19	42	29	29
Multiple polyposis (exp't 1a)			
1	16.5	16.5	67
3	15	33	52
20	23	37	40
Multiple polyposis (exp't 1b)			
1	6	18	76
3	17	26	57
20	21	30	49
Multiple polyposis (exp't 2)			
1	19	11	70
3	2	2	96
21	42	36	22

* Percentage labeling based on individual crypt size.

Mitosis at the various intervals studied was infrequent in the normal specimens, occurring in less than 1% of the total number of cells observed. Labeled mitoses both in normal and polyp tissue were seen in specimens incubated for 19 hours (Figure 4). Mitoses were usually seen in the lower two-thirds of the crypts in normal rectal mucosa, but in the polyp tissue they were occasionally seen in the upper third of the crypt (Figure 4).

The number of mitotic figures present in each polyp specimen varied considerably (Table I). Some polyp specimens were found to have almost twice the number of mitoses present in the normal tissue, with mitotic rates of 1.6% and 1.28% observed and two or more mitotic figures observed in some crypts. Several thousand cells, however, would have to be observed to determine more accurately the mean mitotic frequency of cell division in this slowly dividing tissue.

Seventy per cent of normal, rectal, epithelial cells labeled after 1 hour of incubation were located in the lower portion of the crypts, with no label found in the upper zone and free edge (Table II). Further incubation of normal rectal tissue resulted in an extension of labeled cells to the

upper portion of the crypts and continued heavy labeling of cells in the lower third of the crypts.

In contrast, the polypoid tissue maintained *in vitro* for 1 hour was found in all experiments to incorporate thymidine actively into epithelial cells along the entire length of the rectal crypts. In addition, 67% (experiment 1a), 76% (experiment 1b), and 70% (experiment 2), respectively, of the labeled cells were located in the upper third of the crypts (Table II). At later periods, labeled cells appeared in greater numbers in the lower portion of the crypts, but the upper third of the crypts continued to have high concentrations of cells that actively incorporated thymidine.

A high-power photomicrograph of the normal, human rectal mucosa after 3 hours in tissue culture medium (Figure 5) demonstrates visually the pattern of thymidine incorporation found in normal tissue. The greatest number of labeled cells is located at the basal portion of the crypt with an occasional labeled cell appearing higher in the crypt column. In contrast, Figure 6 shows a por-

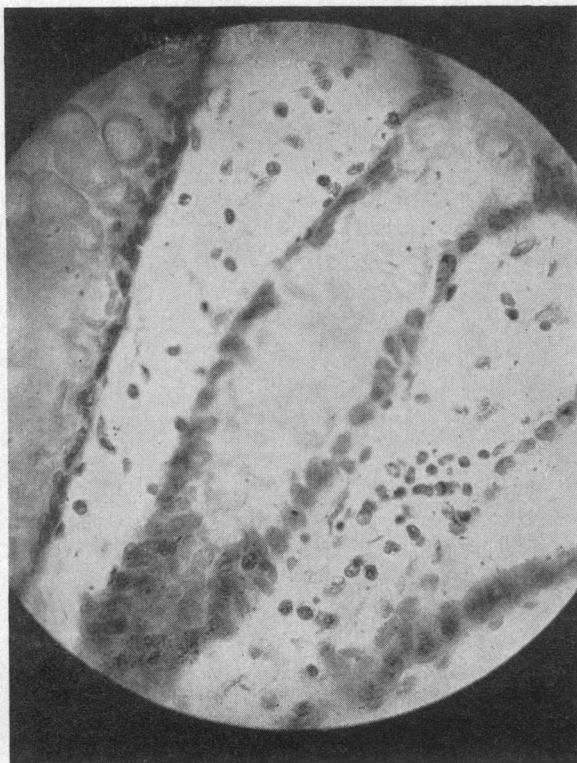


FIG. 5. A RECTAL CRYPT IN NORMAL MUCOSA AFTER 3 HOURS OF INCUBATION, SHOWING LABELED CELLS PREDOMINANTLY AT THE BASE OF THE CRYPT. $\times 600$.

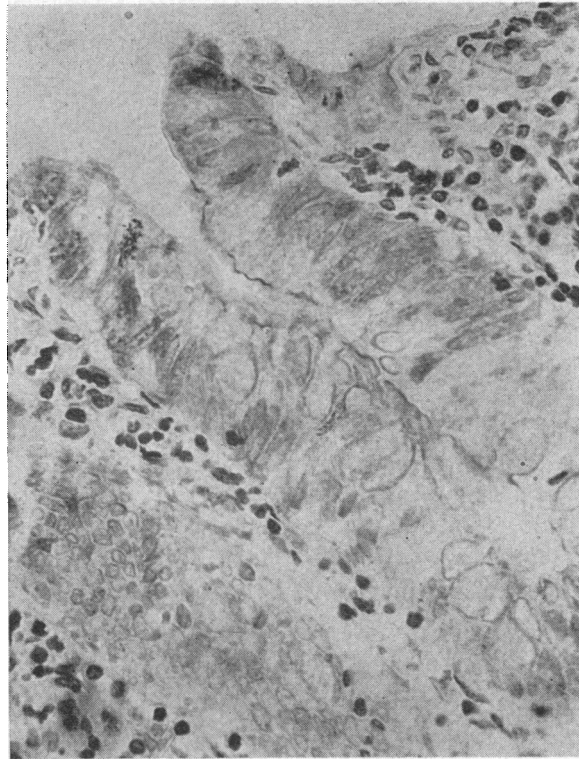


FIG. 6. A RECTAL CRYPT IN THE POLYPOSIS TISSUE AFTER 3 HOURS OF INCUBATION, SHOWING LABELED CELLS IN THE UPPER THIRD AND ALONG THE LUMINAL SURFACE OF THE CRYPT. $\times 600$.

tion of the polyposis tissue also incubated for 3 hours. A reversed pattern of labeling is seen with the greatest number of labeled cells located in the upper third of the crypt and along the luminal border of the crypts.

DISCUSSION

An experimental procedure is presented that permits rectal epithelium to be maintained in a viable state for short periods *in vitro*, in order that actively proliferating cells may be identified both qualitatively and quantitatively. There is good reason to believe that the metabolic activities responsible for thymidine uptake have deteriorated to some extent by 19 to 21 hours *in vitro*, although the percentage of mitoses seen then is approximately the same or higher than at earlier periods, and the number of cells synthesizing DNA doubled in 20 hours under these conditions. Nevertheless, since 50% of the biopsies lysed by 19 to 21 hours, it is reasonable to postulate some biochemical degeneration in those specimens that survive with

little or no lysis present. The basic difference shown here between normal and polyp tissue had manifested itself early, i.e., in 1 to 3 hours, when the problem of degeneration is not an important factor in this system.

In the early periods, the question of penetration or accessibility of the isotope to the lower zone of the crypts in the polyp tissue could be raised. Evidence that this factor did not influence the labeling site in the polyp crypts, however, can be derived from a number of points. The number of cells synthesizing DNA at early times increases rapidly in both normal and polyp tissues. Also, the number of labeled cells per crypt present in 1 to 3 hours is remarkably similar in both tissues, indicating a population of approximately the same size is entering the synthesis stage in both tissues. In fact, in some instances, the number of labeled cells per crypt was higher in the polyp tissue than in the normal. In addition, if accessibility were a factor governing differential incorporation of H³ thymidine into polyp crypts, then we might expect no label to occur at the base of these crypts. Instead we find that 16.5%, 6%, and 19% of the total number of labeled cells (Table II) present at 1 hour in the polyps are in the lower third of these crypts. It would appear then that the isotope was available to all the cells lining the crypt, but the greatest number of actively synthesizing cells in the polyp occurred along the surface closest to the lumen.

The mitotic activity of normal human mucosa was less than 1%. Other studies in this laboratory following *in vivo* injection of H³ thymidine have revealed a mitotic frequency of less than 1% in crypts of the rectum (13). The infrequent appearance of mitotic figures in our study would also fit well with the estimate of Cole and McKalen of a turnover time of about 6 to 8 days (3).

The frequency of mitosis in normal rectal epithelium maintained *in vitro* may have been low because of the general fasting conditions of the patients. Fasting has been shown to cause a reduced mitotic rate in the rat (14). In addition, the specific effects on mitotic activity of routine pharmacologic agents administered to these patients are not known.

At some of the later incubation times of the polyposis tissue, there appeared to be a selective advantage for the survival of shorter crypts, that

is, while the same number of crypts was scored as at the earlier times, the total number of observed cells was reduced at later periods. This is seen at the 20-hour incubation period in both experiments with the polyposis tissue of Patient 1, whereas in the normal rectal mucosa and in Patient 2, this selective effect is small.

The earliest time that labeled mitoses were encountered in either normal or diseased tissue was at 19 hours. Thus, the minimal period for a cell to go from S phase, when thymidine is incorporated and DNA synthesized, to the mitotic phase is 19 hours. Since our sampling does not cover the period 12 to 19 hours, the G₂ or premitotic portion of the proliferative cycle may be a few hours shorter than the figure stated. Although it was not possible to follow this tissue for several days, one might roughly estimate that the mean generation time of these cells should be at least 3 to 4 times this interval of 19 hours (5), that is, a cell may complete its generation cycle in rectal tissue kept *in vitro* approximately once every 3 to 4 days.

The incorporation of H³ thymidine into the nuclei of normal specimens occurred in the same location as after *in vivo* injection of the isotope (5). The lower portions of the crypts were most frequently labeled at early incubation times, although 11% of the surface cells were labeled at 3 hours. After 19 hours of incubation, but not after 3, some cells on the crypt, epithelial cell column could have undergone division and supplied new, labeled, surface epithelial cells. In a study in which H³ thymidine was injected *in vivo*, labeled, rectal, crypt epithelial cells were found to reach the surface in 20 hours (13).

Tissue from the patients with multiple polyposis showed a pattern quite different from the normal, with labeled cells present at early incubation periods located almost exclusively in the upper portion of the crypt and along the free surface of the mucosa. After 19 hours of incubation, some mitosis, and occasionally a labeled mitosis, was found in the upper crypt. This pattern of early incorporation is abnormal and reveals the presence of proliferating cells at the upper portion of the crypts, where mature, well-differentiated cells are characteristically present. The evidence that these surface cells in the polyp tissue incorporate thymidine shortly after exposure to label is of in-

terest because of the abnormal growth of the polypoid tissue and the malignant degeneration known to take place. This observation may also be related to the differences in staining quality seen in cells near or at the surface of polyps (15).

A possible interpretation of the data presented is that two populations of cells are present, a fast-moving population at the tip and a slower moving one at the base of the crypt. The slower growing cells may replace a subsurface epithelium, and the faster cells may perpetuate the polyposis tissue by continued outgrowth or budding. Further studies similar to the one presented here are continuing with the hope that correlations can be developed to identify the rate and mechanism of growth of polypoid tissue and the probability of the future malignancy of such tissue.

SUMMARY

A method is described for *in vitro* culture of human rectal mucosa for periods up to 24 hours. The rate of incorporation of H³ thymidine was measured in nuclei of epithelial cells of rectal mucosa from 16 normal subjects and two subjects with multiple polyposis. Quantitative data on the percentage of labeled cells found in various portions of the rectal crypts at specific time intervals after incubation with the isotope revealed that the rate of incorporation in normal and polyposis tissue was similar. An alteration in the pattern of thymidine incorporation into the crypt epithelium of the polyposis tissue was noted, however, indicating a displacement of the zone of active cell proliferation in these crypts.

ACKNOWLEDGMENTS

The authors gratefully acknowledge the advice and encouragement of Dr. Thomas P. Almy and the technical assistance of Mrs. Camille Boyle, Miss Geraldine Kraska, and Mr. Jay Rubin.

One multiple polyposis subject was provided through the kind cooperation of Dr. Michael Deddish and Dr. Maus Stearns, Rectum and Colon Service, Memorial Hospital, New York, N. Y.

REFERENCES

1. Messier, B., and C. P. LeBlond. Cell proliferation and migration as revealed by radioautography after injection of thymidine H³ into male rats and mice. *Amer. J. Anat.* 1960, **106**, 247.
2. Quastler, H., and F. G. Sherman. Cell population kinetics in the intestinal epithelium of the mouse. *Exp. Cell. Res.* 1959, **17**, 420.
3. Cole, J. W., and A. McKalen. Observations of cell renewal in human rectal mucosa *in vivo* with thymidine-H³. *Gastroenterology* 1961, **41**, 122.
4. Baserga, R., G. C. Henegar, W. E. Kisieleski, and H. Lisco. Uptake of tritiated thymidine by human tumors *in vivo*. *Lab. Invest.* 1962, **11**, 360.
5. Lipkin, M., P. Sherlock, and B. M. Bell. Generation time of epithelial cells in the human colon. *Nature (Lond.)* 1962, **195**, 175.
6. Friedkin, M., D. Tilson, and D. Roberts. Studies of desoxyribonucleic acid biosynthesis in embryonic tissues with thymidine-C¹⁴. *J. biol. Chem.* 1956, **220**, 627.
7. Lisco, H., R. Baserga, and W. E. Kisieleski. Induction of tumours in mice with tritiated thymidine. *Nature (Lond.)* 1961, **192**, 571.
8. Baserga, R., H. Lisco, and W. E. Kisieleski. Further observations on induction of tumors in mice with radioactive thymidine. *Proc. Soc. exp. Biol. (N. Y.)* 1962, **110**, 687.
9. Bateman, A. J., and A. C. Chandley. Mutations induced in the mouse with tritiated thymidine. *Nature (Lond.)* 1962, **193**, 705.
10. Messier, B., and C. P. LeBlond. Preparation of coated radioautographs by dipping sections in fluid emulsion. *Proc. Soc. exp. Biol. (N. Y.)* 1957, **96**, 7.
11. McKusick, V. A. Genetic factors in intestinal polyposis. *J. Amer. med. Assoc.* 1962, **182**, 271.
12. Veale, A. M. O. Clinical and genetic problems in familial intestinal polyposis. *Gut* 1961, **1**, 285.
13. Lipkin, M., B. Bell, and P. Sherlock. Cell proliferation kinetics in the gastrointestinal tract of man. I. Cell renewal in colon and rectum. *J. clin. Invest.* 1963, **42**, 767.
14. Hunt, T. E. Mitotic activity in the gastric mucosa of the rat after fasting and refeeding. *Anat. Rec.* 1957, **127**, 539.
15. Valdes-Dapena, A., and W. J. Beckfield. Adenomatous polyps of the intestine. *Gastroenterology* 1957, **32**, 452.