

### Supplementary figure legends:

**Fig S1. Spleen, lymph node and liver lymphomas in p53<sup>KO</sup>/ATF2<sup>KI</sup> and p53<sup>KO</sup>/ATF2<sup>WT</sup> animals.** Histopathological analysis of tumors from the ATF2<sup>KI</sup> and WT animals crossed with p53<sup>-/-</sup> mice reveal T cell lymphoma as the primary tumor. Examples shown represent lymphomas in spleen lymph nodes or liver. Representative images of CD3 positive staining are also shown.

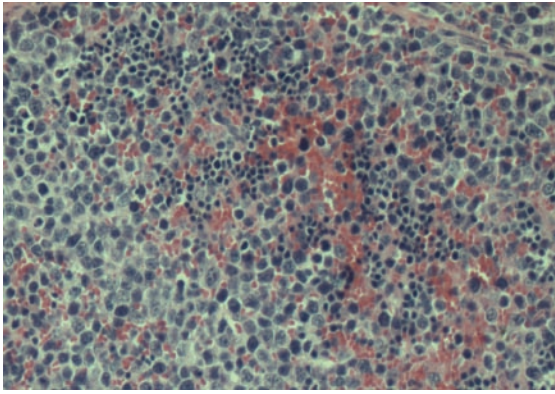
**Fig S2. Early onset of low-grade skin tumors in ATF2<sup>KI</sup> mice.** Percentage of mice with skin tumors identified early as week 11 following DMBA/TPA treatment. Graph depicts relative percentage of tumors at the indicated time points.

**Fig S3. ATF2 KI mice develop higher incidence of SPC.** Histopathological analysis identified the tumor types as papilloma, squamous cell carcinoma (SCC), or Spindle-cell carcinoma (SPC) (see data in Fig S4). Shown is percentage of tumor type among the ATF2 KI and WT groups.

**Fig S4. Immunostaining of skin tumors from ATF2 KI and WT mice.** Immunostaining was performed using the indicated antibodies as detailed in Methods and legend to Fig 7. Magnification shown is x40.

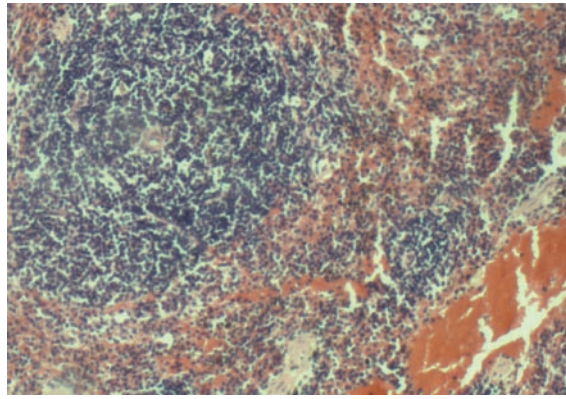
**Fig S5. BrdU staining of skin tumors.** Immunostaining was performed using the antibodies to BrdU as detailed in Methods. Samples shown are representatives of papilloma, and SCC of the ATF2 KI tumors. Similar pattern was seen in the WT mice. Magnification shown is x40.

ATF2 KI / p53 KO

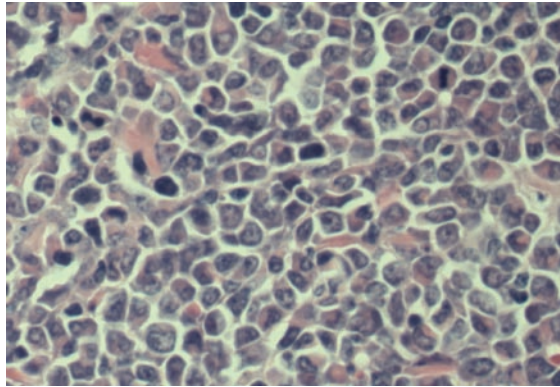


spleen lymphoma

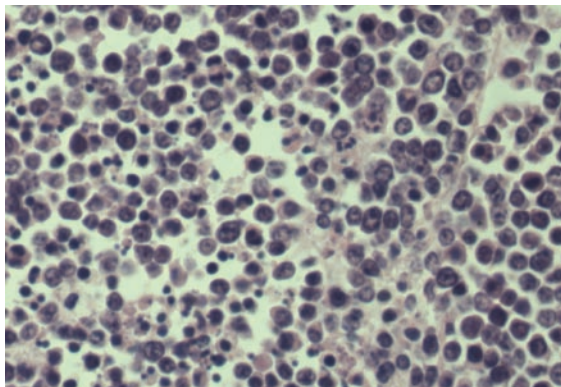
ATF2 WT / p53 KO



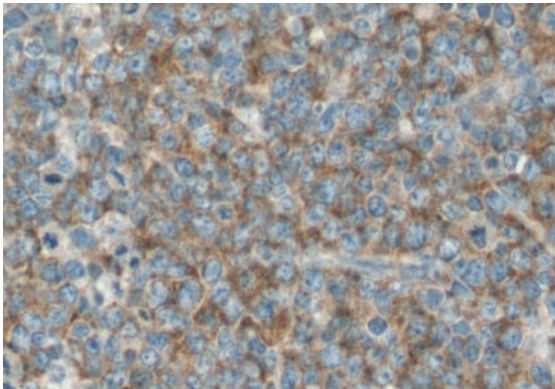
lymph node lymphoma



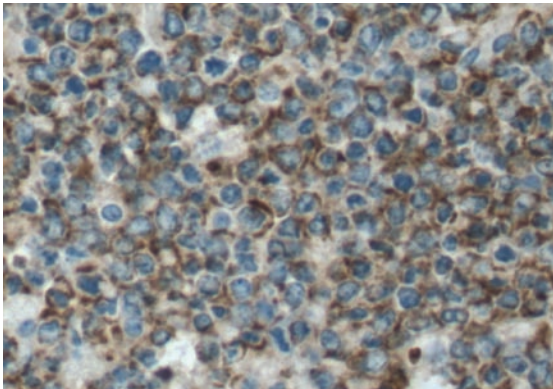
myeloid lymph node lymphoma



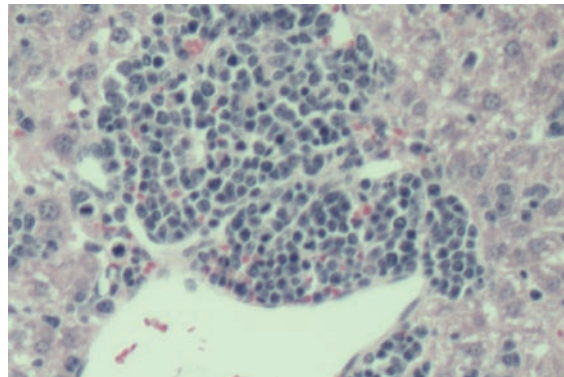
lymph node lymphoma



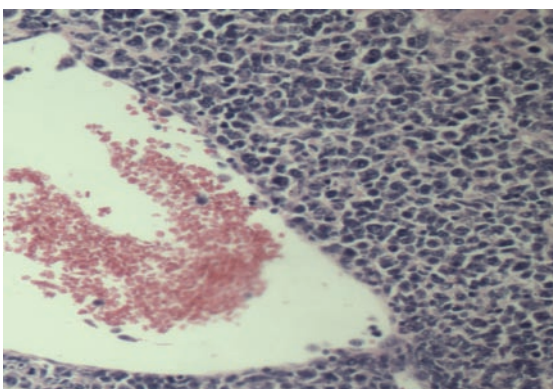
CD3 positive lymph node lymphoma



lymphoma spleen cd3 positive



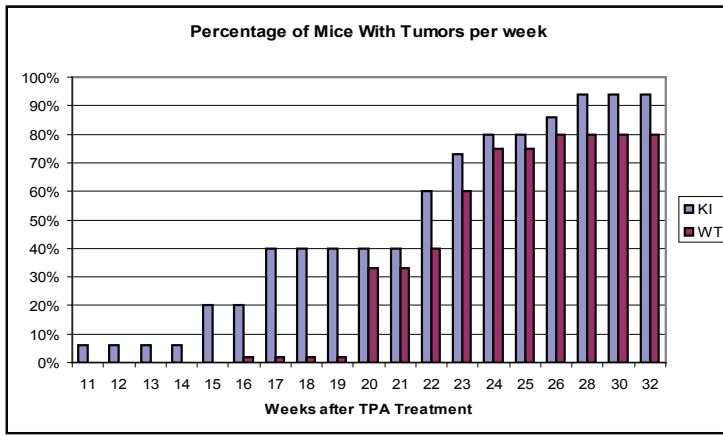
liver lymphoma



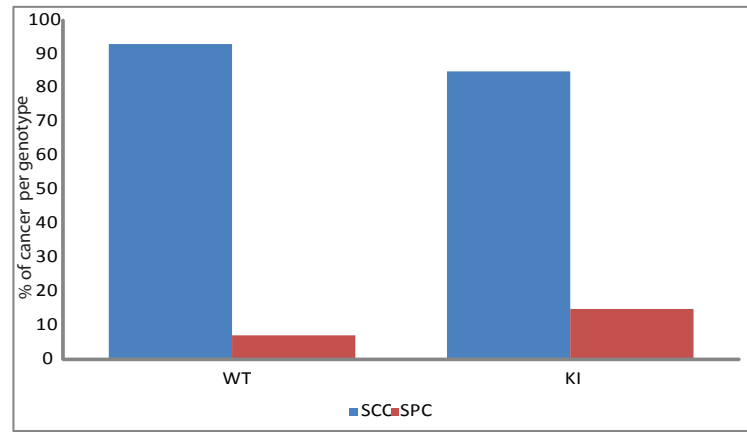
liver lymphoma



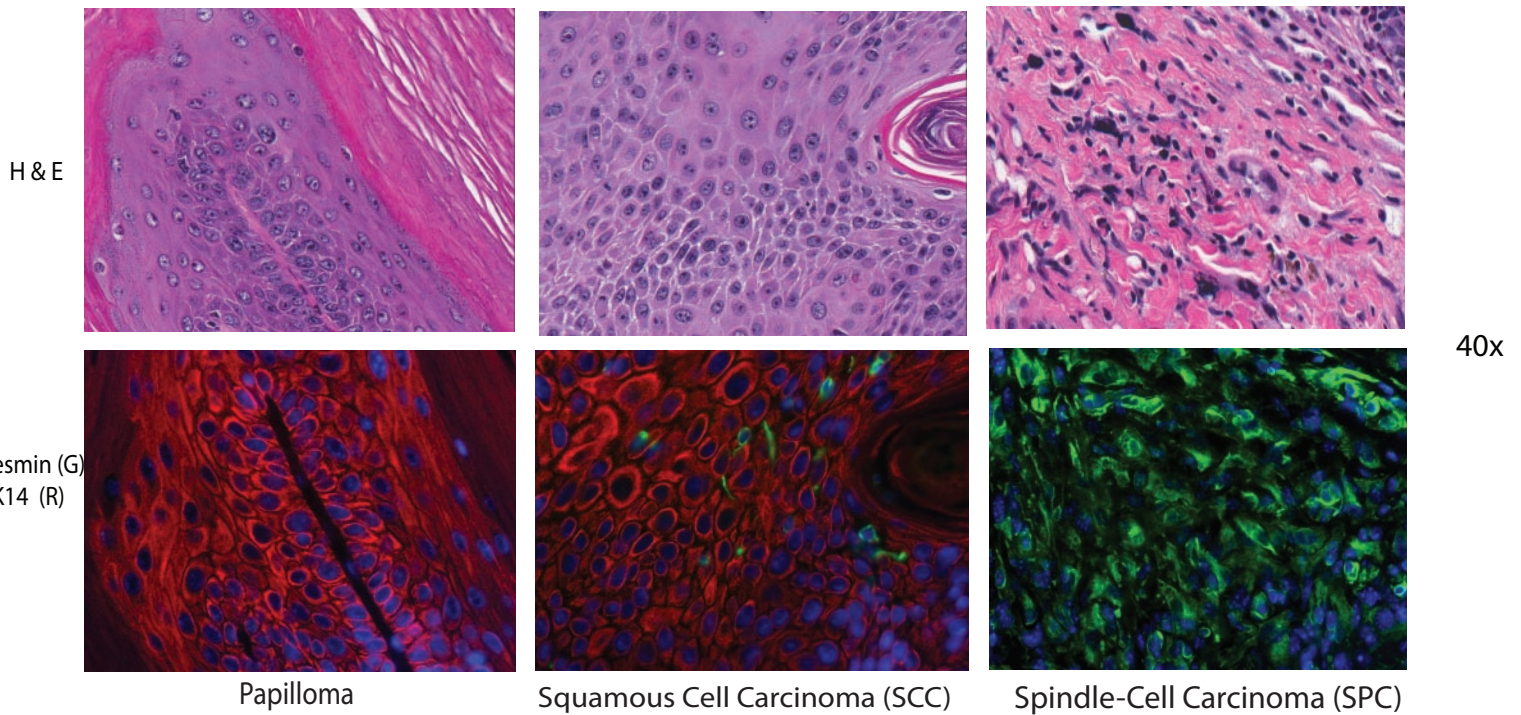
S2



S3



S4



S5

