

Lysosomal α -N-Acetylgalactosaminidase Deficiency, the Enzymatic Defect in Angiokeratoma Corporis Diffusum with Glycopeptiduria

Tamotsu Kanzaki,* Anne M. Wang,[†] and Robert J. Desnick[‡]

*Department of Dermatology, Nagoya City University Medical School, Nagoya, Japan; and the [†]Division of Medical and Molecular Genetics, Mount Sinai School of Medicine, New York 10029

Abstract

Recently a novel case of angiokeratoma corporis diffusum with glycoaminoaciduria was described in a 46-yr-old Japanese woman. Known causes of the cutaneous manifestation were eliminated by enzyme analyses, and further characterization of the accumulated urinary *O*-linked sialopeptides revealed identity to those excreted by patients with an infantile neuroaxonal dystrophy due to lysosomal α -N-acetylgalactosaminidase deficiency. Investigation of the α -N-acetylgalactosaminidase activity and protein in the proband revealed less than 2% of normal activity and the absence of detectable immunoreactive enzyme protein, findings comparable to those in the patients with infantile neuroaxonal dystrophy and α -N-acetylgalactosaminidase deficiency. In addition, the proband's unaffected offspring had half-normal levels of α -N-acetylgalactosaminidase activity, consistent with this enzymatic deficiency being the primary metabolic defect in this autosomal recessive trait. Ultrastructural examination of skin and blood cells from the adult proband revealed the presence of prominent lysosomal inclusions containing diffuse amorphous and filamentous material. In contrast, these morphologic findings were not observed in the non-neural tissues from patients with infantile neuroaxonal dystrophy and α -N-acetylgalactosaminidase deficiency. These studies document the occurrence of two forms of α -N-acetylgalactosaminidase deficiency and sialopeptiduria, a severe infantile-onset form of neuroaxonal dystrophy without angiokeratoma or visceral lysosomal inclusions and an adult-onset form characterized by angiokeratoma, extensive lysosomal accumulation of sialoglycopeptides and the absence of detectable neurologic involvement. (*J. Clin. Invest.* 1991. 87:707-711.) **Key words:** α -N-acetylgalactosaminidase • angiokeratoma corporis diffusum • lysosomal hydrolase

Introduction

Angiokeratoma corporis diffusum is the dermatologic hallmark of several inherited lysosomal storage diseases (1) including Fabry disease, aspartylglycosaminuria, fucosidosis, G_{M1} gangliosidosis type 2, galactosialidosis, β -mannosidosis, and sialidosis (2-7). These cutaneous lesions are telangiectasia (i.e.,

ectatic vessels) that result from the progressive lysosomal deposition of certain undegraded glycolipids, glycopeptides, and/or oligosaccharides in the endothelial cells of capillaries and small vessels in the papillary dermis of individuals with these disorders. The lesions first appear as isolated small red "petechial-like" maculae and are characteristically distributed on the umbilicus, genital area, and lower extremities. With age, they increase in density and the larger lesions become hyperkeratotic dark blue to black papules; hence, the descriptive designation as angiokeratomas.

Recently, Kanzaki and colleagues (8) described a 46-yr-old Japanese woman, the product of a consanguineous union, who had angiokeratoma corporis diffusum and glycoaminoaciduria. Biochemical analyses clearly ruled out the above inherited forms of angiokeratoma, and further studies revealed that the accumulated urinary glycoaminoacids were *O*-linked sialopeptides (e.g., $NANA\alpha 2 \rightarrow 3Gal\beta 1 \rightarrow 3GalNAc\alpha 1 \rightarrow O$ -threonine or serine, [9]). Because the patient had normal α -neuraminidase and β -galactosidase activities, the nature of the specific metabolic lesion underlying the sialoglycopeptiduria was unclear. At about the same time, a new form of inherited infantile neuroaxonal dystrophy due to the deficiency of lysosomal α -N-acetylgalactosaminidase was identified in two consanguineous German sibs (10, 11). The affected brothers appeared to develop normally during the first year of life and then experienced a rapid neurodegenerative course. Identification and subsequent characterization of the accumulated urinary glycopeptides excreted by the sibs led to the demonstration that the primary enzymatic defect in this neurodegenerative disorder was the deficient activity of α -N-acetylgalactosaminidase, a lysosomal glycosidase that releases α -N-acetylgalactosaminyl residues from glycoconjugates including *O*-linked glycopeptides (11, 12).

The possibility that the sibs with infantile neuroaxonal dystrophy and the woman with angiokeratoma excreted the same or similar sialoglycopeptides suggested that these unrelated probands may represent remarkably distinct phenotypic variants of the same enzymatic defect. Support for this concept was provided by the recent demonstration that the urinary sialoglycopeptides from the affected individuals were essentially identical (13). In this communication, we report that the specific enzymatic defect in the Japanese woman with angiokeratoma corporis diffusum and glycoaminoaciduria (8) is the deficient activity of lysosomal α -N-acetylgalactosaminidase. This finding not only identifies the enzymatic defect in an adult-onset form of angiokeratoma corporis diffusum, but also delineates the remarkably distinct adult and infantile phenotypes resulting from the deficient activity of α -N-acetylgalactosaminidase.

Methods

Morphologic studies. All biopsies were obtained from the proband with informed consent. Tissue for light microscopy was fixed in formalin,

Address all correspondence and reprint requests to Dr. R. J. Desnick, Mount Sinai School of Medicine, Fifth Avenue at 100th Street, New York, NY 10029.

Received for publication 18 March 1991 and in revised form 1 May 1991.

J. Clin. Invest.

© The American Society for Clinical Investigation, Inc.

0021-9738/91/08/0707/05 \$2.00

Volume 88, August 1991, 707-711

embedded in paraffin, and sections were stained with hematoxylin and eosin. For electron microscopy, specimens were fixed in glutaraldehyde (5%), postfixed in 2% buffered osmic acid solution for 2 h, and embedded in Epon. Semithin sections were stained in Azur II-toluidine blue and ultrathin sections were contrasted with uranyl acetate and lead citrate.

Biochemical studies. α -N-acetylgalactosaminidase activity in plasma, cultured fibroblasts, and lymphoblasts was determined with 4-methylumbelliferyl- α -N-acetylgalactosaminide (4MU- α -GalNAc) (14) as previously described (11). Protein concentrations were determined by the fluorescamine method (15).

α -N-acetylgalactosaminidase was purified to homogeneity from human lung as described (16, 17) and used to produce antibodies in New Zealand white rabbits. Immunoblotting of fibroblast extracts, equalized for total protein, were performed as previously described (18) with 10 μ g of anti- α -GalNAc IgG per milliliter. The sensitivity of this procedure was determined to be 0.00003 nmol per second of α -GalNAc activity (11).

Results

Case report. The proband was a 46-yr-old Japanese woman, the product of a first cousin union. She was the youngest of ten children, the three oldest siblings died in infancy of measles and pneumonia, and two brothers died of heart failure and tuberculosis at 63 and 20 years of age, respectively. She has two sisters, two brothers, a son, and a daughter. She was healthy until about age 28, when a disseminated petechiae-like eruption was first noted. The lesions initially appeared on the lower torso and spread in a distribution essentially identical to that observed in males affected with Fabry disease (2). At age 48, she had an episode of angina pectoris which has not reoccurred. She currently works as a hospital aid. No dermatologic manifestations were observed in her four healthy living sibs or her two healthy children.

On examination, the patient was 150.5 cm tall and weighed 70 kg. She had no organomegaly or lymphadenopathy. There were no detectable neurological, motor, skeletal, or ocular abnormalities. Her facies were slightly coarse with an enlarged nasal tip and depressed nasal bridge, thick lips, and widely spaced teeth. An EKG was normal.

Dermatological examination revealed dry skin with red to purple maculopapules ranging from less than 1 to 3 mm in diameter and over 100/cm² in the most dense areas (Fig. 1). The telangiectasia were densely distributed over the lower abdomen, groin, and buttocks, and less densely on the face, breasts, and fingers. The larger lesions were hyperkeratotic and did not blanch with pressure. Similar lesions were observed on the lips, as well as the oral and pharyngeal mucosa. Gastroscopic examination revealed telangiectasia on the gastric mucosa. Dilated blood vessels were observed in the ocular conjunctiva, and retinal vessels with a corkscrew-like appearance were observed by funduscopy. No retinal hemorrhage, cherry-red spot, or corneal opacities were observed.

Morphologic studies. Histopathologic examination of the skin lesions revealed localized hyperkeratosis and dilated thin walled blood vessels, which were sometimes blood filled (Fig. 2 A). Dilated vessels were also observed in the mid and upper dermis. Cytoplasmic vacuoles were observed in peripheral granulocytes, monocytes, and lymphocytes in blood smears with Giemsa stain.

Ultrastructural analysis revealed the presence of numerous cytoplasmic vacuoles in vascular endothelial cells, pericytes,

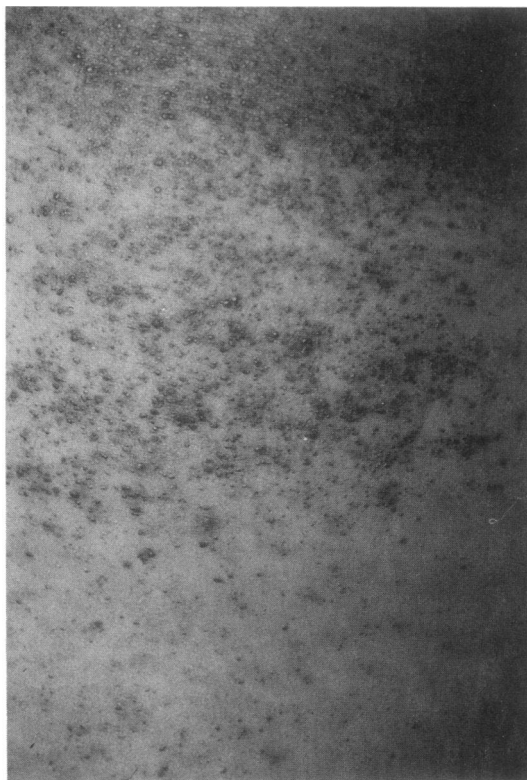

Figure 1. Distribution and density of angiokeratomas on the back of the proband's thigh.

fibroblasts, fat cells, Schwann cells, neural axons, arrector smooth muscle cells, sweat gland cells, and peripheral leukocytes. These membrane-lined vacuoles, which were most prominent in the vascular endothelium and sweat gland cells (Fig. 2 B and C), contained diffuse amorphous and filamentous material. Vacuoles in vascular endothelial cells had multilayered basal laminae, while electron-dense lamellar structures were observed in some vacuoles in sweat gland cells (Fig. 2 C).

Characterization of the enzymatic defect. Table I shows the α -N-acetylgalactosaminidase activities in various sources from the proband with angiokeratoma corporis diffusum and sialoglycopeptiduria. Using the specific fluorogenic substrate, 4MU- α -GalNAc, less than 2% of the respective mean normal values were observed in plasma and in cultured cell extracts. This residual activity was not due to assay variability or to background fluorescence, because the activity was linear with time and protein concentration (data not shown). When fibroblast extracts from the affected proband (0.44 nmol/s per g) and from an unrelated normal individual (65.4 nmol/s per g) were mixed, the expected average activity (26.3 nmol/s per g) was observed. The activities of α -galactosidase A, β -galactosidase, α -fucosidase, α -neuraminidase, and aspartylglycosaminidase in fibroblast and/or lymphoblast extracts from the proband were normal or slightly elevated (data not shown). The α -N-acetylgalactosaminidase activity in plasma from three of the proband's four living sibs and in plasma and cultured cell extracts from the proband's two children were reduced to ~ 50% of normal mean values, consistent with the heterozygous expression of the autosomal recessive enzymatic deficiency (Table I).

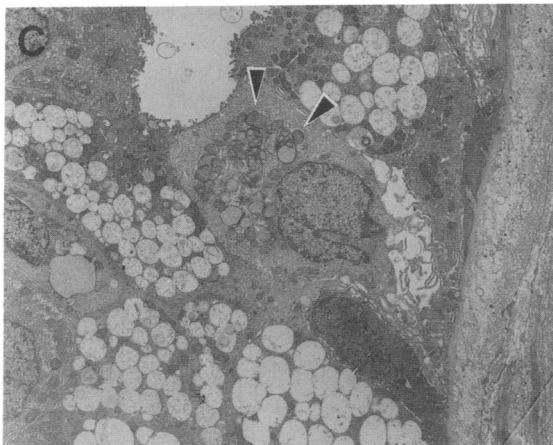
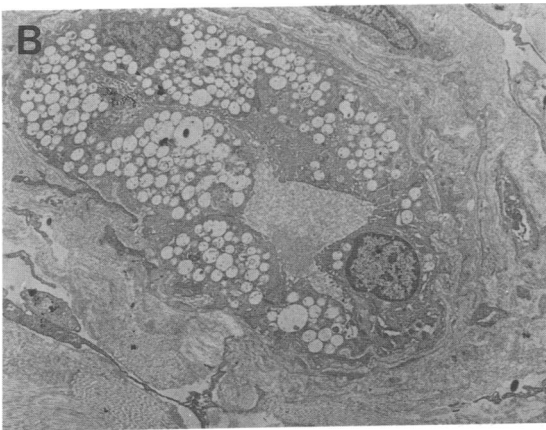
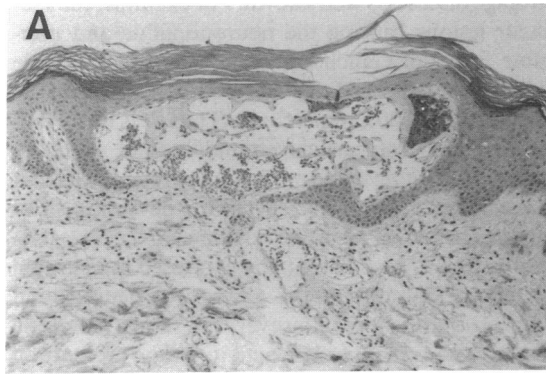


Figure 2. (A) Histopathology of a skin lesion showing hyperkeratosis of the epidermis and dilated capillaries in the upper dermis (hematoxylin-eosin; magnification, 20). (B) Vascular endothelial cell with numerous single-membrane lined vacuoles (arrow) in the cytoplasm (magnification, 3,500). (C) Secretory portion of sweat gland cells showing vacuoles in their cytoplasm, some containing amorphous as well as electron-dense lamelated structures (arrow) (magnification, 3,000).

To further characterize the nature of the enzymatic defect, immunoblot studies were performed with fibroblast extracts from family members and unrelated normal individuals as controls. Using monospecific rabbit anti-human α -N-acetylgalactosaminidase antibodies, two immunoreactive bands of 48 and 117 kD, consistent with the monomeric and dimeric forms of α -N-acetylgalactosaminidase (17), were detected in fibro-

Table I. α -N-Acetylgalactosaminidase Activity in Family Members

Source	Plasma	Lymphoblasts	Fibroblasts
	<i>nmol/s per liter or g protein*</i>		
Proband, affected homozygote	0.05 [†]	0.05	0.28
Brother 1, heterozygote	1.78	—	—
Brother 2, heterozygote	2.84	—	—
Sister 1, noncarrier	7.69	—	—
Sister 2, heterozygote	2.54	—	—
Husband, noncarrier	4.78	14.47	—
Son, heterozygote	3.33	8.97	43.3
Daughter, heterozygote	3.28	—	—
Normal mean \pm 1 SD	5.64 \pm 1.33	17.6 \pm 4.58	100 \pm 17.4
Range	4.00–8.33	10.5–27.2	66.9–126
<i>n</i>	23	13	12

* Assayed with 0.8 mM 4-methylumbelliferyl- α -N-acetylgalactosaminide. [†] Values for the family members represent the average of seven independent determinations.

blast extracts from an unrelated normal individual, and from the proband's heterozygous son (Fig. 3). In contrast, neither immunoreactive band was detected in fibroblast extracts from the proband. These findings indicated that the enzymatic defect in the proband was due to a mutation in the gene encoding α -N-acetylgalactosaminidase, which resulted in the absence of immunologically detectable enzyme protein.

Discussion

Previously, the finding of angiokeratoma corporis diffusum in a mentally normal adult woman suggested the possible diagnosis of Fabry disease (α -galactosidase A deficiency) because rare female carriers of this X-linked recessive disorder have been described with this cutaneous manifestation (2). However, the demonstration that the proband had normal α -galactosidase A activity as well as normal activities for the other lysosomal

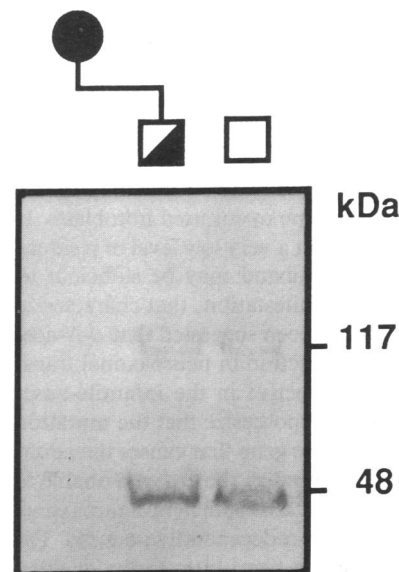


Figure 3. Immunoblot analysis of fibroblast extracts using anti- α -N-acetylgalactosaminidase antibodies. Fibroblast extracts from the proband (lane 1), the proband's heterozygous son (lane 2), and a normal individual (lane 3). See text for details.

enzymes whose deficiencies are characterized by angiokeratoma corporis diffusum (1-7), led Kanzaki and colleagues to search for other metabolic explanations. The discovery that the proband had sialoglycopeptiduria provided the initial clue, but the activities of the relevant glycosidases including α -neuraminidase were normal (9). Thus, the nature of the underlying metabolic defect in this new form of angiokeratoma remained obscure.

Insight into the etiology of the sialoglycopeptiduria was provided by the almost simultaneous report of a new form of infantile neuroaxonal dystrophy due to lysosomal α -*N*-acetylgalactosaminidase deficiency (10). These infants excreted sialoglycopeptides which suggested to one of us (Dr. Desnick) the possibility that the proband's sialoglycopeptiduria also may be due to the deficient activity of this enzyme which normally hydrolyzes the *O*-glycosidic linkage in glycopeptides. In support of this hypothesis was the finding that the urinary glycopeptides from the proband and from the affected brothers with α -*N*-acetylgalactosaminidase deficiency had the same or similar structures (9, 12, 13). The demonstration of deficient α -*N*-acetylgalactosaminidase activity in the proband confirmed the hypothesis. Mixing experiments ruled out the presence of inhibitors as well as the lack of specific activators as the cause of the enzymatic defect. Both of the proband's children had intermediate levels of enzymatic activity consistent with the autosomal transmission of the recessive allele. In addition, immunologic studies revealed the absence of cross-reacting immunologic enzyme protein (Fig. 3). Finally, ultrastructural studies revealed the presence of lysosomes containing undegraded amorphous and filamentous material, consistent with the storage of glycopeptides and oligosaccharides. Thus, the combined biochemical, immunologic, and ultrastructural studies demonstrated that the deficient activity of α -*N*-acetylgalactosaminidase is the primary enzymatic defect causing the lysosomal accumulation of *O*-linked glycopeptides and the resultant angiokeratoma corporis diffusum in the proband.

It is notable that the deficiency of α -*N*-acetylgalactosaminidase activity can result in the two markedly distinct phenotypes observed in the sibs with infantile-onset neuroaxonal dystrophy and the proband with adult-onset angiokeratoma corporis diffusum. Both types of α -*N*-acetylgalactosaminidase deficiency are characterized biochemically by the excretion of the same sialoglycopeptides and the absence of immunologically cross-reacting enzyme protein in cultured fibroblasts. The absence of detectable neurologic involvement in the adult-onset form suggests that sufficient residual activity or function is present in neural cells to prevent the neuroaxonal pathology observed in the infantile-onset patients. The fact that the mutant enzyme protein is not immunologically detectable may reflect the relative instability of the enzyme in cultured fibroblasts. It is conceivable, but speculative, that a very low level of residual activity in the neurons of the proband may be sufficient to prevent the severe neurologic manifestations that characterize the infantile-onset disease. It has been suggested that α -*N*-acetylgalactosaminidase also may function in neuroaxonal transport and that this domain is defective in the infantile-onset patients (11), whereas one may hypothesize that the mutation in the α -*N*-acetylgalactosaminidase gene that causes the adult-onset form with angiokeratoma renders the enzyme unable to hydrolyze *O*-glycopeptides, but retains sufficient neuroaxonal function to prevent the early neurodegenerative course. The occurrence of neurologic and non-neurologic forms of other

lysosomal storage diseases is well known. For example, the specific molecular lesions causing the neuronopathic and non-neuronopathic forms of Gaucher and Niemann-Pick disease have been identified in the acid β -glucosidase gene (19) and the sphingomyelinase gene (20), respectively. Thus, it is likely that a mutation in the α -*N*-acetylgalactosaminidase gene, which results in an altered, albeit unstable protein, may retain sufficient enzymatic activity or function to prevent the development of neurologic manifestations. Alternatively, the α -*N*-acetylgalactosaminidase gene may be differentially expressed in neuronal tissues, which might account for the absence of neuroaxonal pathology in the adult patient. However, determination of the neural α -*N*-acetylgalactosaminidase activity or the presence of neuronal pathology from the proband would require a neural biopsy that could not be justified.

Recently, the molecular nature of the lesion causing the infantile form of α -*N*-acetylgalactosaminidase has been shown to be a missense mutation in codon 325 of exon 8 of the α -*N*-acetylgalactosaminidase gene that alters a glutamic acid to a lysine residue (21, 22). Notably, transient expression of the mutant enzyme in COS-1 cells resulted in the production of an immunologically detectable enzyme protein evidencing the fact that the enzyme was synthesized, but was markedly unstable (21). Future identification of the molecular lesion causing α -*N*-acetylgalactosaminidase deficiency in the proband with angiokeratoma and expression of the mutant protein may provide insight into the biochemical nature of the enzymatic defect. Whatever the precise molecular lesion, it is clear that the adult-onset of angiokeratoma due to α -*N*-acetylgalactosaminidase and the absence of detectable angiokeratoma in the infants with neuroaxonal dystrophy are caused by allelic mutations that differentially alter the enzyme protein. Understanding of the pathogenesis of this new form of angiokeratoma will provide further information about the function of this lysosomal enzyme. However, an unresolved question is whether the proband has neuropathology which may become manifest later in adult life. Analogously, will the sibs with infantile-onset neuroaxonal dystrophy develop angiokeratoma in the future? Clearly, α -*N*-acetylgalactosaminidase deficiency should be considered in the differential diagnosis of angiokeratoma corporis diffusum. The enzyme deficiency can be readily detected in plasma, isolated leukocytes, or cultured fibroblasts as well as by the analysis of urinary glycopeptides and oligosaccharides (11, 13).

Acknowledgments

This work was supported in part by a research grant (5 R01 DK-34045) from the National Institutes of Health, a grant (RR-00071) for the General Clinical Research Center from the National Center for Research Resources, National Institutes of Health, a grant (1-578) from the March of Dimes Birth Defects Foundation, and a grant (02454279) from the Ministry of Education, Japan. Dr. Wang was the recipient of a predoctoral fellowship (5 T32 HD-07105) from the National Institutes of Health.

References

1. From, L., and D. Assaad. 1987. Vascular neoplasms, pseudoneoplasms, and hyperplasias. *In* Dermatology in General Medicine. T. B. Fitzpatrick, A. Z. Eisen, K. Wolff, I. M. Freedberg, and K. F. Austen, editors. McGraw Hill, Inc., New York. 1059-1077.
2. Desnick, R. J., and D. F. Bishop. 1989. Fabry disease: α -Galactosidase

- deficiency. In *The Metabolic Basis of Inherited Disease*. 6th ed. C. R. Scriver, A. L. Beaudet, W. S. Sly, and D. Valle, editors. McGraw-Hill, Inc., New York. 1751-1780.
3. Gehler, J., A. C. Sewell, C. Becker, J. Hartmann, and J. Spranger. 1981. Clinical and biochemical delineation of aspartylglycosaminuria as observed in two members of an Italian family. *Helv. Paediatr. Acta.* 36:179-189.
 4. Epinnette, W. W., A. L. Norins, A. L. Drew, W. Zeman, and V. Patel. 1973. Angiokeratoma corporis diffusum with α -L-fucosidase deficiency. *Arch. Dermatol.* 107:755-757.
 5. Wenger, D. A., M. Sattler, O. T. Mueller, G. G. Myers, R. S. Schneider, and G. W. Nixon. 1980. Adult G_{M1} gangliosidosis: clinical and biochemical studies on two patients and comparison to other patients called variant or adult G_{M1} gangliosidosis. *Clin. Genet.* 17:323-334.
 6. Miyatake, T., T. Atsumi, T. Obayashi, Y. Mizuno, S. Ando, T. Ariga, K. Matsui-Nakamura, and T. Yamada. 1978. Adult type neuronal storage disease with neuraminidase deficiency. *Ann. Neurol.* 6:232-244.
 7. Wenger, D. A., E. Sujansky, P. V. Fennessey, and J. N. Thompson. 1986. Human β -mannosidase deficiency. *N. Engl. J. Med.* 315:1201-1202.
 8. Kanzaki, T., M. Yokota, N. Mizuno, Y. Matsumoto, and Y. Hirabayashi. 1989. Novel lysosomal glycoaminoacid storage disease with angiokeratoma corporis diffusum. *Lancet.* i:875-877.
 9. Hirabayashi, Y., Y. Matsumoto, M. Matsumoto, T. Toida, N. Iida, T. Matsubara, T. Kanzaki, M. Yokota, and I. Ishizuka. 1990. Isolation and characterization of major urinary amino acid *O*-glycosides and a dipeptide *O*-glycoside from a new lysosomal storage disorder (Kanzaki disease). *J. Biol. Chem.* 265:1693-1701.
 10. van Diggelen, O. P., D. Schindler, R. Willemsen, M. Boer, W. J. Kleijer, J. G. M. Huijmans, W. Blom, and H. Galjaard. 1988. α -*N*-acetylgalactosaminidase deficiency, a new lysosomal storage disorder. *J. Inherited Metab. Dis.* 11:349-357.
 11. Schindler, D., D. F. Bishop, D. E. Wolfe, A. M. Wang, H. Egge, R. U. Lemieux, and R. J. Desnick. 1989. Neuroaxonal dystrophy due to lysosomal α -*N*-acetylgalactosaminidase deficiency. *N. Engl. J. Med.* 320:1735-1740.
 12. Linden, H.-U., R. A. Klein, H. Egge, J. Peter-Katalinic, J. Dabrowski, and D. Schindler. 1989. Isolation and structural characterization of sialic acid-containing glycopeptides of the *O*-glycosidic type from the urine of two patients with an hereditary deficiency in α -*N*-acetylgalactosaminidase activity. *Biol. Chem. Hoppe-Seyler.* 370:661-672.
 13. Schindler, D., T. Kanzaki, and R. J. Desnick. 1990. A method for the rapid detection of urinary glycopeptides in α -*N*-acetylgalactosaminidase deficiency and other lysosomal storage diseases. *Clin. Chim. Acta.* 190:81-92.
 14. Szweda, R., U. Spohr, R. U. Lemieux, D. Schindler, D. F. Bishop, and R. J. Desnick. 1989. Synthesis of 4-methylumbelliferyl glycosides for the detection of α - and β -D-galactopyranosaminidases. *Can. J. Chem.* 67:1388-1391.
 15. Bohlen, P., S. Stein, W. Dairman, and S. Udenfriend. 1973. Fluorometric assay of proteins in the nanogram range. *Arch. Biochem. Biophys.* 155:213-220.
 16. Bishop, D. F., and R. J. Desnick. 1981. Affinity purification of α -galactosidase A from human spleen, placenta, and plasma with elimination of pyrogen contamination. *J. Biol. Chem.* 256:1307-1316.
 17. Wang, A. M., D. F. Bishop, and R. J. Desnick. 1990. Human α -*N*-acetylgalactosaminidase: molecular cloning, nucleotide sequence, and expression of a full-length cDNA. *J. Biol. Chem.* 265:21859-21866.
 18. Fabbro, D., R. J. Desnick, and G. A. Grabowski. 1987. Gaucher disease: genetic heterogeneity within and among the subtypes detected by immunoblotting. *Am. J. Hum. Genet.* 40:15-31.
 19. Latham, T., G. A. Grabowski, B. D. M. Theophilus, and F. I. Smith. 1990. Complex alleles of the acid β -glucosidase gene in Gaucher disease. *Am. J. Hum. Genet.* 47:79-86.
 20. Levran, O., R. J. Desnick, and E. H. Schuchman. 1991. Niemann-Pick disease: a frequent missense mutation in the acid sphingomyelinase gene in patients with Ashkenazi Jewish ancestry with Types A and B Niemann-Pick disease. *Proc. Natl. Acad. Sci. USA.* 88:3748-3752.
 21. Wang, A. M., D. Schindler, and R. J. Desnick. 1990. Schindler disease. The molecular lesion in the α -*N*-acetylgalactosaminidase gene that causes an infantile neuroaxonal dystrophy. *J. Clin. Invest.* 86:1752-1756.
 22. Wang, A. M., and R. J. Desnick. 1991. Structural organization and complete sequence of the human α -*N*-acetylgalactosaminidase gene: homology with the α -Galactosidase A gene provides evidence for evolution from a common ancestral gene. *Genomics* 10:133-142.