

Role of Organic Osmolytes in Myelinolysis

A Topographic Study in Rats after Rapid Correction of Hyponatremia

Yeong-Hau H. Lien

Department of Medicine, University of Arizona Health Sciences Center, Tucson, Arizona 85724

Abstract

Organic osmolytes have been implicated in the pathogenesis of myelinolysis because some of them are accumulated slowly during correction of chronic hyponatremia. I investigated whether there was a topographic correlation between demyelination lesions and the regional changes of organic osmolytes after rapid correction of chronic hyponatremia. In normal female Sprague-Dawley rats, concentrations of glutamate, glutamine, taurine, and betaine were highest in the cerebral cortex and decreased toward the brain stem. Conversely, glycine level was highest in the brainstem, and decreased toward the cortex. Myoinositol, glycerophosphorylcholine, glycerophosphorylethanolamine, and creatine were distributed more evenly. In chronic hyponatremic rats (plasma Na 110 ± 4 meq/liter), organic osmolytes decreased globally with the total loss ranging from 13 (medulla) to 24 (cerebellum) mmol/kg H₂O. After rapid correction with intraperitoneal injection of hypertonic saline, the recovery of the loss of organic osmolytes was 48% in the cerebral cortex, cerebellum, and medulla oblongata, 44% in pons, but only 17% in midbrain and 36% in striatum. Histopathology of the brain was examined in nine rats 2–7 d after correction of hyponatremia. Large demyelination lesions were seen persistently in the midbrain and striatum, and smaller lesions in cerebrum, cerebellum, and pons were found less frequently. This is the first report of regional distribution of brain organic osmolytes. After rapid correction of chronic hyponatremia, a topographic correlation between demyelination lesions and delayed accumulation of organic osmolytes exists. (*J. Clin. Invest.* 1995; 95:1579–1586.) Key words: central pontine myelinolysis • idiogenic osmoles • osmolality • brain • HPLC

Portions of this manuscript were presented at the 24th meeting of the American Society of Nephrology in Baltimore, MD, November 17–20, 1991 and have appeared in abstract form (1991. *J. Am. Soc. Nephrol.* 2:764a).

Address correspondence to Yeong-Hau H. Lien, Section of Renal Disease, Department of Medicine, University of Arizona Health Sciences Center, Tucson, AZ 85724. Phone: 602-626-0972; FAX: 602-626-2024.

Received for publication 26 July 1994 and in revised form 23 November 1994.

1. Abbreviations used in this paper: CPM, central pontine myelinolysis; GPC, glycerophosphorylcholine; GPE, glycerophosphorylethanolamine; NMR, nuclear magnetic resonance.

J. Clin. Invest.

© The American Society for Clinical Investigation, Inc.

0021-9738/95/04/1579/08 \$2.00

Volume 95, April 1995, 1579–1586

Introduction

More than 30 yr after the first description of central pontine myelinolysis (CPM)¹ by Adams et al. (1), the pathogenesis of this disease is still not fully understood. CPM is characterized by a loss of oligodendrocytes and myelin with relatively well-preserved neuronal cell bodies and axons in the central basis pontis. Wright et al. (2) later reported similar symmetric demyelination lesions in areas outside the pons, including the thalamus, internal capsule, lower levels of cerebral cortex, and cerebellum. These lesions are termed extrapontine myelinolysis. Initially, CPM was reported to be associated with alcoholism and malnutrition (1). Conger et al. (3) were the first to call attention to the possible importance of the relationship of a hypotonic state to CPM. Norenberg et al. (4) demonstrated that a sharp, marked, and sustained rise in serum sodium levels is associated with CPM. Sterns et al. (5) reported that neurological complications occur more frequently in hyponatremic patients with a higher correction rate of serum sodium. In experimental animals, including rats (6, 7), rabbits (8), and dogs (9), rapid correction of hyponatremia has been shown persistently resulting in demyelination lesions. However, not all investigators agree on the association of rapid correction of hyponatremia with CPM. In a large autopsy series of CPM, it was found that hyponatremic patients only accounted for a small fraction (10). It is clear that rapid correction of hyponatremia is not the sole cause of CPM. Other factors such as alcoholism, malnutrition, chronic liver diseases, malignancy, severe burns, and potassium depletion are also important (1, 11–13).

In this study, I investigated the role of organic osmolytes in the pathogenesis of myelinolysis in rats after rapid correction of hyponatremia. Organic osmolytes are important solutes which are accumulated in, or released from, cells during the adaptation process to the increase or decrease in surrounding osmolality. The major organic osmolytes in the brain are glutamate, glutamine, taurine, creatine/phosphocreatine, and myoinositol (14–17). We have previously shown that after rapid correction of chronic hyponatremia, the reaccumulation of brain organic osmolytes in rats is outpaced by the reaccumulation of brain Na and Cl, and speculated that the delayed increase of organic osmolytes may be relevant to the development of myelinolysis (18). CPM and extrapontine myelinolysis in humans are anatomical site-specific lesions as described earlier (1, 2). The topographic distribution of demyelination lesions induced by rapid correction of hyponatremia in rats was studied by Kleinschmidt-Demasters and Norenberg (6, 7). They demonstrated that after rapid correction of hyponatremia, the neurologically symptomatic rats have large and extensive lesions in the striatum and midbrain. Other regions involved are neocortex, hippocampus, anterior commissure, and cerebellum. It was noted that pons and medulla oblongata were spared. In this study, we performed regional analyses of brain organic osmo-

lytes in normal rats and rats with chronic hyponatremia before and after rapid correction of the hyponatremia. The biochemical studies were then correlated to the histopathological studies to determine whether a topographical relationship between the reaccumulation of organic osmolytes and demyelinating lesions after rapid correction of hyponatremia exists.

Methods

Animal models. Female Sprague-Dawley rats weighing 250–300 g were used. Hyponatremia was induced with the methods described by Verbalis and Drutarosky (19). Female rats were used because of the recent report that menstruating women with postoperative hyponatremic encephalopathy are about 25 times more likely to die or to have permanent brain damage compared with men or postmenopausal women (20). In brief, rats were treated with minipump (Alzet 2002; Alza Corp., Palo Alto, CA) infusion of 4 µg/ml DDAVP (1-desamino-8-D-arginine vasopressin; Rorer Pharmaceutical Corp. Fort Washington, PA) along with feeding of 30–35 ml liquid diet (AIN-76A; Dyets Inc., Bethlehem, PA) per day for 4 d. Control rats received the same diet without DDAVP infusion. Rapid correction of hyponatremia was accomplished by a single intraperitoneal injection of 5% saline 2.5 ml/100 g body wt. Daily weight and plasma Na, K, and osmolality were determined during the induction of hyponatremia and 24 h after rapid correction of hyponatremia. 15 rats, evenly divided into three groups: control, chronic hyponatremia, and rapid correction, were used for the biochemistry studied. For the neuropathological study, nine female hyponatremic rats were treated with 5% saline intraperitoneally to correct hyponatremia rapidly. Normal saline 30 ml was given subcutaneously for 3 d to avoid volume depletion as described by Kleinschmidt-Demasters and Norenberg (6). The rats were allowed to eat normal chow and drink tap water ad lib. the day after hypertonic saline injection. Minipumps were removed on the following day when the plasma osmolality reached the normal range. Plasma Na and osmolality were measured periodically after injection. Rats were euthanized 7 d after injection of hypertonic saline, or earlier if they developed severe neurological symptoms such as seizure, marked lethargy, or paralysis. In addition, six chronically hyponatremic rats without correction were used for examining whether hyponatremia per se would induce demyelinating lesions. The animal protocol was in accord with the ethical standards of the Animal Protocol Committee of the University of Arizona.

Brain dissection. For biochemistry studies, rat brain was rapidly removed from the skull after decapitation, and microdissected on an ice-cold platform into six regions: cerebral cortex, cerebellum, striatum, midbrain, pons, and medulla oblongata according to Ohno et al. (21). The brain sections were frozen with liquid nitrogen and stored at –70°C.

HPLC. Each brain section was weighed and extracted with perchloric acid, then neutralized, passed through a cartridge, and dried with a vacuum centrifuge. The samples were then redissolved in distilled water with a wet weight to volume ratio of 250 mg/ml. Sucrose, not found in the rat brain, was routinely added at a final concentration of 0.2 mM as an internal standard. HPLC was performed using a Sugar-Pak 1 column (Waters Associates, Milford, MA). An aliquot of 50 µl of brain extract was injected and eluted with 0.1 mM calcium disodium EDTA at 0.5 ml/min and 84°C. Metabolites were detected with a refractive index detector (Rainin Instrument Co., Woburn, MA) and analyzed as described previously (18).

Glutamate enzymatic assay. Glutamate, not retained by Sugar-Pak column, was measured by a calorimetric method with glutamate dehydrogenase and diaphorase (22).

Brain histology. The rat brain was dissected, fixed in 10% buffered formaldehyde, and processed routinely for light microscopy. Six paraffin sections from each rat, representing each brain compartment, were stained with hematoxylin-eosin and with Luxol-fast blue as described previously (6). A semiquantitative grading system was used to evaluate the severity of demyelinating lesions. Grade 1+: small localized lesions

Table I. Body Weight, Plasma Na, and Osmolarity

	Rat group (n)		
	Control (5)	Hyponatremia (5)	Rapid correction (5)
Body weight (g)	255±8	251±7	227±18**
Plasma Na (meq/liter)	140±2	107±4*	139±3‡
Plasma osmolality (mosmol/kg)	297±6	232±6*	293±9‡

Values are mean±SD. * $P < 0.01$ vs control rats. ‡ $P < 0.01$ vs hyponatremic rats.

with demyelination, loss of oligodendrocytes, gliosis, and vacuolation. Grade 2+: multiple lesions with similar histological pictures as Grade 1+. Grade 3+: large extensive demyelinating lesions with neuronal necrosis. It is well known that neurons are usually preserved except in the severely demyelinating lesions (6).

Statistics. One way ANOVA was performed to demonstrate differences among group means. Comparison of group means with the control was done using Student's *t* test for unpaired data employing Scheffe's method to correct for multiple comparisons (23). Mann-Whitney non-parametric test was performed to compare the histological grades of demyelinating lesions in brain sections. Significance levels are reported at the $P < 0.05$ and $P < 0.01$ levels.

Results

Physiologic measurements. All rats survived the induction of hyponatremia without significant symptoms. Table I summarizes the body weight, plasma Na levels, and osmolality in control, hyponatremic rats before and after rapid correction. Treatment with DDAVP and liquid diet did not change body weight, but reduced plasma Na, and osmolality significantly comparing to control rats. After rapid correction with intraperitoneal hypertonic saline infusion, serum Na and osmolality were within normal range at 24 h. However, those rats had significant weight loss. Table II reports the brain water content in each brain section of the three groups of rats. Within each group of rats, the water content was always lower in pons and medulla oblongata than other sections ($P < 0.01$). The water content in each brain section was slightly higher in hyponatremic rats when compared with controls, but the differences were not statistically significant ($P > 0.05$). After hypertonic saline infusion, the water content decreased globally when compared with hyponatremic rats. Only in the midbrain and medulla oblongata, was the water content in the rapid correction group significantly lower than the control.

Brain organic osmolytes. Fig. 1 shows the representative HPLC chromatograms of extracts from cerebral cortex (Fig. 1 a) and medulla oblongata (Fig. 1 b) of a normal rat. The peaks of taurine, betaine, and glutamine are higher in the cerebral cortex than medulla oblongata. The peak with a retention time of 24 min is markedly higher in medulla. This peak was identified as glycine using ¹H-nuclear magnetic resonance (NMR) spectroscopy (chemical shift 3.52 and 3.63 ppm in EDTA solution referenced with 3-trimethylsilylpropionate, Lien, Y.-H. H., unpublished data). Another peak with a retention time of 13.4 min was identified as glycerophosphorylethanolamine (GPE). The peak intensities of myoinositol, glycerophosphoryl-

Table II. Brain Water Content

	Cerebrum	Cerebellum	Striatum	Midbrain	Pons	Medulla oblongata
	%					
Control (5)	80.0±0.3	78.4±0.4	77.9±0.3	77.8±0.2	73.7±0.2	75.0±0.1
Hyponatremia (5)	80.5±0.2	78.9±0.5	78.2±0.3	78.3±0.3	74.0±0.2	75.4±0.2
Rapid correction (5)	79.0±0.3*	78.0±0.3*	77.2±0.4*	76.7±0.4*†	73.0±0.3*	74.0±0.4*†

Numbers in parentheses are numbers of rats in each group. * $P < 0.01$ vs hyponatremia, and † $P < 0.01$ vs control.

choline (GPC), GPE, and creatine are comparable between extracts from the cerebral cortex and medulla oblongata.

Table III shows the means and SD of the concentrations of individual organic osmolyte and urea in each brain section of control rats measured by the HPLC and glutamate enzymatic assay. Glutamate, glutamine, taurine, and betaine content was highest in the cerebral cortex and cerebellum, and lowest in pons and medulla oblongata, the differences being two- to threefold. Conversely, glycine level was highest in the pons and medulla, and lowest in cortex and cerebellum, with a fourfold difference. Other organic osmolytes including myoinositol, GPC, GPE, and creatine, appeared to be distributed evenly.

With chronic hyponatremia, all of organic osmolytes decreased in each brain section (Table IV). The total concentration of organic osmolytes and urea decreased to 45–55% of baseline level in brain sections. The decrease of organic osmolytes ranged from 13 (medulla oblongata) to 24 mmol/kg H₂O, which accounted for 40–73% of the changes of the brain osmolality. Individually, most organic osmolytes decreased 50% or more with hyponatremia. Glutamate is the only osmolyte that had < 50% reduction in all sections.

Table V shows the concentrations of organic osmolytes after rapid correction of hyponatremia. The concentrations of glutamate, GPC, GPE, betaine, and glycine returned to the control level in 24 h, except that GPC levels overshoot to 33 and 40%, respectively, of that in the cerebrum and cerebellum. Conversely, there was little or no increase of myoinositol, taurine,

and creatine. Glutamine was partially recovered. The total concentration of organic osmolytes and urea increased to 81, 74, 75, 63, 73, and 82%, respectively, of the normal level in cerebral cortex, cerebellum, striatum, midbrain, pons, and medulla oblongata. The increase of total organic osmolytes including urea was smallest in the midbrain (4.8 mmol/kg H₂O) and followed by striatum (7.4) and medulla oblongata (8.0). Since the baseline osmolyte contents varied among brain sections, the hypertonic saline-induced osmolyte increase was calculated as percentage of the change between the control and hyponatremic values, or the percentage of recovery of the loss of organic osmolytes due to hyponatremia. The recovery was the smallest in the midbrain (27%), followed by striatum (46%), pons (51%), cerebellum (52%), cerebrum (58%), and medulla (61%) ($P < 0.01$, midbrain vs others; $P < 0.05$ striatum vs cerebrum or medulla). Because the brain water content was changed significantly after rapid correction of hyponatremia (Table II), the recovery of organic osmolytes was also calculated in the unit of millimoles per kilograms dry weight. It was noted that the increase of organic osmolytes after rapid correction of hyponatremia was 35, 41, 21, 10, 24, and 21 mmol/kg dry wt, respectively, in the cerebrum, cerebellum, striatum, midbrain, pons, and medulla oblongata. The recovery of organic osmolytes was 17% in the midbrain, and 36% in striatum, 44% in pons, and 48% in cerebrum, cerebellum, and medulla ($P < 0.01$ midbrain vs others; $P < 0.05$ striatum vs cerebrum, cerebellum, or medulla).

Clinical observations after rapid correction of hyponatremia. Fig. 2 shows the time course of the changes in body weight and plasma osmolality of the nine rats that underwent rapid correction of hyponatremia. There was no significant change in body weight after induction of hyponatremia. After injection of hypertonic saline, in spite of subcutaneous injection of normal saline, there was a significant weight loss. At the end of experiment, i.e., 7 d after correction of hyponatremia, the mean weight loss of the five surviving rats was 65 g or 25% of pretreatment weight. Three rats were killed 48 h after correction of hyponatremia because of seizure in two, and coma in one. Another rat was killed on day 4 because of paralysis of extremities. As for plasma osmolality, before induction of hyponatremia, it was 299 ± 3 mosmol/kg H₂O and dropped to 228 ± 7 ($P < 0.01$) after 4 d of DDAVP infusion along with liquid diet. After hypertonic saline injection, plasma osmolality increased to 294 ± 9 mosmol/kg H₂O in 24 h ($P < 0.01$ vs hyponatremic rats, and $P = NS$ vs control rats). At the seventh day, the mean plasma osmolality was 300 mosmol/kg. The changes in plasma Na levels paralleled those in plasma osmolality.

Brain histology. Brain histology was examined in six hypo-

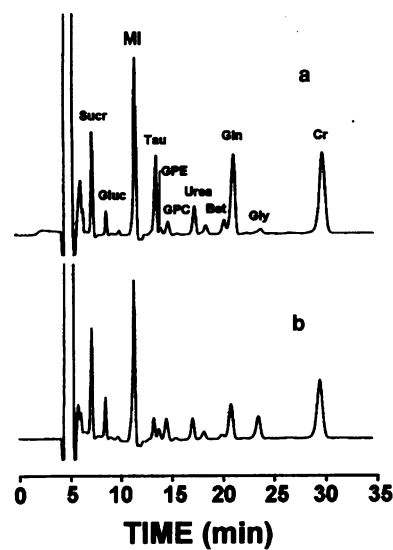


Figure 1. HPLC chromatograms of brain extracts from control rats. (a) Cerebral cortex; (b) medulla oblongata. Peaks from sucrose (Sucr, 2 mM, as internal standard), glucose (Gluc), myoinositol (MI), taurine (Tau), GPE, GPC, urea, betaine (Bet), glutamine (Gln), glycine (Gly), and creatine (Cr) are labeled.

Table III. Regional Distribution of Brain Organic Osmolytes in Control Rats

	Cerebrum	Cerebellum	Striatum	Midbrain	Pons	Medulla oblongata
<i>mmol/kg H₂O</i>						
Glutamate	11.7±0.1	11.6±0.1	9.2±0.4	7.8±0.7	6.0±0.45	5.7±0.6
Glutamine	4.6±0.4	4.8±0.2	3.9±0.3	4.2±0.8	2.8±0.3	2.5±0.2
Taurine	4.3±0.2	4.4±0.3	2.7±0.3	3.2±0.9	2.0±0.5	1.3±0.2
Glycine	0.7±0.2	0.5±0.2	0.9±0.4	0.9±0.1	2.7±0.4	2.8±0.4
Myoinositol	5.9±0.5	6.2±0.3	6.5±0.8	6.5±0.7	7.7±0.9	6.2±0.7
Creatine	7.1±0.5	10.2±0.4	6.7±0.9	7.1±0.6	7.5±0.8	5.7±0.6
Betaine	1.7±0.2	1.4±0.4	1.0±0.2	1.1±0.4	0.7±0.1	0.6±0.1
GPC	0.6±0.07	1.0±0.1	1.2±0.09	1.1±0.2	1.3±0.1	1.0±0.1
GPE	0.6±0.09	0.6±0.2	0.7±0.09	0.8±0.3	1.0±0.1	0.8±0.1
Urea	3.4±0.2	3.4±0.3	3.1±0.2	3.1±0.1	3.3±0.08	2.6±0.08
Total	40.6±1.2	44.0±1.3	36.0±2.4	35.7±3.1	34.9±2.8	29.2±2.9

natremic rats without correction and nine rats receiving rapid correction of hyponatremia. There was no demyelination observed in all six hyponatremic rats. The most striking findings in those underwent rapid correction of hyponatremia were in the midbrain as shown in Fig. 3 a (Luxol-fast blue stain). There were large symmetrical demyelinating lesions in the red nuclei, similar to the hyponatremia-related demyelinating lesions reported by Kleinschmidt-Demasters and Norenberg (6). Fig. 3 b shows smaller lesions in the lateral aspect of pons which have not been reported previously. The location of these pontine lesions were different from those in human CPM lesions which are usually triangular in shape and located at central pontine regions. The pontine lesions reported in our study appeared to be the extension of midbrain lesions. Demyelinating lesions were also found in the striatum, cerebrum cortex, and cerebellum, but not in the medulla oblongata. At higher magnification, pronounced vacuole formation and microglial infiltration were observed in the midbrain lesion (Fig. 4). Oligodendrocytes were markedly reduced and some degenerated neuron cell bod-

ies were seen at the edge of the severely demyelinated lesion. These microscopic findings were consistent with the previously reported findings of CPM in patients (1, 2) and extrapontine myelinolysis in experimental animals (6, 7), and were graded as 3+ according to the semiquantitative grading system described earlier.

Table VI summarizes the histological findings in each brain section of the nine rats treated with hypertonic saline. All nine rats had demyelinating lesions in midbrain and striatum with grades 2+ to 3+. Smaller pontine lesions were found in five rats (1+ to 2+). Two rats had scattered lesions in cerebral cortex and three had cerebellar lesions (1+ to 2+). No lesions in medulla oblongata were found. The severity of demyelinating lesions in the striatum and midbrain was significantly greater than that in the cerebrum, cerebellum, and pons ($P < 0.01$).

Discussion

In this study, I measured the regional concentrations of brain organic osmolytes in normal rats, rats with chronic hypona-

Table IV. Regional Distribution of Brain Organic Osmolytes in Hyponatremic Rats

	Cerebrum	Cerebellum	Striatum	Midbrain	Pons	Medulla oblongata
<i>mmol/kg H₂O</i>						
Glutamate	8.6±0.3*	7.7±0.4*	7.3±0.3*	5.2±0.4*	3.3±0.7*	3.5±0.3*
Glutamine	2.0±0.5*	1.7±0.6*	2.1±0.6*	1.8±0.6*	1.2±0.5*	1.3±0.5*
Taurine	1.4±0.2*	0.9±0.4*	1.4±0.6*	1.1±0.6*	0.7±0.1*	0.7±0.1*
Glycine	0.4±0.06 [‡]	0.3±0.06 [‡]	0.4±0.04 [‡]	0.7±0.06	1.4±0.5*	1.6±0.3*
Myoinositol	2.2±0.7*	2.5±1.1*	2.1±0.7*	2.8±0.9*	3.3±0.6*	3.1±1.1*
Creatine	3.7±0.9*	4.0±1.6*	3.4±1.1*	3.5±0.8*	3.4±0.6*	3.1±0.9*
Betaine	0.9±0.2*	0.4±0.05*	0.7±0.1	0.5±0.1 [‡]	0.4±0.05 [‡]	0.4±0.04
GPC	0.2±0.03*	0.3±0.1*	0.3±0.08*	0.3±0.09*	0.3±0.1*	0.3±0.1*
GPE	0.2±0.04*	0.3±0.08 [‡]	0.3±0.07*	0.4±0.1*	0.5±0.08*	0.5±0.1*
Urea	1.9±0.4*	1.7±0.7*	1.7±0.5*	1.7±0.4*	1.5±0.5*	1.5±0.5*
Total	21.4±3.1*	19.8±3.7*	19.8±3.9*	17.9±3.6*	15.8±3.9*	16.0±3.7*
Percentage of control	53	45	55	50	45	55

* $P < 0.01$, [‡] $P < 0.05$ vs control.

Table V. Regional Distribution of Brain Organic Osmolytes in Hyponatremic Rats after Rapid Correction

	Cerebrum	Cerebellum	Striatum	Midbrain	Pons	Medulla oblongata
	<i>mmol/kg H₂O</i>					
Glutamate	12.1±0.3*	12.0±0.9*	9.2±0.7*	7.4±0.2*	5.6±0.8*	5.4±0.8*
Glutamine	3.6±0.5*†	3.4±0.5*†	2.9±0.8‡	2.0±0.6‡	1.9±0.3‡	1.9±0.2‡
Taurine	2.2±0.7*†	1.7±0.3*†	1.6±0.6‡	0.9±0.2‡	1.3±0.5‡	1.0±0.4
Glycine	0.7±0.2	0.5±0.06	0.8±0.1*	1.0±0.3	2.5±0.2*	2.6±0.2*
Myoinositol	2.9±0.6‡	2.5±0.7‡	2.8±0.7‡	2.7±0.8‡	4.1±0.6‡	4.0±0.6‡
Creatine	4.6±0.6‡	6.3±1.0‡	4.2±1.1‡	3.5±1.0‡	4.4±0.8‡	4.0±0.5‡
Betaine	1.7±0.1*	0.9±0.1*	1.1±0.3	0.8±0.3	0.6±0.1	0.5±0.08
GPC	0.8±0.09‡*	1.4±0.2‡*	1.0±0.2*	1.0±0.06*	1.3±0.2*	1.3±0.2*
GPE	0.4±0.2	0.4±0.2	0.4±0.09‡	0.5±0.1	0.8±0.3	0.8±0.2*
Urea	3.8±0.5*	3.3±0.3*	3.2±0.6*	2.7±0.3*	2.9±0.4*	2.6±0.3*
Total	32.7±2.8*†	32.4±3.2*†	27.2±4.8*†	22.7±2.3*†	25.5±2.2*†	24.0±1.6*†
Increase (%) [†]	11.3 (58)	12.6 (52)	7.4 (46)	4.8 (27)	9.7 (51)	8.0 (61)

* $P < 0.01$, † $P < 0.01$, ‡ $P < 0.05$ vs control. ^{||} $P < 0.05$ vs hyponatremia. [†] Percentage of the change between the control and the hyponatremic values.

tremia, and rats undergoing rapid correction of hyponatremia. I found that the regions, where the recovery of organic osmolytes was the slowest after rapid correction of hyponatremia, i.e., the midbrain and striatum, were those where demyelination lesions were observed most consistently and extensively.

Nine organic osmolytes were measured in this study. All but GPE have been reported functioning as organic osmolytes in the brain previously (14–17). GPE, is synthesized from phosphatidylethanolamine by phospholipase and lysophospholipase, and is hydrolyzed to form phosphorylethanolamine (24). The metabolic pathways of GPE are similar to those of GPC. It has been demonstrated that GPE, similar to GPC, is upregulated by hypertonicity and downregulated by hypotonicity in living C6 glioma cells cultured in bioreactors using ³¹P NMR spectroscopy (25, 26). In the present study, the changes of GPE levels in hyponatremic rats were similar to those in GPC, but unlike GPC, after rapid correction of hyponatremia, there was no overshoot in the level of GPE in all brain sections. Thus, the osmoregulatory mechanisms in the central nervous system may be slightly different between these two molecules.

The distribution of these nine organic osmolytes in the rat brain varies. With the exception of glycine, amino acids and their derivatives are highest in the cerebrum and cerebellum,

and decrease toward the brainstem. Glycine content, however, is higher in the brainstem than other sections. The distribution of myoinositol, creatine, GPC, and GPE is relatively even among the brain sections. The content and distribution of glutamate, glutamine, taurine, and glycine reported in the present study are consistent with those reported previously by Erecinska et al. (27) and Dawson et al. (28). The high concentration of glycine in the brainstem is well-known and its concentration in the spinal cord is even higher (2–5 $\mu\text{mol/g}$ wet wt in the lumbar gray matter) and is exceeded only by that of glutamate (29). The concentrations of glycine in the brainstem decrease significantly with hyponatremia and increase after rapid correction of the hyponatremia, thus, they play a major role on the osmoregulation in the brainstem. Conceivably, it has a similar role in the spinal cord.

The total concentration of organic osmolytes plus urea was highest in the cerebellum (44 mmol/kg H₂O) and cerebrum (41 mmol/kg H₂O), and lowest in medulla oblongata (29 mmol/kg H₂O). Previously, Reulen et al. (30) reported that the electrolyte concentrations in the three regions were: cerebellum: Na, 60, K, 131, Cl 47, total 238; cerebrum: Na, 64, K 128, Cl 56, total 248; and medulla oblongata: Na 71, K, 126, Cl, 61, total 258 (all expressed in mmol/kg H₂O). Thus, the difference in organic osmolytes appears to be made up by the difference in electrolytes. It is likely that these differences among brain regions are due to the difference in the intracellular space.

During rapid correction of chronic hyponatremia, the change of individual osmolyte concentration follows its own pattern in each brain section. Myoinositol, taurine, and creatine are nearly unchanged after rapid correction of hyponatremia, while glutamate, betaine, GPC, GPE, and glycine are almost fully recovered at 24 h. Glutamine level increases in most of brain sections, but is significantly lower than the control value. The recovery of these osmolytes after rapid correction was consistent with the results of our previous study of whole brain analysis. One exception is that previously we reported that glutamate was not normalized after hypertonic saline infusion (18). This difference is likely due to different methods used for glutamate analy-

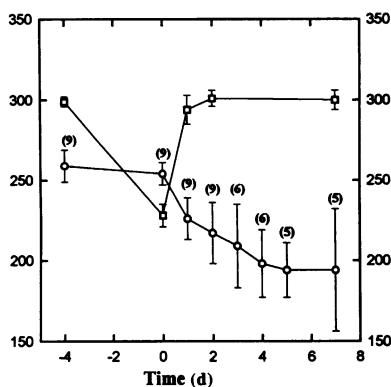
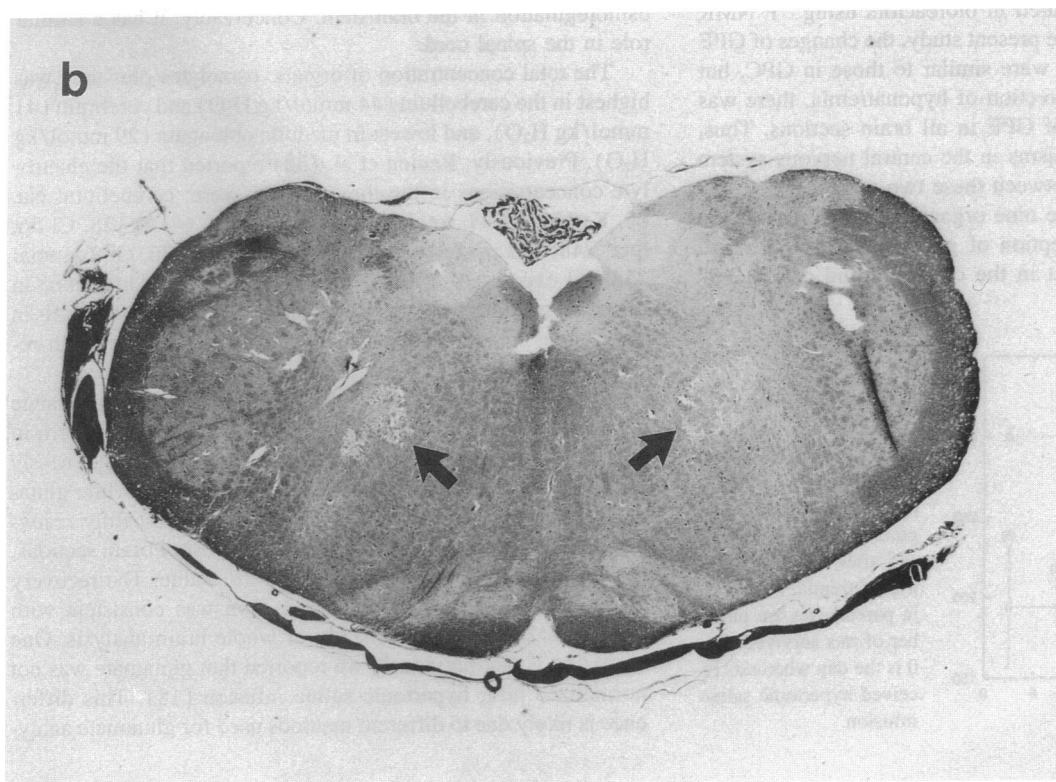
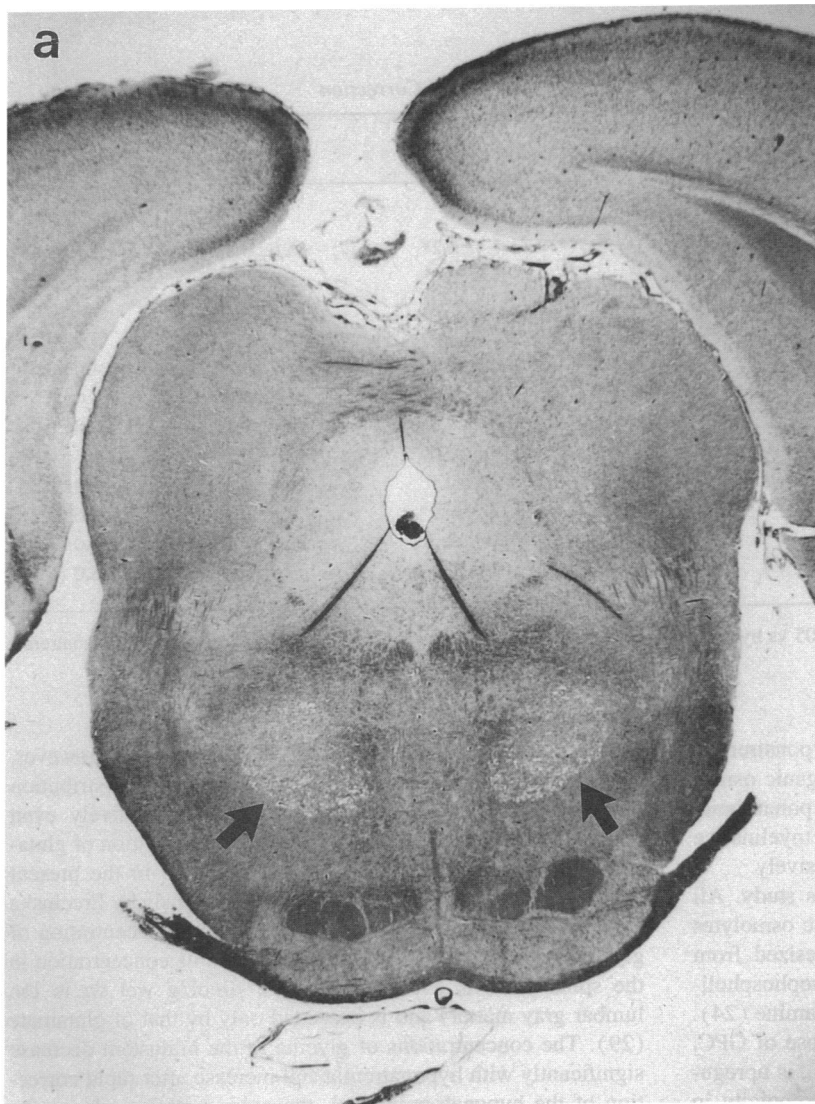


Figure 2. Time course of the changes in body weight (grams) (circles) and plasma osmolality (milliosmol per kilogram) (squares) before and after correction of hyponatremia. Numbers in parentheses are number of rats survived. Day 0 is the day when rats received hypertonic saline infusion.



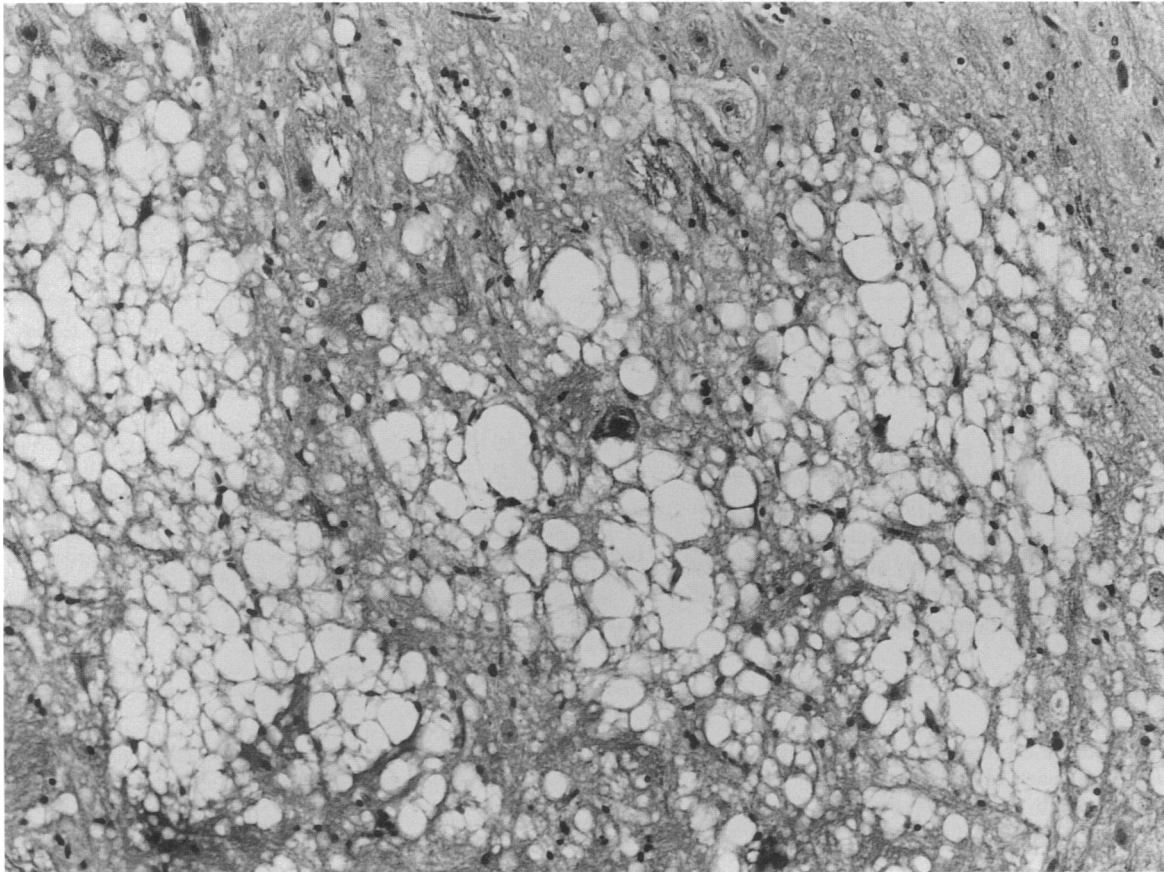


Figure 4. Micrograph of the midbrain lesion shows pronounced vacuole formation and microglial infiltration. Oligodendrocytes are markedly reduced. Some degenerated neuronal cell bodies are seen. Hematoxylin and eosin stain, $\times 175$.

sis: previously ^1H NMR spectroscopy was used, which may underestimate glutamate level because of overlapping with glutamine. In the present study, an enzymatic method specific for glutamate is used to avoid the technical errors. When calculated as a whole (either calculated as millimole per kilogram H_2O , or per kilogram dry weight), the recovery of organic osmolytes due to infusion of hypertonic saline was the smallest in the midbrain, followed by striatum. The complexity of the organic osmolyte system makes it difficult to elucidate the exact mechanisms which lead to the slower accumulation rate of osmolytes in these two regions than others.

The results of histological studies were essentially similar to those reported by Kleinschmidt-Demasters and Norenberg (6). Hyponatremia alone is not associated with any demyelinating changes in the brain. The animals with rapid correction of hyponatremia developed typical myelinolysis with vacuolation, microglial infiltration, and relative preservation of neurons. We found that the midbrain and striatum are the regions where demyelinating lesions developed most consistently and extensively (Table VI). Since these two regions are also the regions

where the recovery of the organic osmolytes was the slowest among all brain sections, it appears that a topographic correlation between the changes of osmolytes and myelinolysis exists.

It is worth mentioning that with the recent development of *in vivo* NMR spectroscopy, many prominent brain metabolites, such as GPC, creatine, glutamine/glutamate, and myoinositol, are now semiquantitated in patients with various disorders (31, 32). The results of our study indicate that the interpretation of *in vivo* magnetic resonance spectroscopy studies should be rigid about the region of interest, and that abnormalities of fluid and electrolytes in patients should be taken into account because most of these brain metabolites are also osmolytes whose levels are affected by changes in osmolality.

In conclusion, we report the first regional analyses of organic osmolytes in rat brain. Brain amino acids such as glutamine, glutamate, taurine, and betaine are higher in upper brain, but glycine is higher in the brain stem. Myoinositol, GPC, GPE, and creatine are relatively evenly distributed. Chronic hyponatremia is associated with global decrease of organic osmolytes. Rapid correction of hyponatremia is associated with normaliza-

Figure 3. Cross section of the midbrain (a) and pons (b). Arrows indicate bilateral symmetrical round, well-defined zones of pallor in the red nucleus (a) and in the midpontine regions (b), probably the extension of the midbrain lesions, indicating the presence of demyelination. Luxol fast blue stain (a) $\times 10$, (b) $\times 12$.

Table VI. Distribution and Severity of Demyelinative Lesions after Rapid Correction of Chronic Hyponatremia

Rat No.	1	2	3	4	5	6	7	8	9
Cerebrum	—	—	—	—	1+*	—	2+	—	—
Cerebellum	—	—	—	—	—	2+	—	2+	1+
Striatum	2+	3+	2+	2+	2+	1+	2+	1+	3+
Midbrain	3+	3+	3+	3+	2+	2+	2+	1+	3+
Pons	1+	2+	1+	—	—	—	—	—	2+
Medulla oblongata	—	—	—	—	—	—	—	—	—

* Grading system: 1+: small localized lesions with demyelination, loss of oligodendrocytes, gliosis, and vacuolation. Grade 2+: multiple lesions with the same histological findings as 1+. Grade 3+: large demyelinative lesions with neuronal necrosis.

tion of GPC, GPE, glutamate, and glycine, but the recovery of glutamine, taurine, myoinositol, and creatine is slow. Delayed increase of organic osmolytes is most prominent in midbrain and striatum, where severe myelinolysis develops a few days after rapid correction. Therefore, our study supports the theory that organic osmolytes may be relevant to the development of myelinolysis secondary to rapid correction of hyponatremia.

Acknowledgments

I thank Debra K. Martin for her excellent technical assistance, and Dr. Eric Prosnitz for his critical review of this manuscript.

This work was supported by National Institutes of Health grant ROI DK45666 and a research grant from the Southern Arizona Foundation.

References

- Adams, R. D., M. Victor, and E. L. Mancall. 1959. Central pontine myelinolysis: a hitherto undescribed disease occurring in alcoholic and malnourished patients. *Arch. Neurol. Psychiatry*. 81:154-172.
- Wright, D. G., R. Laureno, and M. Victor. 1979. Pontine and extrapontine myelinolysis. *Brain*. 102:361-385.
- Conger, J. D., J. A. McIntyre, and W. J. Jacob Jr. 1969. Central pontine myelinolysis associated with inappropriate antidiuretic hormone secretion. *Am. J. Med.* 47:813-817.
- Norenberg, M. D., K. O. Leslie, and A. S. Robertson. 1982. Association between rise in serum sodium and central pontine myelinolysis. *Ann. Neurol.* 11:128-135.
- Sterns, R. H. 1987. Severe symptomatic hyponatremia: treatment and outcome. A study of 64 cases. *Ann. Intern. Med.* 107:656-664.
- Kleinschmidt-Demasters, B. K., and M. D. Norenberg. 1981. Rapid correction of hyponatremia causes demyelination: relation to central pontine myelinolysis. *Science (Wash. DC)*. 211:1068-1070.
- Kleinschmidt-Demasters, B. K., and M. D. Norenberg. 1981. Neuropathologic observations in electrolyte-induced myelinolysis in the rat. *J. Neuropathol. & Exp. Pathol.* 41:76-80.
- Illowsky, B. P., and R. Laureno. 1987. Encephalopathy and myelinolysis after rapid correction of hyponatremia. *Brain*. 110:855-867.
- Laureno, R. 1983. Central pontine myelinolysis following rapid correction of hyponatremia. *Ann. Neurol.* 13:232-242.
- Endo, Y., M. Oda, and M. Hara. 1981. Central pontine myelinolysis: a study of 37 cases in 1000 consecutive autopsies. *Acta Neuropathol.* 53:145-153.
- McKee, A., M. D. Winkelman, and B. Q. Banker. 1988. Central pontine myelinolysis in severely burned patients: relationship to serum hyperosmolality. *Neurology*. 38:1211-1217.11.
- Berl, T. 1990. Treating hyponatremia: damn we do it, damn we don't. *Kidney Int.* 37:1006-1018.

- Lohr, J. W. 1994. Osmotic demyelination syndrome following correction of hyponatremia associated with hypokalemia. *Am. J. Med.* 96:408-413.
- Lien, Y. -H. H., J. I. Shapiro, and L. Chan. 1990. Effects of hypernatremia on organic brain osmoles. *J. Clin. Invest.* 85:1427-1435.
- Heilig, C. W., M. E. Stromski, J. D. Blumenfeld, J. P. Lee, and S. R. Gullans. 1989. Characterization of the major brain osmolytes which accumulate in salt loaded rats. *Am. J. Physiol.* 257:F1108-F1116.
- Lohr, J. W., J. McReynolds, T. Grimaldi, and M. Acara. 1988. Effect of acute and chronic hypernatremia on myoinositol and sorbitol concentration in rat brain and kidney. *Life Sci.* 43:271-276.
- Thurston, J. H., W. R. Sherman, R. E. Hauhart, and R. F. Klopper. 1989. Myoinositol: a newly identified nonnitrogenous osmoregulatory molecule in mammalian brain. 1989. *Pediatr. Res.* 26:482-485.
- Lien, Y. -H. H., J. I. Shapiro, and L. Chan. 1991. Study of brain electrolytes and organic osmolytes during correction of chronic hyponatremia: implication for the pathogenesis of central pontine myelinolysis. *J. Clin. Invest.* 88:303-309.
- Verbalis, J. G., and M. D. Drutarosky. 1988. Adaptation to chronic hyponatremia in rats. *Kidney Int.* 34:351-360.
- Ayus, J. C., J. M. Wheeler, and A. I. Arieff. 1992. Postoperative hyponatremic encephalopathy in menstruant women. *Ann. Intern. Med.* 117:891-897.
- Ohno, K., K. D. Pettigrew, and S. I. Rapoport. 1978. Lower limits of cerebrovascular permeability to nonelectrolytes in the conscious rat. *Am. J. Physiol.* 235:H299-H307.
- Beutler, H.-O. 1985. L-glutamate, calorimetric method with glutamate dehydrogenase and diaphorase. In *Methods of Enzymatic Analysis*, Vol 8. H. E. Bergmeyer, editor. Verlag Chemie, Weinheim, Germany. 369-376.
- Wallerstein, S., C. I. Zucker, and J. L. Fleiss. 1980. Some statistical methods useful in circulation research. *Circ. Res.* 47:1-9.
- Ansell, G., and S. Spanner. 1982. Phosphatidylserine, phosphatidylethanolamine and phosphatidylcholine. In *Phospholipids*. J. N. Hawthorne and G. B. Ansell, editors. Elsevier Science Publishing Co., New York. 1-41.
- Lien, Y. -H. H., H. Zhou, C. Job, C. J. A. Barry, and R. J. Gillies. 1992. In vivo ³¹P NMR study of early cellular responses to hyperosmotic shock in cultured glioma cells. *Biochimie (Paris)*. 74:931-939.
- Lien, Y. -H. H., H. Zhou, C. Job, and R. J. Gillies. 1993. Hypotonicity reduces phosphocreatine, glycerophosphocholine, and glycerophosphoethanolamine in intact cultured glioma cells measured by ³¹P NMR spectroscopy. *Clin. Res.* 41:97a. (Abstr.)
- Erecinska, M., D. Nelson, D. F. Wilson, and I. A. Silver. 1984. Neurotransmitter amino acids in the CNS. I. Regional changes in amino acids levels in rat brain during ischemia and reperfusion. *Brain Res.* 304:9-22.
- Dawson, R., Jr., D. R. Wallace, and M. J. King. 1990. Monoamine and amino acid content in brain regions of brattleboro rats. *Neurochem. Res.* 15:755-761.
- Butterworth, R. F., and J. F. Giguere. 1982. Glutamic acid in spinal cord gray matter in Friedreich's ataxia. *N. Engl. J. Med.* 307:897.
- Reulen, H. J., U. Hase, A. Fenske, M. Samii, and K. Schürmann. 1970. Extrazellulärraum und Ionenverteilung in grauer und weisser substanz des Hundehirns. *Acta Neurochir.* 22:305-325.
- Kreis, R., B. D. Ross, N. A. Farrow, and Z. Ackerman. 1992. Metabolic disorders of the brain in chronic hepatic encephalopathy detected with H-1 MR spectroscopy. *Neuroradiology*. 182:19-27.
- Kreis, R., and B. D. Ross. 1992. Cerebral metabolic disturbance in patients with subacute and chronic diabetes mellitus: detection with proton MR spectroscopy. *Radiology*. 184:123-130.