

# Erythropoietic Protoporphyrin in the House Mouse

## A Recessive Inherited Ferrochelatase Deficiency with Anemia, Photosensitivity, and Liver Disease

Sylvie Tutois,\* Xavier Montagutelli,\* Vasco Da Silva,† H el ene Jouault,‡ Philippe Rouyer-Fessard,|| Karen Leroy-Viard,|| Jean-Louis Gu enet,\* Yves Nordmann,‡ Yves Beuzard,|| Jean-Charles Deybach†

\*Unit  de G n tique des Mammif res, Institut Pasteur, 75724 Paris cedex 15; †Laboratoire de Biochimie, H pital Louis Mourier, 92701 Colombes cedex; ‡Laboratoire d'h matologie, H pital Henri Mondor, 94010 Cr teil; and ||INSERM U91, Laboratoire de biochimie, H pital Henri Mondor, 94010 Cr teil, France

### Abstract

A viable autosomal recessive mutation (named *fch*, or ferrochelatase deficiency) causing jaundice and anemia in mice arose in a mutagenesis experiment using ethylnitrosourea. Homozygotes (*fch/fch*) display a hemolytic anemia, photosensitivity, cholestasis, and severe hepatic dysfunction. Protoporphyrin is found at high concentration in erythrocytes, serum, and liver. Ferrochelatase activity in various tissues is 2.7–6.3% of normal. Heterozygotes (+/*fch*) are not anemic and have normal liver function; they are not sensitive to light exposure; ferrochelatase activity is 45–65% of normal. Southern blot analysis using a ferrochelatase cDNA probe reveals no gross deletion of the ferrochelatase gene. This is the first spontaneous form of erythropoietic protoporphyria in the house mouse. Despite the presence in the mouse of clinical and biochemical features unfrequent in the human, this mutation may represent a model for the human disease, especially in its severe form. (*J. Clin. Invest.* 1991. 88:1730–1736.) Key words: genetic disease • protoporphyria • mutagenesis • ethylnitrosourea • animal model

### Introduction

Ferrochelatase is the last enzyme on the heme biosynthesis pathway. It is present in mitochondria and catalyzes the insertion of the reduced form of iron ( $\text{Fe}^{2+}$ ) into protoporphyrin (1). In humans, erythropoietic protoporphyria is associated with a reduced activity of ferrochelatase (2). The disease is characterized by cutaneous photosensitivity. A mild microcytic, hypochromic anemia is observed in a minority of cases. Fatalities from rapidly progressive liver disease have been reported in at least 20 patients (1). Liver function tests are usually normal until shortly before liver failure becomes evident. Biochemically, erythropoietic protoporphyria (EPP)<sup>1</sup> results in accumulation of protoporphyria in erythrocytes, plasma, and feces. Although EPP is generally assumed to be an autosomal dominant hereditary condition, recent data suggest that the disease may be inherited, in some cases, in an autosomal recessive fashion (3, 4).

Received for publication 11 January 1991 and in revised form 24 May 1991.

1. Abbreviations used in this paper: ENU, ethylnitrosourea; EPP, erythropoietic protoporphyria; GF, griseofulvine.

*J. Clin. Invest.*

  The American Society for Clinical Investigation, Inc.

0021-9738/91/11/1730/07 \$2.00

Volume 88, November 1991, 1730–1736

Ferrochelatase deficiency has been described in cattle (5). Affected cows develop skin lesions after exposure to sunlight but, unlike human, they do not develop anemia or hepatobiliary disease (6). Bovine protoporphyria is transmitted as an autosomal recessive trait.

We describe here ferrochelatase deficiency in the house mouse, observed after a chemical mutagenesis experiment with ethylnitrosourea (ENU). Affected animals exhibit a mild anemia with a high reticulocyte count, photosensitivity, and dramatic hepatobiliary dysfunction with jaundice from the early days of life onwards. This condition is transmitted in an autosomal recessive fashion and represents the first genetically determined mouse model for human erythropoietic protoporphyria. The mutation has been named “ferrochelatase deficiency” (*fch*).

### Methods

**Animals.** The first mutant arose during in-breeding after a mutagenesis experiment in which males from an inbred strain carrying eight recessive mutations were injected with 250 mg/kg ethylnitrosourea (Sigma Chemical Co., St. Louis, MO). After successive matings with 129/Sv and BALB/c inbred strains, inbreeding was carried out. After a few generations of brother-sister mating, three mice in a litter of 10 displayed icteric sera. This characteristic appeared to be transmitted as a simple mendelian recessive trait. Homozygous males (*fch/fch*) from this pedigree were crossed with normal BALB/c females. The obligate heterozygous male offspring (+/*fch*) were crossed in turn with normal BALB/c females to produce heterozygous (+/*fch*) and normal (+/+) males. Heterozygotes (+/*fch*) were identified by crossing with an homozygous female (*fch/fch*). The same process was repeated with the goal of introducing the *fch* mutation into the BALB/c background. Observations were made on these animals, during the process of backcrossing, using BALB/c as controls (+/+).

Tests for allelism with spherocytosis (*sph*) and Hertwig's anemia (*an*) were performed by Pr. H. Scheufler, Martin Luther Universit t, Halle-Wittenberg, Germany.

Linkage experiments were performed using several mutations which affect the coat color or the skeleton, and located on mouse chromosomes 1–11, 13, 15, and 17. In particular, we used leaden (*ln*) for chromosome 1, brown (*b*) for chromosome 4, albino (*c*) for chromosome 7, Sombre ( $E^{So}$ ) for chromosome 8, and waved-2 (*wa-2*) for chromosome 11.

**Southern blot analysis.** High-molecular weight DNA was prepared from six +/+, +/*fch*, and *fch/fch* adult mice, according to standard protocols. 10  $\mu\text{g}$  of each DNA were digested with the following restriction enzymes: Bam HI, Eco RI, Hind III, Sac I, Taq I, and Xba I, under recommended conditions. Digested DNAs were electrophoresed in 0.8% agarose gels and transferred on Hybond N<sup>+</sup> filters (Amersham), as originally described by Southern (7).

Ferrochelatase cDNA was obtained from Taketani (8). The probe was labeled according to the procedure of Feinberg and Vogelstein (9). Hybridization was performed according to the method of Church and Gilbert (10).

**Hematological methods.** Blood samples were collected from mutant and normal appearing related mice at various ages (4 wk, 3 mo, 6 mo, or more) either by puncture of the orbital sinus or by heart puncture.

Blood parameters were measured using standard methods (i.e., Coulter Electronics, Inc., Counter [Hialeah, FL] for cell counts and hemoglobin, new methylene blue staining for reticulocytes).

Red cell osmotic resistance was tested on three mutants and three normal mice, aged 3 mo or more, using a standard protocol (11). The density distribution curve of erythrocytes was obtained according to the method described by Danon and Marikovsky (12).

Dried blood films were examined with Wright-Giemsa stain and by Perl's method for iron.

**Biochemical methods.** The usual biochemical parameters, conjugated and unconjugated bilirubin, transaminases, and alkaline phosphatases were determined by using a model SRA 2000 system (Technicon Instruments Corp., Tarrytown, NY) or a Paramax (Baxter Healthcare Corp., Deerfield, IL).

Hemoglobins were analyzed by cellulose acetate electrophoresis (13). Globin chains synthesis was analyzed after incorporation of <sup>3</sup>H-leucine into blood reticulocytes by PAGE in urea and Triton ×100 (14) followed by autoradiography.

Ferrochelatase activity was measured by a radiochemical method using <sup>55</sup>Fe and mesoporphyrin as substrate, as described by Deybach et al. (15).

Protoporphyrin was determined by the method of Schwartz et al. (16) or separated and quantitated as methyl esters using HPLC with spectrofluorometric detection (17).

**Histology.** Liver, bone marrow, and spleen were examined after Bouin's fixation, Paraplast embedding, and hematein-eosin staining.

## Results

### Clinical features

All *fch/fch* mutant mice are recognizable by the intense yellow color of their sera and, often, by gross bilirubinuria. Jaundice is usually apparent, especially in unpigmented albino mice. It is most severe in pups and young adult mice and often decreases slightly after a few months of age.

Photosensitivity was observed in *fch/fch* homozygotes under standard husbandry conditions (fluorescent light). Inflammatory lesions appear on ears and back, which often become ulcerous. No photosensitivity was observed in heterozygotes.

Young *fch/fch* homozygotes do not show any difference in size or body weight, compared to normal sibs, nor are they retarded in growth. However, they have enlarged livers and spleens, from the early days of life onwards (Table I). After a few months of age, they exhibit an enlarged abdomen (due to hepatomegaly and splenomegaly), decreased fat tissue and hypoactivity. Fertility appears to be reduced in both sexes, probably as a result of the general bad condition of affected animals.

Heterozygotes sometimes have a slightly icteric sera at 3 wk of age, but this disappears by adult age.

### Genetical analysis

**Segregation analysis.** Animals were recorded as mutants when they exhibited icteric sera at both 3 wk of age and at adult age (6–12 wk of age). When mutant mice were intercrossed, all the progeny (45 out of 45) were affected. Matings between affected and normal BALB/c mice produced no mutant progeny (out of > 50 animals). These progeny were considered as obligate heterozygotes. Intercrosses between these putative heterozygotes yielded 33 affected animals out of 173 progeny (19%, not significantly different from the expected value 25%). Crosses between putative heterozygotes and affected homozygotes produced 53% affected offspring (50 out of 95). These data are compatible with the inheritance pattern of a single autosomal recessive gene.

**Test of allelism.** This new mutation was compared to already described mutations causing jaundice or anemia in mice. The mutation was found not to be an allele of the spherocytosis (*sph*) and Hertwig's anemia (*an*) loci.

**Linkage experiments.** No genetic linkage was found between the *fch* mutation and any of the markers which have been tested. Subsequently, the *fch* mutation was found to be linked neither to the albino locus (*c*) which is in the vicinity of the  $\beta$ -globin gene on mouse chromosome 7, nor to the waved-2 locus (*wa-2*) which is close to the  $\alpha$ -globin gene on mouse chromosome 11.

**Southern blot analysis.** For each of the six enzymes tested, all *+/+*, *+/fch* and *fch/fch* animals exhibited the same hybridization pattern with the ferrochelatase cDNA probe (not shown).

### Hematological studies

The results of hematological studies are shown in Fig. 1 and Table II. Homozygous *fch/fch* animals were not anemic at 1 mo of age but normocytic anemia developed with age. Polychromasia, anisocytosis, target cells, and leptocytes were observed on blood films (Fig. 2). The red cell volume range distribution width was found to be increased in 3–6 mo old *fch/fch* mice (34.9, as compared to 21.6 in *+/+* controls). Reticulocytosis was markedly increased (14% in homozygotes instead of 3% in normal controls or heterozygotes). Perl's staining revealed no siderocytes or excess sideroblasts in bone-marrow smears which contained an increased proportion of erythroblasts.

The osmotic fragility of erythrocytes from homozygous *fch/fch* mice was slightly decreased. 50% osmotic lysis of *fch/fch* red cells occurred at a saline concentration of 0.46% compared to a figure of 0.53% for control red cells. The slope was also less

Table I. Comparison of Liver and Spleen Weight with Reference to Body Weight in *fch/fch* and *+/fch* 15-d-old Mice

	Body weight	Liver	Spleen	Liver/ body weight	Spleen/ body weight
	g	g	g	%	%
<i>fch/fch</i> (n = 6)	8.39±2.59	0.638±0.25	0.11±0.037	7.36±2.84	1.29±0.07
<i>+/fch</i> (n = 7)	7.72±4.18	0.34±0.096	0.061±0.017	4.39±0.06	0.79±0.03
P	NS	<0.02	<0.01	<0.001	<0.01

Number in parentheses indicate the number of animals in each group.

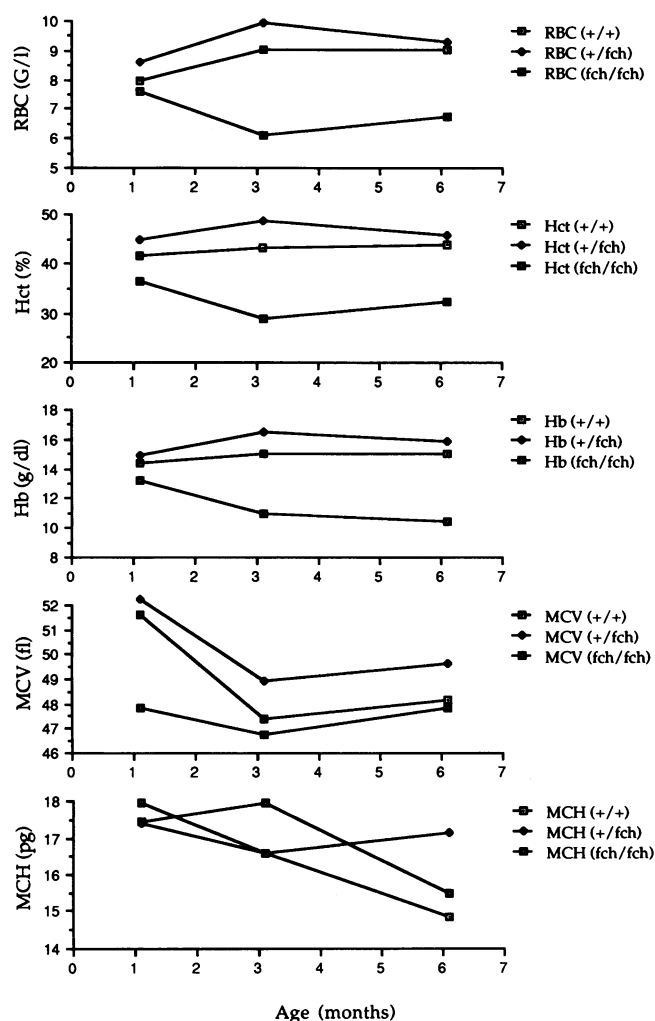


Figure 1. Hematological parameters in +/+, +/-, fch/fch mice (five animals per group) at 1, 3, and 6 mo of age.

abrupt in fch/fch red cells, indicating an increased heterogeneity in cell resistance to osmotic lysis.

The density distribution curve showed a decreased density of fch/fch red cells, median density 1.098 instead of 1.104 for normal cells. The fch/fch red cell density is also more heterogeneous than that of normal cells.

Table II. Hematological Parameters, in fch/fch, +/-, and +/+, 3-6-mo-old Mice (five animals in each group)

	+/+	+/-	fch/fch
Hb (g/dl)	14.6±0.8	16.0±4.4	9.9±1.3
RBC (10 <sup>6</sup> /μl)	8.9±0.5	9.7±0.2	6.5±0.8
Hct (%)	42.6±2.9	47.5±1.3	31.1±4.0
MCV (fl)	47.9±2.0	48.7±1.2	47.7±1.2
MCH (pg/cell)	16.4±0.3	16.4±0.2	15.3±0.6
Reticulocytes (%)	3	3	14

Homozygotes have a normocytic, slightly hypochromic, anemia, with a high reticulocyte count.

### Biochemical studies

Biochemical parameters (Table III) show that plasma bilirubin (mainly conjugated bilirubin) was markedly increased in fch/fch animals as compared to normal +/+ controls. Protoporphyrin was increased in erythrocytes, plasma, liver, and stool. Serum alkaline phosphatase and transaminases were also elevated.

Hemoglobin electrophoretic patterns and globin chain analysis by urea-Triton gel electrophoresis were normal (not shown). In vitro synthesis experiments showed no synthesis disequilibrium between  $\alpha$  and  $\beta$  globin chains.

Ferrochelatase activities in liver, spleen, and kidney in normal (+/+), heterozygous (+/-), and homozygous (fch/fch) animals are shown in Table IV. The level of the residual enzymatic activity is ~ 50% of normal in heterozygotes and 2.7-6.3% in homozygotes.

### Histological studies

Histologic examination of bone marrow and spleen revealed only erythroid hyperplasia. In the liver, focal accumulation of dense, dark brown pigment was observed in canaliculi, interlobular biliary ducts, and Kupffer cells (Fig. 3). Iron staining has been negative. Some portal areas have been infiltrated by mononuclear cells. A moderate portal and periportal fibrosis was found without significant change of hepatocytes morphology. Electron microscopy revealed degenerating hepatocytes and fibrosis. Crystalline structure of the pigment was observed in Kupffer cells and less frequently in hepatocytes (Fig. 4).

### Discussion

The new fch mutation, observed after chemical mutagenesis, produces in fch/fch mice a dramatic increase in the level of protoporphyrin in erythrocytes, plasma, liver, and stool, hemolytic anemia and hepatic abnormalities which mimic the biochemical features found in the severe forms of human EPP (18). These abnormalities are due to a pronounced specific deficiency of ferrochelatase activity, with < 7% residual activity found in all tissues tested (Table IV). Because of its very high erythropoietic activity, the spleen was used instead of bone marrow to estimate the level of enzymatic activity. Heterozygous (+/-) mice display normal biochemical and hematological values (Tables II and III) but have a 50% enzymatic deficiency (Table IV). These results are consistent with an autosomal recessive mode of inheritance. Moreover, they strongly suggest that the ferrochelatase structural gene itself could be the site of the mutation. A gross deletion within this gene can be excluded by the results from Southern blot analysis, but a point mutation, which has been reported to be the most frequent outcome of mutagenesis with ENU, remains possible.

Photosensitivity was observed in homozygotes (fch/fch) under standard husbandry condition (fluorescent light) but not in heterozygotes. Skin lesions were more severe in albino than in pigmented mice, on ears and back than on light protected areas. This feature is similar to the condition observed in the human or in cattle.

In spite of the morphological aspects, the increased osmotic resistance and the low density of erythrocytes, the fch mutation was shown not to be a form of thalassemia for at least two reasons. First, before we backcrossed onto BALB/c the stock in which the mutation arose, we found homozygotes (fch/fch)

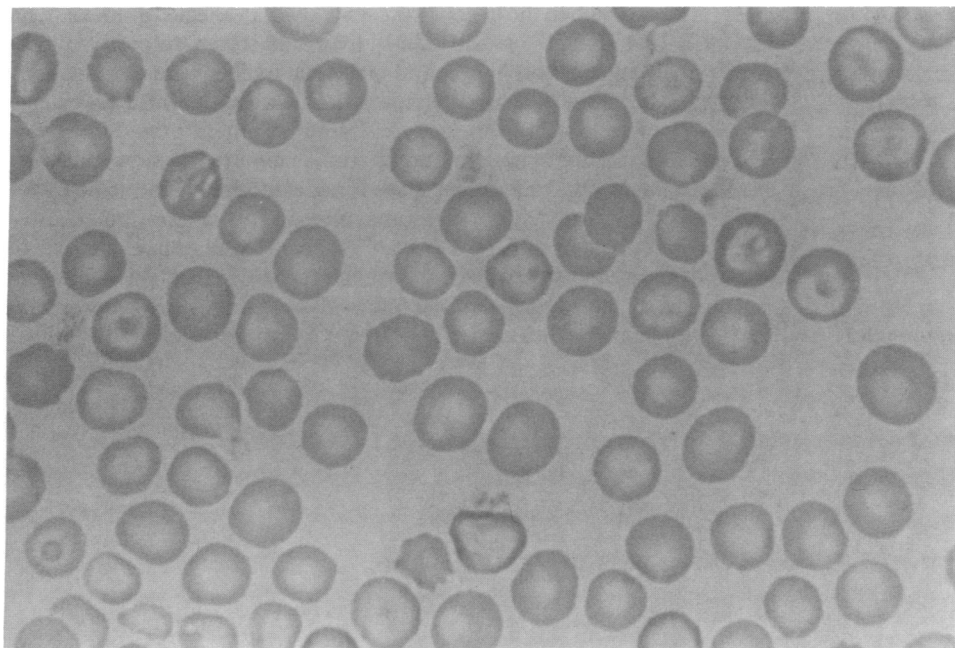


Figure 2. Erythrocyte morphology in an adult *fch/fch* mouse. Target cells, polychromasia, hypochromia, and anisocytosis are observed.

among albino (*c/c*) as well as nonalbino (*+/+* or *+/c*) animals, indicating that albino (*c*), which is linked to the  $\beta$ -globin gene on mouse chromosome 7, is not linked to the *fch* mutation. In addition, the *fch* determinant was not linked to the  $\beta$  globin haplotypes. Linkage results indicated that *fch* is not linked to *wa-2*, which is closely linked to  $\alpha$ -globin gene, on mouse chromosome 11. Second, in vitro synthesis experiments did not show disequilibrium between  $\alpha$  and  $\beta$  globin chain synthesis. These results clearly show that *fch* is not linked to globin genes.

Erythrocytes are heterogenous in hemoglobin content (some are very hypochromic) and in size (as shown by the increased range distribution width). They have a decreased density, which is a very sensitive parameter for detecting cells with a low hemoglobin concentration, and a higher resistance to hypoosmolarity. These features may be related in part to the reticulocytosis. They also suggest a slightly decreased hemoglobin synthesis which can be attributed to the profound deficiency in ferrochelatase of the highly erythropoietic spleen and

not to a thalassemic determinant. Portal hypertension, hypersplenism, and cholestatic jaundice may have enhanced the hematological abnormalities. There is no indication of an iron metabolism defect in erythroblasts, as evidenced by Perl's staining and electron microscopy of bone marrow and spleen.

We could not test allelism for all other recessive mutations causing anemia in mice, mainly because we could not get mutant mice from holders. However, we were able to discard most of these loci, partly because of a very different phenotype (19, 20), partly according to results from linkage experiments.

Scheufler (21) has described an anemia in the mouse (*hbd*, hemoglobin deficit) associated with a high level of free red cell protoporphyrin. This anemia is mild, hypochromic and microcytic. It is not associated with hyperbilirubinemia, or with liver abnormalities (22).

The only spontaneous animal model of EPP has been described in cows (5). It is associated with a photosensitizing disease, transmitted as a recessive trait (6). Ferrochelatase activity

Table III. Biochemical Parameters, in *+/+*, *+/fch*, and *fch/fch* 3–6-mo-old Mice

	<i>+/+</i>	<i>+/fch</i>	<i>fch/fch</i>
Protoporphyrins*			
Erythrocytes (nmol/liter)	1020–5988 (n = 5)	808–2303 (n = 5)	26101–128586 (n = 5)
Serum (nmol/liter)	10–17 (n = 5)	6–13 (n = 4)	170–3180 (n = 5)
Liver (nmol/g)	390–480 (n = 4)	750–820 (n = 4)	200000–800000 (n = 4)
Stool (nmol/g)	<30 (n = 2)	<30 (n = 3)	208–304 (n = 2)
Bilirubine ( $\mu$ mol/liter)‡			
Total	3.0±1.22 (n = 5)	2.33±0.52 (n = 6)	137±54 (n = 3)
Conjugated	2.6±0.89 (n = 5)	2.33±0.52 (n = 6)	110±54 (n = 3)
Alkaline phosphatase (U/liter)‡	121.4±19.4 (n = 5)	102.5±47.8 (n = 6)	1983±556 (n = 6)
GOT (U/liter)‡	59.8±13.3 (n = 5)	72.8±23.1 (n = 6)	538±71 (n = 5)
GPT (U/liter)‡	37.2±5.9 (n = 5)	42.3±11.1 (n = 6)	510±97 (n = 5)

\* Range of values. ‡Mean±SD. Number in parentheses indicates the number of animals in each group.

Table IV. Ferrochelatase Activity in Different Organs (in nmol of Meso-heme Synthesized/mg protein per hr)

	+/+	+/ <i>fch</i>	<i>fch</i> / <i>fch</i>	+/ <i>fch</i> +/+	<i>fch</i> / <i>fch</i> +/+
				%	%
Liver (n = 6)	24.5±1.9	15.8±2.0	0.67±0.19	65	2.7
Spleen (n = 4)	23.6±3.4	10.6±2.0	1.48±0.69	45	6.3
Kidney (n = 4)	27.5±2.9	14.9±0.7	0.92±0.24	54	3.3

Number in parentheses indicates the number of animals in each group.

was 43% in the liver of the carriers and, in affected animals, 7.3, 8.4, and 20% in the kidney, liver, and spleen, respectively (5). Red cell morphology and blood cell indices were normal. The bilirubin level was not reported. Cutaneous lesions were extensive. Erythrocytes and fecal protoporphyrin exceeded by far those of human protoporphyrin. As reported so far, the bovine deficiency in ferrochelatase is not associated with the hematological and hepatic features observed in severe human EPP cases and in *fch/fch* mice (23). This lack of hepatobiliary disease in cattle with protoporphyrin could be explained, in part, by the enhancement of bile acids secretion which helps maintaining efficient protoporphyrin excretion (24).

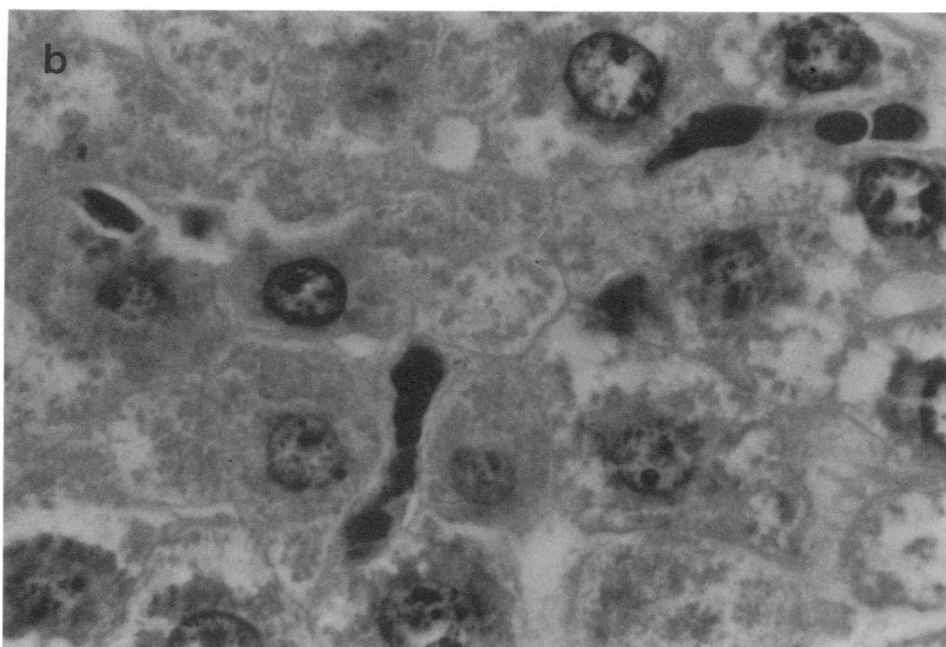
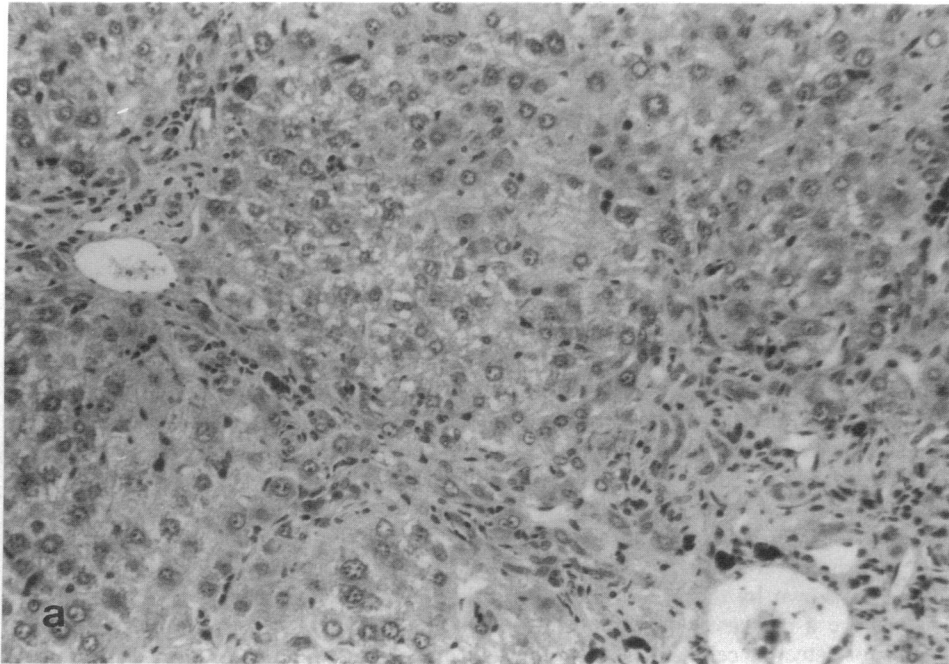


Figure 3. Liver histology shows portal and periportal fibrosis (a). Accumulation of dense brown pigment is observed in canaliculi and interlobular biliary ducts (b).

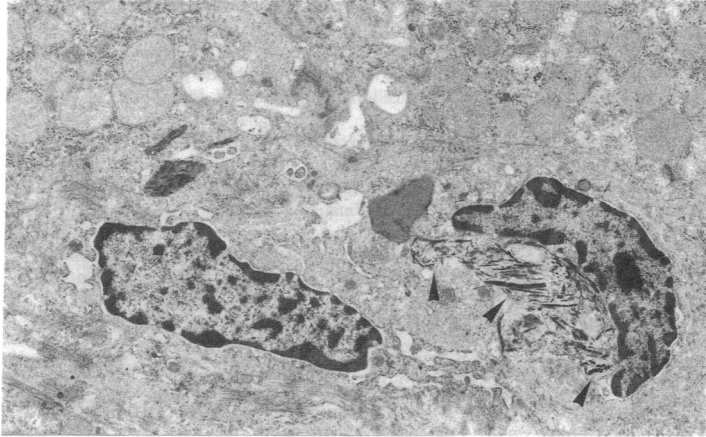


Figure 4. Electron micrographs of a *fch/fch* mouse showing crystallike structure of the pigment (arrows).

A biochemical protoporphyria phenotype can be easily experimentally induced in mice using griseofulvine (GF) as an inhibitor of ferrochelatase (25). It has been used as an experimental model for human EPP but the site of excess protoporphyrin synthesis in GF-induced mice is thought to be the liver, despite erythrocyte protoporphyrin concentration can become comparable to that observed in human EPP (26).

Human EPP is an hereditary disorder of heme synthesis characterized clinically by early skin photosensitivity, mainly in the form of burning and oedema shortly after exposure to sunlight. It is characterized biochemically by an increased level of protoporphyrin IX in red cells, plasma and feces, as the consequence of deficient ferrochelatase activity. The disease usually takes a benign course. Photosensitivity is thought to be produced by photochemical activation of the excess protoporphyrin. A minority of patients show a mild hypochromic microcytic anemia.

The inheritance of human EPP has been generally assumed to be as an autosomal dominant trait, but with partial penetrance (1, 27). However, latent cases seem to be very common. A study on 91 Dutch families (28) concluded that the disease followed a recessive mode of transmission but this study was based only on phenotypic features (fluorocytes in blood) and not on ferrochelatase activity measurements. Nevertheless, the profound enzymatic defect repeatedly found in patients (10–30% of normal) compared to the defect in asymptomatic carriers (40–50% of normal) (3) and the recent reports of a recessive mode of transmission of the ferrochelatase defect (3, 4) associated with clinical features similar to those observed in usual cases suggest that EPP is not transmitted as a simple dominant trait but may require more than a single gene defect for disease expression.

The hepatic defects represent a major and constant feature in the *fch/fch* mouse. Hepatomegaly is observed from the early days of life onwards and increases with age. It is associated with cholestasis, as shown by the high levels of conjugated bilirubin and alkaline phosphatase activity, and dilation of intrahepatic biliary ducts containing crystals. Unconjugated bilirubin is less affected, indicating that the hepatic conjugation system is very active but saturated, in relation to the increased hemolysis. Cirrhosis and hepatocyte dysfunction are documented by elevated transaminases and light and electron microscopy showing degenerated hepatocyte and fibrosis. Crystals, most probably of protoporphyrin, which is produced in excess by the er-

ythron, are present in hepatocytes and Kupffer cells. These crystals are likely to be responsible for cholestasis, which in turn explains the increase of conjugated bilirubin, an unusual feature in hemolytic anemia.

In the human EPP, a fairly large number of patients suffer from cholelithiasis with gallstones made of protoporphyrin complexes. The severity of the disease is related in a minority of cases to fibrosis and even cirrhosis of the liver, but acute liver failure is not frequent (1). Light and electron microscopic examination of liver biopsies from human EPP patients have revealed a wide variability in findings, ranging from normality to periportal fibrosis and severe cirrhosis. Accumulation of protoporphyrin has been detected as brown pigments in hepatocytes, Kupffer cells and biliary canaliculae. A recent study (29) concluded that ultrastructural changes in the hepatic parenchymal cells are present in early stages of the disease. Moreover, biliary canicular abnormalities responsible for cholestasis were observed, similar to that described in rat livers perfused with protoporphyrin (30).

Human EPP thus remains controversial with regard to its pathophysiological aspects, mode of inheritance, skin phototoxicity, liver injury, and treatment. The source of excess protoporphyrin seems to be the erythron as suggested by the recent liver transplantation reports in EPP patients (31). However, the mechanism of liver injury, appropriate markers to detect patients at risk of liver failure and then appropriate therapy are some important aspects which an animal model, like the *fch/fch* mouse, could help clarify.

## Conclusion

The *fch* mutation is characterized by a ferrochelatase deficiency. In the homozygous state, this mutation is responsible for more severe anemia and hepatic dysfunction than the human disease. In contrast, heterozygotes remain asymptomatic at 1 yr of age, but their long-term clinical evolution will have to be assessed. The mutation will be localized on the mouse chromosomes. Molecular studies will be attempted to check whether the ferrochelatase gene is affected, or not.

Despite differences in inheritance and penetrance of the severe hepatic phenotype, this mutation represents a useful model to study the pathophysiological features of the human disease. Bone marrow transplantation experiments will provide indications on the major source of excess protoporphyrin

production. Putative risk factors could be identified to predict severe liver injury. Treatments could also be attempted to prevent or to stop the progression of the disease (chenodesoxycholic acid, hematin transfusion).

## Acknowledgments

We are grateful to Dr. Taketani and Dr. Grandchamp for the gift of the ferrochelatase cDNA probe. We thank Pr. H. Scheufler for checking allelism of *fch* with *an* and *sph* mutations; Dr. P. Baldacci for critical reading of this manuscript.

This work was supported by grants from the Economic European Community and the Fondation pour la Recherche Médicale.

## References

1. Kappas, A., S. Sassa, R. A. Galbraith, and Y. Nordmann. 1989. The porphyrias. In *The Metabolic Basis of Inherited Disease*, 6th ed. C. R. Scriver, A. L. Beaudet, W. S. Sly, and D. Valle, editors. McGraw-Hill Book Co., New York. 1305-1365.
2. Nordmann, Y., and J.-C. Deybach. 1989. Human hereditary porphyrias. In *Biosynthesis of Heme and Chlorophylls*. H. A. Dailey, editor. McGraw-Hill Book Co., New York. 491-542.
3. Deybach, J. C., V. Da Silva, Y. Pasquier, and Y. Nordmann. 1986. Ferrochelatase in human erythropoietic protoporphyria: the first case of a homozygous form of the enzyme deficiency. In *Porphyrias and Porphyrins*. Y. Nordmann, editor. John Libbey, Paris. 163-173.
4. Norris, P. G., A. V. Nunn, J. L. M. Hawk, and T. M. Cox. 1990. Genetic heterogeneity in erythropoietic protoporphyria: a study of the enzymatic defect in 9 affected families. *J. Invest. Dermatol.* 95:260-263.
5. Ruth, G. R., S. Schwartz, and B. Stephenson. 1977. Bovine protoporphyria: the first nonhuman model of this hereditary photosensitizing disease. *Science (Wash. DC)*. 198:199-201.
6. Bloomer, J. R., K. O. Morton, R. J. Reuter, and G. R. Ruth. 1982. Bovine protoporphyria: documentation of autosomal recessive inheritance and comparison with the human disease through measurement of heme synthase activity. *Am. J. Hum. Genet.* 34:322-330.
7. Southern, E. 1975. Detection of specific sequences among DNA fragments separated by gel electrophoresis. *J. Mol. Biol.* 98:503-517.
8. Taketani, S., Y. Nakahashi, T. Osumi, and R. Tokunaga. 1990. Molecular cloning, sequencing, and expression of mouse ferrochelatase. *J. Biol. Chem.* 265:16377-16380.
9. Feinberg, A. P., and B. Vogelstein. 1984. A technique for radiolabelling DNA restriction endonuclease fragments. *Anal. Biochem.* 137:266-267.
10. Church, G. M., and W. Gilbert. 1984. Genomic sequencing. *Proc. Natl. Acad. Sci. USA*. 81:1991-1995.
11. Dacie, J. 1980. *The Hemolytic Anemias*. Grune and Stratton, New York. 37-42.
12. Danon, D., and Y. Marikovsky. 1964. Determination of density distribution of red cell population. *J. Lab. Clin. Med.* 64:668-674.
13. Whitney, J. B. 1978. Simplified typing of mouse hemoglobin (Hbb) phenotype using cystamine. *Biochem. Genet.* 16:667-672.
14. Rouyer-Fessard, P., M. C. Garel, C. Domenget, D. Guetarni, D. Bachir, P. Colonna, and Y. Beuzard. 1989. A study of membrane protein defects and  $\alpha$  hemoglobin chains of red blood cells in  $\beta$  thalassemia. *J. Biol. Chem.* 264:19092-19098.
15. Deybach, J. C., H. de Verneuil, and Y. Nordmann. 1981. The enzymatic defect in porphyria variegata. *Hum. Genet.* 58:425-428.
16. Schwartz, S., M. H. Berg, I. Bossenmaier, and H. Dinsmore. 1960. Determination of porphyrins in biological materials. *Methods Biochem. Anal.* 8:281-293.
17. Gray, C. H., C. K. Lim, and D. C. Nicholson. 1977. The differentiation of the porphyrias by means of high pressure liquid chromatography. *Clin. Chem. Acta*. 77:167-178.
18. DeLeo, V. A., M. Poh-Fitzpatrick, and L. Harber. 1976. Erythropoietic protoporphyria: 10 years experience. *Am. J. Med.* 60:8-22.
19. Leiter, E. H., W. G. Beamer, L. D. Schultz, J. E. Barker, and P. W. Lane. 1987. Mouse models of genetic diseases. In *Medical and Experimental Mammalian Genetics: A Perspective*. Y. A. McKusick, T. H. Roderick, J. Mori, and N. W. Paul, editors. Alan R. Liss, New York. 221-257.
20. Lyon, M. F., and A. G. Searle. 1989. *Genetic Variants and Strains of the Laboratory Mouse*. 2nd ed. Oxford University Press, Oxford, 876.
21. Scheufler, H. 1969. Eine weitere Mutante der Hausmaus mit Anämie (*hbd*). *Z. Versuchstierk.* 11:348-353.
22. Bannerman, R. M., L. M. Garrick, P. Rusnak-Smalley, J. E. Hoke, and J. A. Edwards. 1986. Hemoglobin deficit: an inherited hypochromic anemia in the mouse. *Proc. Soc. Exp. Biol. Med.* 182:52-57.
23. Brenner, D. A., and J. R. Bloomer. 1979. Comparison of human and bovine protoporphyria. *Yale J. Biol. Med.* 52:449-454.
24. Bloomer, J. R., J. G. Straka, H. Hill, M. K. Weimer, and G. R. Ruth. 1990. Comparison of bile porphyrin concentrations in cattle and human beings with protoporphyria. *Am. J. Vet. Res.* 51:1144-1146.
25. De Matteis, F., and C. Remington. 1963. Disturbance of porphyrin metabolism caused by griseofulvine in mice. *Br. J. Dermatol.* 75:91-104.
26. Nakao, K., O. Woda, F. Tokaku, S. Sassa, Y. Yano, and G. Urata. 1967. The origin of the increased protoporphyria in erythrocytes of mice with experimentally induced porphyria. *J. Lab. Clin. Med.* 70:923.
27. Bloomer, J. R., H. L. Bonkowsky, P. S. Ebert, and M. J. Mahoney. 1976. Inheritance in protoporphyria. Comparison of haem synthetase activity in skin fibroblasts with clinical features. *Lancet*. ii:226-228.
28. Went, L. N., and E. C. Klasen. 1984. Genetic aspects of erythropoietic protoporphyria. *Ann. Hum. Genet.* 48:105-117.
29. Rademakers, L. H. P. M., M. I. Cleton, C. Kooijman, H. Baart de la Faille, and J. Van Hattum. 1990. Early involvement of hepatic parenchymal cells in erythrohepatic protoporphyria? An ultrastructural study of patients with and without overt liver disease and the effect of chenodeoxycholic acid treatment. *Hepatology*. 11:449-457.
30. Berenson, M. M., C. Gunther, W. S. Samowitz, and D. Bjorkman. 1990. Formation of biliary thrombi in protoporphyria-induced cholestasis. *Hepatology*. 11:757-763.
31. Samuel, D., B. Boboc, J. Bernuau, H. Bismuth, and J. R. Benhamou. 1988. Liver transplantation for protoporphyria: evidence for the predominant role of the erythropoietic tissue in protoporphyria overproduction. *Gastroenterology*. 95:816-819.