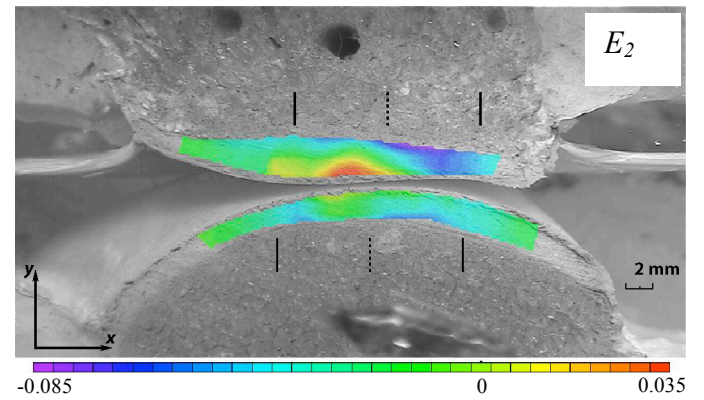
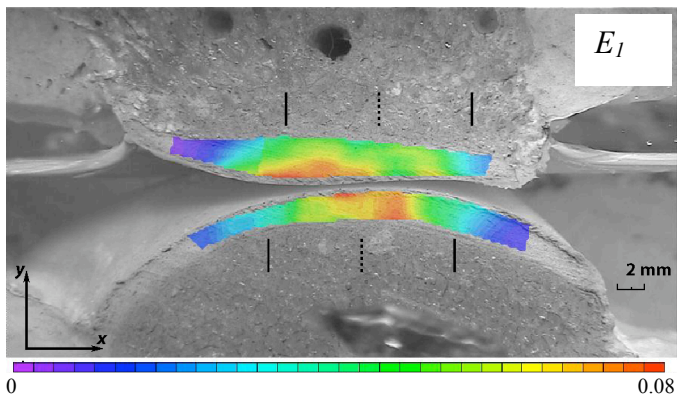












(a)

Fig. S 2. Two-dimensional strain maps for five human PFJ specimens (all male): (a) age 45, left knee; (b) age 52, left knee; (c) age 42, left knee; (d) age 42, right knee; (e) age 54, left knee.



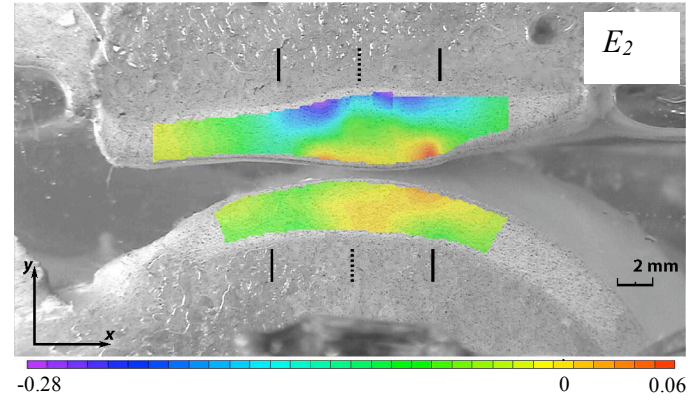
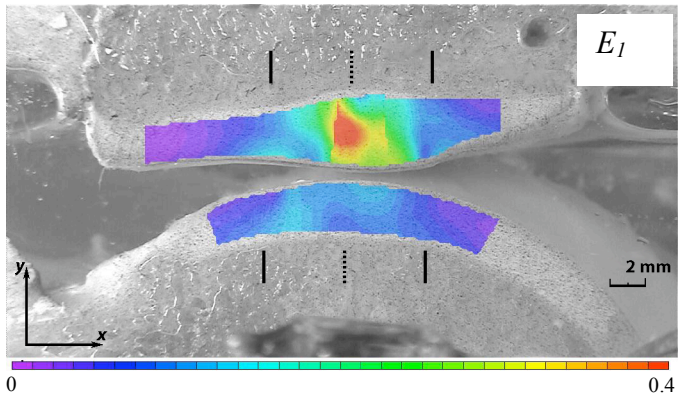

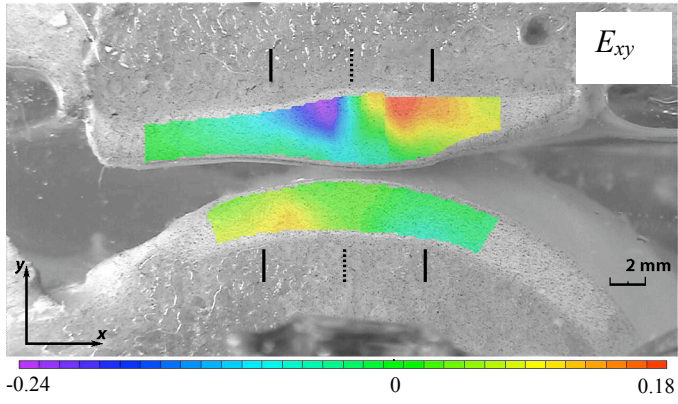
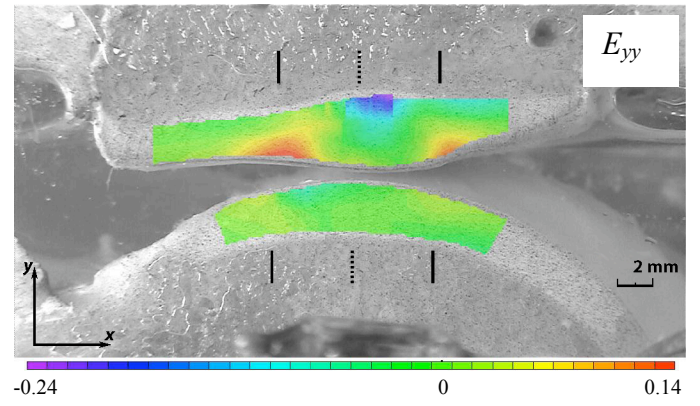
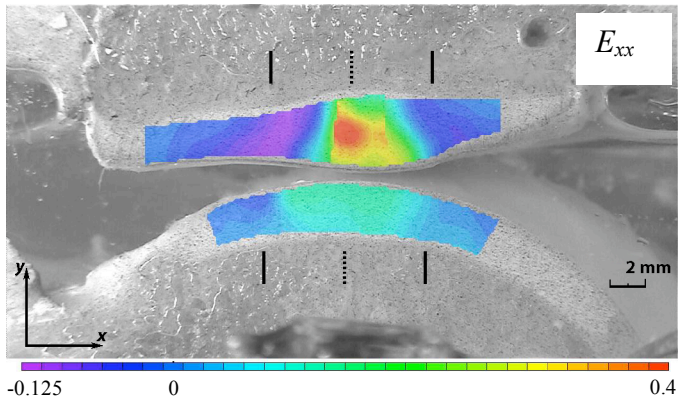
(b)

Fig. S 2. Continued.









(c)

Fig. S 2. Continued.



(d)

Fig. S 2. Continued.



(e)

Fig. S 2. Continued.