

# Immunotherapy of Coccidioidomycosis

ANTONINO CATANZARO, LYNN SPITLER, and KENNETH M. MOSER

*From the Pulmonary Division, Department of Medicine, University of California, San Diego, School of Medicine, San Diego 92103; the Veterans Administration Hospital, San Diego 92037; and the University of California, San Francisco, School of Medicine, San Francisco, California 94122*

**ABSTRACT** Transfer factor (TF) derived from donors with strong delayed hypersensitivity to coccidioidin (CDN) was administered to four patients with active disseminated or progressive pulmonary coccidioidomycosis. The clinical and immunologic response to TF was studied.

Before the administration of TF, all four patients had defective thymus-derived lymphocyte (T-cell) function. In no case were lymphocytes in culture stimulated to incorporate [<sup>3</sup>H]thymidine when exposed to CDN. Cases 1 and 2 had no skin test response to CDN or other antigen, nor was antigen-induced migration inhibition factor (MIF) release detected. Cases 3 and 4 had skin reactivity to CDN as well as MIF release. Lymphocyte reactivity to phytohemagglutinin (PHA), as measured by the incorporation of [<sup>3</sup>H]thymidine, was low or absent in all.

After the administration of TF, patients with negative skin tests became reactive to CDN, MIF release was present in all but case 1, and lymphocyte stimulation was present in response to CDN in all.

Lymphocyte reactivity to PHA was also increased after the administration of TF in all cases. All responses to single doses of TF were transient, lasting no more than 10 days. Subsequent doses were less effective at restoring lymphocyte stimulation once it had waned. Multiple doses of TF administered at frequent intervals appear to be the most effective way to maintain lymphocyte reactivity.

Clinical response to the administration of TF correlated closely with specific transfer as measured by response to CDN in skin test, lymphocyte stimulation, and MIF release. After TF administration, all patients mounted a more effective host response against the

infecting fungus. In each patient, smears and cultures became negative. Fistulas, when present, diminished in extent or closed; and pulmonary infiltrates cleared. Nonspecific signs of infection such as fever, weight loss, and anorexia also improved. Clinical improvement paralleled immunologic improvement. When immunologic improvement was transient so was clinical improvement. Multiple doses of TF at frequent intervals may maintain transferred T-cell reactivity. TF may prove to be a useful adjunct in the management of patients with coccidioidomycosis. Whether TF from CDN-negative donors may have similar effects is not known and requires exploration.

## INTRODUCTION

The variability of clinical response to infection with *Coccidioides immitis* has been recognized for many years. Using the development of cutaneous delayed hypersensitivity (CDH)<sup>1</sup> to intradermal coccidioidin (CDN), it has been established that 90% of residents in highly endemic areas become infected by *C. immitis*. Yet, clinical disease is uncommon (1). In the great majority of instances, the inhaled fungus is contained in the lungs by granuloma formation. Yet, in some, progressive pulmonary disease occurs, and in a small number, the infection disseminates from the lungs to other organs.

Expanding knowledge of the role of cell-mediated immunity (CMI) in conditioning the response to other infections led us to question its potential contribution to the clinical variability of patients infected with *C. immitis*. This question was stimulated by the observation that 50% of patients with disseminated disease

This work was presented in part at the National Meeting of the American Thoracic Society, New York, 1973.

Dr. Spitler is the recipient of National Institutes of Health Research Career Development Award (AI 4-3012).

Received for publication 22 February 1974 and in revised form 13 May 1974.

<sup>1</sup>Abbreviations used in this paper: CDH, cutaneous delayed hypersensitivity; CDN, coccidioidin; CF, complement fixation; CMI, cell-mediated immunity; MIF, migration inhibition factor; PHA, phytohemagglutinin; SI, stimulation index; SK-SD, streptokinase-streptodornase; T cell, thymus-derived lymphocytes; TF, transfer factor.

failed to develop CDH to intradermal CDN (2). More recently, we have shown that patients with a poor biologic response to *C. immitis* infection have abnormal thymus-derived lymphocyte (T-cell) function in response to both mitogen and specific antigen (3). These data have suggested that enhancement of CMI in such patients might have therapeutic potential. The most promising current avenue for achieving such enhancement is the administration of transfer factor (TF).

TF is a dialyzable extract of immune leukocytes which is capable of transferring cellular immunity from an individual with CDH to CDN to a nonreactive recipient (4). Therapeutic use of TF began in 1969 in a patient with the Wiskott-Aldrich syndrome (5). Subsequently, it has been used to treat a variety of other illnesses associated with defective cellular immunity (6). More recently TF has been administered to patients with intracellular infections such as mucocutaneous candidiasis (7-9), leprosy (10), and coccidioidomycosis (11, 12). The present report describes the results of TF administration on the clinical course of coccidioidomycosis and the reactivity of lymphocytes to CDN and phytohemagglutinin (PHA) in four patients.

## METHODS

*Patient selection.* Four patients ranging in age from 7 to 58 yr were studied. Diagnosis of coccidioidomycosis was confirmed in each by bacteriologic or histologic demonstration of *C. immitis*. Clinical course was followed with X ray and serologic studies (complement fixation [CF] and precipitin) and bacteriologic examinations at appropriate intervals. Disseminated coccidioidomycosis was diagnosed when bacteriologic or histologic demonstration of *C. immitis* was made in any organ outside the lungs.

*Skin tests.* Antigens used were: CDN 1:100, 1:10 (Cutter Laboratories, Berkeley, Calif.); streptokinase-streptodornase (SK-SD) 5 U (Varidase, Lederle Laboratories, Pearl River, N. Y.); histoplasmin (Parke, Davis & Co., Detroit, Mich.); purified protein derivative (U. S. Public Health Service); trichophyton 1:1000 (Hollister-Stier Labs., Spokane, Wash.); Mumps (Lederle Laboratories). Each antigen was injected intradermally in a volume of 0.1 ml. Induration was measured at 48 h. A positive reaction is defined as over 5 mm induration.

*Antigen and mitogen.* CDN was prepared from *C. immitis*, Silveira, by Dr. Demosthenes Pappagianis (TS-1-72). Previous studies have demonstrated that antigenicity of CDN in skin test does not correlate with either protein or carbohydrate concentration (13). Accordingly, the dose of CDN is expressed as a dilution of the crude extract. Each culture was stimulated with three doses of CDN, 0.01, 0.05, 0.1 ml of 1:10 dilution. PHA was purchased from Burroughs Wellcome Co. (Research Triangle Park, N. C.). A dose range from 0.1 to 12  $\mu\text{g}/\text{ml}$  was explored. Maximal stimulation was found at 3  $\mu\text{g}/\text{ml}$  in both immune and nonimmune subjects. Patients with coccidioidomycosis also demonstrated maximal response to 3  $\mu\text{g}/\text{ml}$ . Consequently, all studies reported here were performed at that dose. Lyophilized SK-SD was reconstituted in phosphate-buffered

saline (PBS), dialyzed exhaustively against PBS, and stored at a concentration of 1,000 U/ml. 50 U/ml was used to stimulate cultures.

*Lymphocyte transformation.* Peripheral venous blood was collected into a syringe containing 20 U of preservative-free heparin/ml of blood. The syringe was placed upright at 37°C to allow sedimentation of erythrocytes. The leukocyte-plasma layer was collected and centrifuged at 800 *g* for 10 min. The leukocytes were resuspended in F10 medium (Grand Island Biological Co., Grand Island, N. Y.) and washed twice with media. The cells were suspended in F10 medium supplemented with 20% plasma from a single AB+ donor and placed in culture at 750,000 lymphocytes/ml. Triplicate 2-ml cultures containing  $1.5 \times 10^6$  lymphocytes, were incubated at 37°C in 5% CO<sub>2</sub>-enriched air atmosphere. Stimulated and control cultures were terminated at days 3 and 5 for PHA, days 5, 7, and 9 for CDN. Control unstimulated, mitogen-stimulated, and antigen-stimulated cultures were treated in the same manner. 1 h before each culture was to be terminated, 1  $\mu\text{Ci}$  [<sup>3</sup>H]-thymidine was added to each tube. Incubation was continued for 1 h at 37°C. The culture was terminated with 100-fold excess of unlabeled thymidine and centrifuged at 4°C. Cells were washed with saline twice. The cell mass was treated with 5 ml 6.7% trichloroacetic acid at 4°C. Precipitate was collected by centrifugation and redissolved in 1 ml 0.1 M NaOH. This procedure was repeated three times. Finally, the precipitate was dissolved in 2 ml Protosol (New England Nuclear, Boston, Mass.) and mixed with 10 ml of Aquasol (New England Nuclear). [<sup>3</sup>H] incorporation was measured as beta scintillation in a Packard liquid scintillation counter (Packard Instrument Co., Inc., Downers Grove, Ill.). Stimulation which was twofold or greater was considered a positive response.

*Macrophage inhibition factor.* MIF production was assayed by the technique of Rocklin, Myers, and David (14), modified in that peripheral blood leukocytes are collected as described above. Eagle's minimal essential medium, Spinner modification (Grand Island Biological Co.), was used to culture  $3 \times 10^6$  lymphocytes in 1 ml. Triplicate cultures were stimulated with three doses of CDN, (0.01, 0.05, 0.1 ml of 1:10 dilution) or SK-SD (100 U). Controls included media without cells or antigen, media with cells and no antigen, media with antigen and no cells. Tubes were incubated at 37°C in 5% CO<sub>2</sub>-enriched air atmosphere. Supernate was collected from each tube at 24, 48, and 72 h. At 24 and 48 h, 4 ml of fresh media containing the same concentration of antigen as originally used was added to the cells.

Supernatant fluids from like cultures were pooled, dialyzed against distilled water, lyophilized, and reconstituted to 20% of their original volume. Peritoneal exudate cells were collected from Hartley strain guinea pigs. Intraperitoneal injection with 30 ml of mineral oil was made. 72 h later, the peritoneal cavity was drained and washed with media. The peritoneal exudate cells were collected and washed three times in media. Capillary tubes were loaded with a cell suspension and packed by centrifugation. Capillary tubes were cut at the cell interface and mounted in Mackness type chambers. Chambers were filled with processed supernatant fluid from the above described cultures or controls. Migration of guinea pig peritoneal exudate cells was measured by planimetry at 24 and 48 h. Migration in experimental chambers containing supernates of lymphocytes cultured with antigen was measured and divided by migration in control chambers containing super-

nates of lymphocytes cultured without antigen. Percent was obtained by multiplying by 100. Inhibition of migration by 20% or more in experimental chambers as compared with control chambers is indicative of MIF production.

*Preparation of TF.* Donors of TF met the following criteria: (a) They had CDH to intradermal CDN (1:100) in 48 h of over 20 mm of induration; (b) [<sup>3</sup>H]thymidine incorporation after lymphocyte culture in the presence of CDN was at least four times greater than control cultures on the 6th day; (c) MIF was released when lymphocytes were cultured in the presence of CDN; (d) Australia antigen was not detected in peripheral blood. Lymphocytes were harvested by leukapheresis of 2 U of whole blood or by leukapheresis on the Aminco cell separator (American Instrument Co., Inc., Silver Springs, Md.). TF was prepared by our modification (5) of the method of Lawrence (4). The cells were suspended in saline, frozen, thawed, and refrozen until all cells were ruptured, then treated with DNAase and magnesium sulfate. This preparation was placed in a dialysis sac and dialyzed against distilled water. The dialysate was lyophilized and reconstituted in 2 ml normal saline. Each dose was prepared from a single donor and is defined as the amount of TF obtained from 5 × 10<sup>8</sup> lymphocytes. The preparations were tested for pyrogenicity and were passed through a 0.22- $\mu$ m Millipore filter (Millipore Corp., Bedford, Mass.) before use. Ability to cause transfer in normal, nonsensitive individuals was also assayed by skin test, MIF release, and lymphocyte stimulation in response to CDN. TF was given subcutaneously, and in addition, TF was given subcutaneously twice in an attempt to achieve local transfer.

#### CHARACTERIZATION OF STUDY PATIENTS

*Clinical status.* Case 1 was a 50-yr-old Mexican American male who was admitted to University Hospital with a 4-mo history of fatigue and weight loss. 2 mo previously, he had developed a nonproductive cough, afternoon fever, and night sweats. 4 wk later, he noted anorexia, weakness, and weight loss. 1 wk before admission, he observed a generalized rash which subsequently evolved into raised lesions on his face and trunk. The fever became persistent and the patient deteriorated acutely over the 3 days before admission. There was a history of diabetes. The patient had been born in Mexico City, lived in Imperial Beach, Calif. for 2 yr, and had worked as a laborer on surrounding farms.

Physical examination revealed a toxic, diaphoretic, slightly wasted Mexican man with papular crusted lesions on his face. Respirations were shallow with a rate of 40/min. Fine rales were audible throughout the chest. Cardiac examination disclosed a regular rhythm, a rate of 120/min, and no gallops or murmurs. The abdomen was soft, scaphoid, and nontender. The liver and spleen were moderately enlarged. X ray of the chest revealed a miliary lesion throughout both lung fields. Laboratory data included: hematocrit, 33%; leukocyte count, 9,000; erythrocyte sedimentation rate,

74 mm/h; bilirubin, 3.5 total; urinalysis, 4+ protein. Arterial blood gas analysis on room air revealed P<sub>O</sub><sub>2</sub> = 50 mm Hg; P<sub>CO</sub><sub>2</sub> = 29 mm Hg; and pH 7.54. Wet mount of exudate from lesions on the face revealed many spherules with endospores typical of *C. immitis*. Similar spherules were seen on liver biopsy. Cultures from these skin lesions as well as the blood and bone marrow revealed *C. immitis*. Serologic studies with CDN were positive: CF, 1:512, precipitin, +4. Skin tests with purified protein derivative-S, SK-SD, 50 U, mumps, and CDN 1:10 produced no induration at 24 or 48 h. Histoplasmin produced 2 mm of induration at 48 h.

Case 2 is a 58-yr-old Caucasian man who has had pulmonary coccidioidomycosis for 14 yr. His disease was first discovered when a routine chest X ray revealed a cavity. The patient was asymptomatic. The diagnosis was established by histologic demonstration of *C. immitis* on lung biopsy. Systemic amphotericin (3 g) was administered and the cavity closed. 7 yr before admission, the pulmonary infection reactivated. He was treated with further systemic amphotericin (6 g) and again responded. 3 yr before admission and again just before admission, he had reactivation of pulmonary infection. He also had chronic obstructive pulmonary disease. When he entered the study, he was chronically ill and appeared much older than his chronological age. His chest wall was thin and respiratory excursions were decreased. Breath sounds were distant and diffuse rales were present. Chest X ray revealed marked loss of volume and extensive fibronodular infiltration at both apices which had been present unchanged for several years. There was a new alveolar filling pattern in the left lower lobe. Sputum culture revealed *C. immitis*.

Case 3 is a 37-yr-old Negro woman who has had coccidioidomycosis for 20 yr. Her initial manifestation was cervical adenitis. Biopsy established the coccidioid etiology and she was treated with local surgical drainage. 5 yr later, she had had a localized pneumonia due to *C. immitis*. 10 yr before admission, she developed widespread pneumonia due to *C. immitis*. She received systemic amphotericin (4 g) and improved slowly. 6 yr before admission, she developed a right paraspinal mass which has persisted to the present without change. 1 yr before admission, she developed an abscess in the right gluteal area. This was accompanied by fever, sweats, and pain at the site of the abscess. Culture of the abscess yielded *C. immitis*. A program of irrigations with 50 mg amphotericin and local surgical drainage three times a week, was begun. This program was continued until admission, when it was demonstrated that irrigation fluid placed in the gluteal abscess was recovered in the airway. Physical

TABLE I  
*CDH in Patients with Coccidioidomycosis before the Administration of TF*

	CDN		Candida		Mumps	SK-SD		Tricho- phytin	Purified protein derivative	Histo- plasmin
	1:10	1:100	1:1000	1:400		5 U	50 U			
Case 1	0	0	0	0	0	0	0	0	0	0
2	0	0	0	0	0	0	0	0	0	2*
3	—	35	8	—	17	12	—	17	0	0
4	9	0	0	0	0	0	0	12	0	0

\* Millimeters of induration measured 48 h after intradermal injection of test antigen.

examination upon entry to the study revealed a thin, chronically ill woman. Cervical nodes were matted but revealed no acute inflammation. The fistulous tracts were found draining from the lower quadrant of each gluteal area. X rays demonstrated a right paraspinal mass from T7-12. Sinograms revealed broad fistulas extending from each gluteal area to the lateral border of the psoas bilaterally communicating with the paraspinal mass at T7-12 and emptying into the left lower lobe bronchus.

Case 4 is a 7-yr-old Mexican girl who developed paraplegia at age 2. At the age of 5, a full workup revealed that her neurologic defect was secondary to an extensive paraspinal inflammatory mass which had enveloped and partially destroyed the third, fourth, and fifth thoracic vertebral bodies. She also had extensive pulmonary infiltration at both upper lobes. *C. immitis* was cultured from her sputum and from abscess fluid. Over the next 18 mo the patient was given daily intravenous amphotericin to a total dose of 8 g. She also had several surgical procedures designed to remove necrotic tissue, attempt bone grafts, and maintain adequate drainage. Despite vigorous medical and surgical treatment, the fistulas continued to drain copious quantities of material which contained viable *C. immitis*. She was debilitated and toxic at the time of admission to the study. Examination revealed a 40-lb Mexican girl who was underdeveloped, chronically ill, and too weak to get out of bed. There was a 10 × 5-cm fluctuant mass over the spine at C7 draining a yellow discharge. There were rales on auscultation of the right upper chest. The child was unable to move her lower extremities. These muscles were atrophied and there was a Babinski on the right. Osteolytic changes were seen in several ribs as well as the vertebral bodies of C4-7. Infiltrates were present in both upper lobes and left lower lobe. Contrast study demonstrated extension of the fistulous tract through the pleura into the posterior mediastinum at the level of T9.

## RESULTS

*Base-line immunologic data.* All four patients had defective T-cell function. Cases 1 and 2 had negative

skin test to CDN as well as all other antigens tested. Cases 3 and 4 had positive skin tests to CDN as well as other antigens (Table I). MIF production was detected upon stimulation by CDN in cases 3 and 4, however [<sup>3</sup>H]thymidine incorporation was not increased by CDN in any patient (Table II).

*Immunologic response to TF.* Case 1 was given 1 U of TF subcutaneously on three occasions (Fig. 1). The 1st U of TF was divided, 10% was given subcutaneously on the upper arm in preparation for later skin testing. The remainder, as well as the two subsequent doses, was given subcutaneously in the thighs. Intradermal CDN 1:10 was applied at two sites 24 h after TF administration. The skin test applied at the site of previous subcutaneous TF administration developed erythema and soft cutaneous edema which measured 20 mm. The skin test applied on normal, unprepared skin produced no reaction, 5 days after the 1st U of TF, [<sup>3</sup>H]thymidine incorporation after stimulation with CDN was significantly increased. Response to PHA unfortunately was not measured in this first post-TF sample; response to SK-SD was measured and was increased 7.5-fold over control. MIF production was not detected. 14 days after the first dose of

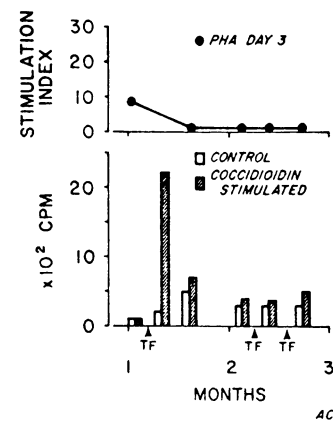


FIGURE 1 Illustrates the course of case 1. The upper panel indicates little response to PHA at any time. The lower panel demonstrates that the first dose of TF was followed by vigorous responsiveness to CDN.

TABLE II  
Clinical and Immunologic Response to TF

Clinical improvement		Lymphocyte SI							
		Skin test response to CDN		PHA				MIF response to CDN	
		Before TF	After TF	Before TF	After TF	Before TF	After TF	Before TF	After TF
1	yes	-	+	8	1	1	8	-	-
2	yes	-	+	1-2	1-5	1	4	-	+
3	yes	+	+	5-10	40-110	1	5	+	+
4	yes	+	+	12-16	100-271	1	8	+	+

TF, lymphocyte stimulation was down almost to control level. 2 subsequent U of TF had no demonstrable effect on the response to PHA in vitro or to CDN in vitro or in skin test. An overview of the response in each case is presented in Table II.

Case 2 was given 7 U of TF subcutaneously (Fig. 2) over an 11-mo period. Intradermal CDN 1:100 was applied at two sites 24 h after the injection of the 1st U of TF. The skin test applied at the site of previous subcutaneous TF administration developed 9 mm induration at 48 h. The skin test applied over normal, untreated skin produced no reaction. 6 days after the 1st U, in vitro studies demonstrated fourfold stimulation of thymidine incorporation by CDN. A second dose of TF was given subcutaneously 7 days after the first. 10 days after this second dose, there was a marked increase in thymidine incorporation in the unstimulated tubes without antigen and the addition of CDN did not produce any further increase. Systemic transfer of skin test reactivity to CDN had occurred. 2 wk after the second dose of TF, lymphocyte reactivity had returned to pretreatment levels in both control and CDN-stimulated cultures. 6 wk after the

second injection of TF, there was no skin test response to CDN 1:10. Subsequent injections of TF had no effect on thymidine incorporation response to PHA. There was no response to PHA in any of the cultures over a period of 12 mo. At the 13th mo of observation, 8 wk after 2 U of TF, thymidine incorporation was 8-fold increased over control on day 3 and 33-fold increased on day 5. MIF was not detected in response to CDN before injection of TF. After TF, MIF was consistently released in response to CDN.

Case 3 was given 7 U of TF subcutaneously over 12 mo (Fig. 3). 5 days after her 1st U of TF, lymphocyte culture showed vigorous thymidine incorporation in response to CDN. Skin test response to CDN 1:100 was 35 mm induration at 48 h before the administration of TF. Accordingly skin test response to CDN was not repeated during the period of observation.

By the 10th day after TF, the response had returned to base-line levels. The 2nd U of TF, as in Case 2, was followed by a significant thymidine incorporation in control cultures collected 10 days after the administration of TF. The 3rd U also was followed by an

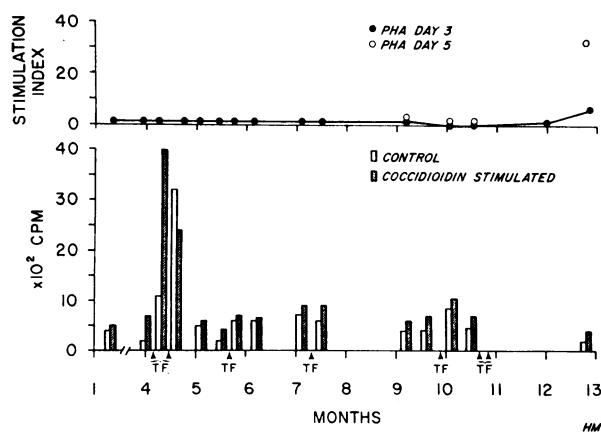


FIGURE 2 Illustrates the course of case 2. The upper panel demonstrates no response to PHA until 13 mo. The lower panel shows an increased incorporation in CDN-stimulated cultures after the first two doses of TF.

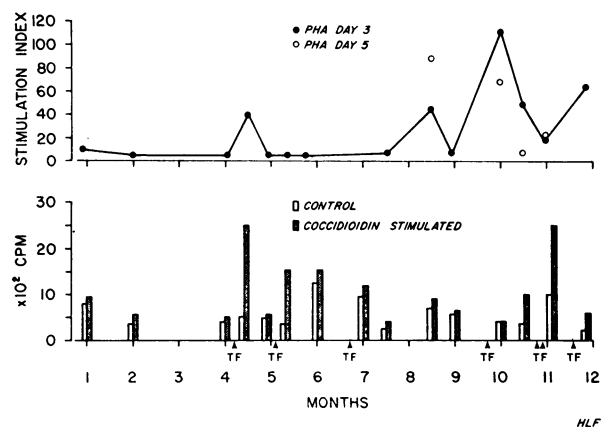


FIGURE 3 Illustrates the course of case 3. Both PHA and CDN response were found after TF on several occasions.

increased incorporation in stimulated and control cultures when measured 7 days after the injection. Within 4 wk, that effect was gone, and by the 9th mo, all studies were back to base-line levels. A 4th U of TF had no effect on control or stimulated cultures. Doses five and six were given together and resulted in marked stimulation of thymidine incorporation in response to CDN. A single seventh dose did not prevent a return of incorporation to a lower level. However, CDN-stimulated incorporation was threefold greater than control. PHA response was absent initially. Increased response to PHA often followed administration of TF. The time-course of the response to PHA was delayed initially and became normal after TF.

Case 4 was given six doses of TF subcutaneously over 5 mo (Fig. 4). Skin tests were avoided during the period of observation. 7 days after the 1st U of TF, in vitro studies showed greater than threefold stimulation by CDN over control. Four more doses of TF were given, one each week over the next month. In vitro studies showed an initial elevation of incorporation in control cultures which dropped toward base-line levels later in the month. CDN continued to stimulate significant incorporation. TF was withheld for 5 wk. At the end of that period, the response to CDN and control cultures had returned to pretreatment levels. Stimulation index (SI)<sup>2</sup> response to PHA initially ranged between 12 and 14 on day 3. SI on day 5 was 73. After TF, the SI of lymphocytes to PHA was increased (SI = 271 on day 3 and 145 on day 5). When TF was withheld for 5 wk, the SI dropped to 18 on day 3 and 38 on day 5.

*Clinical response to TF.* Case 1 was treated with amphotericin 50 mg/day intravenously as well as TF.

<sup>2</sup>SI refers to counts per minute in culture with antigen or mitogen divided by the counts per minute in culture without antigen or mitogen.

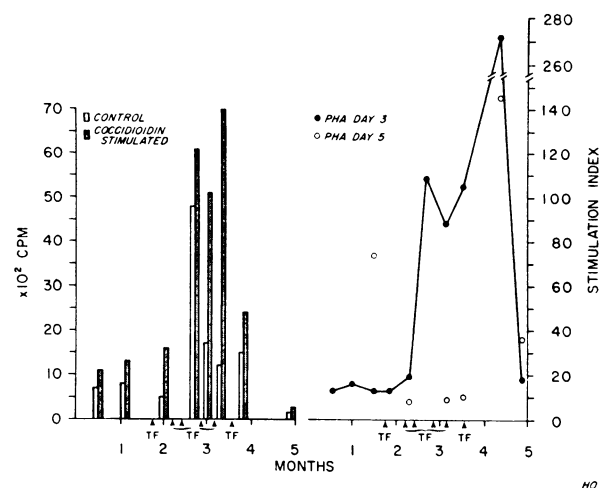


FIGURE 4 Case 4 had marked increase in response to CDN and PHA in response to repeated doses of TF. They both returned to base-line levels after 6 wk without TF.

48 h after the administration of TF, the patient developed erythema multiforme around the raised lesions on his skin. He developed a similar lesion around the site of CDN injection but not at other antigen injection sites. The induced skin lesions persisted for several days but did not become raised or indurated. A biopsy of one of the lesions showed perivascular infiltration by lymphocytes. His fever diminished, and the patient became more active and regained appetite. The skin lesions became smaller and began to heal. (Fig. 5). Spherules of *C. immitis* which had been abundant in the exudate of skin lesions decreased markedly in number of the first 2 wk of therapy. Spherules could not be found even on histologic examination of skin lesions. Multiple cultures revealed no *C. immitis*. The patient's subsequent course was one of slow deterioration with cachexia, Coombs positive hemolytic anemia, and hepatic dysfunction. He died 7 wk after therapy

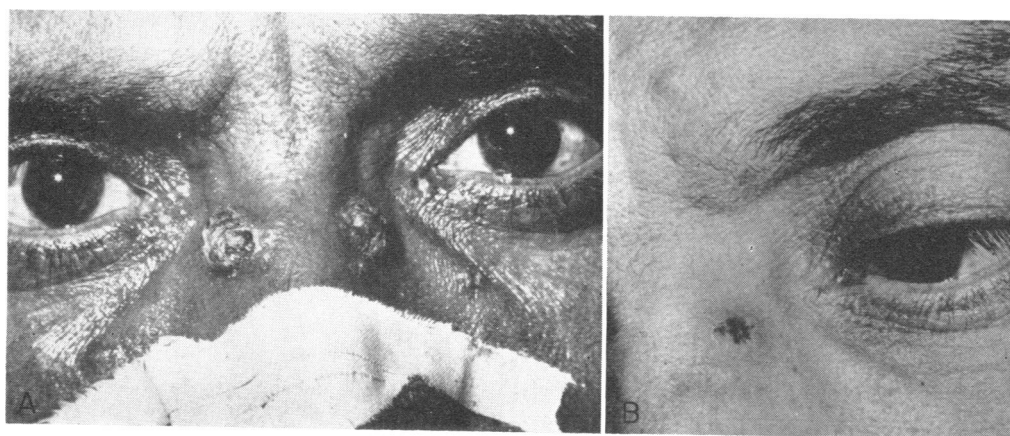


FIGURE 5 Case 1 (A) on entry to study, (B) after 4 wk of therapy, see text.

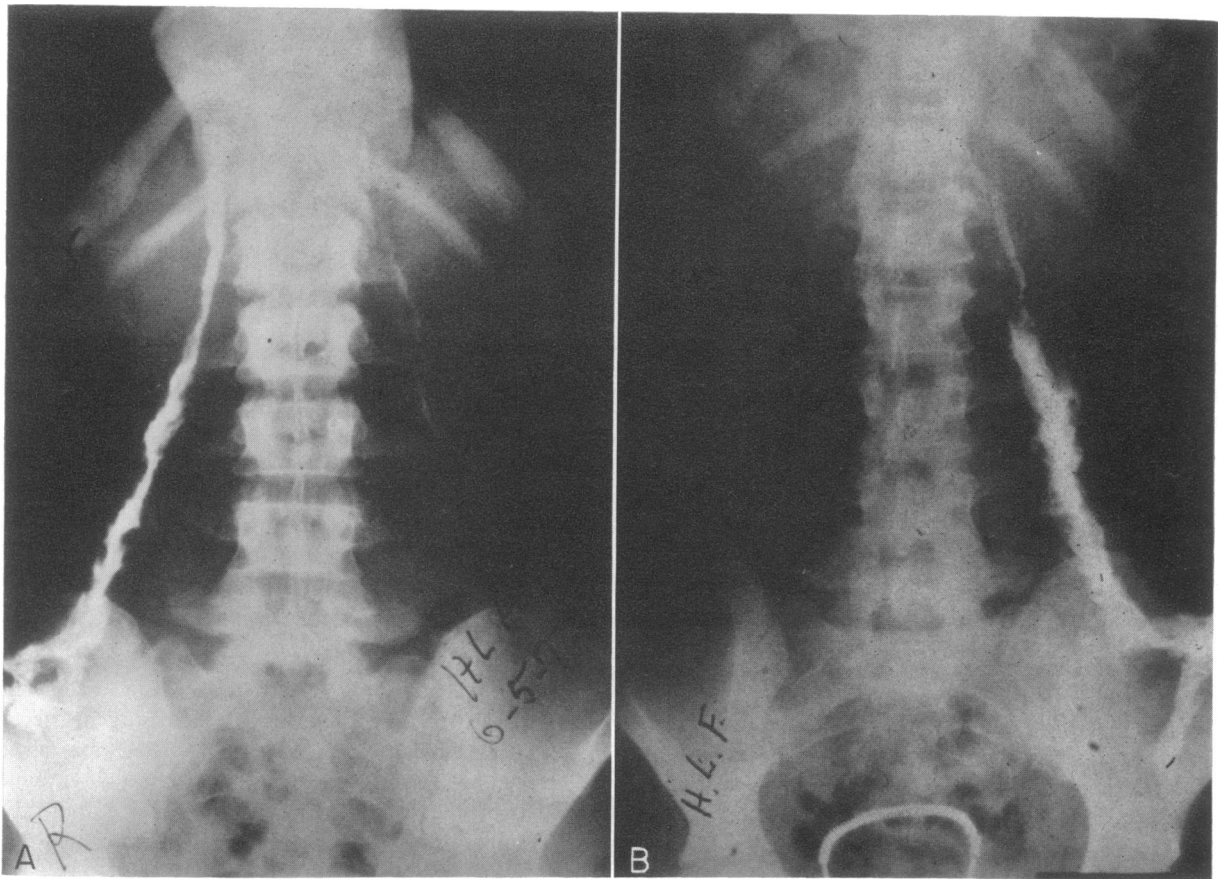


FIGURE 6 Case 3 (A) and (B) show extensive fistula formation at the time of entry to the study.

with TF had begun. The cause of death was not apparent. Postmortem examination could not be obtained.

Case 2 did not receive concomitant amphotericin therapy. The patient improved gradually over several weeks after receiving TF. His sputum production decreased and cultures were negative for *C. immitis*. His exercise tolerance, weight, and sense of well-being all increased. During the period from the 7th to the 10th mo when TF was withheld, the patient deteriorated dramatically. Sputum production increased, severe hemoptysis occurred, and an area of infiltration observed previously on chest X-ray became a large cavity. Sputum culture was positive for *C. immitis* and *Escherichia coli*. TF therapy was reinstated and sputum culture promptly became negative. Slow clinical improvement followed with increased exercise tolerance and weight gain. CF with CDN was positive to a titer of 1:256. Serial studies revealed no change in titer over the period of 13 mo.

Case 3 had a broncho-mediastinal-retroperitoneal-cutaneous fistula which drained necrotic material. Bacteriologic study of that material demonstrated *C. immi-*

*tis*. The basic therapy that had been administered for 13 mo before study entry, as well as during the study period, consisted of instillation of 50 mg amphotericin into the fistulous tract three times each week. Concurrent with the first three doses of TF, drainage from the fistulas decreased in amount and stopped on the right side. Culture of the wound failed to recover fungi. A sinogram showed no fistula on the right, and on the left the fistula no longer traversed the diaphragm. When TF was not administered through the 9th mo of follow-up, drainage increased from both fistulas and a sinogram demonstrated re-establishment of both fistulous tracts and their communication with the posterior mediastinal areas and the airway. Renewed TF therapy, given at frequent intervals, resulted in reclosure of the fistula on the right and decreased drainage on the left. (Fig. 6).

Case 4 had been receiving amphotericin 15 mg/day intravenously at the onset of the study. This was continued for the entire study period. The patient was extremely ill when she received her first dose of TF. Subsequent doses were given regularly until she had

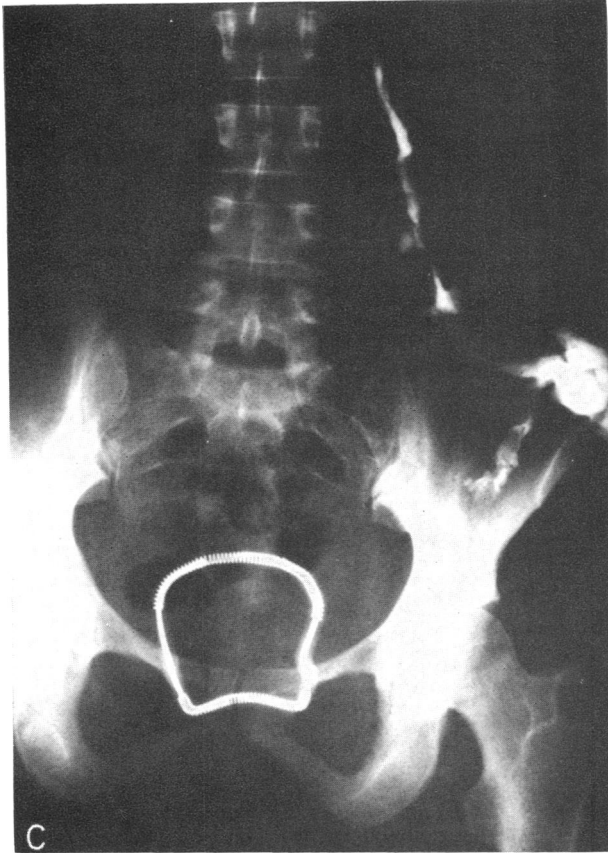


FIGURE 6 (C) Case 3 after 4 wk of therapy, see text.

received six doses. Over the 2 mo period of TF administration, the patient experienced continuous improvement. She quickly became afebrile; her drainage diminished, then stopped; the fistulous tract healed over; and she regained neurologic function to the point that she was able to walk with ease. During the next 2 mo, she continued to improve with increase of weight, and resumed near normal activity. Radiologically, her pulmonary infiltrates have nearly resolved, a nodule has formed in the lingula and bone lesions appear to be healing (Fig. 7).

#### DISCUSSION

The treatment of coccidioidomycosis presents a difficult set of problems. Amphotericin is the only currently available standard agent with activity against *C. immitis*. Systemic administration of amphotericin is often associated with significant toxic effects; i.e., chills, fever, nausea, shock-like picture, potassium loss, renal failure, and anemia (15). In addition, the drug is only fungistatic and requires host defense mechanisms to rid the body of infection. Mortality rates in disseminated coccidioidomycosis, particularly acute dissemina-

tion, remain high (16). These patients frequently lack skin reactivity to CDN despite a vigorous antibody response as detected by CF (16).

In a previous report (3), we demonstrated that patients with a poor biologic response to infection with *C. immitis* show a defect in skin test reactivity to CDN. They also show defects in cellular immunity in vitro as manifested by failure to undergo lymphocyte stimulation and MIF release in response to CDN. An abnormal kinetic response in lymphocyte stimulation to CDN and PHA has also been demonstrated.

TF is capable of transferring skin test reactivity from a skin test positive donor to a skin test negative normal recipient (17). Not only skin reactivity but also in vitro parameters of cellular immunity are transferred (18). TF is exceedingly potent, the amount contained in 0.1 ml of packed leukocytes being sufficient to transfer systemic reactivity to a normal individual (19). These observations led to attempts to use TF therapeutically to reconstitute patients with diminished cellular immunity (6-12). In these conditions TF has been clearly shown to cause conversion of skin tests and in vitro tests of cellular immunity. However, clinical response is more difficult to assess.

The administration of TF to patients with coccidioidomycosis offers a unique opportunity to study several interrelated questions. What is the nature of the defect in CMI in patients with coccidioidomycosis? Can it be corrected by TF? What effect does TF have on the course of clinical disease? Is that effect related to specific immunologic action of TF?

In this study we chose not to discontinue the administration of amphotericin in those patients who were receiving it (cases 1, 2, and 4) since the disease was considered life-threatening and the efficacy of TF is unproven. The prognosis in case 1 was bleak. Fatality in patients with acute coccidioidal fungemia has been reported to be 100% (16). Cases 2 and 4 had had a long period of observation on standard therapy which served as an internal control. Case 3 was treated with TF alone. All patients in this study showed a defect in cellular immunity to CDN in at least one of the three tests used (skin reactivity, lymphocyte stimulation, or MIF release). Clinical response to infection was inadequate in all patients. As indicated above case 1 had a bleak prognosis. Cases 2, 3, and 4 had not been able to clear the infection even after 2-18 yr of conventional therapy. With the exception of the MIF release, which remained negative in case 1, all three tests of the cellular immune response became positive, at least temporarily, in all the patients after the administration of TF from donors sensitive to CDN. The most striking effect of the administration of TF was on the transfer of specific response to CDN in lym-



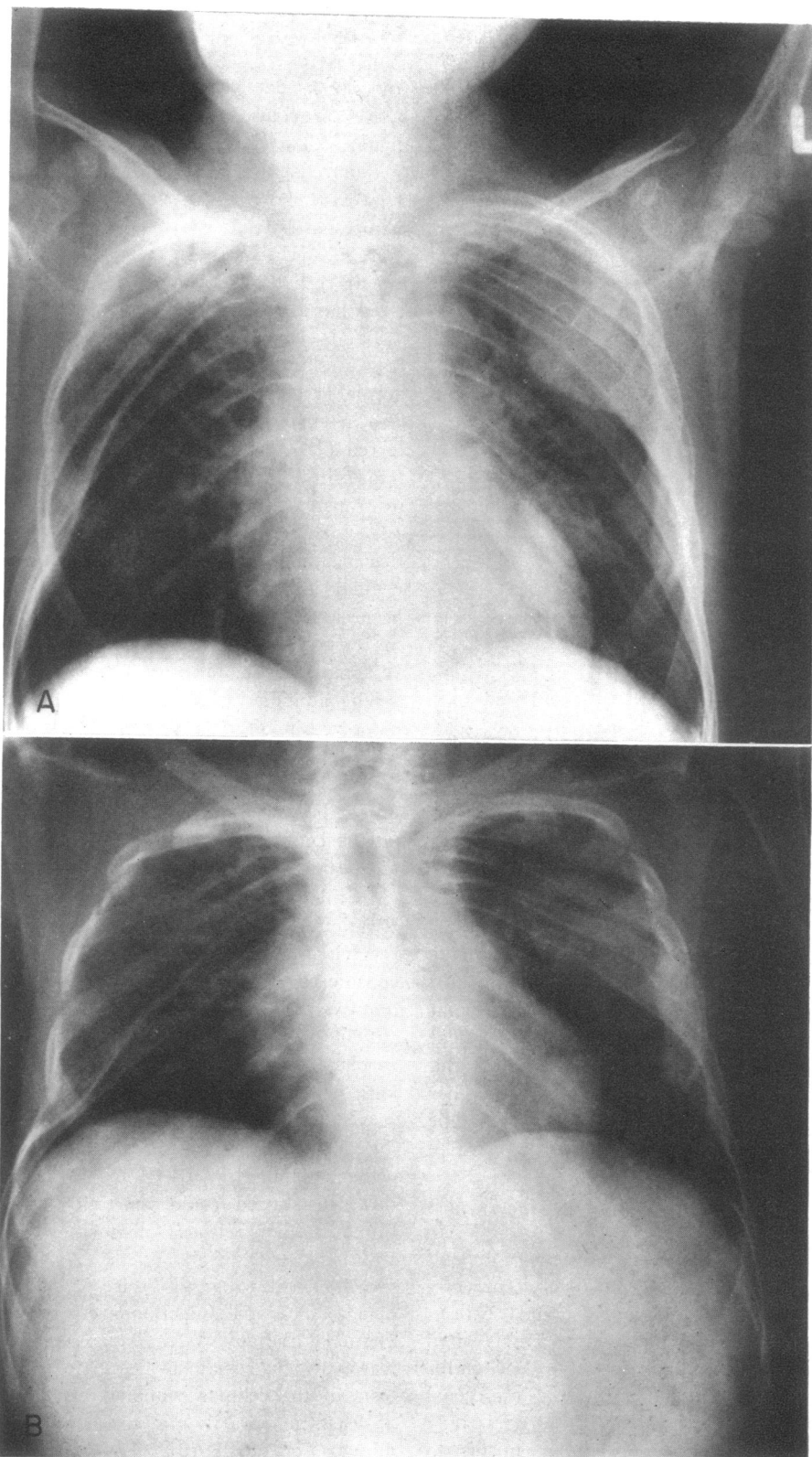


FIGURE 7 Case 4 (A) shows chest X ray at the time of entry to the study, (B) after 8 wk of therapy, see text.

phocyte stimulation. No patient had lymphocyte stimulation by CDN before TF; all became positive after TF. We did not determine the specificity of transfer by the administration of TF derived from the donors without sensitivity to CDN.

The transient nature of the transferred immunity in the patients presented is in contrast with the reported results in normal where evidence in skin and in vitro for transferred sensitivity persists for months to years (19). In our patients, the conversion of skin test reactivity was transient. Increased lymphocyte stimulation to CDN, which appeared within 24 h of administration of one dose of TF, was lost usually within 10 days. Subsequent single doses of TF were less effective when initial transferred reactivity had waned. Reconversion required multiple doses, as in case 2. These data suggest that the best approach is to repeat doses frequently, as in case 4. Even in case 4, when exquisite sensitivity to CDN had been transferred, it waned when TF was not administered over a period of 6 wk. Similar loss of transferred reactivity and failure to regain it with further administration of TF has been observed in a patient with a completely unrelated disease, severe combined immunodeficiency diseases.<sup>3</sup> Montgomery, South, and Wilson (20) have made a similar observation and have further noted that, when reactivity was lost to one antigen, it could still persist to a second, unrelated antigen. The mechanism responsible for this failure to re-establish reactivity after loss of initial TF-transferred sensitivity is not at all clear. One possible explanation could be that TF acts on a precursor cell which may have specificity for an antigen or group of antigens. This cell is induced under the influence of specific TF to "mature" and become reactive to the specific antigen in vivo and in vitro. When these short-lived specific T cells are eliminated at the site of infection or their capacity to interact with antigen altered, specific sensitivity to CDN wanes. If the precursor cells are in limited number, or more immature or less responsive cells to TF must be called forth, greater doses of TF may be required. With time precursor cells may be regenerated from a more immature population of cells. The generation of new TF-responsive cells may explain the observation that when additional TF is given later, responsive cells may be present (11). The lack of reactivity to PHA is not a marker that can be used to predict the lack of response to TF.

Two patients showed marked changes in their response to PHA after TF. This observation has not been previously reported. Most recipients of TF re-

<sup>3</sup> Pirofsky, B., and L. E. Spittler. Unpublished observations.

ported in the literature have been responsive to PHA before TF administration. A few patients whose lymphocytes were unreactive in the mixed lymphocyte response have had TF administered. These patients regained the capacity to react in the mixed lymphocyte response after TF administration (21). While change in PHA responsiveness in two patients cannot be considered a definitive observation, it does suggest that TF may have nonspecific as well as specific effects. Nonspecific enhanced lymphocyte reactivity may be induced by the crude TF preparation in addition to the transfer of specific reactivity. The nonspecific effects are not necessarily due to the specific active material in the preparation but may be part of the crude extract of cells.

Although the clinical response to TF is the most difficult aspect of the study to assess, each patient had at least some objective evidence of clinical improvement after TF. Response to the first dose was the most marked. The effect was transient, and if TF were not continued, the patient deteriorated. This was most obvious in cases 2 and 3. Case 4 showed the most striking response to TF. This patient had had optimal medical and surgical therapy for over a year, yet draining fistulas persisted. She had extensive infection and was toxic. After several doses of TF, and improvement in the in vitro correlates of CMI, she steadily improved clinically, began to gain weight and lead a near normal life.

The observation that case 1 developed erythema multiforme after the initial dose of TF is of considerable interest. Erythema multiforme, when it occurs in coccidioidomycosis, is associated with erythema nodosum and is part of the primary infection in patients with strong delayed hypersensitivity to CDN (22). At the time of TF administration, case 1 had no skin reaction to CDN 1:10, his lymphocytes were not stimulated by CDN nor was MIF release detected. Within 24 h after the administration of TF, erythema multiforme had developed around skin nodules, prior CDN test sites, and apparently uninvolved skin. TF administration was followed by positive response to CDN by lymphocytes in culture; MIF and skin test remained negative. The time of onset of erythema multiforme and the fact that the setting was not typical for that seen in coccidioidomycosis certainly suggest that the lesion was related to the administration of TF. Erythema nodosum was noted in four patients with lepromatous leprosy after the administration of TF. The skin lesions were transient in the lepromatous patients, as they were in the patient with coccidioidomycosis, and probably do not constitute a major hazard to TF therapy (10). We are unable to comment on the specificity of the clinical and immunologic response to TF

from CDN-positive donors since TF from CDN-negative donors was not studied. Having demonstrated an effect of TF in these patients the specificity of requirements of TF should be addressed in further studies.

A major concern before the initiation of TF therapy was whether the sudden re-establishment of specific cellular immunity in patients with widespread infection might result in an overwhelming adverse reaction. In the studies by Bullock in patients with leprosy, major systemic adverse effects of TF were not observed (10). Case 1 was of particular concern since he had coccidioidal fungemia and miliary disease to the extent that pulmonary gas exchange was greatly impaired. With the administration of TF his gas exchange did not deteriorate. His general condition improved despite the occurrence of erythema multiforme. The clinical improvement, as well as the lymphocyte stimulation by CDN, was short lived and could not be regained with subsequent doses of TF. At the time of death there was no evidence of active infection. Appropriate cultures revealed no fungi. The cause of death cannot be determined with certainty since autopsy was not performed. Again the question of TF toxicity must be addressed. A review of the clinical course may be helpful. He did show laboratory and clinical evidence of improvement and clearing of active infection. His therapy included amphotericin of course, at a dose of 125 mg/day. He suffered hepatic dysfunction, microangiopathic anemia, and sodium wasting. However, at the time of entry to the study, case 1 had acute miliary disease and coccidioidal fungemia. Mortality in such patients is reported to be universal, even with amphotericin (16).

These studies demonstrate that all of the parameters of cellular immunity tested (skin test reactivity, lymphocytes stimulation, and MIF production) can be reconstituted, at least temporarily, by the use of TF in patients with disseminated coccidioidomycosis. They further suggest that clinical benefit to the patient may result. It is important to establish firmly whether or not the addition of this immunotherapeutic regimen to the standard therapy of disseminated coccidioidomycosis with amphotericin may result in clinical benefit to the patient and/or shortening of the course of amphotericin therapy.

The correlation of clinical improvement with immunologic reconstitution in these patients provides strong evidence for the role of CMI in clearing infection with *C. immitis*. Full elucidation of the mechanisms involved and the therapeutic potential of TF await further investigation.

## ACKNOWLEDGMENTS

The authors wish to extend their appreciation to Sharon Batcher, James Dice, Patricia Flanagan, Hazel Talley, Mae Hsu, and Christine von Muller for technical assistance, and to Mary Gortmaker for preparation of the manuscript. Discussion with Dr. Peter Baram has been very helpful and is appreciated. We are most grateful to the physicians who provided primary care to the patients listed and facilitated the study. They are Doctors Vernon Wyborney, J. Randall Miller, David Chadwick, Patricia Dunkley, John Shepard, and Kenneth Miller.

This study was supported by Research Grants from the California Research and Education Fund and the National Institutes of Health (Pulmonary SCOR, HL-14169), and NIH grant AI-CA-10686.

## REFERENCES

1. Smith, C. E., R. R. Beard, H. G. Rosenberg, and E. C. Whiting. 1946. Varieties of Coccidioidal infection in relation to epidemiology and control of the disease. *Am. J. Public Health*. **36**: 1394-1402.
2. Fiese, M. J. 1958. *In Coccidioidomycosis*. Charles C. Thomas, Publisher, Springfield, Ill. 1st edition. 96-98.
3. Catanzaro, A., L. Spitler, and K. M. Moser. 1974. Cellular immune response to coccidioidomycosis. *Cell. Immunol.* In press.
4. Lawrence, H. S. 1955. The transfer in humans of delayed skin sensitivity to streptococcal M substance and to tuberculin with disrupted leukocytes. *J. Clin. Invest.* **34**: 219-230.
5. Spitler, L. E., A. S. Levin, D. P. Stites, H. H. Fudenberg, B. Pirofsky, C. S. August, E. R. Stiehm, W. H. Hitzig, and R. A. Gatti. 1972. The Wiskott-Aldrich syndrome: results of transfer factor therapy. *J. Clin. Invest.* **51**: 3216-3224.
6. Levin, A. S., L. E. Spitler, and H. H. Fudenberg. 1973. Transfer factor therapy in immunodeficiency states. *Annu. Rev. Med.* **24**: 175-208.
7. Rocklin, R. E., R. A. Chilgren, R. Hong, and J. R. David. 1970. Transfer of cellular hypersensitivity in chronic mucocutaneous candidiasis monitored *in vivo* and *in vitro*. *Cell. Immunol.* **1**: 290-299.
8. Kirkpatrick, C. H., R. R. Rich, and T. K. Smith. 1972. Effect of transfer factor on lymphocyte function in anergic patients. *J. Clin. Invest.* **51**: 2948-2958.
9. Schulkind, M. D., W. H. Adler, III, W. A. Altmeier, III, and E. M. Ayoub. 1972. Transfer factor in the treatment of a case of chronic mucocutaneous candidiasis. *Cell. Immunol.* **3**: 606-615.
10. Bullock, W. E., J. P. Fields, and M. W. Brandriss. 1972. An evaluation of transfer factor as immunotherapy for patients with lepromatous leprosy. *N. Engl. J. Med.* **287**: 1053-1059.
11. Graybill, J. R., J. Silva, Jr., R. H. Alford, and D. E. Thor. 1973. Immunologic and clinical improvement of progressive coccidioidomycosis following administration of transfer factor. *Cell. Immunol.* **8**: 120-135.
12. Catanzaro, A., L. Spitler, and K. M. Moser. 1973. Defective cellular immunity in patients with coccidioidomycosis. *Am. Rev. Respir. Dis.* **107**: 1084. (Abstr.)
13. Pappagianis, D., E. W. Putnam, and G. S. Kabazaski. 1961. Polysaccharide of *Coccidioides immitis*. *J. Bacteriol.* **82**: 714-723.
14. Rocklin, R. E., O. L. Myers, and J. R. David. 1970.

- An *in vitro* assay for cellular hypersensitivity in man. *J. Immunol.* **104**: 95-102.
15. Utz, J. P., J. E. Bennett, M. W. Brandriss, W. T. Butler, and G. J. Hill, II. 1964. Amphotericin B toxicity. Combined clinical staff conference at the National Institutes of Health. *Ann. Intern. Med.* **61**: 334-340.
  16. Winn, R. W., S. M. Finegold, and R. W. Huntington, Jr. 1965. Coccidioidomycosis with fungemia. In Coccidioidomycosis. Libero Ajello, editor. The University of Arizona Press, Tucson, Ariz. 93-109.
  17. Rapaport, F. T., H. S. Lawrence, J. W. Millar, D. Pappagianis, and C. E. Smith. 1960. Transfer of delayed hypersensitivity to coccidioidin in man. *J. Immunol.* **84**: 358-367.
  18. Spitler, L. E., A. S. Levin, and H. H. Fudenberg. 1973. Human lymphocyte transfer factor. *Methods Cancer Res.* **8**: 59-106.
  19. Lawrence, H. S. 1969. Transfer factor. *Adv. Immunol.* **11**: 169-266.
  20. Montgomery, J. R., M. A. South, and R. Wilson. 1973. Study of a gnotobiotic child with severe combined immune deficiency disease. *Clin. Res.* **21**: 118. (Abstr.)
  21. Griscilli, C., J. P. Revillard, H. Betuel, C. Herzog, and J. L. Touraine. 1973. Transfer factor therapy in immunodeficiencies. *Biomedicine (Paris)*. **18**: 220-227.
  22. Smith, C. E. 1940. Epidemiology of acute coccidioidomycosis with erythema nodosum. *Am. J. Public Health.* **30**: 600-611.