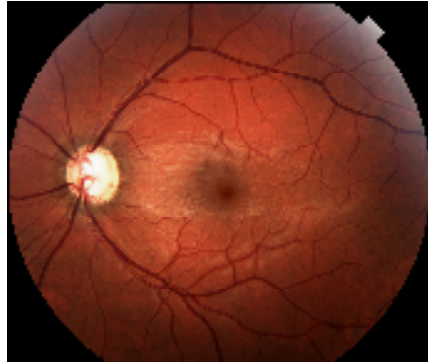
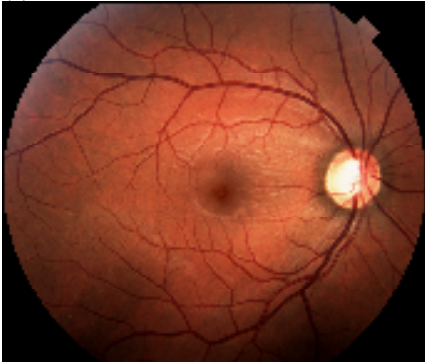
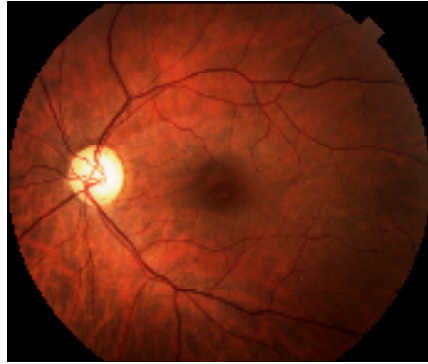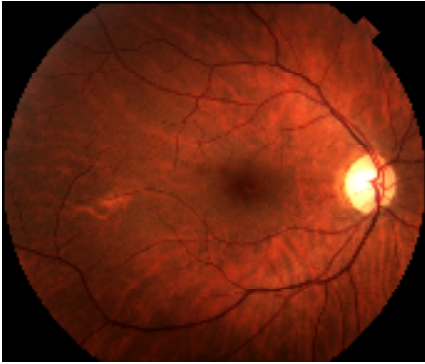


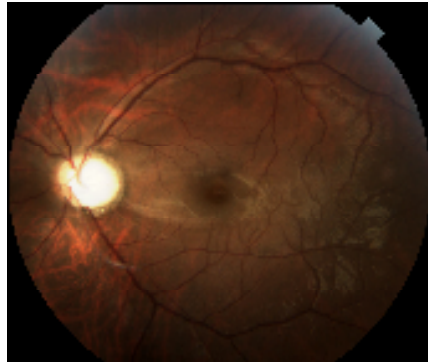
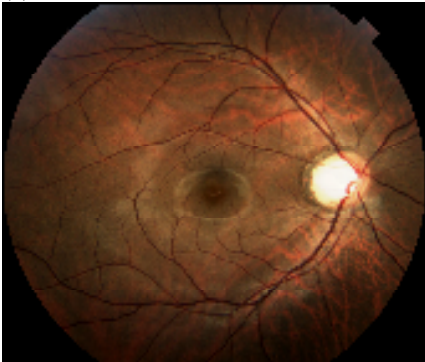
(a) Patient #1



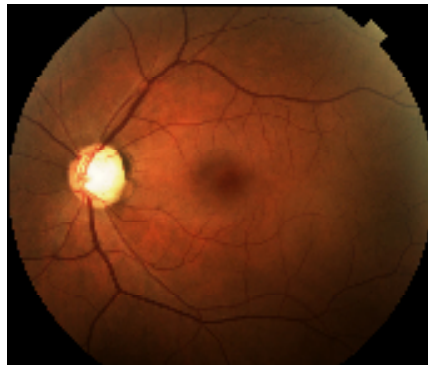
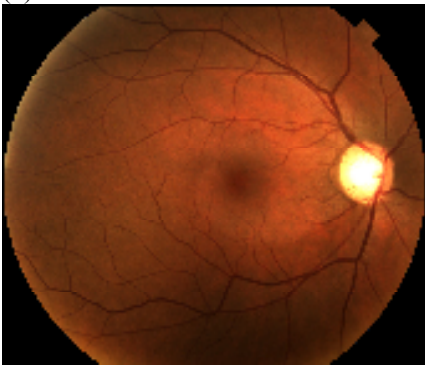
(b) Patient #2



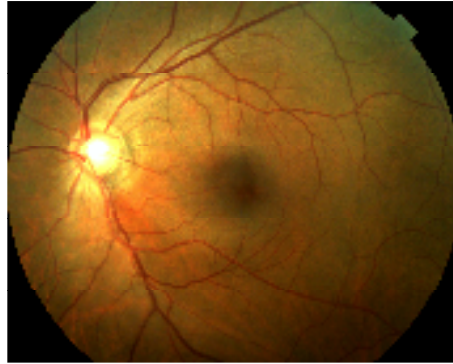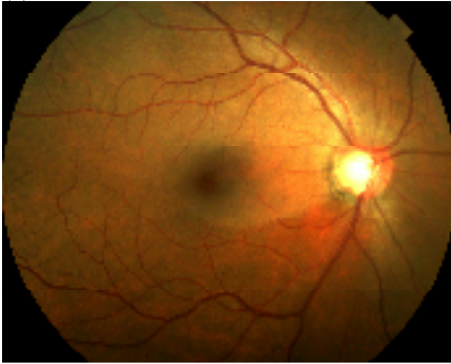
(c) Patient #3



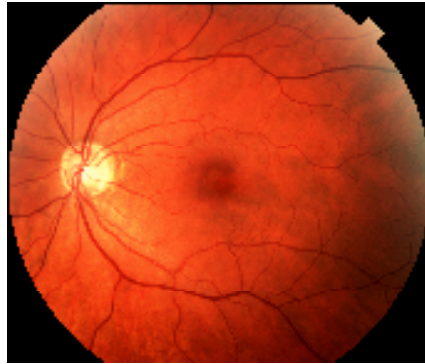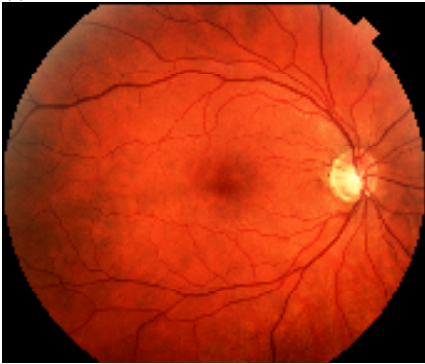(d) Patient #4



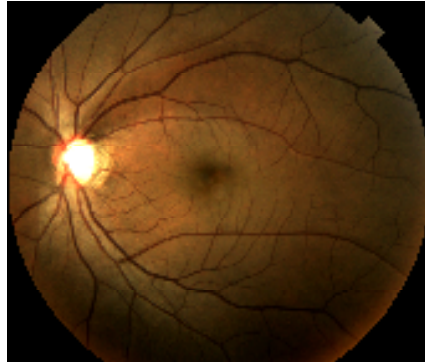
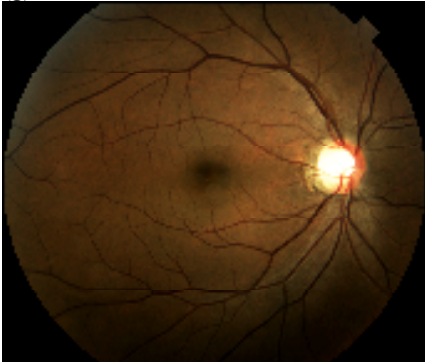
(e) Patient #5



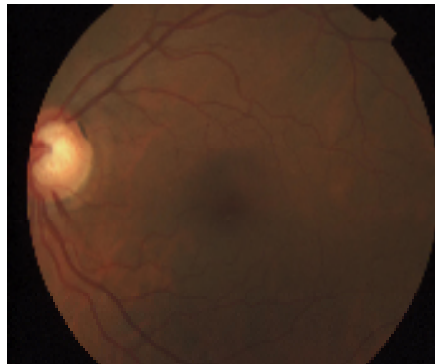
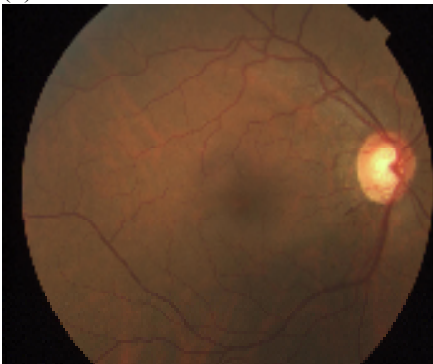
(f) Patient #6



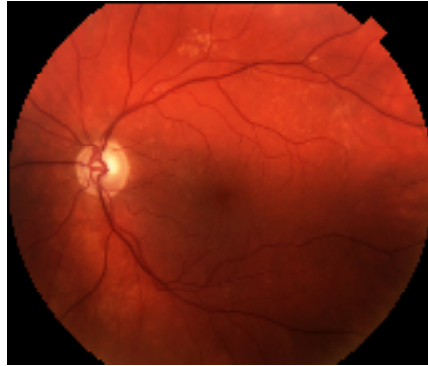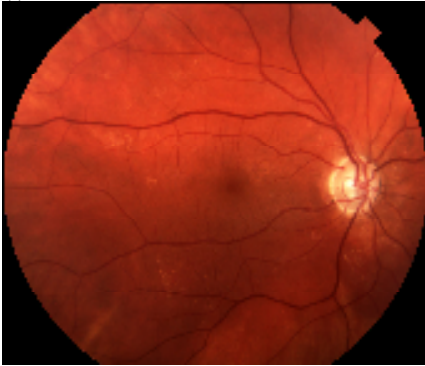(g) Patient #7



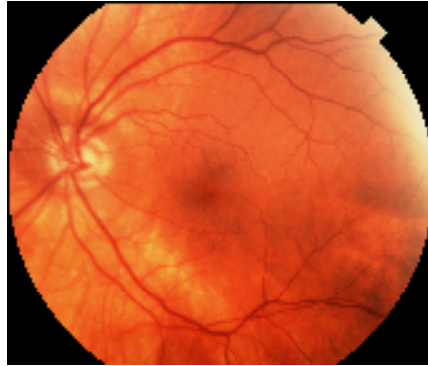
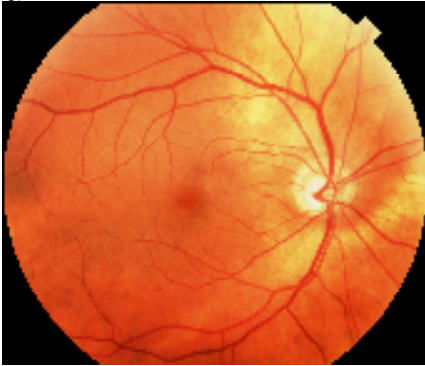
(h) Patient #8



(i) Patient #9



(j) Patient #10



Supplement Figure 1: Fundus photographs of both eyes of our 10 glaucoma patients