

Involvement of chromosome X in primary cytogenetic change in human neoplasia: Nonrandom translocation in synovial sarcoma

C. TURC-CAREL*, P. DAL CIN*, J. LIMON*, U. RAO*, F. P. LI†‡, J. M. CORSON§, R. ZIMMERMAN‡, D. M. PARRY‡, J. M. COWAN¶, AND A. A. SANDBERG*||

*Roswell Park Memorial Institute, Buffalo, NY 14263; †The Dana Farber Cancer Institute, Boston, MA 02115; ‡Department of Pathology, Brigham and Women's Hospital, Boston, MA 02115; ‡Clinical Epidemiology Branch, National Cancer Institute, Bethesda, MD 20892; and ¶Department of Human Genetics, Yale University School of Medicine, New Haven, CT 06510

Communicated by David Harker, November 26, 1986 (received for review June 24, 1986)

ABSTRACT A translocation that involves chromosome X (band p11.2) and chromosome 18 (band q11.2) was observed in short-term *in vitro* cultures of cells from five synovial sarcomas and one malignant fibrous histiocytoma. In four of these tumors, the translocation t(X;18)(p11.2;q11.2) was reciprocal. The two other tumors had complex translocations: t(X;18;21)(p11.2;q11.2;p13) and t(X;15;18)(p11.2;q23;q11.2). A translocation between chromosomes X and 18 was not detected in other histological types of soft tissue sarcoma. The X;18 rearrangement appears to characterize the synovial sarcoma and is the first description of a primary, nonrandom change in the sex chromosome of a human solid tumor.

The identification of nonrandom chromosomal changes in human leukemias is useful in diagnosis and classification, particularly of the acute leukemias (1). The alterations also provide clues to the genesis of these neoplasms. Cytogenetic analysis of human solid tumor cells is more complex, and progress has been slow. However, technical advances have yielded the karyotypes of some solid tumors, which can be utilized in analytical investigations of the etiology, diagnosis, and prognosis of these cancers (1).

Cytogenetic studies of soft tissue sarcomas in humans have remained largely unexplored. To date nonrandom primary changes have been found in two types of soft tissue sarcoma, liposarcomas (2) and certain subtypes of rhabdomyosarcoma (3, 4). Another soft tissue sarcoma, synovial sarcoma, has been analyzed extensively in the clinical and pathology literature, but its chromosome pattern has been described in only a single report (5).

Synovial sarcoma, according to the experience of Enzinger and Weiss (6), is the fourth most common type of soft tissue sarcoma. The neoplasm usually develops in adolescents and young adults, is more common in males than females, and has no racial bias.

A sex chromosome has not been shown to be involved in a consistent primary chromosomal change in any human neoplasm. In a study of the karyotype of soft tissue sarcomas in humans, we detected translocations affecting the X chromosome in four synovial sarcomas. The observation prompted a critical review of two soft tissue sarcomas (one poorly differentiated and one spindle cell) in which we had identified similar changes in the X chromosome (7). This report describes the findings of a more detailed histological and chromosomal analysis of these six tumors.

MATERIALS AND METHODS

Clinical Histories and Pathology. Patient 1. In September 1984, a 25-year-old white female underwent an above-knee

amputation for a synovial sarcoma in the calf. She received postoperative chemotherapy, but developed pulmonary metastases that were resected in April and October 1985. In January 1986, a third thoracotomy showed widespread metastases and chemotherapy was administered. The patient was alive at the time of the last follow-up (May 1986). Microscopic examination of sections from tissue removed at the time of amputation revealed a typical biphasic synovial sarcoma of the soft tissue of the left calf. The metastatic lesions showed a synovial sarcoma, lacking the typical biphasic pattern.

Patient 2. A 24-year-old black female had, in April 1984, a 3-month history of pain and swelling of the right foot. A needle biopsy was used to identify a synovial sarcoma, and a below-knee amputation was performed a month later. The tumor microscopically invaded adjacent tissues but no distant disease was found. She remained free of tumor until multiple pulmonary metastases were found 6 months later. She responded transiently to chemotherapy but died 18 months after the initial diagnosis of synovial sarcoma. Histologically the tumor was a high-grade synovial sarcoma of the monophasic spindle cell type. Immunohistochemical studies of the primary tumor were positive for the presence of keratin proteins.

Patient 3. A 34-year-old white female underwent a hemipelvectomy in January 1985 for a nontender mass of the proximal left thigh that extended to the acetabulum. Despite postoperative chemotherapy the patient developed massive metastases in the left lung, left humerus, and spine. In December 1985 she underwent a thoracotomy and resection of the left upper lobe of the lung. The patient was alive with extensive disease at the time of the last follow-up (May 1986).

Microscopic examination of the primary and metastatic lesions showed a high-grade spindle cell sarcoma. Keratin proteins were demonstrated in tumor cells of the left thigh mass by immunohistochemical examination. The final diagnosis was monophasic synovial sarcoma.

Patient 4. The patient is a 30-year-old black male who noted a 0.5-cm protuberance in the right proximal thenar eminence in October, 1980. X-rays were negative, and he was observed. The mass continued to enlarge, and an exploration of the right hand in 1981 revealed a tumor invading the thenar musculature and the median nerve. A partial excision was performed, and the diagnosis was a high-grade monophasic synovial sarcoma. The patient subsequently had a right forearm amputation that showed microscopic foci of residual synovial sarcoma. Three years later, he developed pulmonary metastases that were resected and treated with daunomycin and cyclophosphamide. He developed additional pulmonary nodules that have been surgically removed.

The publication costs of this article were defrayed in part by page charge payment. This article must therefore be hereby marked "advertisement" in accordance with 18 U.S.C. §1734 solely to indicate this fact.

||To whom reprint requests should be addressed at: Department of Genetics and Endocrinology, Roswell Park Memorial Institute, 666 Elm Street, Buffalo, NY 14263.

Immunohistochemical study of a pulmonary metastasis revealed the presence of keratin proteins within many of the tumor cells, as is characteristic of synovial sarcoma.

Patient 5. An 18-year-old white male underwent resection of a huge (2.8 kg) calcified retroperitoneal mesenchymal sarcoma in 1979 and received postoperative chemotherapy for a year. However, he required additional surgery for four recurrences in the chest and abdomen during the next 6 years. The patient died of progressive disease in September 1985. Tumors from the primary and several metastatic sites were similar in appearance and were classified initially as poorly differentiated soft tissue sarcoma (7). Immunohistochemical examination showed strong reactivity of spindle tumor cells for keratin proteins and led to a final diagnosis of monophasic synovial sarcoma.

Patient 6. A 59-year-old white female underwent a resection of a primary tumor of the abdominal wall in February 1984, that arose at a cholecystectomy incision site. Three local recurrences of the tumor were successfully excised in the next 10 months, and the patient has been free of disease during the ensuing 16 months of follow-up.

The primary tumor was initially diagnosed as a low-grade malignant fibrous histiocytoma. The local tumor recurrences were consistent with a spindle cell sarcoma, and this diagnosis was proposed for the primary tumors as well (7). Moreover, no keratin proteins were found on a further immunohistochemical examination of the tumor. The final diagnosis was malignant fibrous histiocytoma.

None of the six patients had a family history of cancer, though the mother of patient 6 died of a carcinoma of the liver.

Immunohistochemical Procedures. Immunoperoxidase studies were performed to detect keratin proteins in the tumors. The presence of keratin proteins in the cytoplasm of tumor cells is a characteristic property of synovial sarcoma and aids in the identification of monophasic synovial sarcoma (8). The following antibodies were used: a rabbit polyclonal antibody to human callus (Dako, Santa Barbara, CA) at a dilution of 1:100 (8); a rabbit polyclonal antibody to bovine muzzle keratin (Dako) at 1:100 (9); mouse monoclonal antibodies AE1 and AE3 (Boehringer Mannheim) at 1:200 (9); and a mouse monoclonal anticytokeratin antibody (catalog number 7650, Becton Dickinson), following instructions in the supplier's kit.

Chromosomal Analysis. G-banded metaphases were obtained from short-term cultures of cell suspensions after

collagenase disaggregation of surgical specimens from patients 1 and 3–6 according to a procedure described (10). In patient 2, xenografted tumors were generated in nude mice from a primary tumor specimen. The material from passage 2 was used for cytogenetic studies. The specimen was short-term cultured after its disaggregation with collagenase.

The dates on which the specimens were obtained and the origin of the specimens are presented in Table 1. After gross mechanical dissection, each specimen was incubated at 37°C for 24 hr in collagenase (GIBCO, 200 units/ml). The single-cell suspension was cultured in 20% (vol/vol) fetal calf serum (GIBCO) supplemented with McCoy's 5A modified medium (GIBCO) (1.5×10^6 cells per ml). Cultures with a high mitotic index were stopped by the addition of colcemid (GIBCO, 0.01 μ g/ml, 1–16 hr). Treatment with a hypotonic solution (KCl at 3 g/liter, EGTA at 0.2 g/liter, and Hepes at 4.8 g/liter, pH 7.4) was performed in the culture flasks at 37°C for 30–60 min. Cell suspensions obtained after mechanical removal were then fixed (10). Air-dried slides were G-banded by direct staining with Wright's stain (EM Science, 2.5 g/liter) or after denaturation with a trypsin solution (GIBCO). A minimum of 10 metaphases was analyzed. Chromosomal abnormalities are described according to the directions of International System for Human Cytogenetic Nomenclature, 1985 (11). Phytohemagglutinin-stimulated cultures of peripheral blood lymphocytes were obtained from patients 1, 3, and 6.

RESULTS

No cytogenetically normal cells were found in any of the tumor cultures. Every patient had clonal chromosomal changes, the details of which are presented in Table 1. The striking feature was the consistent involvement of chromosomes X and 18 in all the cases. A reciprocal translocation, t(X;18)(p11.2;q11.2), could be identified in patients 1 and 4, and complex reciprocal translocations, t(X;18;21)(p11.2;q11.2;p13) and t(X;15;18)(p11.2;q23;q11.2), could be identified in patients 2 and 3, respectively (Fig. 1). The reciprocal exchanges between the different chromosomes are schematically presented in Fig. 2. The chromosome patterns resulting from the complex translocation t(X;18;21) in patient 2 allowed the breakpoints to be assigned clearly at Xp11.2 and 18q11.2 (Fig. 2B). These clear-cut locations substantiated the assignment of the breakpoints in the simple translocations

Table 1. Specific details of cytogenetic data

Patient	Specimen		Source [†]	Procedure		Number of metaphases examined	Karyotype
	Diagnosis*	Date		Culture, hr	Colcemid, μ g/ml		
1	SS(B)	10/9/1985	M	2	2	20	56,X,t(X;18)(p11.2;q11.2),+4,+7,+9,+12,+12,+13,+15,+20,+21,+21,t(7;9)(p11.2;p13)
		1/16/1986	M	4	2	31	
2	SS(M)	1/25/1985	P [‡]	10	16	10	46,X,t(X;18;21)(p11.2;q11.2;p13)
3	SS(M)	12/11/1985	M	26	5	16	46,X,t(X;15;18)(p11.2;q23;q11.2),del(3)(p13p21)
4	SS(M)	8/6/1986	M	4	2	20	47,Y,t(X;18)(p11.2;q11.2),t(1;3)(p13;q12),-1,+der(1)t(1;?)p36.3;?,+der(2)t(2;12)(q21;q21.2),-11,+der(11)t(11;?)p15.5;?,del(12)(q21.2) [§]
5 [¶]	SS(M)	4/8/1985	R	2	16	20	47,Y,t(X;18)(p11.2;q11.2),inv(4)(p16q27),del(8)(p23)-17,+der(17)t(8;17)(q11.2;p13),+r
6 [¶]	MFH	4/1/1985	R	2	16	33	45,X,t(X;18)(p11.2;q11.2),del(5)(q13),t(7;11)(q36;q21),-13,-15,+t(13q15q),-16,+der(16)t(9;16)(p13;p12)

*SS(B), SS(M), and MFH refer to synovial sarcoma (biphasic), synovial sarcoma (monophasic), and malignant fibrous histiocytoma, respectively.

[†]P, R, and M: primary, recurrent, and metastatic tumor, respectively.

[‡]Xenografted tumor in nude mice (second passage).

[§]Karyotype of the stemline.

[¶]Patients 1 and 2 in ref. 7.

t(X;18) and also prompted us to reanalyze data from patients 5 and 6 (7).

We initially described in patients 5 and 6 a common translocation between chromosomes X and 18 but with the breakpoints at Xq13 and 18p11 [t(X;18)(q13;p11)]. Further comparison of the markers derived from the translocations in patients 5 and 6 with those derived from the translocation observed in patients 1 and 4 [t(X;18)(p11.2;q11.2)] led to the conclusion that the translocations involving X and 18 were identical in these four patients. Therefore, we reassigned the breakpoints in patients 5 and 6 to Xp11.2 and 18q11.2 (Fig. 1). In patients 1, 3, and 6 phytohemagglutinin-stimulated blood lymphocytes had normal karyotypes.

DISCUSSION

The sarcomas from our six patients showed clonal translocations between chromosomes X and 18. The breakpoints appeared identical and were Xp11.2 and 18q11.2 (Fig. 1). A simple reciprocal translocation, t(X;18)(p11.2;q11.2), was present in four cases. Two other cases exhibited complex translocations, t(X;15;18)(p11.2;q23;q11.2) and t(X;18;21)(p11.2;q11.2;p13). This latter translocation was the sole cytogenetic rearrangement in patient 2 and can be considered as a primary karyotypic change. The involvement of chromosomes X and 18 in the translocations is tumor specific and

was not detected in the constitutional karyotype of three of our patients. Confirmation of the breakpoints can be obtained by the use of molecular probes mapped to the involved regions of Xp and 18q.

The change involving the X chromosome was observed in five patients with synovial sarcoma and in one patient with malignant fibrous histiocytoma. The change was found in both major types of synovial sarcoma, i.e., in the classical biphasic type (patient 1) and in the monophasic spindle cell type (patients 2–5). In the four patients of monophasic synovial sarcoma, the diagnosis was suggested by histologic examination and was confirmed in each by the immunohistochemical demonstration of keratin proteins in the malignant tumor cells as is characteristic of these tumors (12). No keratin proteins were demonstrable in the malignant fibrous histiocytoma (patient 6), as reported (8).

In the literature, the only cytogenetic study on a synovial sarcoma showed a deletion of chromosome 1 and a translocation between the long arms of chromosomes 2 and 9, but no changes involving chromosomes X and 18 (5). Studies of other soft tissue sarcomas have also not shown clonal abnormalities of chromosomes X and 18. Nonrandom involvement of chromosomes 2, 3, and 13 has been found in rhabdomyosarcoma (3, 4) and chromosomes 12 and 16 in myxoid liposarcoma (2).

The translocation involving Xp11.2 and 18q11.2 appears to characterize at least five synovial sarcomas in unrelated patients and to constitute a tumor-related (primary) chromosome change. To our knowledge, this is the first example of a nonrandom change involving a sex chromosome in a specific form of cancer. In the remaining patient (patient 6) in our series, the diagnosis was another form of soft tissue sarcoma, a malignant fibrous histiocytoma. Disagreement and errors in subclassification of soft tissue sarcoma are common and were found in one-third of the 216 patients in a histopathology review (12).

Immunohistochemical studies can improve diagnostic accuracy. Patient 6 showed no keratin proteins to support the diagnosis of a synovial sarcoma, but only a small specimen was available for study. Nevertheless this case raises the possibility that a few tumors not classified as synovial sarcomas by conventional criteria may also bear a t(X;18) rearrangement.

Clonal translocations involving the X chromosome have been tabulated in a wide variety of human solid tumors (7). Though the breakpoints on the X chromosome of these tumors clustered preferentially in bands Xp22, Xq22, and Xq28, the translocated fragments of the X chromosome were rearranged to diverse autosomes without consistent patterns. In addition, the chromosome changes in these tumors showed no correlation with histology or site of the primary tumor.

Detection of the X;18 translocation in additional synovial sarcomas, but not in other tumors, can help establish the finding as a diagnostic tool. The observation may also be useful because the diagnosis of synovial sarcoma is difficult in some cases, with poorly differentiated histology.

Until recently none of the known and expressed oncogenes had been mapped to the human X chromosome (13), and it has been suggested that the mammalian X chromosome was deprived of oncogenes and related genes by a process of evolutionary preadaptation (14). However, a gene in the *RAF* oncogene group, *ARAF1*, has now been mapped to the human X chromosome between Xp21 and Xq11 (15), a region that encompasses the breakpoint on chromosome X in synovial sarcoma. Whether this very newly described oncogene, which is actively transcribed in human T cells, fetal liver cells, and HL-60 cells (15), plays a role in the pathogenesis of synovial sarcoma merits study. No oncogene has been mapped to the other consistent breakpoint in synovial sarcoma, 18q11.2. However, the *YES1* oncogene and the

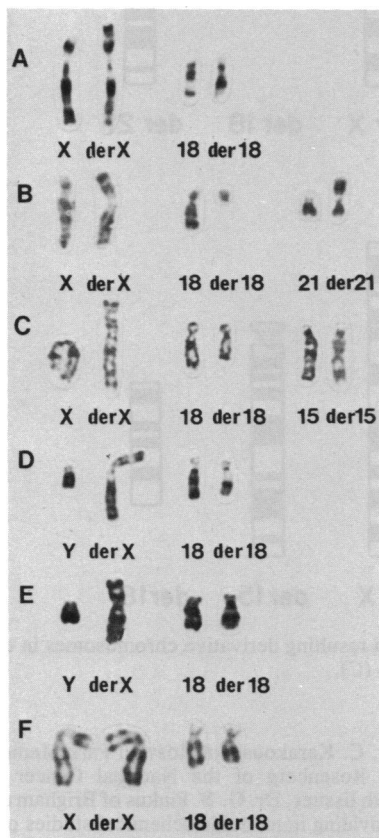


FIG. 1. G-banded partial karyotypes showing the involvement of the X chromosome (derX) in tumor cells from five patients with synovial sarcoma (patients 1, 2, 3, 4, and 5; A, B, C, D, and E, respectively) and one patient with malignant fibrous histiocytoma (patient 6; F). An X chromosome is involved in simple reciprocal translocations with chromosome 18 (der18) in patients 1, 4, 5, and 6 (A, D, E, and F, respectively). An X chromosome is involved in complex translocations with chromosome 21 (der21) in addition to chromosome 18 in patient 2 (B) and with chromosome 15 (der15) in addition to chromosome 18 in patient 3 (C).

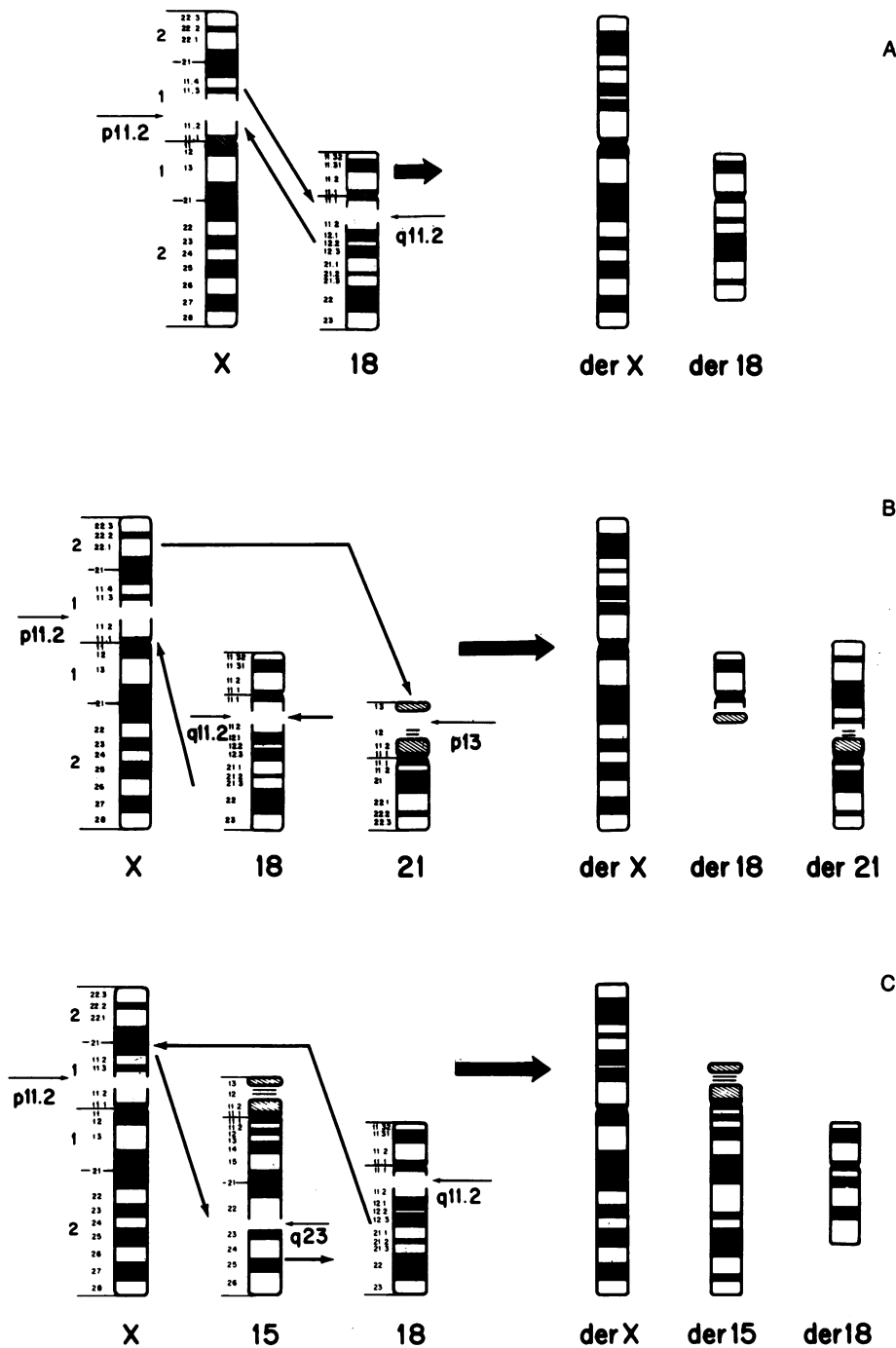


FIG. 2. Diagram showing the breakpoints (short arrows), exchanges (long arrows) and resulting derivative chromosomes in translocations $t(X;18)(p11.2;q11.2)$ (A), $t(X;18;21)(p11.2;q11.2;p13)$ (B), and $t(X;15;18)(p11.2;q23;q11.2)$ (C).

BCL2 sequence are located distally to 18q11.2, i.e., at 18q21 (16). The *ERV1* oncogene has also been assigned to chromosome 18 (17).

Another gene possibly involved in the development of synovial sarcoma is the erythroid-potentiating activity/tissue-inhibitor of metalloproteinase gene (*EPA/TIMP* gene), which also has been mapped to Xp11.1-Xp11.4 (18). The tissue inhibitor of metalloproteinase (*TIMP*) is an inhibitor of collagenase and other tissue metalloproteinases and has been purified from pig synovium among other sources (19). The physiological properties and regulation of this gene are still poorly understood. As in the case of *ARAF1*, the role of the *EPA/TIMP* gene in synovial sarcoma is yet to be established.

We thank Dr. C. Karakousis of Roswell Park Memorial Institute and Dr. S. A. Rosenberg of the National Cancer Institute for supplying us with tissues, Dr. G. S. Pinkus of Brigham and Women's Hospital for providing immunohistochemical studies of the tumors, Miss Kathleen Carr for excellent technical assistance, and Mrs. Anne Marie Dulinawka and Mrs. Sharon Zolnowski for secretarial help. C.T.-C. is a Fellow of the Association pour la Recherche sur le Cancer (ARC), Villejuif, France. This study was supported in part by Contracts NO1-CP-21032, NO1-CP-21031 and NO1-CP-21037 from the National Cancer Institute.

1. Sandberg, A. A. (1985) *CRC Crit. Rev. Clin. Lab. Sci.* **22**, 219-274.
2. Turc-Carel, C., Limon, J., Dal Cin, P., Rao, U., Karakousis, C. & Sandberg, A. A. (1986) *Cancer Genet. Cytogenet.* **23**, 291-300.

3. Trent, J. M., Thompson, E., Meltzer, P., Casper, J. & Fogh, J. (1985) *Cancer Genet. Cytogenet.* **16**, 189–198.
4. Turc-Carel, C., Lizard-Nacol, S., Justrabo, E., Favrot, M., Philip, T. & Tabone, E. (1986) *Cancer Genet. Cytogenet.* **20**, 361–362.
5. Becher, R., Wake, N., Gibas, Z., Ochi, H. & Sandberg, A. A. (1984) *J. Natl. Cancer Inst.* **72**, 823–831.
6. Enzinger, F. M. & Weiss, S. W. (1983) *Soft Tissue Tumors* (Mosby, St. Louis, MO), pp. 519–549.
7. Limon, J., Dal Cin, P. & Sandberg, A. A. (1986) *Cancer Genet. Cytogenet.* **23**, 87–91.
8. Corson, J. M., Weiss, L. M., Banks-Schlegel, S. P. & Pinkus, G. S. (1984) *Human Pathol.* **15**, 615–621.
9. Pinkus, G. S., Etheridge, C. L. & O'Connor, E. M. (1986) *Am. J. Clin. Pathol.* **58**, 269–277.
10. Limon, J., Dal Cin, P. & Sandberg, A. A. (1986) *Cancer Genet. Cytogenet.* **23**, 305.
11. Harnden, D. G. & Klinger, H. P., eds. (1985) *ISCN 1985: An International System for Human Cytogenetic Nomenclature*; Cytogenet. Cell Genet. (Karger, Basel).
12. Presant, C. A., Russell, W. O., Alexander, R. W. & Fu, Y. S. (1986) *J. Clin. Oncol.* **4**, 1658–1661.
13. Goodfellow, P. N., Davies, K. E. & Ropers, H. H. (1985) *Cytogenet. Cell Genet.* **40**, 296–352.
14. Hameister, H. & Adolph, S. (1986) *Hum. Genet.* **72**, 241–244.
15. Huebner, K., Ar-Rishdi, A., Griffin, C. A., Isobe, M., Kozak, C., Emanuel, B. S., Nagarajan, L., Cleveland, J. L., Bonner, T. I., Godsborough, M. D., Croce, C. M. & Rapp, U. (1986) *Proc. Natl. Acad. Sci. USA* **83**, 3934–3938.
16. Naylor, S., Lalonel, J.-M. & Shaw, D. J. (1985) *Cytogenet. Cell Genet.* **40**, 242–267.
17. O'Brien, S. J., Bonner, T. L., Cohen, M., O'Connell, C. & Nash, W. J. (1983) *Nature (London)* **303**, 74–77.
18. Huebner, K., Isobe, A., Gasson, J. C., Golde, D. W. & Croce, C. M. (1986) *Am. J. Hum. Genet.* **38**, 819–826.
19. Bunning, R. A. D., Murphy, G., Kumar, S., Phillips, P. & Reynolds, J. J. (1984) *Eur. J. Biochem.* **139**, 75–80.