

# Graft-vs.-host disease elicits expression of class I and class II histocompatibility antigens and the presence of scattered T lymphocytes in rat central nervous system

(blood–brain barrier/autoimmunity/microglial cell/pericyte/astrocyte)

WILLIAM F. HICKEY\*† AND HIROMITSU KIMURA‡

\*Laboratory of Neuropathology, Department of Pathology and Laboratory Medicine, and ‡Department of Surgery, School of Medicine, University of Pennsylvania, Philadelphia, PA 19104

Communicated by Eliot Stellar, December 5, 1986 (received for review June 6, 1986)

**ABSTRACT** In the central nervous system (CNS) of healthy animals, T lymphocytes and cellular expression of major histocompatibility complex (MHC) gene products are virtually undetectable. Yet, in CNS immunological diseases, such as multiple sclerosis in humans, these constituents of the immune response must appear by some mechanism. Immunohistochemical examination of the CNS of F<sub>1</sub> hybrid rats following induction of graft-vs.-host disease by parental lymphocytes revealed extensive parenchymal and vascular expression of host class I and II (Ia) MHC-encoded cell surface molecules. In addition, occasional scattered T lymphocytes were detected in the CNS of these animals. F<sub>1</sub> hybrid rats reconstituted during the neonatal period with bone marrow cells from one parental strain also expressed increased levels of MHC antigens in the CNS. Thus, evidence is presented that the “immunological privilege” of the CNS seems to decrease or disappear during a strong systemic immune response such as graft-vs.-host disease. These findings may have important implications concerning the mechanism of induction of human CNS immunological diseases.

In the course of evolution the brain has become isolated behind the blood–brain barrier from the perturbations affecting other organs (1, 2). Although this permits the maintenance of a relatively constant milieu in which the nervous system can function, it presents a potential problem if the immune system is to recognize and react to non-self- and neoantigens occurring within the central nervous system (CNS) behind the blood–brain barrier. In a state of health, the CNS is believed to be an immunologically privileged site which does not participate in the immune reactions of the rest of the body, and in which identifiable components of the immune system are rare or nonexistent (3–8). However, in disease, mechanisms must be activated that allow specific immunologically mediated reactions to occur in the brain and spinal cord. Multiple sclerosis is a human disease in which the normal control mechanisms appear to malfunction; the immune system attacks normal CNS components in the absence of any documented foreign threat. One of the questions central to neuroimmunology and our understanding of human autoimmune neurological diseases concerns the manner in which antigen-specific T lymphocytes are able to pass the blood–brain barrier, enter the CNS, and respond to a specific antigen.

Antigen recognition by T cells is restricted by cell surface molecules encoded in the major histocompatibility complex (MHC). For activation of helper T cells, antigen-presenting cells exhibiting cell surface class II molecules (e.g., the Ia molecule) are needed (9, 10); cytotoxic T cells require class I molecules for recognition of their specific antigens (11). Yet

only rare endogenous brain cells express these molecules normally, and then weakly at best (7, 8, 12, 13).

*In vitro* it has been demonstrated that it is possible to induce both class I and II MHC molecules on astrocytes, oligodendroglial cells, and microglial cells by exposure to  $\gamma$ -interferon (14); further, astrocytes in tissue culture can express Ia, elaborate interleukin 1, and present a CNS antigen to helper T cells (15, 16). In the living animal, induction of class I and II molecules on the surface of CNS cells and infiltration of the nervous system by lymphocytes has required the administration of CNS auto-antigens, neurotropic virus, or direct injection into the CNS of foreign tissue or  $\gamma$ -interferon (3, 8, 14, 15, 17, 18). While extensive MHC antigen expression on cells in the brain and T-lymphocyte infiltration has been documented in multiple sclerosis (19, 20), none of the mechanisms that are currently known to cause such changes experimentally have been shown to be active in the human disease.

Strong, sustained systemic immune reactions, such as graft-vs.-host disease (GvHD), bear numerous similarities to certain spontaneous human autoimmune illnesses (21–23). In seeking an alternative approach for the study of lymphocyte immigration and antigen presentation and recognition in the CNS, we have examined GvHD as an experimental system. This model employs no nervous system antigen, does not entail a mechanical disruption of the blood–brain barrier, and does not clinically involve the brain as a known target organ, but does induce a strong generalized immune response as might occur naturally under some circumstances such as a systemic viral infection (22, 24).

## MATERIALS AND METHODS

**Rats.** The animals used were the F<sub>1</sub> hybrids of Lewis (RT1<sup>l</sup>) and DA (RT1<sup>av1</sup>) strains of rat; these (L × DA)F<sub>1</sub> rats are highly susceptible to GvHD (25).

Table 1 details the manipulations of the individual animals studied. Some rats were neonatally inoculated via the anterior facial vein with  $5 \times 10^7$  bone marrow cells of the Lewis parental strain. All rats were 4–6 months old when used. GvHD was induced by injection, via the tail vein, of  $5\text{--}40 \times 10^7$  parental thoracic duct lymphocytes. Selected animals were given sublethal irradiation prior to GvHD induction in order to potentiate disease severity. Control rats were subjected to the same manipulations as test animals, save the induction of GvHD by injection of parental cells. All animals were observed for the development of clinical signs of GvHD and were killed 9–12 days after GvHD induction, at a time

Table 1. Animal manipulations and results

Rat identification number*	Neonatal bone marrow inoculation	Pre-GvHD irradiation (450 rads)	Source and number ( $\times 10^{-6}$ ) of cells injected i.v. to induce GvHD	Class I expression	Ia on endothelium	Ia on parenchymal cells	T cells in CNS parenchyma
<i>Control</i>							
15	—	—	(L $\times$ DA)F <sub>1</sub> , 50	0	0	0	0
17	—	—	(L $\times$ DA)F <sub>1</sub> , 250	1	0	0	0
18	—	—	—	1	0	0	0
<i>Manipulated, non-GvHD<sup>†</sup></i>							
1	+	—	—	0	0	2	0
4	+	+	—	1	0	2	0
6	—	+	—	1	0	0	0
8	+	+	—	1	0	2	0
10	+	—	—	1	1	2	0
<i>GvHD</i>							
2	+	—	Lewis, 50	2	2	3	2
3	+	+	Lewis, 50	3	2	3	2
5	—	+	Lewis, 50	2	2	3	2
7	+	+	Lewis, 50	3	2	3	1
9	+	—	Lewis, 50	2	1	2	2
11	—	—	Lewis, 400	3	2	3	2
12	—	—	Lewis, 50	2	1	2	1
13	—	—	Lewis, 400	3	2	3	2
14	—	—	Lewis, 50	2	1	2	2
16	—	—	Lewis, 400	3	2	3	2
19	—	—	DA, 200	2	1	2	2
20	—	—	DA, 50	2	1	2	1

Details of the grading for the histological findings are given in *Methods*.

\*All rats used were (L  $\times$  DA)F<sub>1</sub> hybrids.

<sup>†</sup>These rats were subjected to various manipulations, but not to GvHD induction; GvHD was not clinically noted in this group.

when the acute phase of the disease was approaching its peak. Following vascular perfusion with 250 ml of cold Dulbecco's phosphate-buffered saline, tissue from the lower spinal cord, brainstem, and cerebellum was removed and rapidly frozen for immunohistological examination.

**Immunohistochemical Staining.** The methods employed for immunoperoxidase and immunofluorescence labeling of CNS tissue have been detailed (17, 26). In brief, 5- $\mu$ m-thick frozen tissue sections were fixed for 1–2 min in absolute methanol at  $-25^{\circ}\text{C}$ . After fixation, they were immediately rinsed in cold buffer and the appropriate primary antibody was applied to the tissue. For immunoperoxidase staining, the avidin-biotin system was employed (26). For fluorescence studies to exhibit double labeling, rhodamine- or fluorescein isothiocyanate-conjugated antiserum specific for the primary antibody was used (17).

**Antibodies and Antiserum.** The following well-characterized murine monoclonal antibodies directed against rat MHC-encoded antigens or T-lymphocyte surface markers were used: OX-6, specific for a framework determinant of the rat Ia molecule (27); OX-3, identifying an epitope in the variable region of the Ia molecule of Lewis, but not DA, rats (27); OX-19, detecting an antigen on the surface of all rat T cells (28, 29); OX-18, detecting class I antigens of all rat strains (29); I1-69, recognizing Lewis, but not DA, class I antigens (30); W3/25, identifying T lymphocytes with helper function, as well as activated macrophages (29, 31); OX-42, labeling microglia, dendritic cells, macrophages, and granulocytes (32); and OX-8, a T-cell-specific antibody indicating those with a suppressor/cytotoxic function (29). A rabbit antiserum against glial fibrillary acidic protein (GFAP), an astrocyte-specific intermediate-filament protein, was used to identify astrocyte cell bodies and processes (33).

**Interpretation of Results.** The stained CNS tissue sections were graded in a semiquantitative manner for each of the features being sought. Grading for T lymphocytes was as follows: 0 when none were seen, 1 when rare single cells were found, 2 when scattered groups of two or three cells were

detected, and 3 when larger groups were noted. For all other features, if no expression was detected, a grade of 0 was given; if only rare, single positive cells were found, the grade was 1; if small groups or clusters of positive cells were noted, the grade was 2; a grade of 3 was assigned if large clusters or confluent fields of positive cells were present.

## RESULTS

GvHD was found to induce strong expression of both class I and Ia antigens at all levels of the CNS studied (Fig. 1). Scattered T lymphocytes were also observed in the brain and spinal cord parenchyma; rarely, small lymphocyte clusters were also noted (Fig. 2). Morphological examination of hematoxylin/eosin-stained tissue sections of the CNS of rats with GvHD revealed no evidence of structural alteration or detectable infiltrating cells. Thus, the nature of the CNS changes cannot be termed "inflammatory." The results of the study are presented in Table 1.

Within the spinal cord, cerebellum, and brainstem, endothelial cells were the strongest expressors of class I molecules (Figs. 1A and 3A). This antigen was found on nearly all endothelial cells regardless of vessel size, as well as on numerous parenchymal cells. Class II (Ia) expression was most extensive on parenchymal cells (Figs. 1B and 4); endothelial expression was limited to scattered smaller vessels, and Ia was not present on all endothelial cells in a given vessel (Fig. 3B). Astrocytes in the CNS of rats with GvHD were enlarged, with prominent cytoplasmic processes. Immunofluorescence double-labeling (17) revealed rare astrocytes positive for Ia and class I molecules, but cells immunohistochemically identified as astrocytes by their cytoplasmic glial fibrillary acidic protein comprised only a very small percentage of the cells expressing these MHC molecules. The Ia-positive astrocytes in GvHD were  $<0.1\%$  of the Ia-positive cells, a frequency similar to such astrocytes occurring in experimental allergic encephalomyelitis (EAE), an animal model of multiple sclerosis (17).

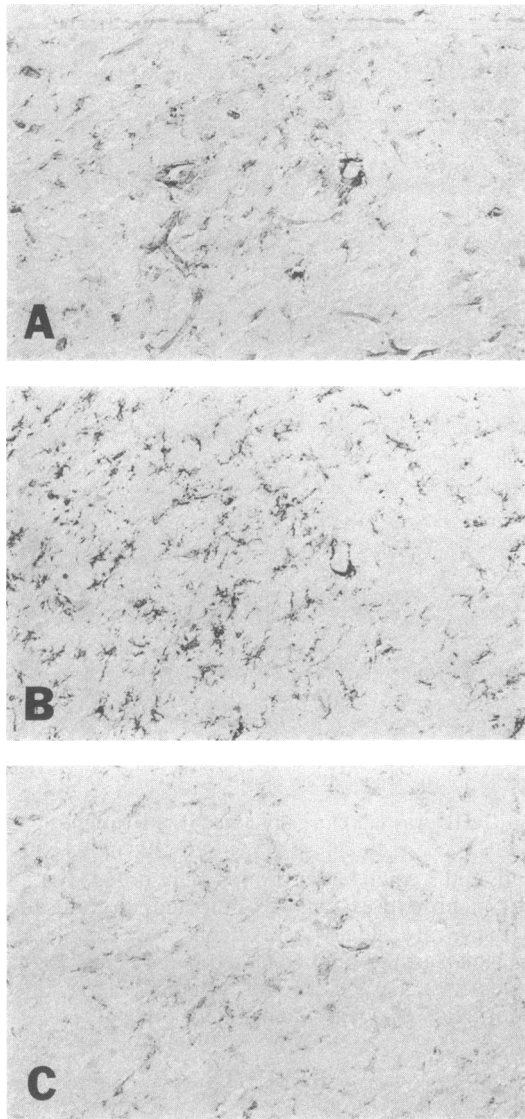


FIG. 1. The same area in three consecutive tissue sections of spinal cord from a rat with severe GvHD. (A) Vascular and parenchymal positivity for class I antigens. (B) Ia positivity, extensive on parenchymal cells and around one blood vessel. (C) W3/25 positivity on parenchymal and perivascular cells in the same distribution as seen for Ia. (Immunoperoxidase staining;  $\times 200$ .)

In extensive areas of the neural parenchyma, multiple nonastrocytic cells with an arborized shape were positive for Ia; in adjacent tissue sections, cells of a similar morphology and positive for the molecular marker W3/25 were present in the same areas (Fig. 1 B and C). This dual positivity with Ia and W3/25 is found on macrophages and antigen-presenting cells (31). The majority of the CNS parenchymal cells expressing MHC-encoded antigens in rats with GvHD appear to be activated microglia. The microglia, identified by the antibody OX-42, have a staining pattern that is coextensive with Ia positivity in the adjacent tissue section (Fig. 5). In addition, it was frequently observed that cells lying immediately external to the vessel and having cytoplasmic extensions in a perivascular arrangement were strongly positive for Ia (Fig. 3B); the origin and function of these pericytes could not be determined.

Examination of the CNS of animals 19 and 20 allowed the conclusion that the Ia molecules expressed by these cells were of host origin, since the detected Ia molecule contained an epitope, recognized by the monoclonal antibody OX-3, that is possessed by Lewis, but not DA, rats (27). In these two rats the transferred GvHD-inducing cells could not have been the

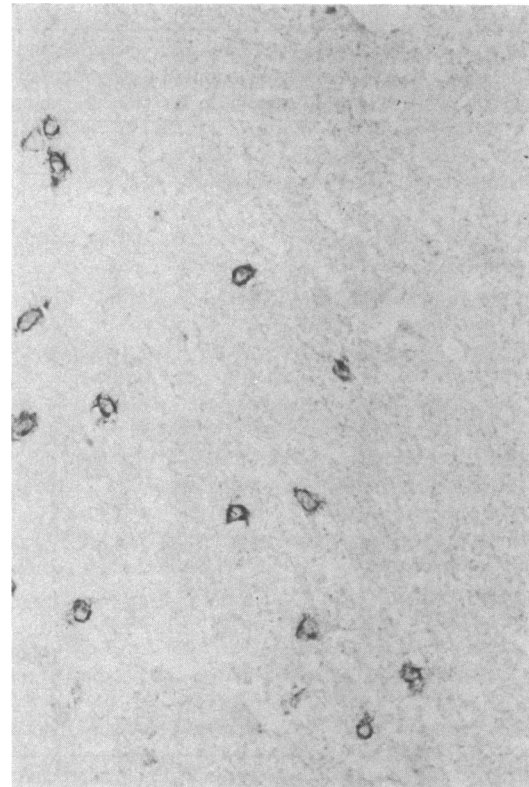

FIG. 2. A cluster of T lymphocytes found in the CNS of a rat with GvHD. In most animals clusters were smaller, and positive cells were sparsely scattered in the parenchyma. (Immunoperoxidase staining;  $\times 450$ .)

source of this antigen. Likewise, in these rats the monoclonal antibody Il-69, specific for Lewis-derived class I antigens (30), was positive, indicating that this antigen was also of host origin.

Scattered single or small groups of two to three lymphoid cells were detected with the pan-T-cell antibody OX-19 (Fig. 2). Of the lymphocytes found in the CNS, some were of the W3/25 T-helper phenotype while others expressed the cytotoxic/suppressor OX-8 phenotype (29). Overall, these cells were rare, typically being in less than one in ten  $\times 400$  fields. Their presence was not necessarily associated with areas of the CNS parenchyma exhibiting strong MHC antigen expression. The origin (host or graft) of these lymphocytes and their antigen specificity is unknown.

It was evident that neither neonatal bone marrow inoculation nor sublethal irradiation was required for development of GvHD or immune activation of the CNS. Nevertheless, irradiated F<sub>1</sub> animals did develop a more severe disease and more extensive MHC antigen expression than nonirradiated F<sub>1</sub> rats receiving the same number of parental cells.

Of interest is the observation that animals neonatally reconstituted with Lewis bone marrow, without irradiation or GvHD induction, demonstrated low but detectable expression of Ia on scattered clusters of cells in the CNS, typically distributed in perivascular arrangements (Fig. 4). This level of expression, while well below that seen in the GvHD rats, exceeded that seen in the negative controls that were not reconstituted. In addition, this Ia positivity was not seen in rats given only irradiation or injection of syngeneic lymphocytes.

## DISCUSSION

The results show that a strong systemic immune response can induce extensive expression of the MHC class I and class II (Ia) molecules on cells in the CNS. In other studies, GvHD has been shown to induce class II expression on epithelial

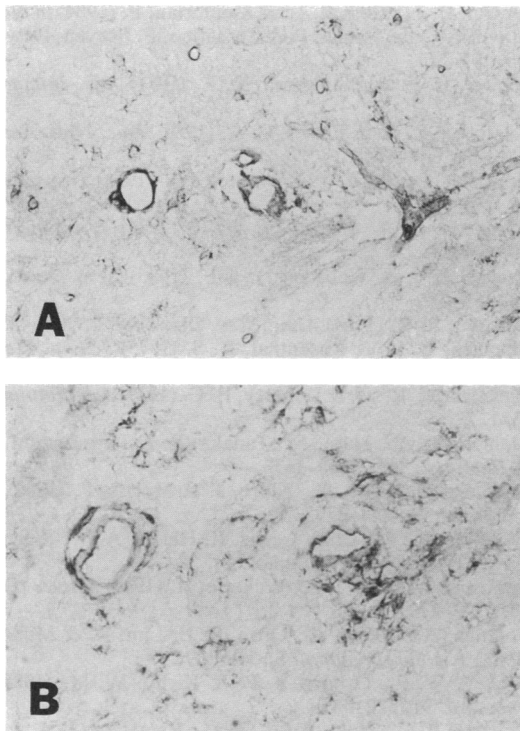


FIG. 3. Endothelial cell positivity for class I (A) and Ia (B) molecules in an animal with GvHD. Class I positivity is diffuse and continuous on the endothelium of most vessels regardless of size. Ia positivity is seen on pericytes and is focally positive on the endothelium of medium-size parenchymal vessels. (Immunoperoxidase staining; A  $\times 360$ , B  $\times 450$ .)

cells in gut, skin, and other tissues that do not normally exhibit it (34). GvHD induced in neonatal animals affects the development of normal cerebellar morphology and neuronal maturation (35); however, the mechanism by which this occurs remains unknown. It is possible that a connection exists between the elaboration of class I or II molecules on CNS parenchymal cells and the production of neuronal migration abnormalities during a vulnerable period of differentiation. Yet, in the adult rat, this change does not produce any signs of neurological illness.

The brain purportedly is protected behind the blood-brain barrier from participation in systemic immune reactions such as GvHD. Our data indicate that not only does the CNS participate, it is also subject to the presence of detectable numbers of lymphocytes. This occurs without evidence of inflammation, mechanical disturbance of the blood-brain barrier, or administration of a nervous system-derived antigen. Thus, the immunological isolation of the CNS appears to decrease or disappear during systemic immune reactions. Whether this occurs in other conditions, such as viral infection, remains to be demonstrated.

The cellular participants in the immunological activation of the nervous system by GvHD are not fully defined. The microglial cell and pericyte are most probably the principal cells in the CNS parenchyma expressing Ia molecules. The positivity of these cells with both anti-Ia and W3/25 antibodies strongly suggests this, since such dual positivity has been reported for macrophages (31), cells closely akin to microglial cells. This view is furthered by a recent study (12) of EAE, in which cells having the same dendritic morphology and cell surface Ia, W3/25 positivity have been presumptively identified as microglia. Although the identification of cells as microglia as opposed to infiltrating macrophages/monocytes might be questioned in that study of a developing inflammatory reaction in the CNS (12), in

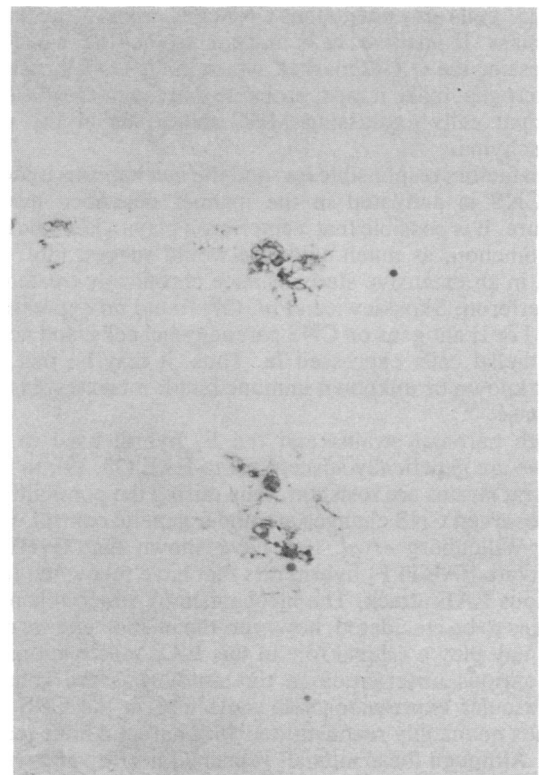

FIG. 4. Small groups of Ia-positive perivascular cells found in the CNS parenchyma of rats neonatally reconstituted with parental bone marrow to produce tolerance. This animal (no. 10) showed no signs of GvHD, and GvHD had not been induced in the rat as an adult. (Immunoperoxidase staining;  $\times 270$ .)

GvHD no such pervasive inflammation occurs in the CNS parenchyma, making it more likely that the branching Ia<sup>+</sup>,

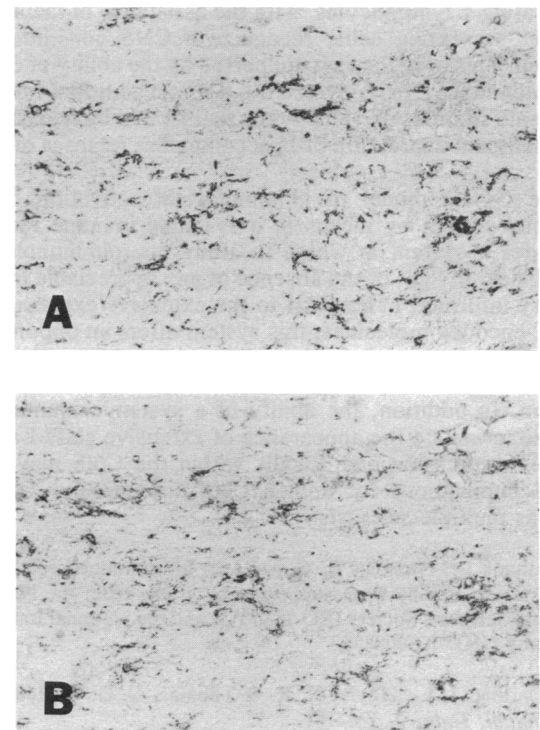


FIG. 5. The same area in adjacent tissue sections stained with antibodies OX-42 (A), to identify microglia, and OX-6 (B), to show Ia expression. Positivity is coextensive and largely superimposable. (Immunoperoxidase staining;  $\times 200$ .)

W3/25<sup>+</sup> cells are endogenous CNS cells. Finally, the fact that the class II-positive cells appear to be the same cells expressing the OX-42 marker, which in the CNS is restricted to microglia, make it most probable that the microglia are the principal cells expressing MHC molecules in the neural parenchyma.

The factors responsible for, and the mechanisms by which, the CNS is activated in the manner described here are obscure. It is possible that  $\gamma$ -interferon plays a key role in this phenomenon, as much evidence would suggest (36). However, in an extensive study of mice chronically treated with  $\gamma$ -interferon, Skoskiewicz *et al.* (37) found no expression of class I or II antigens on CNS parenchymal cells, and no CNS endothelial cells expressed Ia. Thus, it may be that some other known or unknown immune factor mediates this CNS response.

Both parental strains and the F<sub>1</sub> hybrid used in these studies are genetically susceptible to EAE (38, 39), to which most rat strains are resistant, thus raising the possibility that the observed CNS changes are under genetic control. In this vein, Willenborg *et al.* (39) have shown that GvHD can reactivate EAE in F<sub>1</sub> hybrid rats that have recovered from a previous EAE attack. The mechanism by which this occurs remains to be elucidated; however, the phenomena we report here may play a critical role in this EAE reactivation.

A curious observation in this study was the enhanced perivascular expression of Ia molecules in the CNS of F<sub>1</sub> hybrids neonatally reconstituted with parental bone marrow cells. Although these animals remained healthy and without any signs of GvHD for months prior to entry into the study, it is possible that such reconstituted rats may exhibit a state of chronic, subclinical GvHD associated with tolerance to the transferred parental bone marrow, since such marrow contains small numbers of mature T cells.

This study demonstrates that in GvHD the major participants required for a T-cell-mediated immune response are present within the CNS parenchyma; it is possible that a self-sustaining immune reaction might develop if some of the infiltrating T lymphocytes, with the assistance of facultative antigen-presenting cells, recognize a CNS constituent as antigen. This hypothesis is supported by the ability of GvHD to reinduce EAE in recovered rats without additional specific antigenic stimulus (39) and by the finding that increased CNS parenchymal expression of Ia accompanies relapses of EAE (40).

The GvHD model of immunological activation of the nervous system by means of a systemic immune reaction provides a system in which to study neuroimmunological responses. In light of the absence of any appreciable inflammatory infiltrate, in contrast to the extensive expression of MHC-encoded molecules, this system offers an opportunity to investigate the mechanisms by which systemic immune responses induce immunological activation of the nervous system. In addition, the ability of a systemic immune response to induce the appearance of extensive class I and II antigen expression and T cells within the CNS may have direct implications for human CNS autoimmune diseases such as multiple sclerosis.

We thank Dr. Nicholas K. Gonatas for his continued encouragement. These studies were supported by grants from the National Multiple Sclerosis Society (RG-1685-A1) and the National Institutes of Health (KO7-NS00889).

1. Darling, J. L., Hoyle, N. R. & Thomas, D. G. T. (1981) *Immunol. Today* **2**, 176-181.
2. Rapoport, S. I. (1976) *Blood Brain Barrier in Physiology and Medicine* (Raven, New York).
3. Griffin, D. E., Hess, J. L. & Mokhtarian, F. (1984) in *Neuroimmunology*, eds. Behan, P. & Spreafico, F. (Raven, New York), pp. 193-217.
4. Barker, C. F. & Billingham, R. E. (1971) *Adv. Immunol.* **25**, 1-54.
5. Lampson, L. A. & Fisher, C. A. (1984) *Proc. Natl. Acad. Sci. USA* **81**, 6476-6480.
6. Fontana, A., Fierz, W. & Wekerle, H. (1984) *Transplantation* **38**, 293-298.
7. Lampson, L. A. & Hickey, W. F. (1986) *J. Immunol.* **136**, 4054-4063.
8. Craggs, R. I. & Webster, H. deF. (1985) *Acta Neuropathol.* **68**, 263-272.
9. Unanue, E. R. (1984) *Annu. Rev. Immunol.* **2**, 395-428.
10. Shevach, E. M. & Rosenthal, A. S. (1973) *J. Exp. Med.* **138**, 1213-1229.
11. Zinkernagel, R. M. & Doherty, P. C. (1979) *Adv. Immunol.* **27**, 51-177.
12. Matsumoto, Y., Hara, N., Tanaka, R. & Fujiwara, M. (1986) *J. Immunol.* **136**, 3668-3676.
13. Williams, K., Hart, D., Fabre, J. & Morris, P. (1980) *Transplantation* **29**, 274-279.
14. Wong, G. H. W., Clark-Lewis, I., Harris, A. W. & Schrader, J. W. (1984) *Eur. J. Immunol.* **14**, 52-56.
15. Fontana, A., Fierz, W. & Wekerle, H. (1984) *Nature (London)* **307**, 273-276.
16. Fontana, A., Weber, E., Grop, P. J., Lim, R. & Miller, J. F. (1983) *J. Neuroimmunol.* **5**, 261-269.
17. Hickey, W. F., Osborn, J. P. & Kirby, W. M. (1985) *Cell. Immunol.* **91**, 528-535.
18. Doherty, P. C., Zinkernagel, R. M., Ramshaw, I. A. & Grant, C. K. (1981) *J. Neuroimmunol.* **1**, 93-99.
19. Traugott, U., Scheinberg, L. C. & Raine, C. S. (1985) *J. Neuroimmunol.* **8**, 1-14.
20. Hofman, F. M., von Hanwehr, R. I., Dinarello, C. A., Mizel, S. B., Hinton, D. & Merrill, J. E. (1986) *J. Immunol.* **136**, 3239-3245.
21. Dameshek, W. & Schwartz, R. S. (1959) *Blood* **14**, 1151-1158.
22. Gleichmann, E., Pals, T., Rolink, A. G., Radaszkiewicz, T. & Gleichmann, H. (1984) *Immunol. Today* **5**, 324-332.
23. Tateno, M., Kondo, N., Itoh, T. & Yoshiki, T. (1985) *Clin. Exp. Immunol.* **62**, 535-544.
24. Elkins, W. L. (1971) *Prog. Allergy* **15**, 78-187.
25. Bellgrau, D., Smilek, D. & Wilson, D. B. (1981) *J. Exp. Med.* **153**, 1660-1665.
26. Hickey, W. F., Gonatas, N. K., Kimura, H. & Wilson, D. B. (1983) *J. Immunol.* **131**, 2805-2810.
27. McMaster, W. R. & Williams, A. F. (1979) *Eur. J. Immunol.* **9**, 426-433.
28. Dallman, M. J., Mason, D. W. & Webb, M. (1982) *Eur. J. Immunol.* **12**, 511-518.
29. Mason, D. W., Arthur, R. P., Dallman, M. J., Green, J. R., Spickett, G. P. & Thomas, M. L. (1983) *Immunol. Rev.* **74**, 57-82.
30. Kimura, H. & Wilson, D. B. (1984) *Nature (London)* **308**, 463-464.
31. Jeffries, W. A., Green, J. & Williams, A. F. (1985) *J. Exp. Med.* **162**, 117-127.
32. Robinson, A. P., White, T. M. & Mason, D. W. (1986) *Immunology* **57**, 239-247.
33. Bignami, A., Eng, L. F., Dahl, D. & Uyeda, C. T. (1972) *Brain Res.* **43**, 429-435.
34. Barclay, A. N. & Mason, D. W. (1982) *J. Exp. Med.* **156**, 1665-1676.
35. Griffin, W. S. T., Head, J. R. & Morrison, M. R. (1981) *Transplant. Proc.* **13**, 1237-1240.
36. Doherty, P. C. (1985) *Trends NeuroSci.* **8**, 41-42.
37. Skoskiewicz, M. J., Colvin, R. B., Schneeberger, E. E. & Russell, P. S. (1985) *J. Exp. Med.* **162**, 1645-1664.
38. Gasser, D. L., Palm, J. & Gonatas, N. K. (1975) *J. Immunol.* **115**, 431-433.
39. Willenborg, D. O., Rolinson, A. & Danta, G. (1985) *Cell. Immunol.* **90**, 614-619.
40. Sakai, K., Tabira, T., Endoh, M. & Steinman, L. (1986) *Lab. Invest.* **54**, 345-351.